

E-ISSN: 2395-1958
P-ISSN: 2706-6630
IJOS 2021; 7(1): 339-342

www.orthopaper.com
Received: 11-11-2020
Accepted: 16-12-2020

Dr. SV Gowtam
Department of Orthopaedics, Krishna Institute of Medical Sciences Deemed to be University, Karad, Maharashtra India

Dr. Amit B Garud
Department of Orthopaedics, Krishna Institute of Medical Sciences Deemed to be University, Karad, Maharashtra India

Dr. Rahul Sharma
Department of Orthopaedics, Krishna Institute of Medical Sciences Deemed to be University, Karad, Maharashtra India

Dr. Mithilesh Nikam
Department of Orthopaedics, Krishna Institute of Medical Sciences Deemed to be University, Karad, Maharashtra India

Corresponding Author:
Dr. SV Gowtam
Department of Orthopaedics, Krishna Institute of Medical Sciences Deemed to be University, Karad, Maharashtra India

Cozens phenomenon of proximal tibia

Dr. SV Gowtam, Dr. Amit B Garud, Dr. Rahul Sharma and Dr. Mithilesh Nikam

DOI: https://doi.org/10.22271/ortho.2021.v7.i1f.2506

Abstract
Introduction: The incidence of all proximal tibial fractures in children is 5 to 6/100,000.[1]It has numerous complications, such as angular deformity and leg-length discrepancy. Usually proximal tibial metaphyseal fractures are known to result in late valgus deformity.
Patient Assesment: Patient assessment involves clinical and radiological examination using plain radiography of both tibias, anteroposterior and lateral view.
Management: If spontaneous correction of the deformity is not observed and there is sufficient growth remaining, hemi-epiphysiodesis can offer the optimal solution. Permanent epiphysiodesis, be it open or percutaneous, can only be used in those approaching skeletal maturity, recognizing that, if timing is incorrect, this can result in over- or under-correction and leg length discrepancy.
Conclusion: Cozen's phenomenon is an unpredictable, uncommon and potentially under diagnosed condition. It is now possible to safely correct the valgus deformity with minimal surgery. Guided growth, tethering the proximal medial tibial physis with an extra-periosteal, nonlocking plate, and two screws are recommended.

Keywords: Cozen's, phenomenon, epiphysiodesis

Introduction
In paediatric orthopaedics itis advisable for a long-term follow-up for fractures with late onset complications. The incidence of all proximal tibial fractures in children is 5 to 6/100,000.[1]It has numerous complications, such as angular deformity and leg-length discrepancy.[2]Usually proximal tibial metaphyseal fractures are known to result in late valgus deformity. Dr Cozen, in his article published in 1953, 3 was the first to describe a valgus deformity of the tibia that occurs after a patient sustains a proximal tibial metaphyseal fracture. We tend to refer to the complication of late valgus deformity which may occur as 'Cozen's phenomenon' [48].

Theories of causes: (1) malreduction of the initial fracture (2) soft tissue interposition [7] and (3) medial tibial overgrowth secondary to fracture induced hyperaemia or due to release of the medial mechanical periosteal restraint (4) discrepancy in tibia/fibular growth with subsequent tethering of lateral tibia growth by the fibula or loss of tethering effect of the pes anserius [3, 5, 6] (5) eccentric callus formation [3, 4, 8]. Fractures of the proximal tibial metaphysis are usually present in children between the ages of three to six years following a laterally applied force to an extended knee with resulting failure of the medial metaphysis in tension. The fracture may be complete or an incomplete (greenstick fractures) with opening of the medial cortex [5]. These fractures often may appear benign, as commonly they are undisplaced and non-angulated. However, even in the absence of angulation or displacement of the fracture there may be a progressive increase in valgus angulation during fracture healing and even after immobilisation treatment has ceased [3, 51].

Patient assessment
Patient assessment involves clinical and radiological examination using plain radiography of both tibias, anteroposterior and lateral view. Angulation is measured by anteroposterior radiograph by calculating the angle between a line perpendicular to the upper epiphyseal plate and the axis of the tibial shaft below the fracture site according to Visser and

Veldhuizen [8]. Elongation is assessed clinically at final follow-up with patients standing, using the medial malleolus tip and the superior surface of the medial condyle as landmark [48]. Nenopoulos *et al*. [9] classified fractures as either undisplaced fractures, metaphyseal fractures with a medial gap involving only the medial cortex, complete displaced fractures, stress fractures, or buckle fractures [50]. Radiographic measurements included the mechanical axis deviation and zone (by quadrant), leg length discrepancy, lateral distal femoral angle (LDFA), and medial proximal tibial angle (MPTA).

Management

One management strategy is to observe the patient rather than intervene, as some authors have shown that mild deformity can correct spontaneously [10-12] However, with observation alone, distal tibial compensatory varus deformity can cause "serpentine tibia" [13]. The patella-femoral stability is hampered as the mechanical axis is lateralized away from centre of the knee leading to eccentrically loading of the lateral knee structures. Moreover, there may be long-term problems with the resulting ankle varus [14]. By consensus, proximal tibial osteotomies are contraindicated due to the high rate of complications including neurovascular injury, compartment syndrome, and a high rate of recurrence [15, 16, 47]. If spontaneous correction of the deformity is not observed and there is sufficient growth remaining, hemi-epiphysiodesis can offer the optimal solution [13, 17, 18] Permanent epiphysiodesis, be it open or percutaneous, can only be used in those approaching skeletal maturity, recognizing that, if timing is incorrect, this can result in over- or under-correction and leg length discrepancy. In contradistinction, reversible physeal tethering (guided growth) can be offered at any age and repeated as needed.

Disscusion

One of the most popular theories suggests that increased vascular response to the fracture causes asymmetric stimulation of the medial proximal tibial growth plate [19-26] Another theory is that the soft-tissue interposition at the fracture site causes the valgus deformity [8, 27-30] Some authors have attributed the deformity to loss of reduction or initial malreduction of the fracture [26, 31, 32, 38] Other authors have argued that the tethering by the fibula or the iliotibial band causes the deformity [27, 33, 34, 38] In addition, early weight-bearing after fracture and/or native valgus angulation has been blamed for the deformity before rigid callus formation [35, 36] There are postulations that the development of Cozen's phenomenon could be influenced by the child's age at the time of the fracture. This assumption was based on the known fact that there is a physiological genu valgum in children after the age of two years, which reaches its peak at the age of four years and usually resolves by the age of seven years, as is portrayed in the Salenius curve [37] Skak *et al*. [39] published a case series of 40 children aged from nine months to 12 years, with fractures of the proximal metaphysis, who were followed up between three and 14 years of the injury. He concluded that 15% of greenstick and complete fractures developed valgus deformity whereas it was not recorded either in buckle or in fissure fractures. Predisposing factors were young age and persistent valgus at the fracture site union [48].

Conservative treatment usually involves reduction and treatment with casting. Any displacement or valgus deformity must be corrected, usually by closed manipulation under anaesthetic. An above knee cast should be applied in full extension and with varus moulding to close the medial fracture gap. Treatment of non-displaced fractures is a long leg cast in near full extension with varus. The cast duration should be 6–8 weeks with serial radiographs to assess fracture position and healing. The child should return to normal activities as soon as normal movement at the knee and ankle is achieved with no residual tenderness at the fracture site [5, 51]. The authors recommended that the only indication for operative treatment was a persisting medial gap after closed manipulation. Tuten *et al*. [40] re-evaluated seven patients aged 11 months to 6.3 years with proximal tibial metaphyseal fractures, who had developed a valgus deformity within 12 months after healing of the fracture. They were followed up for an average of 15 years and three months. In all patients, the affected tibia was longer than the uninjured tibia. The authors concluded there was spontaneous improvement of the deformity. Zionts and MacEwan [41] reviewed the cases of seven children aged 11 months to six years and four months with post-traumatic tibia valga. The children were followed up for an average of 39 months. All patients exhibited overgrowth of the injured tibia. However, not all authors suggest a wait and see approach. Müller *et al* [42] published a case series of seven children aged from two years and ten months to ten years and two months who were followed up for an average of 34 months. They observed valgus deformity occurring in all cases and partial remodelling seen only in children up to the age of five years. Therefore, they recommended surgical correction and osteosynthesis as a preferred method of treatment. In fact, in a most recent paper, Morin *et al*. [43] treated 19 patients with proximal tibial fractures who developed valgus deformity by guided growth at 18 months post-fracture [48]. Burton and Hennrikus [44] later reported a 50% rate of 5 degrees valgus deformity at an average of 8.8 months. Moreover, in the age group in which Cozen's phenomenon is purported to occur, there are physiological changes to tibial morphology occurring that tend towards development of valgus alignment. These changes resolve over time as part of normal growth [50]. Some practitioners still treat Cozen's phenomena expectantly [12, 45]. However, Zionts *et al*. [12] reported that the mechanical axis remains at least 15 mm lateral to the knee centre in his series. It is unclear regarding the long-term consequences related to this, but they are likely undesirable. Mechanical axis lateralization can lead to abnormal circumduction gait, sometimes with consequent out-toeing, while altering joint reactive forces and provoking degenerative changes [46]. Although these effects take years to evolve, they may be averted by early intervention, taking advantage of the open physis to restore the mechanical axis and mitigate against limb length discrepancy. It is advisable waiting at least a year post-fracture before offering intervention. Guided growth is not time sensitive, so the decision to intervene may be further postponed unless or until symptoms evolve [49].

Conclusion

Cozen's phenomenon is an unpredictable, uncommon and potentially under diagnosed condition. It is imperative that parents are warned of lateonset valgus deformity at an early stage to help prevent distress at a later stage and instructed to seek advice from the paediatric orthopaedic team if the deformity occurs [51].

Cozen's phenomena of the tibia are manifested by medial tibial overgrowth following several causes including: fracture (most common), biopsy, bone graft harvest, traction pin insertion, and infection. By consensus, corrective osteotomy

is contraindicated, due to rapid recurrence of the deformity. It is now possible to safely correct the valgus deformity with minimal surgery. Guided growth, tethering the proximal medial tibial physis with an extra-periosteal, nonlocking plate, and two screws are recommended. Patients need to be followed until they reach skeletal maturity, with repeat intervention, if necessary [49].

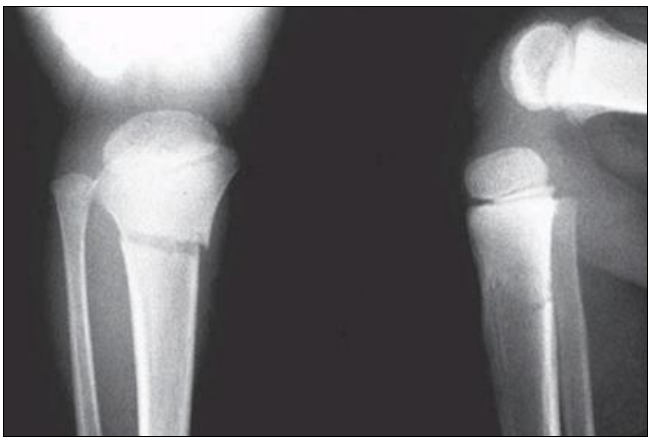

Fig 1: Anteroposterior and lateral radiographs of the proximal tibial metaphyseal fracture with an intact fibula in a 3-year-old child.

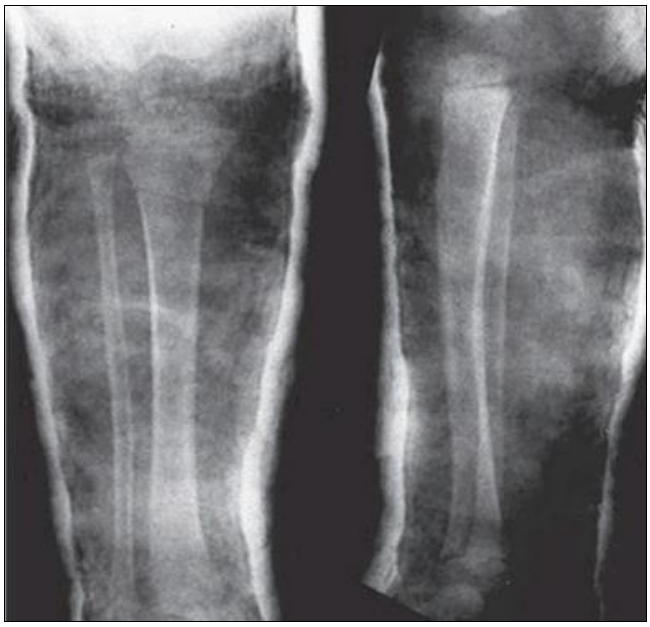

Fig 2: Anteroposterior and lateral radiograph in the initial long-leg cast demonstrate an acceptable alignment. (Photos taken from Rockwood and Wilkins's Fractures in Children page 1140)

Reference

1. Skak SV. Valgus deformity following proximal tibial metaphyseal fracture in children. Acta OrthopScand 1982;53:141-147. Crossref. PubMed.
2. Rang M. Childrens fractures. Philadelphia; Lippincott JB 1983.
3. Jackson DW, Cozen LE. Genu valgum as a complication of proximal tibial metaphyseal fractures in children. J Bone Joint Surg Am 1971;53:1571-1578.
4. Taylor SL. Tibial overgrowth: a cause of genu Valgum. J Bone Joint Surg 1963;45-A:659.
5. Egol AK, Koval KJ, Zuckerman JD. Paediatric fractures and dislocations. In: Egol AK (ed.) Handbook of fractures. Chapter 50, Part V 2010,728-730.
6. Cozen L. Fracture of the proximal portion of the tibia in children followed by valgus deformity. Surg Gynecol Obstet 1953;97:183-188.
7. Weber BG. Fibrous interposition causing valgus deformity after fracture of the upper tibial metaphysis in children. J Bone Joint Surg Br 1977;59-B:290-292.
8. Visser JD, Veldhuizen AG. Valgus deformity after fracture of the proximal tibial metaphysis in childhood. Acta Orthop Scand 1982;53:663-667. Crossref. PubMed.
9. Nenopoulos S, Vrettakos A, Chaftikis N, *et al*. The effect of proximal tibial fractures on the limb axis in children. Acta Orthop Belg 2007;73:345-353.
10. Best TN. Valgus deformity after fracture of the upper tibiain children. J Bone Joint Surg 1973;55B:222.
11. Tuten HR, Keeler KA, Gabos PG *et al*. Post-traumatic tibia valga in children: a long-term follow-up note. J Bone Joint Surg Am 1999;81(6):799-810.
12. Zionts LE, McEwen GD. Spontaneous improvement of post-traumatic tibial valga. J Bone Joint Surg Am 1986;68A:680-686.
13. Robert M, Kouri N, Carlioz H *et al*. Fractures of the proximal tibial metaphysis in children: Review of a series of 25 cases. J Pediatr Orthop 1987;7:444-449.
14. Tarr RR, Resnick CT, Wagner KS *et al*. Changes in tibiotalar joint contact following experimentally induced tibial angular deformity. Clin Orthop 1985;199:72-80.
15. Dietz FR, Merchant TC. Indications for osteotomy of the tibia in children. J Pediatr Orthop 1990;10:486-490.
16. Mycoskie P. Complications of osteotomies about the knee in children. Orthopedics 1981;4:1005-1015.
17. Bowen JR, Leahey JL, Zhang ZH *et al*. Partial epiphysiodesisat the knee to correct angular deformity. Clin Orthop 1985;198:184-190.
18. Phemister DB. Operative arrestment of longitudinalgrowth of bones in the treatment of deformities. J Bone JointSurg 1933;15:1-15.
19. Blount WP. Fractures in children. Baltimore, PA: Williams and Wilkins Co 1954. Crossref.
20. Griffin PP. The lower limb. In: Lovell WW, Winter RB, eds. Pediatric orthopaedics Philadelphia, PA: J B Lippincott 1978,884-886.
21. Houghton GR, Rooker GD. The role of the periosteum in the growth of long bones. Anexperimental study in the rabbit. J Bone Joint Surg Br 1979;61-B:218-220. Crossref. PubMed.
22. Green NE. Tibia valga caused by asymmetrical overgrowth following a nondisplaced fracture ofthe proximal tibial metaphysis. J Pediatr Orthop 1983;3:235-237. Crossref. PubMed.
23. Jordan SE, Alonso JE, Cook FF. The etiology of valgus angulation after metaphyseal fracturesof the tibia in children. J Pediatr Orthop 1987;7:450-457. Crossref. PubMed.
24. Aronson DD, Stewart MC, Crissman JD. Experimental tibial fractures in rabbit's simulating proximal tibial metaphyseal fractures in children. *Clin Orthop Relat Res* 1990;255:61-67.
25. Ogden JA. Skeletal injury in the child. New York, NY: Springer Verlag 1999.
26. Lalonde F, Wenger D. Tibia. In: Rang M, Pring M, Ray D, eds. Rang's children's fractures.Philadephia, PA: Lippincott Williams & Wilkins 2005.
27. Jackson DW, Cozen L. Genu valgum as a complication of proximal tibial metaphyseal fracturesin children. J Bone Joint Surg Am 1971;53-A:1571-1578. Crossref.
28. Weber BG. Fibrous interposition causing valgus

deformity after fractures of the upper tibialmetaphysis in children. J Bone Joint Surg Br 1977;59-B:290-292. Crossref. PubMed.
29. Coates R. Knock knee deformity following upper tibial greenstick fractures. J Bone Joint Surg Br 1977;59-B:516.
30. Rooker GD, Coates RL. Deformity after greenstick fractures of the upper tibial metaphysis. In:Houghton GR, Thompson GH, eds. Orthopaedics 1. Problematic musculoskeletal injuries inchildren. London: Butterworths 1983:1-13.
31. Salter RB, Best TN. Pathogenesis and prevention of valgus deformity following fractures of theproximal metaphyseal region of the tibia in children. J Bone and Joint Surg Br 1972;54-B:767.
32. Bahnson DH, Lovell WW. Genu valgum following fracture of the proximal tibial methaphysis inchildren. Orthop Trans 1980;4:306.
33. Goff CW. Surgical treatment of unequal extremities. Springfield: Thomas 1960.
34. Taylor SL. Tibial overgrowth: a cause of genu valgum. J Bone Joint Surg Am 1963;45-A:659.
35. Lehner A, Dubas J. Secondary deformities after separation of epiphyses and after fracturesclose to epiphysial lines. Helv Chir Acta 1954;21:388-410. PubMed.
36. Pollen AG. Fractures and dislocations in children Edinburgh. London: Churchill Livingstone 1973.
37. Salenius P, Vankka E. The development of the tibiofemoral angle in children. J Bone Joint Surg Am 1975;57-A:259-261. Crossref.
38. Cozen L. Fracture of the proximal portion of the tibia in children followed by valgus deformity.Surg Gynecol Obstet 1953;97:183-188. PubMed.
39. Skak SV, Jensen TT, Poulsen TD. Fracture of the proximal metaphysis of the tibia in children. Injury 1987;18:149-156. Crossref. PubMed.
40. Tuten HR, Keeler KA, Gabos PG, Zionts LE, MacKenzie WG. Posttraumatic tibia valga inchildren. A long-term follow-up note. J Bone Joint Surg Am 1999;81-A:799-810. Crossref.
41. Zionts LE, MacEwen GD. Spontaneous improvement of post-traumatic tibia valga. J Bone JointSurg Am 1986;68-A:680-687. Crossref.
42. Müller I, Muschol M, Mann M, Hassenpflug J. Results of proximal metaphyseal fractures in children. Arch Orthop Trauma Surg 2002;122:331-333. Crossref. PubMed.
43. Morin M, Klatt J, Stevens PM. Cozen's deformity: resolved by guided growth. Strategies Trauma Limb Reconstr 2018;13:87-93. Crossref. PubMed.
44. Burton A, Hennrikus W. Cozen's phenomenon revisited. J PediatrOrthop B 2016;25:551-555.
45. Zionts LE. Fractures around the knee in children. J Am Acad Orthop Surg 2002;10(5):345-355.
46. Stevens P, MacWilliams B, Mohr A Gait analysis of staplingfor genu valgum. J Pediatr Orthop 2004;24:70-74.
47. Herring JA. Post-traumatic valgus deformity of the tibia. JPediatr Orthop 1981;1:435-439.
48. Does Cozen's phenomenon warrant surgical intervention? Journal of children's orthopaedics (https://online.boneandjoint.org.uk/doi/full/10.1302/1863-2548.14.190147)
49. Cozen's deformity: resolved by guided growth (https://doi.org/10.1007/s11751-018-0309-y)
50. Prevalence of cozen's phenomenon of the Proximal Tibia (https://journals.lww.com/pedorthopaedics/Abstract/2019/07000/Prevalence_of_Cozen_s_Phenomenon_of_the_Proximal.7.aspx)
51. Cozen's phenomenon: a reminder; Scottish Medical Journal (http://scm.sagepub.com/content/58/3/e10)