



International Journal of Orthopaedics Sciences

E-ISSN: 2395-1958
P-ISSN: 2706-6630
IJOS 2021; 7(1): 242-244
© 2021 IJOS
www.orthopaper.com
Received: 21-11-2020
Accepted: 26-12-2020

Dr. Randhir Kumar
PG Student, Department of
Orthopaedics, Darbhanga
Medical College and Hospital,
Darbhanga, Bihar, India

Dr. Nand Kumar
Professor and H.O.D.,
Department of Orthopaedics,
Darbhanga Medical College and
Hospital, Darbhanga, Bihar,
India

Dr. Ashutosh Kumar
Assistant Professor,
Orthopaedics, Department of
Trauma and Emergency, Indra
Gandhi Institute of Medical
Sciences, Patna, Bihar, India

Comprehensive study of fracture distal end radius with plating and k wire fixation

Dr. Randhir Kumar, Dr. Nand Kumar and Dr. Ashutosh Kumar

DOI: <https://doi.org/10.22271/ortho.2021.v7.i1d.2490>

Abstract

Distal end radius fracture is a common fracture seen in the routine orthopedic OPD. The optimal management of distal radius fractures remains controversial.

AIM: To compare functional outcomes following volar plating and K-wire fixation of distal end radius fractures and compare which method produced better result. The functional outcome in terms of the range of movements, pain, and grip strength of the patients was assessed at 6 months in both groups by demerit score system of Gartland and Werley.

Result: Functional outcome as per Gartland and Werley was 95% excellent to good results in plating group as compared to 75% in K-wire fixation group.

Conclusion: The study emphasizes that open reduction and internal fixation with volar plating have excellent functional outcome when compared to K-wire fixation in distal radius fractures. When considering the cost, K-wire fixation is preferred over volar plating.

Keywords: Distal radius fracture, K- wire, fixation, volar plating

Introduction

Fractures of the distal radius are the most common fractures of all. 30% of the patients treated in the emergency centers have an injury to the wrist, and majority of them have distal radius fractures [3]. Abraham Colle of Dublin, Ireland in the year 1814 was the first to describe what is now commonly known as Colles' fracture; he had described it as a fracture involving distal corticocancellous junction of the radius with classical deformity [4, 5]. Management protocols for these fractures have undergone significant advancement over the preceding years. These can be treated conservatively using closed reduction and immobilization in a plaster cast, which may lead to early displacement; hence, skeletal fixation to maintain the reduction has been recommended [6, 7]. Methods such as external fixation used for ligamentotaxis, percutaneous fixation with K-wires or plate osteosynthesis or combination of all the above have been advocated to achieve adequate reduction and fixation of displaced distal radius fractures [8].

Aims and Objectives

To compare functional outcomes following volar plating and K-wire fixation of distal end radius fractures and compare which method produced better outcomes.

Materials and Methods

An observational study was done at the Department of Orthopaedics, in DMCH darbhanga the duration of the study was from July 2018 to august 2020. All patients with radiologically confirmed fractures of distal end radius were included in the study. We excluded, undisplaced fractures, those who have not attained skeletal maturity, open fractures of distal radius associated with neurovascular deficit. All patients who satisfied the inclusion and exclusion criteria during the study period were included in the study until sample size was attained. The patients were allocated into two groups of 20 patients each. One group was treated by open reduction and volar plating (Group A), and the other group was treated by closed reduction percutaneous Kwire fixation and cast application (Group B).

Corresponding Author:
Dr. Ashutosh Kumar
Assistant Professor,
Orthopaedics, Department of
Trauma and Emergency, Indra
Gandhi Institute of Medical
Sciences, Patna, Bihar, India

Outcome Measurements

The functional outcome in terms of range of movements, pain, and grip strength of the patients were assessed at 6 months in both groups by Dr. Ashutosh. Demerit score system of Gartland and Werley (Fig. 1). The range of movement of the wrist and forearm was measured using a goniometer. Grip strength was assessed by a dynamometer. The intensity of pain was recorded on a visual analog scale from 1 to 10.

Method of Collection

All patients who attend the outpatient/casualty of Orthopaedic Department at Darbhanga medical college, Bihar during stipulated time period, having distal end radius fracture were included in the study. All fractures were classified according to Fernandez classification, and only Type 2 and 3 fracture patterns were included in the study (Table 1). Functional assessment was done at 6 months with the help of Gartland and Werley score system. Conclusions were drawn at the end of the study. After obtaining ethical clearance from the Institutional Ethics committee, the study was conducted among the study populations after obtaining written informed consent. Group A (Fig. 2 and 3) was operated through volar approach, under tourniquet control and the use of a volar T plate. Group B was treated by closed reduction and K-wire fixation (Fig. 4). Similar plaster splints, antibiotic (cephalosporins), and analgesic regimens were used in both groups. Stitches were removed in Group A after 10 days, and a gentle physiotherapy plan was instituted. K-wires were removed at 5–6 weeks in the other group and cast continued for 2 more weeks. A similar rehabilitation program consisting of assisted and active range of motion exercises was done in both the groups for 3 months.

Results

The present study consists of 20 cases of distal radial fractures treated 12 cases were closed fractures 8 cases were open fractures. All cases were followed the following are the observations made and the available data are analyzed as

follows.

Table 1: Age Incidence

Age in Years	No. of Cases	Percentage
21 - 30	5	25
31- 40	5	25
41 - 50	4	20
51 - 60	4	20
61 - 70	2	08

Table 2: Sex Incidence

Sex	No. of Cases	Percentage
Male	12	60
Female	08	40

Table 3: Side of Involvement

Side	No. of Cases	Percentage
Right	12	60
Left	08	40

Table 3: Mode of Injury

Mechanism of Injury	No. of Cases	Percentage
Road traffic accident (RTA)	10	50
Fall on outstretched hand (FOOH)	10	50

Table 5: Extra articular and intra articular fracture

Type	NO.	%
Extra articular Fractures	12	60
Intra articular Fractures	08	40

Table 6: Type of fixation

Type of Fixation	No. of Cases	Percentage
Closed Reduction and percutaneous pinning with K wire	12	60
Open Reduction and Internal Fixation with plate and screws (OR&IF)	08	40

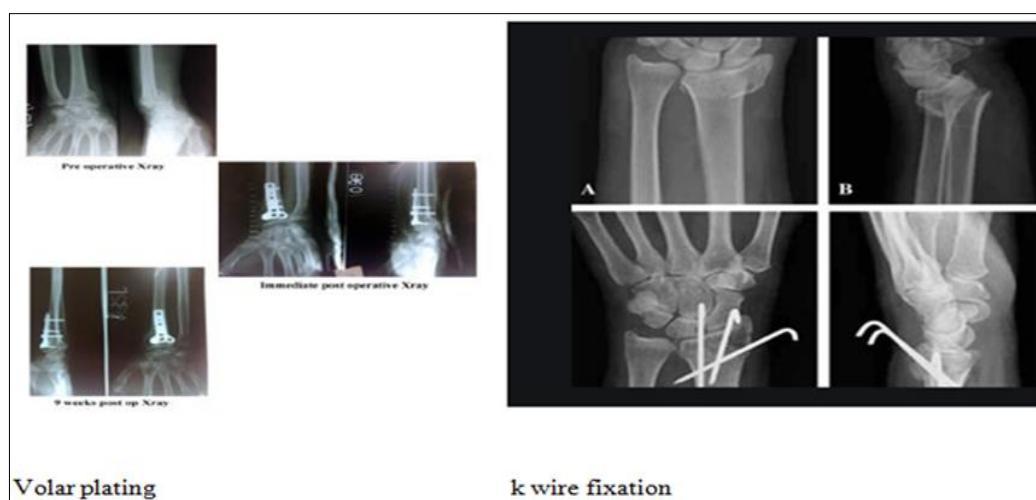


Fig 1: Show the volar plating k wire fixation

Discussion

The fractures of the distal end of radius despite being the most common upper extremity fractures continue to pose a therapeutic challenge. The aim is to regain the normal range of movements and anatomical integrity without pain. Treatment modalities have undergone significant advancements due to improved imaging techniques, which have provided a better understanding of fractures and

explained the effects of the different injury types on fracture formation and factors that lead to instability. Kiernan C in his study compared radiological outcomes in those treated with volar locking plate to those undergoing manipulation and Kwire fixation in the 20–65 years population. According to them, volar plating has superior advantage when compared with K-wire fixation. Beharrie *et al.*, in 2004, published a study comparing these two methods. They showed a clear

advantage of K-wire fixation over T-plate method. Conclusion The study emphasizes that open reduction and internal fixation with volar plating have better functional outcome when compared to K-wire fixation in distal 4] Kerala Jou patients had an excellent outcome, 2 (10%) patients had good outcome, and 5 (25%) patients had fair outcome (Table 2 and Graph 3). Discussion the fractures of the distal end of radius despite being the most common upper extremity fractures continue to pose a therapeutic challenge. The aim is to regain the normal range of movements and anatomical integrity without pain. Treatment modalities have undergone significant advancements due to improved imaging techniques, which have provided a better understanding of fractures and explained the effects of the different injury types on fracture formation and factors that lead to instability. Kiernan C in his study compared radiological outcomes in those treated with volar locking plate to those undergoing manipulation and K wire fixation in the 20–65 years population. According to them, volar plating has superior advantage when compared with K-wire fixation. Beharrie *et al.*, in 2004, published a study comparing these two methods. They showed a clear advantage of K-wire fixation over T-plate method.

Conclusion

The study emphasizes that open reduction and internal fixation with volar plating have better functional outcome where there is significant intra articular displacement while K-wire fixation is better in extra articular fracture.

References

1. Khan JI, Hussain FN, Mehmood T, Adil O. A comparative study of functional outcome of treatment of intra articular fractures of distal radius fixed with percutaneous Kirschner's wires vs T-plate. *Pak J Med Sci* 2017;33:709-13.
2. Kwok IH, Leung F, Yuen G. Assessing results after distal radius fracture treatment. *Geriatr Orthop Surg Rehabil* 2011;2:155-60.
3. Johnson NA, Dias JJ, Wildin CJ, Cutler L, Bhowal B, Ullah AS *et al.* Comparison of distal radius fracture intra-articular step reduction with volar locking plates and K wires: A retrospective review of quality and maintenance of fracture reduction. *J Hand Surg Eur* 2017;42:144-50.
4. Rizzo M, Katt BA, Carothers JT. Comparison of locked volar plating versus pinning and external fixation in the treatment of unstable intraarticular distal radius fractures. *Hand NYN* 2008;3:111-7.
5. Canale ST, Beaty JH. *Campbell's Operative Orthopaedics*. 12th ed., St. Louis, Mo; London: Mosby 2012;4:4664.
6. Khan. Volar Plating in Distal End Radius Fractures and its Clinical and Radiological Outcome as Compared to other Methods of Treatment. Available from: <http://www.joas.in/article.asp?issn=2319-2585;year=2016;volume=4;issue=1;spage=40;epage=44;au last=Khan>. [Last cited on 2018 Mar 23].
7. Bucholz RW, Court-Brown CM, Heckman JD, Tornetta P, editors. *Rockwood and Green's Fractures in Adults: Two Volumes Plus Integrated Content Website*. 7th ed. Philadelphia, PA: Wolters Kluwer 2009, 2296.
8. Brennan SA, Kiernan C, Beecher S, O'Reilly RT, Devitt B, Kearns S *et al.* Volar plate versus k-wire fixation of distal radius fractures. *Injury* 2015;47:372-6.
9. Changulani M, Okonkwo U, Keswani T, Kalairajah Y.

Outcome evaluation measures for wrist and hand – Which one to choose? *Int. Orthop* 2008;32:1-6.