



E-ISSN: 2395-1958
P-ISSN: 2706-6630
IJOS 2021; 7(1): 182-184
© 2021 IJOS
www.orthopaper.com
Received: 27-11-2020
Accepted: 30-12-2020

Dr. Anvesh G
Associate Professor,
Department of Orthopedics,
Narayana Medical College,
Nellore, Andhra Pradesh, India

Dr. Maddu. Indhra Kumar Varma
Post Graduate,
Department of Orthopedics,
Narayana Medical College,
Nellore, Andhra Pradesh, India

Corresponding Author:
Dr. Anvesh G
Associate Professor,
Department of Orthopedics,
Narayana Medical College,
Nellore, Andhra Pradesh, India

Clinical outcome for tibial shaft fractures treated with intramedullary nailing through suprapatellar approach

Dr. Anvesh G, Dr. Maddu. Indhra Kumar Varma

DOI: <https://doi.org/10.22271/ortho.2021.v7.i1c.2479>

Abstract

Tibial fractures have a bimodal distribution with low energy spiral pattern being more common in patients over 50 years of age and high energy transverse and comminuted being more common in patients under 30 years of age. This was a prospective study included patients with tibial shaft fractures treated with intramedullary nailing through suprapatellar approach in semi extended position of knee in 20 patients at Our Institute of Orthopaedics and Traumatology. In our study out of 16 patients, 10 patients had grade 2 compound fractures (62.5%), the remaining 6 patients had grade 1 compound fracture (37.5%).

Keywords: tibial shaft fractures, intramedullary nailing, suprapatellar approach

Introduction

Tibia is a long tubular bone with a triangular cross section in medial side of the leg. The upper end can differ from lower end as it is much larger. The medial and lateral side of the bone can be distinguished by examining the lower end, this end has prominent downward projection, the medial malleolus on its medial side ^[1]. The anterior and posterior aspects can be distinguished by examining the shaft, has a sharp anterior border. The upper part and medial and lateral condyle are separated by intracondylar area. The anterior aspect of upper end of tibia is marked by another projection called tibial tuberosity ^[2].

Tibial fractures have a bimodal distribution with low energy spiral pattern being more common in patients over 50 years of age and high energy transverse and comminuted being more common in patients under 30 years of age ^[3].

However high energy tibial fracture in younger patients are approximately twice as common in males than females. High energy tibial diaphyseal fractures are commonly associated with vehicular trauma.

In surgical treatment intramedullary nail fixation remains the treatment of choice for displaced and undisplaced tibial shaft fractures in adult population.

Recent advance in nail design and reduction techniques have expanded the indications for intramedullary nail fixation to more proximal as well as more distal tibia fractures involving metaphyseal area. Establishing an anatomic starting point appears to be crucial in these fracture patterns. Suprapatellar nailing in the semi extended position has recently been suggested as a safe and effective surgical technique. This technique allows establishment of an appropriate starting point and semi extended position facilitates the fracture reduction of apex anterior deformity ^[4].

Methodology

This was a prospective study included patients with tibial shaft fractures treated with intramedullary nailing through suprapatellar approach in semi extended position of knee in 20 patients at Our Institute of Orthopaedics and Traumatology.

Inclusion Criteria

- Age greater than or equal to 20 years

- Closed fractures of both bone leg
- Segmental fractures of tibia
- Proximal one third of tibia fracture
- All diaphyseal fracture of tibia
- Ipsilateral femoral fractures
- Stiff knee

Exclusion Criteria

- Paediatric fractures of tibia
- Age more than 70 years
- Associated comorbidities
- Intra articular extension fracture

Results

In our study 4 patients out of 20 patients had closed fractures (20%), the remaining 16 patients had open fractures (80%).

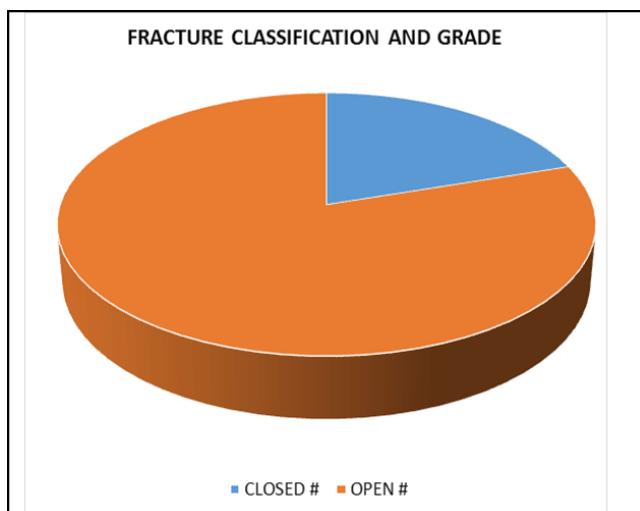


Fig 1: Fracture Classification

In our study out of 16 patients, 10 patients had grade 2 compound fractures (62.5%), the remaining 6 patients had grade 1 compound fracture (37.5%).

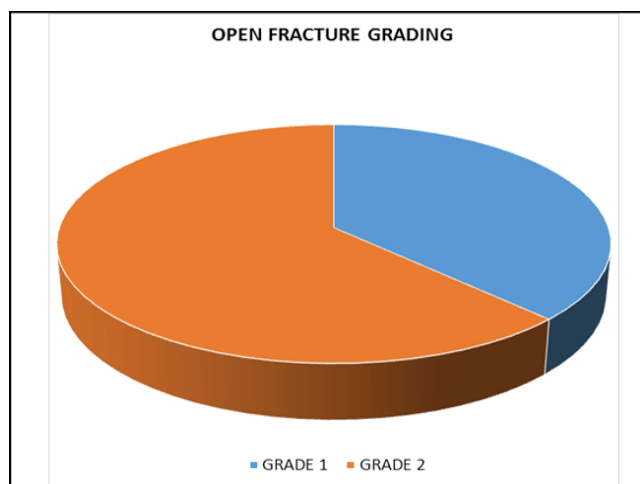


Fig 2: Fracture Grading

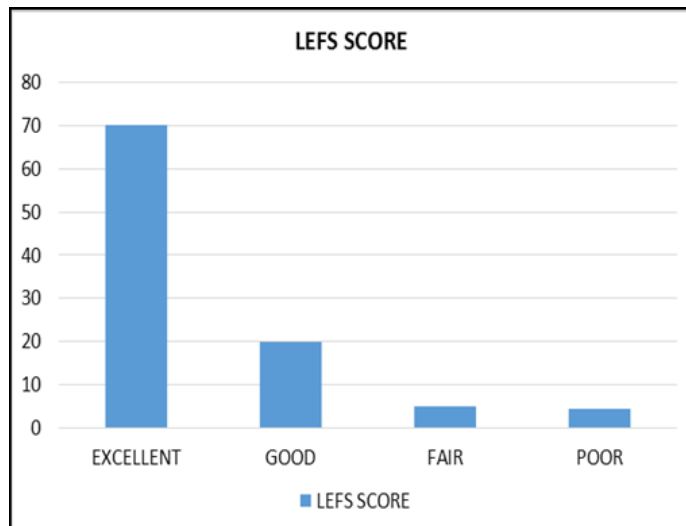


Fig 3: LEFS Score

In our study analysis out of 20 patients, 14 (70%) patients had excellent LEFS score, 4 (20%) patients had good LEFS score 1 (5%) patients had fair LEFS score 1 (5%) patients had poor LEFS score.

Discussion

Roy W. Sanders *et al.* [5] studied semi extended intramedullary nailing of tibia using suprapatellar approach: Radiographical Results and Clinical Outcomes at a minimum of 12 month follow up, report that the procedure resulted in excellent tibial alignment, union, knee range of movement with no apparent sequela in the patellofemoral joint based on immediate arthroscopy and 1 year MRI scans. Even more interesting was the absence of anterior t ibial pain typically found in upto 25%-60 % of cases where tibia nail is inserted in standard fashion.

Thirty six patients were available for follow-up at a minimum 1 year after the index procedure. All but two fractures healed after the index procedure there was one radiographic malunion. (2.7%) One patient complained of mild pain at the scar but no patient complained of anterior knee pain (2.7%). In 13 of 15 patients undergoing arthroscopic assessment of patellofemoral joint and pre-nail and post-nail insertion no cartilage changes. Two patients had Grade 2 chondromalacia of trochlea immediately after the procedure, but these did not correspond with either MRI scans or clinical findings at one year.

Ole Brink *et al.* [6] studied 25 patients in suprapatellar nailing of tibial fractures: Surgical hints. At our institution we have used the technique for 4 years with different system. In the beginning we used it for selected proximal fractures and later on distal tibial fractures and now also on shaft fractures. The technique also has been found to be useful in patient with multiple fractures such as ipsilateral femoral fractures, because all fractures can be operated without the need for manual traction or rearrangement. The method appears to be safe with no greater rate of complications compared with tradition methods.

Beigang Fu *et al.* [7] studied locked META intramedullary nailing fixation for tibial fractures via suprapatellar approach for 23 patients. The biggest advantage of suprapatellar approach was the extension of knee during the operation which was very useful in the treatment for complex metaphyseal and diaphyseal tibial fractures. In this study all 13 patients with tibial fractures of metaphyses, four cases of tibial multisegmental fractures and two cases of ipsilateral femoral fractures obtained satisfactory reduction and good recovery outcomes with no loss of reduction and aggravating displacement in the follow-up except for one case of proximal tibial fractures with 5 degree angulation Sanders *et al.* [8] have initially reported the clinical and radiographic results of tibial fractures after suprapatellar intramedullary nailing found excellent tibial alignment, union and range of motion of knee joint. The study did not identify significant sequelae affecting the patellofemoral cartilage as per MRI arthroscopic evolution in particular it was not worthy that in their series did not identify any patient with postoperative knee pain at minimum 12 months of followup.

Conclusion

Reamed locked intramedullary nailing remains the standard treatment for displaced tibial shaft fractures. In our study we describe surgical hints in addition to the benefits of suprapatellar approach. A correct starting point remains a crucial part of surgical procedure.

References

1. Moghaddam A, Zietzschmann S, Bruckner T, Schmidmaier G. Treatment of atrophic tibia non-unions according to diamond concept: results of one- and two-step treatment. *Injury* 2015; 46:S39-50.
2. Franke J, Hohendorff B, Alt V *et al.* Suprapatellar nailing of tibial fractures-Indications and technique. *Injury* 2016; 47:495-501.
3. Stinner DJ, Mir H. Techniques for intramedullary nailing of proximal tibia fractures. *Orthop Clin North Am* 2014; 45:33-45.
4. Krettek C, Miclau T, Schandelmaier P *et al.* The mechanical effect of blocking screws (Poller screws) in stabilizing tibia fractures with short proximal or distal fragments after insertion of small-diameter intramedullary nails. *J Orthop Trauma* 1999; 13:550-3.
5. Sanders RW, Di Pasquale TG, Jordan CJ *et al.* Semiextended intramedullary nailing of the tibia using a suprapatellar approach: radiographic results and clinical outcomes at a minimum of 12 months follow-up. *J Orthop Trauma* 2014; 28:S29-39.
6. Buehler KC, Green J, Well TS, Duwelius P3. A technique for intramedullary nailing of proximal third tibia fractures. *J Orthop Trauma*. 1997; 11:218-223.
7. Beltran MJ, Collinge CA, Patzkowski JC *et al.* Intra-articular risk of suprapatellar nailing. *Am J Orthop*. 2012; 12:546-550.
8. Katsoulis E, Court-Brown C, Giannoudis PV. Incidence and aetiology of anterior knee pain after intramedullary nailing of the femur and tibia. *J Bone Joint Surg Br*. 2006; 88:576-580.