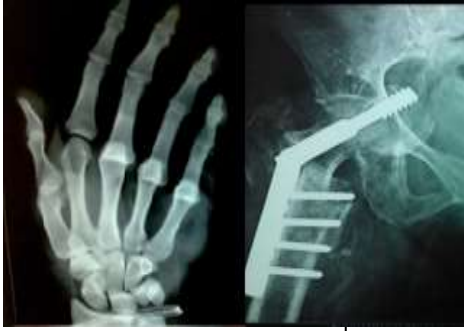



# International Journal of Orthopaedics Sciences

E-ISSN: 2395-1958  
P-ISSN: 2706-6630  
IJOS 2021; 7(1): 157-161  
© 2021 IJOS  
[www.orthopaper.com](http://www.orthopaper.com)  
Received: 08-11-2020  
Accepted: 17-12-2020

**Dr. PG Jagannath**  
Assistant Professor,  
Department of Orthopaedics,  
ESIC Medical College and  
Hospital, KK Nagar, Chennai,  
Tamil Nadu, India

**Dr. SN Lokesh Kumar**  
Assistant Professor,  
Department of Orthopaedics,  
SRM Medical College and  
Hospital, SRMIST University,  
Kattankulathur, Chennai, Tamil  
Nadu, India

**Dr. PG Vijay Karthik**  
Assistant Surgeon, Government  
Medical College, Thiruvallur,  
Chennai, Tamil Nadu, India

**M Durai Kumar**  
Associate Professor,  
Department of Orthopaedics,  
ESIC and PGIMS, Chennai,  
Tamil Nadu, India

**Corresponding Author:**  
**Dr. SN Lokesh Kumar**  
Assistant Professor,  
Department of Orthopaedics,  
SRM Medical College and  
Hospital, SRMIST University,  
Kattankulathur, Chennai, Tamil  
Nadu, India

## Management of unstable lateral end clavicle fracture with suture anchor technique - single centre experience

**Dr. PG Jagannath, Dr. SN Lokesh Kumar, Dr. PG Vijay Karthik and M Durai Kumar**

DOI: <https://doi.org/10.22271/ortho.2021.v7.i1c.2475>

### Abstract

Fracture of the lateral end clavicle especially displaced fractures like the type II b are difficult to manage. Superior displacement due to deforming forces of trapezius and the small distal lateral fracture fragment cause difficulty in surgical management. Suture anchor technique is an easy and reliable way of fixing these fractures and has a superior functional outcome. This study illustrates the functional outcome following suture anchor fixation of lateral end clavicle fractures.

**Materials and Methods:** 153 fracture clavicles since 2011 out of which 23 are lateral end clavicle fracture of which are stable and treated conservatively among these 11 patients had type 2 unstable distal end fracture and thus selected to undergo surgical intervention.

**Results:** A total of 11 patients with type II clavicle fractures were enrolled in our study (9 males, 2 females). Mean patient age was  $43.1 \pm 8.5$  years, and mean follow-up period was 25.3 months (range: 12–56 months). CMS scores for all 11 patients at 3 and 12 months postoperatively were  $73.10 \pm 5.43$  and  $91.63 \pm 3.72$ , respectively.

**Conclusion:** Several methods of fixation with K wire, open reduction and internal fixation (ORIF) with plate and screws spanning the acromioclavicular joint, hook plate, coracoclavicular screw fixation and suture anchor fixation wires have been described in literature. For unstable lateral end clavicle fractures stabilization with suture anchor is a safe, reliable management and less technically demanding mode of management with good results.

**Keywords:** Unstable lateral end clavicle fracture, suture anchor fixation, novel technique

### Introduction

Distal clavicle fracture is caused by trauma with direct force on the bone due a fall in adults. It accounts for 2.6 – 4% of all adult fractures [1]. Though fracture of the shaft is the commonest, lateral end fracture constitutes 21–28% of all clavicle fractures. Of these 10–52% are displaced fractures [2]. Treatment modalities vary from immobilization to operative reduction depending on the stability of the fracture. Several methods of fixation with K wire, open reduction and internal fixation (ORIF) with plate and screws spanning the acromioclavicular joint, hook plate, coracoclavicular screw fixation and suture anchor fixation wires have been described in literature. In this study we have reviewed the technique reliability reproducibility and ease of surgery in fixing the lateral end clavicle fracture with suture anchors.

### Materials and Methods

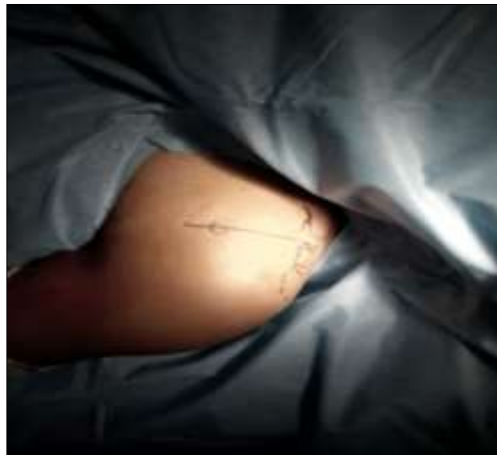In the Department of Orthopedics at our institute which is a teaching medical college hospital, we have seen 153 fracture clavicles since 2011 out of which 23 are lateral end clavicle fractures. Twelve of these cases had a stable fracture pattern and were treated conservatively. Eleven patients had type 2 unstable distal end fracture and thus selected to undergo surgical intervention. The patients after evaluation for fitness for surgery underwent ORIF with suture anchor.

The patients were selected after they were eligible under our inclusion criteria which included only a) Acute trauma, b) Skeletally mature patients c) Closed fractures

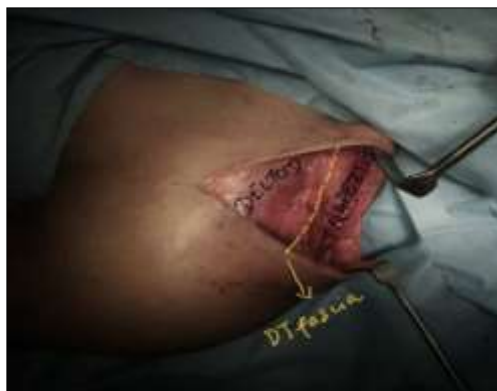Exclusion criteria included patients with multiple, pathologic or bilateral clavicle fractures and other.

**Surgical technique**

The patients were put in Beach chair position under General anaesthesia. Superior approach to the Acromioclavicular joint was used. A longitudinal incision was made approximately 5 cm from the distal clavicle to the coracoid process. Before incision thorough infiltration with tumescent solution containing 0.1ml adrenaline (1 in 1000) diluted with 500ml of 0.9% NaCl solution was injected the incision region to reduce the bleeding.

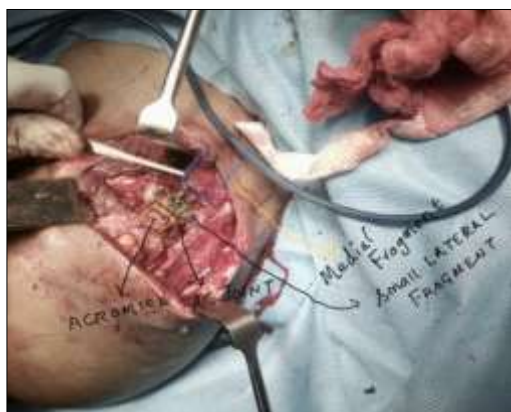


**Fig 1:** Delto-trapezial interval



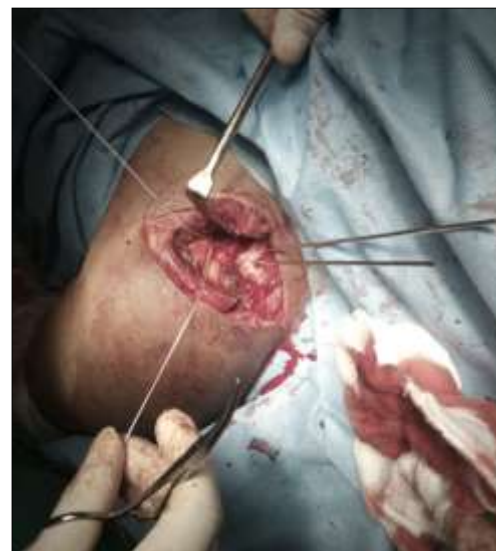**Fig 2:** Longitudinal skin incision over the shoulder

The subcutaneous tissue was undermined in both medial and lateral direction, thus exposing the delto-trapezial fascial interval. The delto-trapezial fascia is split in line and the deltoid muscle is split vertically in line with the coracoid base, where the suture anchor is to be anchored. The fractured fragments are identified.



**Fig 3:** Intra-operative picture depicting the anatomical landmarks post fixation

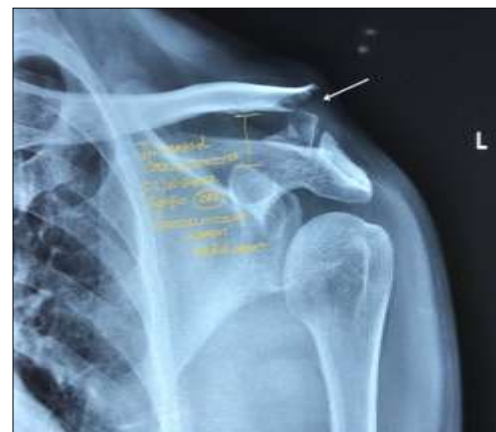The base of the coracoids is identified and a 2.7-mm drill was used to create 2 holes in the clavicle. Suture anchor of size 5 mm inserted and correspondingly drill holes were drilled in the medial end of the clavicle 1 cm away from the fracture site. A single suture anchor was inserted in the base of the coracoids, and the arms were pulled through the drill holes and tied over the clavicle in an over reduction position. If a butterfly fragment is there then it is to be held with the cerclage ethibond (number 2) and then the keeping the fracture reduced the suture anchor fibres are secured with knotting. Fixation is stable hemostasis secured and wound closed in layers. Delto-trapezial fascia closed also the deltoid split. Sterile dressing was done. Shoulder immobilizer was applied postoperatively.



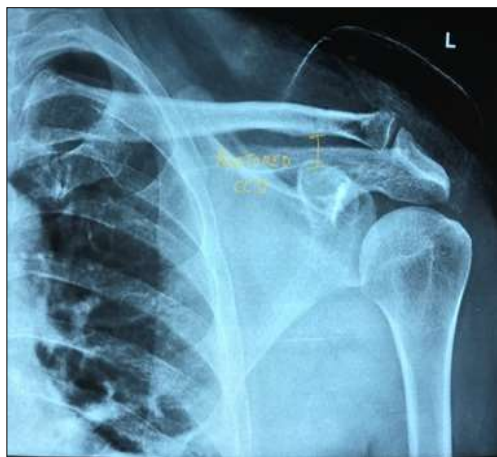
**Fig 3:** Fragments reduced and fixed with suture

**Rehabilitation protocol advised to our patients**

Dressing change was done in the second Postoperative day. Suture removal done on POD 14. Shoulder immobilisation till 3 weeks. Range of motion activities started from the 4th week onwards. 4th to 5th week - Abduction and rotation, gravity eliminated. 6th week to 9th week - abduction, flexion and rotation against gravity. After 12 weeks repeat x ray were done to confirm the fracture union patient advised for gradual weight lifting. Return to intense activities was possible at the end of the third month. All patients were followed at postoperative months 3, 6, and 12 and underwent clinical and radiographic evaluation after 1 year.



**Fig 4:** Preop X ray depicting lateral end clavicle fracture type 2



**Fig 5:** Post-operative X ray after fixation with suture anchor

Post-operative assessment of the joint was done at postoperative months 3 and 12 months using the Constant-Murley Shoulder Outcome Score (CMS). The Visual Analog Scale (VAS) questionnaire was used at every follow up to evaluate patient satisfaction. Radiological assessment was done at all follow ups to assess. During follow-up, complications including infection and malunion or nonunion (based on Zanca radiographic view) were evaluated. Loss of reduction and clavicular shortness were evaluated in each patient by measuring and comparing the side of fracture with

the opposite side on follow-up radiographs.

**Results**

The age group of the study cohort ranged from 21 to 53 years and male: female ratio 5:1.

A total of 11 patients with type II clavicle fractures were enrolled in our study (9 males, 2 females). Mean patient age was 43.1±8.5 years, and mean follow-up period was 25.3 months (range: 12–56 months). CMS scores for all 11 patients at 3 and 12 months postoperatively were 73.10±5.43 and 91.63±3.72, respectively Mean time interval between injury and surgery was 12.22±5.21 days. No superficial infection was recorded in any patients. According to VAS scores, patient satisfaction was 8.15±1.18 at 3 months and 9.12±0.89 at 12 months. 8 patients were in excellent condition and 3 patients were in good condition at 12 months postoperatively. Mean duration of surgery was 57.25±10.41 min, and there was no significant relationship between CMS scores and duration of surgery (minutes per patient) (p=0.801 and p=0.779 for 3 months and 12 months, respectively). Mean time to union in our patients was 4.76±1.36 months

All the patients are doing extremely well and returned back to their normal level of activity.

On radiographic evaluation bony union was observed in all cases.

**Table 1:** Patient characteristics

Sl. No.	Age/sex	Lateral end clavicle fracture	Type of fixation	Return to work	Constant murley shoulder outcome score at 3 months	Constant murley shoulder outcome score at 12 months
1.	25/M	Type II b	Suture anchor	10 weeks	69	89
2.	39/F	Type II	Suture anchor	10 weeks	71	91
3.	51/M	Type II	Suture anchor	10 weeks	68	88
4.	53/M	Type II b	Suture anchor	10 weeks	68	90
5.	40/M	Type II b	Suture anchor	10 weeks	70	91
6.	35/M	Type II b	Suture anchor	10 weeks	72	92
7.	39/F	Type II b	Suture anchor	10 weeks	74	89
8.	45/M	Type II b	Suture anchor	10 weeks	68	88
9.	36/M	Type II b	Suture anchor	10 weeks	69	90
10.	41/M	Type II b	Suture anchor	10 weeks	69	89
11.	33/M	Type II b	Suture anchor	10 weeks	71	90

**Table 2:** Patients’ functional status based on Constant-Murley shoulder outcome score at 3 and 12 months postoperatively

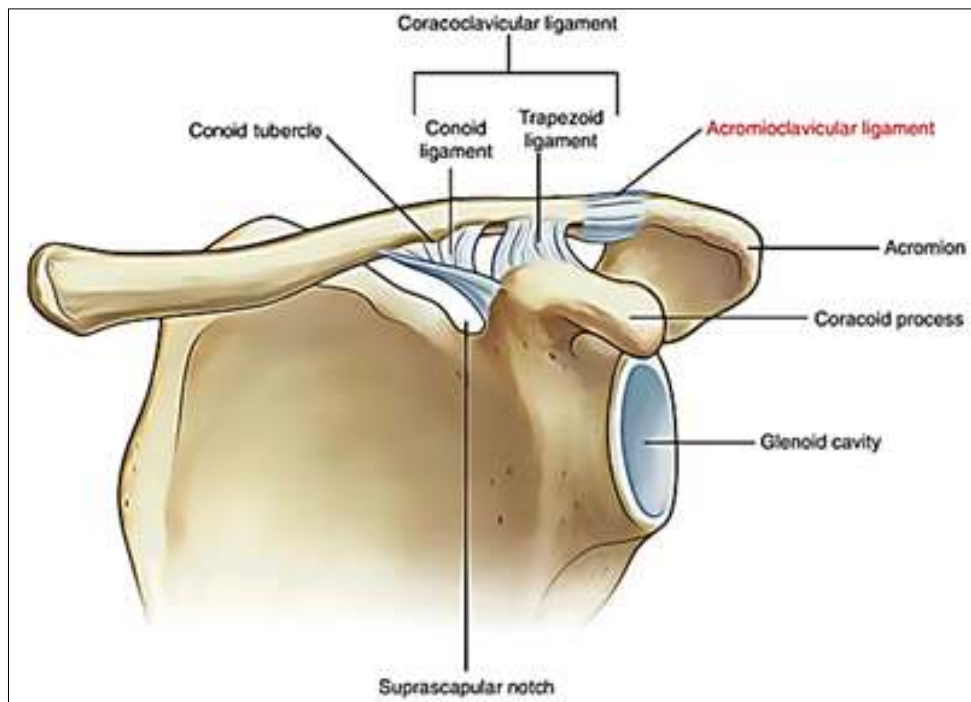
	Count	
	N	%
<b>Post-operative 3 months</b>		
Excellent	8	66.7%
Good	3	25%
Acceptable	1	8.3%
Fair	-	-
<b>Post-operative 1 year</b>		
Excellent	8	66.7%
Good	3	25%
Acceptable	1	8.3%
Fair	-	-

**Discussion**

Clavicle is one of the common bones to be traumatically fractured [1]. Most clavicle fractures can be successfully treated by nonsurgical methods. The treatment outcomes of

the distal clavicle fractures depends the bone displacement and injury to the coracoclavicular ligament which makes the fractures unstable [2]. Type 1 injuries generally being stable without any displacement are managed conservatively with a sling to support the weight of the limb. Type 3 injuries are managed similarly which unites as such, but may lead on to AC joint arthrosis which will need surgical resection of the distal fragment. Type 4 is just a periosteal disruption in children and bone fills the periosteal sleeve resulting in union and remodelling. There are no clear management guidelines for type 2 and 5 [2, 3].

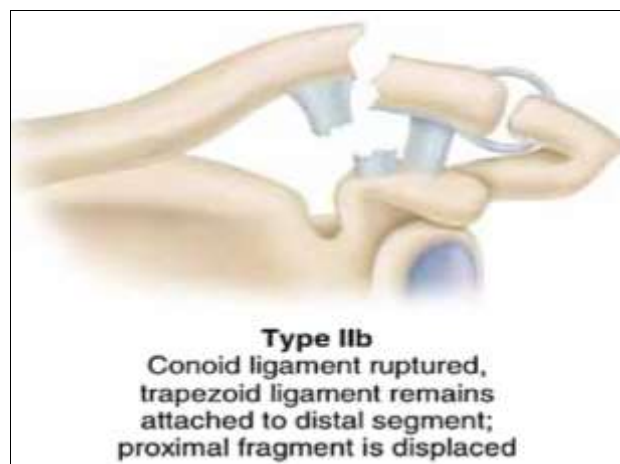
Fractures are classified based on those that involve or are distal to the conoid tubercle of the clavicle. The reason for this distinction is that fractures that are medial to the conoid tubercle can generally be treated like middle-third fractures, but those bone fractures lateral to the conoid present different management concerns and treatment requirements based on the intactness of the coracoclavicular ligaments [4].



**Fig 6:** Anatomy of lateral end of clavicle

Neer <sup>[1]</sup> type II distal clavicle fractures without Coracoclavicular ligament injuries form a special group which are at high risk of complications such as nonunion or shoulder dysfunction due to conservative management. Nonsurgical treatment results in nonunion in 33.3% of cases and surgical treatment results in nonunion in 1.6% of cases as shown by oh *et al* <sup>[5]</sup>. If the conoid part of coracoclavicular

ligament is torn with fracture lateral to the conoid tubercle; then the distal part sags down with the medial end of the clavicle going up this is compounded by the pull of the trapezius, causing the coracoclavicular distance (CCD) to increase. Due to these issues there is a high risk of non-union if the fracture is managed conservatively <sup>[5]</sup>.



**Fig 8:** Type 2b fracture of lateral end of clavicle

**Table 3:** Fixation technique as advised by various authors and orthopaedic surgeons

Method of fixation	Challenges	Comments (6)
1. Distal clavicle plating	Small lateral or distal end may not get adequate hold in the small fragment.	Less stability- may lead to nonunion or delayed union or may need longer period of immobilisation
2. Plating that includes acromion	Acromioclavicular joint is spanned	Excessive soft tissue dissection. Implant induced bursitis
3. K-wires	Easy to finish the surgery	Very less stability. Force so great and large in this area – may lead to break down of k-wire No accurate reduction possible. Loss of fixation and shoulder stiffness. Implant migration
4. Hook plate	Very good stability for very early mobilisation	Sometimes may slip from underneath the acromion and also acromion lysis (4) forcing for implant exit (7)
5. Coracoclavicular screw	Less dissection.	Needs C arm.

technique	No implant related irritation	If no bicortical purchase of screw then early mobilisation cannot be done
6. Suture anchors	Good stable fixation for this fracture.	Early mobilisation. No implant induced irritation to the soft tissues. No need for implant removal

Various treatment modalities have been described to treat these type 2 Neer fractures. Intramedullary Kwire fixation is a simple procedure [6]. But K wire fixation has complications which include pin migration, infections and failure of fixation [6, 7]. Threaded pins is safer than with smooth pins for transacromial fixation, as the threading prevents pin movement [8]. However, delayed complications of the acromioclavicular joint, such as arthrosis, still remain a concern. Scadden and Richards obtained good results from fixation using malleolar screws [6] though their use for comminuted fractures or small distal fragments is limited. Hook plate fixation has been more effectively used in recent years, but due to subacromial impingement and rotator cuff tears a second surgery to remove the hardware is essential [7]. Mersilene tapes were used to treat distal clavicle fracture by Chen *et al* [8]. They reported anatomic locking plate combined with suture-endobutton for CC ligament reinforcement to be a reliable method to achieve osteosynthesis and stabilization in Neer type IIB distal clavicle fractures without compromising the physiology of the shoulder [5].

Suture anchor fixation of distal clavicle fracture by closed reduction method or mini open method helps to preserve the biological process of fracture union and healing [8]. This method has helped to achieve successful bony union with no surgical complications and there is no additional cost or re-surgery for implant removal or implant failure thereby preventing additional costs. The technique used in this study can provide favorable results in treatment of patients with distal clavicle fractures.

### Conclusion

For unstable lateral end clavicle fractures stabilization with suture anchor is a safe, reliable management and less technically demanding mode of management with good results.

### References

1. Campbell's Operative Orthopaedics 13<sup>th</sup> edition PART XV Fractures and Dislocations in Adults P2934.
2. Sambandam B, Gupta R, Kumar S, Maini L. Fracture of distal end clavicle: A review. *J Clin Orthop Trauma* 2014;5(2):65-73.  
DOI: 10.1016/j.jcot.2014.05.007. PMID: 25983473; PMCID: PMC4085358
3. Flinkkila T, Ristiniemi J, Hyvonen P, Hamalainen M. Surgical treatment of unstable fractures of the distal clavicle: A comparative study of Kirschner wire and clavicular hook plate fixation. *Acta Orthop Scand* 2002;73(1):50-53.
4. Flinkkila T, Ristiniemi J, Lakovaara M *et al*. Hook-plate fixation of unstable lateral clavicle fractures: A report on 63 patients. *Acta Orthop* 2006;77(4):644-649.
5. Charity RM, Haidar SG, Ghosh S, Tillu AB. Fixation failure of the clavicular hook plate: A report of three cases. *J Orthop Surg* 2006;14(3):333-335.
6. Ballmer FT, Gerber C. Coracoclavicular screw fixation for unstable fractures of the distal clavicle: A report of five cases. *J Bone Joint Surg Br* 1991;73:291-294.
7. Neer CS II. Fractures of the clavicle. In: Rockwood CA,

Green DP, eds. *Fractures in Adults*. Philadelphia: JB Lippincott 1984, P707-713.

8. Oh JH, Kim SH, Lee JH, Shin SH, Gong HS. Treatment of distal clavicle fracture: a systematic review of treatment modalities in 425 fractures. *Arch Orthop Trauma Surg* 2011;131(4):525-533.