

E-ISSN: 2395-1958
P-ISSN: 2706-6630
IJOS 2021; 7(1): 74-78

www.orthopaper.com
Received: 22-10-2020
Accepted: 02-12-2020

Dr. Prabhu Basavanagouda
Professor,
Department of Orthopaedics,
JJM Medical College,
Davanagere, Karnataka, India

Dr. Anvith S Shetty
Junior Resident,
Department of Orthopaedics,
JJM Medical College,
Davanagere, Karnataka, India

Dr. Likhith D
Junior Resident,
Department of Orthopaedics,
JJM Medical College,
Davanagere, Karnataka, India

Dr. Sharanagoud Honnagol
Junior Resident,
Department of Orthopaedics,
JJM Medical College,
Davanagere, Karnataka, India

Dr. Pranav Rajendra Prasad Rao
Junior Resident,
Department of Orthopaedics,
JJM Medical College,
Davanagere, Karnataka, India

Corresponding Author:
Dr. Anvith S Shetty
Junior Resident,
Department of Orthopaedics,
JJM Medical College,
Davanagere, Karnataka, India

A prospective study of surgical management of diaphyseal shaft fracture of bones of forearm in adults with limited contact dynamic compression plate

Dr. Prabhu Basavanagouda, Dr. Anvith S Shetty, Dr. Likhith D, Dr. Sharanagoud Honnagol and Dr. Pranav Rajendra Prasad Rao

DOI: https://doi.org/10.22271/ortho.2021.v7.i1b.2460

Abstract
Fractures of forearm bone are one of the most common injuries seen in day-to-day practice. The forearm, in combination with the proximal and distal radioulnar joints, allows pronation and supination movements that are important in the usual activities of daily living. The forearm serves an important role in upper extremity function. Decisive management is required after fractures of the shafts of the radius and ulna if the function is to be restored.
The Limited Contact Dynamic Compression Plate, was developed by Perren S. M. et to release the new concept of biological internal fixation. Grooves on the undersurface of the LC-DCP improved blood circulation. There is decreased damage to contact between plate and bone. It also allows for a small bone bridge beneath the plate at the most critical area, which is otherwise weak due to a stress concentration effect. This study is undertaken to assess the results of diaphyseal fractures of Bones of the Forearm using LCDCP to study the advantages and its complications.
Materials and Methods: Patients admitted to Cg Hospital and Bapuji Hospital between 2019 July to 2020 September were taken into the study after taking informed consent.
Results: This study consists of 30 cases of fractures, Both Bone Forearm Fractures. All cases were openly reduced and internally fixed with 3.5 mm LCDCP. The fracture was common in the second and third decades. In our study, male preponderance was found with 73.3% males and 26.7% female patients. Side affected 24(80%) Left side and 6 patients (20%) right side. The mode of injury in the present study was RTA (33.3%) and fall (66.6%). An average time for the union was around 5 months. Results were evaluated by the Andersons scoring system. In the present study, we had 24 patients (80%) with excellent results, 5 case (16.6%) as to satisfactory and 1 case (2%) as unsatisfactory. No case needed refixation. In the present study, there was 3 case (10%) of superficial infection, 1 case (3.3%) of Posterior Interosseous Nerve injury.
Conclusion: LC-DCP can be considered the best mode of treatment for closed diaphyseal fractures of both bones forearm.

Keywords: Both bones forearm, diaphyseal fractures, limited contact dynamic compression plate, Andersons scoring system

Introduction
The human forearm serves an important role in the upper extremity function, facilitating the placement of the hand in space, thus helping to provide the upper extremity with its unique mobility. Fractures involving the bones of the forearm present unique problems not encountered with fractures of other long bones and may significantly affect the function of the upper limb [1]. It is difficult to achieve a satisfactory closed reduction of displaced fractures of the forearm bones, and if achieved, it is hard to maintain, for this reason, fractures of both bones or a displaced isolated fracture of the radius and ulna should be treated by open reduction, plate fixation, and cancellous bone grafting whenever there is bone loss. It is essential to regain length, apposition, axial alignment and normal rotational alignment while treating diaphyseal fractures of the radius and the ulna to gain a good range of pronation and supination. The chances for the occurrence of malunion and non-union are greater because of the difficulties in reducing and maintaining the reduction of two parallel bones in the presence of the pronating and supinating muscles, which have angulatory as well as rotatory influences [2].

Open reduction and internal fixation with plating is generally accepted as the best method of treatment for displaced diaphyseal fractures of the forearm in the adults [2]. The value of compression in obtaining rigid internal fixation had been noted by various authors [3, 4, 5]. Compression techniques have a lower incidence of non-union and are found to hasten rehabilitation, with less joint stiffness [6, 7].

Treatment by closed reduction and cast immobilization results in a poor functional outcome with unsatisfactory results reported in up to 92% of cases, usually caused by malunion, nonunion or syntosis [5, 6, 8]. Various types of plates are available for open reduction and internal fixation using plates and screws [3]. Stabilization with internal plate fixation following fracture of both bones of the forearm restores nearly normal anatomy and motion [9]. However, a moderate reduction in the strength of the forearm, wrist and grip should be expected. The plates most widely used for internal fixation of forearm fractures are the 3.5 dynamic compression plate (DCP) and the 3.5mm Limited Contact Dynamic Compression Plate (LcDcp). In comparison to the DCP, the contact area between the bone and the LC-DCP is reduced by about 50% [10, 11]. The limited contact dynamic compression plates (LC-DCP), developed in 1991, was said to reduce the bone–plate contact by approximately 50% to minimise the disruption of periosteal blood vessels beneath the plate [12]. The LC-DCP has a groove within the undersurface (leads to an improvement in the blood supply to the underlying plate bone segment) that allows for a small amount of callus formation as well as even distribution of stiffness along with the plate, undercut plate holes allow extended tilting of plate screws, uniformly spaced as well as symmetrical plate holes and has a optimal screw effect [13, 14]. But the LC-DCP still relied on the plate–bone interface for stability [11, 15].

In the present study, thirty cases of diaphyseal fracture of bones of the forearm are treated surgically with LC-DCP in JJM Medical College, Davanagere. With Andersons *et al*. scoring system, the functional outcome was evaluated.

Materials and Methods

Source of Data

The present study includes treatment of cases of fracture of both bones forearm in adults by open reduction and internal fixation with LCDCP plate between July 2019 to September 2020 at Chigateri General Hospital and Bapuji Hospital attached to J. J. M Medical College, Davanagere.

Method of collection of Data (including sampling procedures if any): The study proposes to include patients with diaphyseal shaft fracture of bones of forearm admitted and examined according to protocol. Associated injuries will be noted. Clinical and radiological investigations will be carried out to get fitness for surgery.

Patients will undergo a limited contact dynamic compression plate for both bone forearm fractures. Post operatively, patients will be followed up at regular intervals at 1 month, 2 month, 3 month, 6 month, 1 year till the end of this study clinically and with x-rays to study the union rate and to look for any complications.

Inclusion criteria

- Patients above 18 years of age.
- Closed or type 1 Compound diaphyseal shaft fracture of either of forearm bones.
- Competent neurological and vascular status of the affected extremity

Exclusion criteria

- Patients not willing for surgery
- Patients below 18 years of age
- Patients medically unfit for surgery

Operative procedure

Position

The patient is supine on the operating table and a Pneumatic tourniquet is recommended. Out of the two Approaches, Henry and Dorsal Thompson Approach Henry approach were done more routinely.

Operative procedure

After anaesthesia, part was painted and draped. The radius Volar Henry's approach. Ulna was approached directly over the subcutaneous border. After identifying the fracture ends, periosteum was elevated and the fracture ends were cleaned. With the help of reduction clamps, fracture was reduced and held in position. The plate was then applied after contouring, if required. For upper third radial fractures, the plate was fixed dorsally, for distal two-thirds, the plate was fixed dorsolaterally and for distal radial fractures, the plate was fixed on the volar aspect. In ulna, fractures plate was applied over the posteromedial surface of ulna [16]. Using the neutral drill guide, the first screw is applied to the fragment, which forms an obtuse angle with the fracture near the plate. The resulting space between the fracture plane and plate undersurface guides the opposite fragment towards the plate. The arrow of the neutral drill guide points towards the fractures. 2.5 mm drill bit is used for drilling a hole through both cortices and with a depth gauge appropriate 3.5 mm screw length is determined, 3.5 mm drill tap used before screw insertion [16]. After adaptation of the fragments, a screw hole for axial compression is drilled in the fragment, which forms an acute angle near the plate. Here the load guide is used with the arrow pointing towards the fracture line to be compressed. At this position, a lag screw will be inserted for axial compression.

Physiotherapy

A posterior plaster splint was applied for comfort for 2 to 3 days. The patient was encouraged to perform both active and active-assisted range of motion exercises of the shoulder and hand. Elbow range of motion, supination and pronation exercises were begun as soon as remission of pain and swelling of forearm permits, usually after 2 to 3 days. These isotonic exercises are very much essential for the excellent outcome. Physiotherapy helps in fracture union, as there is increased blood supply and tethering of muscles to the bone and soft tissue contracture is avoided. Thus physiotherapy with rigid fixation gives excellent results.

Results

The present study consists of 30 cases of fracture both bones of the forearm. All the cases were openly reduced and internally fixed with 3.5mm LC-DCP. The study period was from July 2019 to September 2020.

Table 1: Age distribution

Age(YRS)	No of Patients	%
18-25	16	53.3
26-35	4	13.3
36-45	5	16.6
46-60	4	13.3
60 & above	1	3.3
Total	30	100

Table 2: Sex distribution

Sex	No of patients	%
Male	22	73.3
Female	8	26.7
Total	30	100

Table 3: Side affected

Side affected	No of patients	%
Right	24	80
Left	6	20
Total	30	100

Table 4: Level of fracture

Level	No of patients	%
Distal 1/3	12	40
Middle 1/3	12	40
Proximal 1/3	6	20
Total	30	100

Table 5: Mode of injury

Mode of injury	No of patients	%
Rta	10	33.3
Self fall	20	66.6
Total	30	100

Table 6: Duration of union

Time of union	No of cases	%
<4 months	13	43.3
4-6 months	16	53.3
6 months –1yr	1	3.3
Total	30	100

Determination of union is by using the Criteria of Anderson *et al*. [18]

1. Fractures which healed in less than 6 months were classified as unions. 2. Those, which required more than 6 months to unite and had no additional operative procedures, were classified as delayed unions. 3. Those, which failed to unite without other operative procedures, were classified as non-unions.

Table 7: Complications

Complications	No of cases	%
Superficial infection	3	10
Pin injury	1	3.3

Criteria for Evaluation of Result

Table 7: "Anderson" *et al*. scoring system

Result	Union	Flexion & extension at wrist joint	Supination & pronation
Excellent	Present	<10% loss	<25% loss
Satisfactory	Present	<20% loss	<50% loss
Unsatisfactory	Present	<30 % loss	>50% loss
Failure	Nonunion with or without loss of motion		

Table 8: Functional results

Results	No of cases	%
Excellent	24	80
Satisfactory	5	16.6
Unsatisfactory	1	3.3
Failure	Nil	Nil

Fig 1: Pre op x-ray

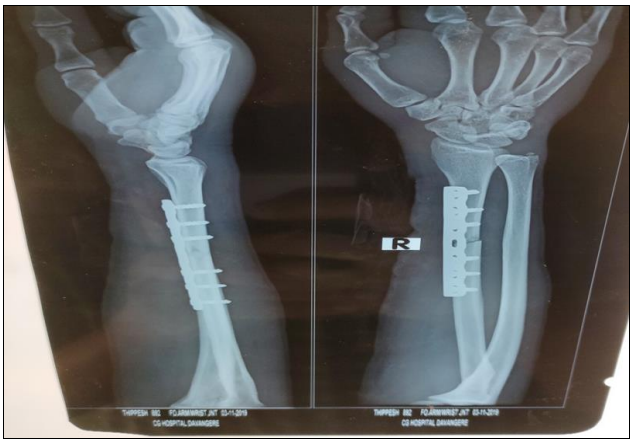

Fig 2: Immediate post op X-ray

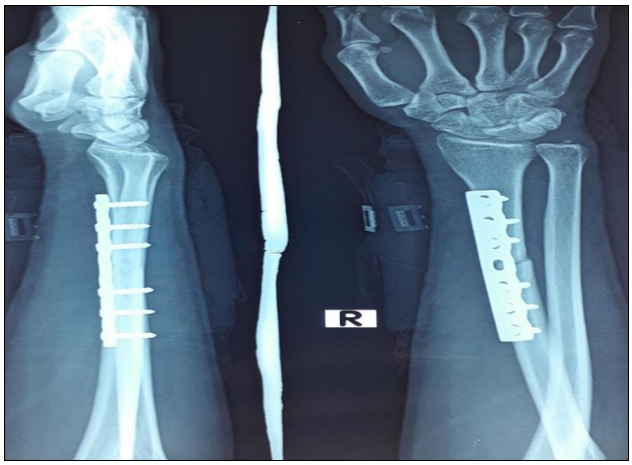

Fig 3: 3 Months post op x-ray

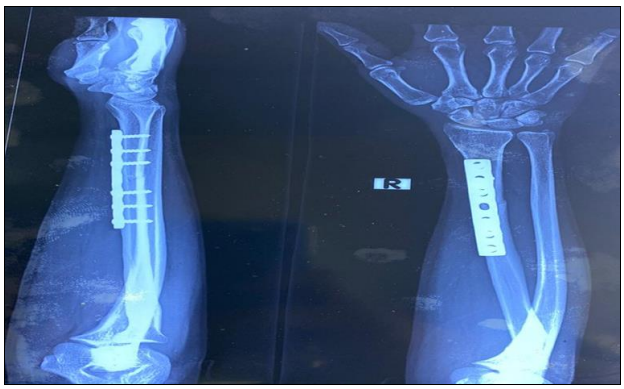

Fig 4: 6 months post op x ray

Discussion

Fractures of both bones of the forearm are relatively common injuries which can challenge the treating physician [12]. Rotation of the forearm is a complex interaction between the radiuses and the ulna and restoration of movements depend upon both an accurate reduction of fractures and early initiation of post-operative movements. Loss of rotation impedes the function of the upper limb and activities of daily living [12]. It is difficult to achieve a satisfactory closed reduction of displaced fractures of the forearm bones, and if achieved, it is hard to maintain. Unsatisfactory results of closed treatment have been reported to range from 35% to 72%. For this reason, open reduction with internal fixation is routine except for UN displaced fractures.

Open reduction and Internal Fixation is the treatment of choice for the early mobilization of the forearm and wrist [18]. Compression plate fixation has become the treatment of choice for fractures of both bones of the forearm. Compression plate fixation gives a high rate of union, a low rate of complications, and a satisfactory return of rotation of the forearm [12].

Kurt. P. Droll in his 2007 study stated plate fixation of diaphyseal fractures of both bones of the forearm using 3.5mm Limited contact Dynamic Compression plate restores nearly normal anatomy and motion even though strength remains an average of 30% less than that of contralateral extremity years after the injury [2]. Although callus formation was found to be more in the non-anatomically reduced forearms [19]. In the early days of plating, DCP was the preferred method of fixation, as it provided good compression across the fracture site [20]. However, studies have shown that DCPs caused vascular compromise in the periosteum due to constant pressure cause by the plate and the extensive periosteal stripping which caused poor poor fracture healing. The 3.5 mm LC-DC Plate is an excellent method for internal fixation of fractures of the forearm [5]. The LCDC plate has a number of design modifications which are designed to reduce the problems associated with conventional DC plate. Recent studies regarding the bone-plate interface following the plating of fractures have concluded that cortical contact between the plate and bone is the single most important factor influencing the cortical porosity [21, 22]. Periosteal stripping produces an area of ischaemia [23] which is noted with the use of DCP unlike LC-DCP where periosteal stripping is minimum or periosteum is preserved.

Experimental studies evaluating LC-DC plate where limited cortical contact is seen have caused less cortical ischaemia and a lower magnitude of reactive hyperaemia in the cortical bone beneath the plate [22]. Oblique undercutting of the plate between the screw holes minimizes the contact of the plate to the cortical bone underneath. Recent data has shown that the LCDC plates due to their unique design causes less disturbance of cortical blood flow at the time of application and is associated with a lower magnitude of peak reperfusion and osteoporosis postoperatively [22]. The LCDC plate, owing to its undercut between the holes, has even levels of stiffness along the entire plate, allowing smoother, easier contouring and distributing stress more evenly.

The LCDCP is an effective option for management of fractures of both bones of forearm and the outcome is determined by using proper principles of plating. In our study we studied union rates of 30 cases operated with Open Reduction and Internal fixation using LCDC plate. The functional outcome were evaluated using Anderson *et al.* classification scoring system.

Only one case had nonunion and rest 29 cases had union.24 cases (80%) had excellent results, 5 cases had satisfactory results (16.6%) and one case had unsatisfactory results (3.3%) according to Anderson *et al*. scoring system.

Conclusion

The LC-DCP is an excellent implant of choice for fracture of both bones of forearm. Using this study we can conclude LCDC plate brings about the union of fracture of both bone forearm yields excellent results in 24 cases and satisfactory results in 5 out of a total 30 cases.

The Limited contact dynamic compression plate minimizes vascular damage to the plated bone segment of diaphyseal bones and thus brings about excellent results, the advantages being early mobilization, early union, which help in early fracture healing.

References

1. Moore KL, Dalley AF, Agur AMR. Clinically oriented Anatomy. 6th Ed. Philadelphia: Lippincott William and Wilkins; Crenshaw AH, Perez FA, Fractures of the shoulder, arm and forearm. In 2010.
2. Knight RA, Purvis GD. Fractures of both bone forearm in Adults. J Bone Joint Surg Am 1949;31:755-64.
3. Anderson LD, Sisk D, Tooms RE, Park WI. 3rd Compression-plate fixation in acute diaphyseal fractures of the radius and the ulna. J Bone Joint Surg Am 1975;57:287-297.
4. Bagby GW, James JM. The effect of compression on the rate of Fracture healing using a special plate. Am J Surg 1958;95:761-71.
5. Müller ME, Allgöwer M, Willenegger H. Manual of internal fixation techniques recommended by AO group. 3rd ed. New York: Springer–Verlag Berlin 1990.
6. Chapman MW, Gorden JE, Zissimos AG. Compression plate fixation of acute fractures of the diaphyses of the radius and ulna. J Bone Joint Surg Am 1989;71:159-69.
7. Goldfarb CA, Ricci WM, Tull F, Ray D, Borelli J, Jr Functional outcome after fracture of both bones of the forearm. J Bone Joint Surg Br 2005;87:374-9.
8. Kotwal PP. Fractures of the Radius and Ulna. In: Kulkarni GS (Ed.); Textbook of orthopaedics and Trauma, 2nd Ed. New Delhi: Jaypee 2008,1967.
9. Sevitt Simon. Primary repair of fractures and compression fixation. Chap-10 in bone repair and fracture healing in man. Churchill Livingstone, Edinburgh 1981,145-156.
10. Colton C. History of Osteosynthesis. Chapter-2, in AO / ASIF Instruments and Implants, 2nd ed, Texhammer R, C. Colton, Berlin, Springer Verlag 1994,3.
11. Thakur AJ. Bone plates. Chapter-4 in The elements of fracture fixation, Churchill Livingstone, New Delhi 1997,57-79.
12. Leung F, Chow SP. A prospective, randomized trial comparing the limited dynamic compression plate with the point contact fixation for forearm fractures. J Bone Joint Surg Am 2003;85:2343-8.
13. Gustilo RB, Mendoza RM, Williams DN. Problems in the management of type (III) (Severe) open fractures: a new classification of type (III) open fracture. J Trauma 1984;24:742.
14. Perreo SM. The concept of biological plating using the Limited contact dynamic compression plate (LC-DCP). Scientific background, design and application: Injury 1991;22(1):1-41.

15. Egol KA, Kubiak EN, Fulkerson E, Kummer FJ, Koval KJ. Biomechanics of locked screws and screws. J Orthop Trauma 2004;18:488-3.
16. Perren SM. Basic Aspects of Internal Fixation. Chapter-1, in Manual of Internal Fixation, 3rd Edn. Allgower M. Schneider R, Willenegges, Berlin, Springer Verlag 1991,1.
17. Ralph Hertel, Domique Rothenfluh A. Fractures of the shaft of radius and ulna; chapter 27 in Rockwood &Green fractures in adults by Robert. W. Bucholz, James. D. Heckman 2006,967-987.
18. Nasab SAM, Sarrafan N, Atri H, Aliabadi G. Outcome of forearm shaft fractures in adults treated by open reduction and internal fixation with DCP. Pak J Med Sci 2012;28(1):45-8.
19. Leung F, Chow SP. Locking compression plate in the treatment of forearm fractures: A prospective study. J Orthop Surg (Hong Kong) 2006;14:291-4.
20. Angadi V, Patil AB, Nagnur R, Palled GS. The efficacy of dynamic compression plate versus locking compression plate with regards to fracture fixation, implant fixation and bone reaction Int J Orthop Sci 2016;2(3):85-7.
21. Perren SM, Cordey J, Rahn BA, Gauthier E, Schnieder E. Early temporary porosis of bone induced by internal fixation implants: a reaction to necrosis, not to stress protection? C/in Orthop Rel Res 1988;232:139.
22. Swiontkowski MF, Senft D, Taylor S, Agnew SG, Santoro V. Plate design has an effect on cortical bone perfusion. Proc Orthop Res Sot 1991;14:66.
23. Whiteside LE, Ogeta K, Lesker P *et al*., The acute effects of Periosteal stripping and Medullary Reaming on Regional Blood flow. Clin Orthop 1978;131:266.