

E-ISSN: 2395-1958
P-ISSN: 2706-6630
IJOS 2021; 7(1): 87-89
© 2021 IJOS
www.orthopaper.com
Received: 29-10-2020
Accepted: 10-12-2020

Dr. Manan Shah
Department of Orthopaedics,
MGM Medical College and
Hospital, Kamothe,
Maharashtra, India

Dr. Alfven Vieira
Department of Orthopaedics,
MGM Medical College and
Hospital, Kamothe,
Maharashtra, India

Dr. Deepak Jain
Department of Orthopaedics,
MGM Medical College and
Hospital, Kamothe,
Maharashtra, India

Corresponding Author:
Dr. Manan Shah
Department of Orthopaedics,
MGM Medical College and
Hospital, Kamothe,
Maharashtra, India

A comparative study of type 2 radial head fractures treated by conservative versus operative management

Dr. Manan Shah, Dr. Alfven Vieira and Dr. Deepak Jain

DOI: <https://doi.org/10.22271/ortho.2021.v7.i1b.2463>

Abstract

Aims and Objectives

1. To evaluate the clinical and functional outcome in Type 2 Radial head fracture treated with conservative management or operative management.
2. To study the complications, if any with radial head fracture fixation and conservative treatment.

Materials and Methods: 50 patients of Type 2 radial head fractures were treated either none operatively or by open reduction and internal fixation. 25 patients underwent conservative treatment and 25 patients underwent open reduction and internal fixation. Patients were divided into study groups by randomisation. Patients were followed up for a period of 6 months following their injury, and overall results were determined by using the Quick Dash scoring system. Institutional ethics committee approval was obtained before proceeding with this study.

Results: In our study, no statistically significant differences were found in the study groups in terms of age, sex, side affected or mechanism of injury. Quick Dash scores were not found to vary significantly in either groups at 6 months. One patient in our study had a palsy of the posterior interosseous nerve following surgery.

Conclusion: The authors cannot recommend open reduction and internal fixation for type 2 radial head fractures, as conservative management in this study has shown to have equally good results without the possibility of complications of surgery.

Keywords: Radial head, internal fixation, conservative treatment

Introduction

Fractures of the radial head most often occur as the result of a fall on the outstretched arm [1, 2]. The long-term outcome associated with un displaced and minimally displaced fractures, independent of the method of treatment, consistently has been described as excellent [3, 4, 5]. In contrast, the outcome following displaced and comminuted fractures has not been as consistent, with some studies demonstrating a high proportion of unfavourable results [6, 7, 8] and other studies demonstrating predominantly favourable results [3, 5, 9, 10, 11, 12]. As a result of the uncertainty regarding the long-term results, open reduction and internal fixation of the radial head has received more interest during the last decade, predominantly for the treatment of displaced two-fragment fractures [13-17].

Some previous investigators have reported on Mason type-II fractures only but have combined radial head and neck fractures, whereas others have reported on radial head fractures only but have combined Mason type-II and III fractures [7, 8, 10, 11, 14, 17]. Combining fracture patterns in this way can lead to unclear results. For example, a displaced intraarticular fracture (such as a radial head fracture) with residual joint incongruity can have an inferior long-term outcome in comparison with a displaced extra articular fracture (such as a radial neck fracture) [18]. In addition, a comminuted fracture of the proximal part of the radius (a Mason type-III fracture) can have a worse outcome in comparison with a Mason type-II two-part fracture because type-III fractures are more often associated with higher energy mechanisms of injury. In 2006, Thomas Akkeson *et al.* published a landmark paper on the long term outcomes of patients treated conservatively while suffering from Type 2 radial head fractures. They concluded that: "The initial nonoperative treatment of Mason type-II fractures of the radial head that are displaced by 2 to 5 mm is associated with a predominantly favourable outcome, especially if a delayed radial head excision is performed in the few cases in which the early outcome is unsatisfactory [19]."

This paper was the first to question the rising trend of operative management of radial head fractures after the advent of low profile plates and smaller screws. These implants had made the option of fixing radial head fractures viable for the first time, with many authors reporting well to excellent results with these fixation techniques.

In 2016, a Japanese compared the results of fixation of type 2 and type 3 radial head fractures, and contrasted them with the long term results of excision, and found that fixation lead to significantly better results as compared to excision, even in higher energy fracture patterns [20].

While multiple studies compare the results of various modalities of operative interventions, the studies contrasting conservative and operative management are scarce. Further research is sorely needed in this area.

Aims and Objectives

1. To evaluate the clinical and functional outcome in Type 2 Radial head fracture treated with conservative management or operative management.
2. To study the complications, if any with radial head fracture fixation and conservative treatment.

Materials and Methods

50 patients of Type 2 radial head fractures were treated either none operatively or by open reduction and internal fixation. 25 patients underwent conservative treatment and 25 patients underwent open reduction and internal fixation. Fixation was either by Herbert screws or a combination of Herbert screws and a low profile pre contoured locking radial head plate. Patients were divided into study groups by randomisation. Patients were followed up for a period of 6 months following their injury, and overall results were determined by using the Quick Dash scoring system. Institutional ethics committee approval was obtained before proceeding with this study.

Inclusion criteria: Patient who were diagnosed as closed Type 2 radial head fractures, Age > 18 years, both male and female patients.

Exclusion Criteria: Fracture associated with elbow dislocation, Pathological fractures, Old untreated fractures, Associated upper limb fractures, Poly traumatized patients (Injury Severity Score>15), Patients not consenting for the study or chit method of randomization. Patient were followed

up at 4 weeks, 2 months and 3 months and at 6 months. At every follow up visit, Quick Dash scoring was evaluated for the patient.

Post-operative procedure: Mobilization started on the day following surgery, wound check done on the second day following surgery and the patient was then discharged.

Conservative Management procedure: An above elbow slab was applied on the day of injury, which was changed to an above elbow cast as soon as swelling subsided. This cast was maintained for three weeks, following which it was removed and active motion was encouraged.

Results

In our study, the youngest patient was 19 years old and the oldest patient was 58 years old. The mean age was 39.7 years. The average hospital stay for operated patients was 6.2 days, while patients treated conservatively were not hospitalized. Operated patients were mobilized on the day following surgery while the conservatively treated patients were mobilized three weeks post their injury. Two patients treated conservatively were lost to follow up after their last visit at 3 months post injury, but both had already obtained excellent results by the time of their final visit.

In the group treated conservatively, 18 of 25 patients subjectively had no elbow complaints. 4 patients experienced minor impairments in function. This was manifested as pain on loading and occasional pain at rest. 2 patients had more marked symptoms and a delayed return to work. Only 1 patient had a more profound affection of function, with decreased range of motion and severe pain on loading. This patient was treated by a delayed radial head excision which lead to improvement in function. In the group treated operatively, 19 of 25 patients subjectively had no elbow complaints. 3 patients complained of occasional pain on loading, 2 patients had more significant impairment that required prolonged rest from work and 1 patient developed a palsy of the posterior interosseous nerve.

No statistically significant difference was found in the study groups in terms of age, sex mechanism of injury or side affected. There was no statistically significant difference found in the results obtained by Quick Dash scores at the end of 6 months of follow up.

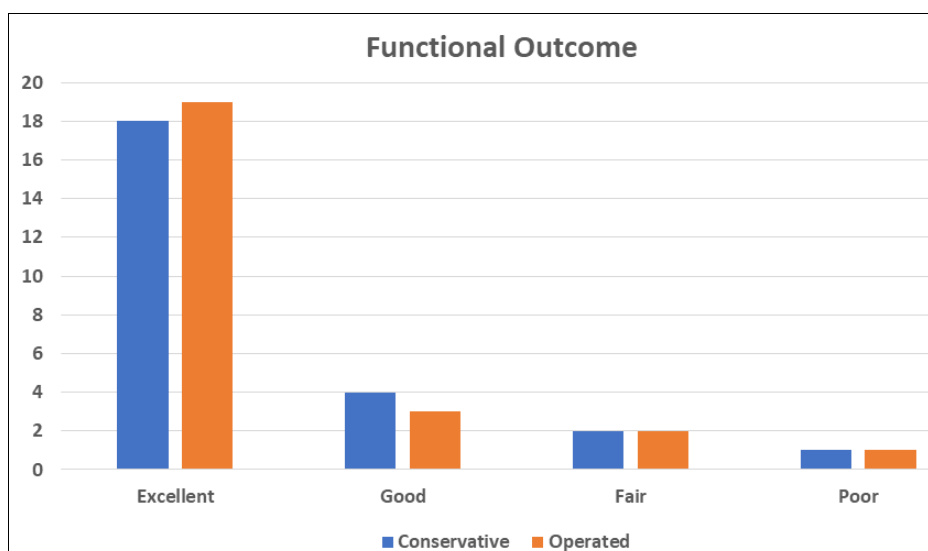


Fig 1: Functional outcome

Table 1: Results

Parameter	Conservative group(Mean)	Operative group(Mean)
Age	41.4	38.8
Sex	11 Male, 14 Female	12 Male, 13 Female
Mechanism of injury	Low energy: 22	Low energy: 21
	High energy: 3	High energy: 4
Side affected	16 Right, 9 Left	15 Right, 10 Left
Quick Dash score(at 6 months)	29.6	27.8

Discussion

This study demonstrates that conservative management of type 2 radial head fractures predominantly leads to excellent or good results. It supports the observations made by Akkeson *et al.* [19] in 2006, who questioned the increasing trend towards open reduction and internal fixation for these fractures. Arner [3] also found that in series of 186 displaced radial head fractures treated conservatively, 164(88%) had well to excellent results. Other studies do not share the same optimism for the conservative treatment of displaced radial head fractures. Mason [8] reported good or excellent results in only 10 out of 20 patients followed up for 2 years following conservative treatment. Most studies on radial head fractures are typically restricted by small sample sizes, which makes it difficult to draw any definite conclusions or recommendations for treatment. This inconsistency has promoted the operative treatment of these fractures without any clear evidence for improved outcomes over conservative treatment. These studies rarely comment on the complications associated with radial head fixation, including mal reduction, infection, and posterior interosseous nerve palsy. In our study, no statistically significant differences were found in both groups in terms of age, sex, side affected or mechanism of injury. Quick Dash scores were not found to vary significantly in both groups. One patient in our study had a palsy of the posterior interosseous nerve following surgery, which definitely begs the question as to whether it is wise to expose the patient to potential surgical complications without clear benefits of surgery.

Conclusion

The authors cannot recommend open reduction and internal fixation for type 2 radial head fractures, as conservative management in this study has shown to have equally good results without the possibility of complications of surgery.

References

- Keon-Cohen BT. Fractures at the elbow. *J Bone Joint Surg Am* 1966;48:1623-39.
- Odelberg-Johnson G. On fractures of the proximal portion of the radius and their causes. *Acta Radiol* 1921;3:45-53.
- Arner O, Ekengren K, von Schreeb T. Fractures of the head and neck of the radius; a clinical and roentgen graphic study of 310 cases. *Acta Chir Scand* 1957;112:115-34.
- Herbertsson P, Josefsson PO, Hasserijs R, Karlsson C, Besjakov J, Karlsson MK. Displaced Mason type I fractures of the radial head and neck in adults: a fifteen-to thirty-three-year follow-up study. *J Shoulder Elbow Surg* 2005;14:73-7.
- Poulsen JO, Tophoj K. Fracture of the head and neck of the radius. Follow-up on 61 patients. *Acta Orthop Scand* 1974;45:66-75.
- Helferich H. On fractures and dislocations. Hutchinson J, translator. London: New Sydenheim Society 1899,96-7.
- Ikeda M, Oka Y. Function after early radial head resection for fracture: a retrospective evaluation of 15 patients followed for 3-18 years. *Acta Orthop Scand* 2000;71:191-4.
- Mason ML. Some observations on fractures of the head of the radius with a review of one hundred cases. *Br J Surg* 1954;42:123-32.
- Bakalim G. Fractures of radial head and their treatment. *Acta Orthop Scand* 1970;41:320-31.
- Malmvik J, Herbertsson P, Josefsson PO, Hasserijs R, Besjakov J, Karlsson MK. Fracture of the radial head and neck of Mason types II and III during growth: a 14-25 year follow-up. *J Pediatr Orthop B* 2003;12:63-8.
- Herbertsson P, Josefsson PO, Hasserijs R, Karlsson C, Besjakov J, Karlsson M. Uncomplicated Mason type-II and III fractures of the radial head and neck in adults. A long-term follow-up study. *J Bone Joint Surg Am* 2004;86:569-74.
- Herbertsson P, Josefsson PO, Hasserijs R, Besjakov J, Nyqvist F, Karlsson MK. Fractures of the radial head and neck treated with radial head excision. *J Bone Joint Surg Am* 2004;86:1925-30.
- Esser RD, Davis S, Taavao T. Fractures of the radial head treated by internal fixation: late results in 26 cases. *J Orthop Trauma* 1995;9:318-23.
- Geel CW, Palmer AK, Ruedi T, Leutenegger AF. Internal fixation of proximal radial head fractures. *J Orthop Trauma* 1990;4:270-4.
- King GJ, Evans DC, Kellam JF. Open reduction and internal fixation of radial head fractures. *J Orthop Trauma* 1991;5:21-8.
- Pearce MS, Gallannaugh SC. Mason type II radial head fractures fixed with Herbert bone screws. *J R Soc Med* 1996;89:340-4.
- Ring D, Quintero J, Jupiter JB. Open reduction and internal fixation of fractures of the radial head. *J Bone Joint Surg Am* 2002;84:1811-5.
- Dirschl DR, Marsh JL, Buckwalter JA, Gelberman R, Olson SA, Brown TD. Articular fractures. *J Am Acad Orthop Surg* 2004;12:416-23.
- Primary Nonoperative Treatment of Moderately Displaced Two-Part Fractures of the Radial Head BY Thomas Åkesson *et al.*, *J Bone Joint Surg Am*. 2006.
- Commented Fractures of the Radial Head: Comparison of Resection and Internal Fixation Surgical Technique By Masayoshi Ikeda, MD, PhD *et al.*, 2016. doi:10.2106/JBJS.E.00841.