

E-ISSN: 2395-1958
P-ISSN: 2706-6630
IJOS 2021; 7(1): 98-103

www.orthopaper.com
Received: 12-11-2020
Accepted: 14-12-2020

R Sahaya Jose
Associate Professor, Department of Orthopaedics, Sree Mookambika Institute of Medical Sciences, Kanyakumari, Tamil Nadu, India

K Visnu
Post Graduate, Department of Orthopaedics, Sree Mookambika Institute of Medical Sciences, Kanyakumari, Tamil Nadu, India

Shaheen Hameed
Post Graduate, Department of Orthopaedics, Sree Mookambika Institute of Medical Sciences, Kanyakumari, Tamil Nadu, India

K Vivek
Post Graduate, Department of Orthopaedics, Sree Mookambika Institute of Medical Sciences, Kanyakumari, Tamil Nadu, India

Corresponding Author:
R Sahaya Jose
Associate Professor, Department of Orthopaedics, Sree Mookambika Institute of Medical Sciences, Kanyakumari, Tamil Nadu, India

Functional outcome of tension band wiring in transverse fracture of medial malleolus

R Sahaya Jose, K Visnu, Shaheen Hameed and K Vivek

DOI: https://doi.org/10.22271/ortho.2021.v7.i1b.2466

Abstract
Background and Objectives: Medial malleoli fracture is one of the common fractures in ankle joint mainly due to road traffic accidents in which transverse fracture of medial malleolus accounts for significant morbidity and mortality. Tension band wiring (TBW) is an accepted modality of treatment which enables the early mobilization of the patients more than any other methods of treatment at present. TBW converts a tensile force into compressive force thereby improves fracture healing, early mobilization and improved functional outcome of medial malleoli fracture of ankle joint.
Materials and Methods: A longitudinal cohort study of transverse fracture of medial malleolus requiring surgical treatment, 20 patients were selected by convenient sampling technique and were operated by tension band wiring technique. In our study, we use Lauge- Hansen classification pronation – abduction and pronation- eversion type, patients were evaluated for functional outcome by using American Orthopaedic Foot and Ankle Society (AOFAS) Ankle – Hind foot scale. All data were analyzed using SPSS software v 20.0.
Results: The result of our study shows the effectiveness of the procedure for medial malleolus where good to excellent results were obtained in 75% of cases, fair results were in 15% of cases and poor results in 10%.
Conclusion: TBW is a simple, inexpensive technique and effective means of fixing medial malleolus fracture based on biomechanical principle with minimum complications. Long-term complications of prolonged immobilization like joint stiffness, muscle wasting, pressure sores and osteoporosis are avoided. TBW for medial malleolus helps by achieving compression at the fracture site, the fracture heals faster and helps in early rehabilitation.

Keywords: Tension band wiring, medial malleoli, American orthopaedic foot, ankle society (AOFAS), ankle – hind foot scale

Introduction

Fracture at the ankle joint is commonly encountered by an orthopaedic surgeon in day-to-day daily practices. In this era, fracture of medial malleoli is mainly resulted from road traffic accidents with the lesser force of impact and due to twisting type of injury to the ankle. The medial malleolus is the slightly expanded medial portion of the distal end of tibia and projects inferomedially [1]. It is intra-articular and being subjected to continuous deforming forces from muscles. It is also difficult to restore the desired anatomical continuity and congruity of the articular surfaces after reduction and thereby causing complications like osteoarthritis, stiffness of joints, non-union, etc. Hence with better operative techniques, internal fixation of these fractures with tension band wiring (TBW) for transverse fractures has become an accepted mode of treatment with its outcome and results enabling the patient to resume their work without hampering their day-to-day life. TBW of medial malleoli fractures speeds up the healing and rehabilitation. It also allows for the early mobilization of the joint, thereby preventing stiffness of joints and other complications related to immobilization.

TBW is based on the principle of conversion of distractive forces into compressive forces at the fracture site, in transverse fractures, the advantages being rigid fixation and early ambulation in relation to other methods of internal fixation [2]. To apply an implant with a tension band technique, a device is fixed eccentrically to the convex side of the fractured bone. Since a curved structure has a compression side and a tension side when an axial load is applied, the device on the tension side neutralizes the forces under the axial load.

A tension band can produce compression statically or dynamically. The tension band wiring procedure allows a range of movements immediately at the involved joints, which provides an improved functional outcome.

Materials and Methods

This longitudinal cohort study selected conventional sampling of 20 patients with fracture of medial malleolus who attended Orthopaedics Department Sree Mookambika Institute of Medical Science, Kulasekharam from the period of July 2018 to July 2020 with the help of Lauge Hansen classification[3] pronation-abduction and pronation eversion type. Ethical approval was taken from the college Institutional Human Ethics Committee. Patients who are diagnosed as Closed displaced transverse fracture of Medial Malleolus, between the age group of 18 to 70 years, of both sex are included in the study. Whereas Patients with Comminuted fractures, Patients with any prior established deformity of the ankle due to old fracture, Polytrauma cases, Patients aged less than 18 years, and Patients who sustained Compound fractures were excluded from the study. We assessed the patients on an OPD basis at 4th, 8th, 12th week, 6months and yearly follow-up postoperatively with functional outcome were assessed by using American Orthopaedic Foot and Ankle Society (AOFAS) Ankle–Hind foot scale [4]. All data were analyzed using SPSS software v 20.0.

Operative technique: In our study under spinal anesthesia, antero-medial approach [5] was used. TBW done with 2 K-wires of size 1.5 to 2mm and 18 gauge stainless steel wire. Below knee POP slab was applied in a neutral position. The slab can be removed after 2 weeks and replaced with a removable splint. Check dressing was done on 2nd postoperative day. Following routine dressing, repeat x-ray AP and lateral views of the affected ankle were done. Sutures were removed on 12th post-operative day and an active range of movements started. Weight-bearing was allowed after 6 weeks.

Results

Out of 20 patients, 40% patients aged between 31-40 years. 25% of patients had an age between 41-50 years. 20% of patients had age between 20 -30 years. The least number of patients was seen in age between 51- 60 years. (Fig 1).

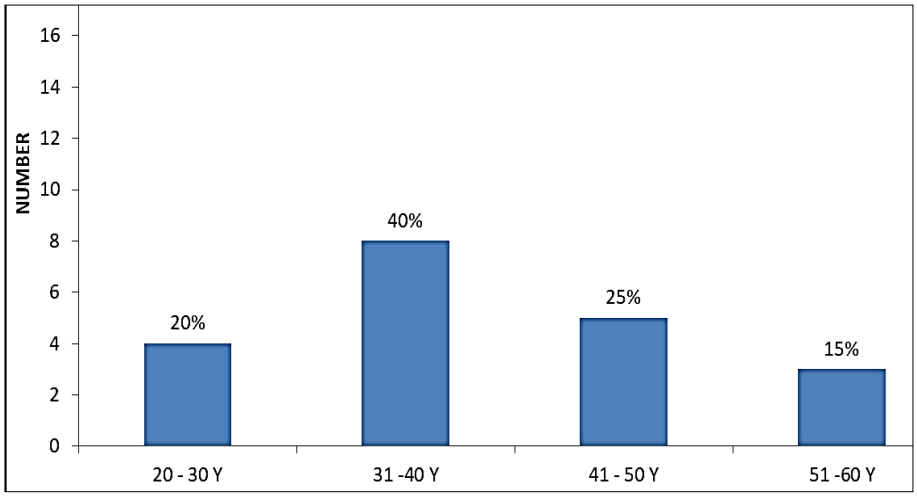

Fig 1: Distribution of patients based on the age

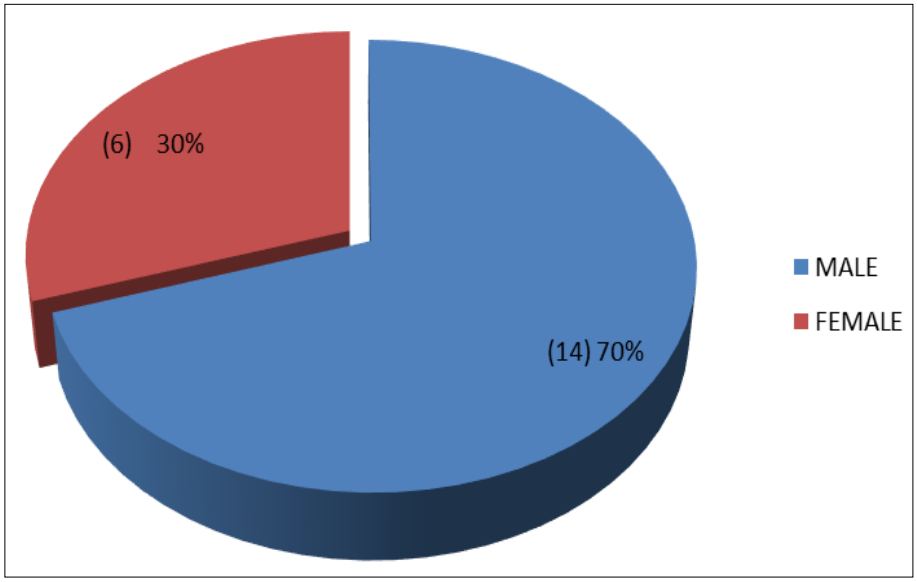

Fig 2: Distribution of patients based on gender

Males was more compared to females, were 70% was males in this study. Right side was most commonly fractured than left.

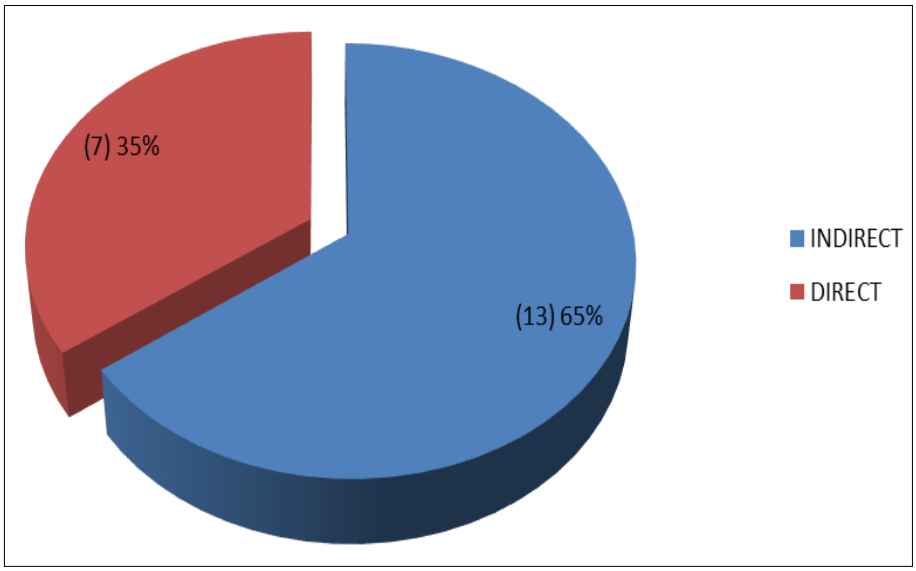

Fig 3: Distribution of patients based on mechanism of injury

65% patients had an indirect mode of injury and others had direct mode of injury

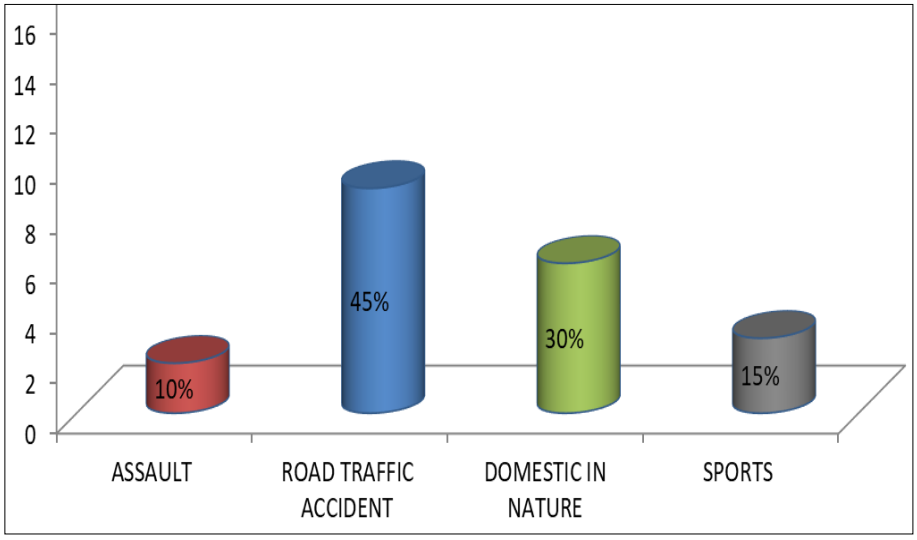

Fig 4: Distribution of patients based on mode of injury

Maximum patients had Road traffic accident mode of injury 45%. Domestic in nature type had 30% patients. 15% of patients had sports type. 10% of patients had the Assault mode of injury.

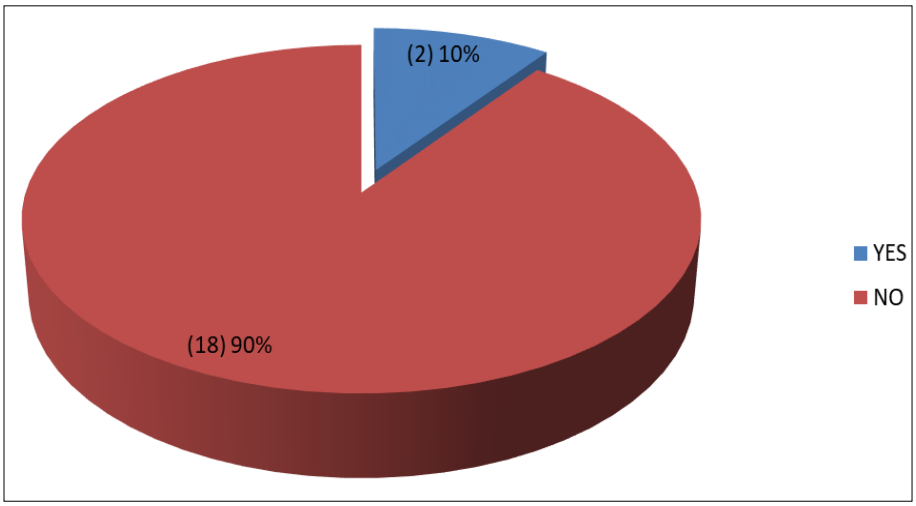

Fig 5: Distribution of patients based on associated injury

90% patients do not have any associated injury. Only 10% patients had associated injury.

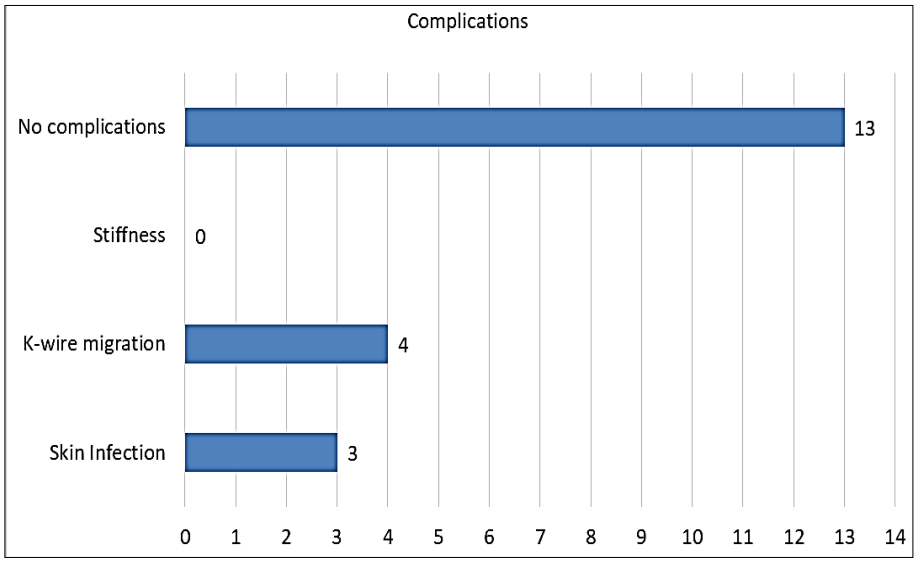

Fig 6: Complications of TBW in medial malleoli fracture

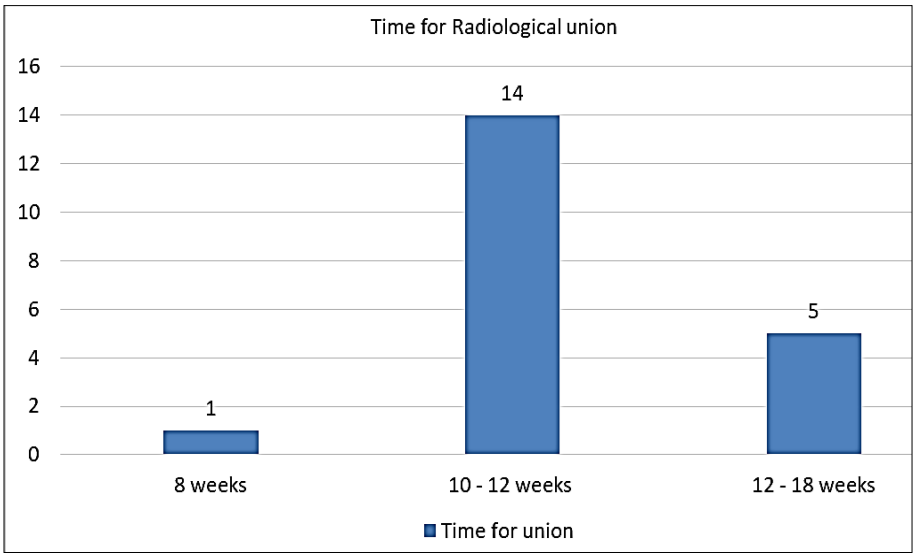

Fig 7: Time for radiological union

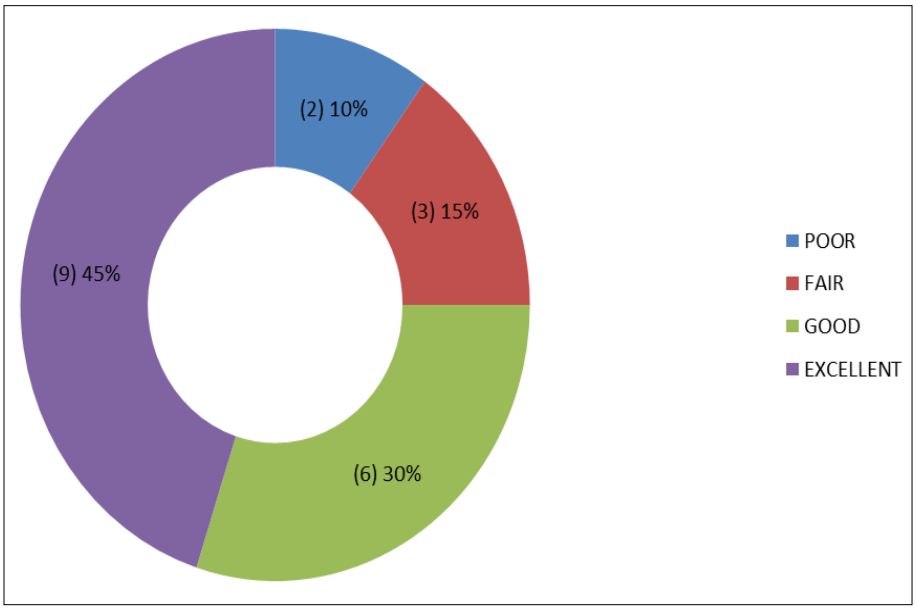

Fig 8: Distribution of patients based on final outcome

45% patients showed excellent outcome followed by 30% showed good. 15% patients showed fair and 10% showed poor outcome.

Case example: Medial malleolar fracture

Preparation

Exposure of the fracture site

Fixation of the fracture

Tension band wiring applied

Case example: Medial malleolar fracture

Pre-op X-ray

Post-op 4 weeks

Post-op 8 weeks

Discussion

Tension band wiring for medial malleolus was used in our 20 cases. It has given favorable results in our study. The findings, end results and other data will be analyzed and compared in the following discussion. The mean age of patients in this study was 36.5 years. This finding was slightly similar to the studies conducted by Gregory joy *et al* [6], and Georgiadis DM *et al* [7].

As in other studies on medial malleolus fractures, Male predominance was observed in this study also comprised of 14 (70%) male patients and 6 (30%) female patients. Maximum patients in this study were sustained by Road traffic accident 45%. In addition right ankle was the side more commonly injured than the left, which is comparable to other standard studies. In this study 13 (65%) patients had an indirect mechanism of the injury which was more compared with direct type 7 patients (35%). We had 10% of patients with associated injuries like posterior malleolar fracture and tibial pilon fracture.

Table 1: Comparison of outcome with previous studies

Series	Medial malleolus			
	Excellent (%)	Good (%)	Fair (%)	Poor (%)
Reddy KR *et al* [11]	43.3	30	20	6.7
Karra Bansilal [12]	50	32	14	4
Sagar Jawale [13]	77.7	11.1	11.1	0
Present study	45	30	15	10

Medial malleolus fractures in general necessitate exact anatomical reduction, since it is close to the ankle joint, to re-establish near-normal tibio-talar articulation. In our study we found that patients who had more anatomical reduction had better outcome both clinically and radiologically this supports the findings of Gregory. Joy *et al* [6].

Incomplete reduction in malleolar fracture may cause complications like post-traumatic stiffness and arthritis [8]. An in-depth knowledge about the anatomy of ankle, the mechanism of the injury and strictly following the basic principles of fracture treatment are the basis for a good result. Anatomical reduction of the fracture fragment in displaced medial malleoli fractures also corrects the talar displacement which is vital in treatment of unstable fractures [9, 10].

The results in this study are compared with Reddy KR *et al* [11], Karra Bansilal [12], Sagar Jawale [13]. In the study done by Reddy KR *et al*, good to excellent results were obtained in about 73.3% cases, in Karra Bansilal *et al* series, good to excellent results were obtained in 82% of cases. Similarly, in Sagar Jawale series, good to excellent results were obtained in 88.8% of cases. In our present study we found that the effectiveness of the Tension band wiring procedure for the medial malleoli fracture were good to excellent in 15 patients (75 %), fair results were in 3 patients (15%) and poor results in 2 patients (10%).

In our study there was no complication in 13 patients (65%), superficial infection was seen in 3 (15%) patients and K-wire migration was observed in 4 (20%) patients. The superficial infection was attributed to uncontrolled diabetes in all of these patients.

Conclusion

TBW is a simple, inexpensive technique and effective means of fixing medial malleolus fracture based on biomechanical principle with minimum complications. Long term complications of prolonged immobilization like joint stiffness, muscle wasting, pressure sores and osteoporosis are avoided. TBW for medial malleolus helps by achieving compression at fracture site, the fracture heals faster and helps in early rehabilitation.

Reference

1. Egol KA, Zuckermann JD. Handbook of fractures. LWW. 4th edition. Handbook of fracture 2013, P477.
2. Fowler TTY, Kevin Pugh J, Alan Litsky S, Benjamin Taylor C, Bruce French G. Medial malleolar fractures: A biomechanical study of fixation techniques. Orthopaedics 2011;34:349-55.
3. Campbell's Operative Orthopaedics, 11th ed 3, P2713.
4. Van Lieshout EEM, De Boer AS, Meuffels DE *et al*. American Orthopaedic Foot and Ankle Society (AOFAS) Ankle-Hindfoot Score: a study protocol for the translation and validation of the Dutch language version. BMJ Open 2017;7(2):e012884.
5. Stanley Hoppenfeld, Piet de Boer, Richard Buckley. Surgical Exposures in Orthopaedics. The Anatomic Approach 5th ed, Chap 12 P638.
6. Gregory Joy G, Patzakis MJ, Harvey JP. Precise Evaluation of the Reduction of Severe Ankle Fractures. J Bone Joint Surg 1974;56A:979-993.
7. Georgiadis GM, White DB. Modified tension band wiring of medial malleolar ankle fractures. J Foot and Ankle 1995;16:64-8.
8. Beris AE, Kabbani KT, Xenakis TA, Mitsionis G, Soucacos PK, Soucacos PN. Surgical treatment of malleolar fractures – a review of 144 patients. Clin Orthop Related Research 1997;341:90-98.
9. Böstman O, Hirvensalo E, Vainiopää S *et al*. Ankle Fractures Treated Using Biodegradable Internal Fixation. Clin Orthop 1989;238:195-203.
10. Bray TJ, Endicott M, Capra SE. Treatment of Open Ankle Fractures. Clin Orthop 1989;240:47-52.
11. Rao TK, Rathod J, Parinitha, Kiran V. A Prospective Study on Surgical Management of Medial Malleolar Fractures with Tension Band Wiring. Inter J Contemp Med Res 2016;3(7):2049-52.
12. Bansilal K, Kommera S. Management of Fractures Of Patella Olecranon, Malleoli By Tension Band Wiring Method. International Journal of Medical Science and Clinical Invention 2016;3(5):1824-36.
13. Dr. Sagar Jawale, Dr. Gaurav Ranglani, Dr. Parminder Singh, Dr Arvind Kadwad, Dr. Vinothkumar L, Dr. Deepak Tambe. A prospective observational study of 30 patients of avulsion fracture treated with tension band wiring followed up to 6 months. International Journal of Orthopaedics Sciences 2019;5(4):520-525. DOI: 10.22271/ortho.2019.v5.i4i.1726.