



# International Journal of Orthopaedics Sciences

E-ISSN: 2395-1958  
P-ISSN: 2706-6630  
IJOS 2021; 7(1): 34-38  
© 2021 IJOS  
[www.orthopaper.com](http://www.orthopaper.com)  
Received: 11-11-2020  
Accepted: 25-12-2020

**Dr. Shubham Redhal**  
Post Graduate Trainee,  
Department of Orthopaedic,  
Muzaffarnagar Medical College  
Muzaffarnagar, Uttar Pradesh,  
India

**Dr. Arpit Goyal**  
Post Graduate Trainee,  
Department of Orthopaedic  
Muzaffarnagar Medical College  
Muzaffarnagar, Uttar Pradesh  
India

**Dr. Vipul Kumar**  
Assistant Professor, Department  
of Orthopaedic, Muzaffarnagar  
Medical College Muzaffarnagar,  
Uttar Pradesh, India

**Dr. Anil Singh**  
Associate Professor, Department  
of Orthopaedic, Muzaffarnagar  
Medical College Muzaffarnagar,  
Uttar Pradesh, India

**Dr. Arvind Kumar**  
Professor and Head,  
Department of Orthopaedic,  
Muzaffarnagar Medical College  
Muzaffarnagar, Uttar Pradesh,  
India

**Corresponding Author:**  
**Dr. Shubham Redhal**  
Post Graduate Trainee,  
Department of Orthopaedic,  
Muzaffarnagar Medical College  
Muzaffarnagar, Uttar Pradesh,  
India

## Functional outcome of hemiarthroplasty as a treatment option for trochanteric fractures

**Dr. Shubham Redhal, Dr. Arpit Goyal, Dr. Vipul Kumar, Dr. Anil Singh and Dr. Arvind Kumar**

DOI: <https://doi.org/10.22271/ortho.2021.v7.i1a.2457>

### Abstract

**Objectives:** Management of unstable intertrochanteric fractures in elderly patients is challenging due to osteoporosis. Comminuted unstable intertrochanteric fractures require early postoperative immobilization. Most of the recent reports have recommended Hemiarthroplasty for treatment of unstable intertrochanteric fractures to avoid various immobilization-associated complications like bed sore, pneumonia, urinary infection. The purpose of this study was to evaluate the functional and clinical outcomes of bipolar hemiarthroplasty for intertrochanteric fractures.

**Methods:** Fifteen patients aged over 60 years underwent hemiarthroplasty to treat unstable intertrochanteric fractures and were followed up over 12 months. All surgeries were performed by the same surgical team using the Hardinge (lateral) approach. Wires, cables, and plates were used as required. Use of cemented prostheses was considered when the lesser trochanter had been displaced. All patients were allowed full weight-bearing as tolerated as soon as possible. Clinical evaluation was based on Harris Hip Scores.

**Results:** In our study, there were 6 male and 9 female patients with mean age of 70.26 years. 86.67% of the cases admitted were due to trivial trauma, 13.33% due to RTA with right side being more common side affected. In all patient partial weight bearing was started within 5 days. Good to excellent results were seen in 92.85% cases & Fair results were seen in 7.15% of cases in our study according to Harris Hip Score.

**Conclusions:** Primary bipolar hemiarthroplasty for treating unstable intertrochanteric fractures provide a stable, pain free and mobile joint. It also eliminates the need for prolonged immobilization and permits early ambulation. As reported by others, hip hemiarthroplasty is an effective treatment choice for unstable intertrochanteric femoral fracture in older patients.

**Keywords:** Primary bipolar hemiarthroplasty, harris hip score, unstable intertrochanteric fractures

### Introduction

Trochanteric fracture is most common fracture in elderly population. Incidences of these fracture has increased primarily due to increasingly like spam and more sedentary life style in elderly population, it is more due to trivial trauma whereas in younger population, it occur due to high velocity trauma [1]. Intertrochanteric fracture is more common in female as compared to men due to osteoporosis. Unstable intertrochanteric fracture in elderly patients as associated with high rates of morbidity and mortality compound due to need for prolonged immobilization, a though result have been improved with use of internal fixation [2]. Conservative trauma of this fracture result in decubitus ulcer, pneumonia, joints contracture, urinary infection and thromboembolic complication [3]. Adequate fixation is very important in these patients, so as to mobilize them earliest and prevent complication of recumbency like bedsores, deep vein thrombosis and respiratory infections. Osteoporosis and difficult anatomical reduction are one of the most important factors leading to unsatisfactory results in these fractures [4, 5, 6]. To allow early post-operative weight bearing and to avoid excessive collapse at fracture site, hemiarthroplasty is recommended by some surgeon [7, 8, 9]. So patient treated with hemiarthroplasty are early mobilized and rate of complications get decreased.

**Material & Methods**

This Prospective study was done in Muzaffarnagar Medical College under the guidelines of institute of ethic committee of Hospital, a total number of 15 patients during period of 18 months between 2019 to 2020 were considered.

**Inclusion criteria**

1. Patient with unstable intertrochanteric fracture
2. Patient with non-united trochanteric fracture
3. Patient with trochanteric fracture treated by internal fixation which had gone failure.

**Exclusive criteria**

1. Poly trauma patient & injury to ipsilateral lower limb
2. Medically unfitted patient
3. Compound intertrochanteric fracture femur
4. Patient not willing for surgery

Anterior Posterior, X-ray of the pelvis with both hips and later view of injured joint were taken injured limb was taken in a Thomas under standard aseptic precaution. Surgery were performed using Hardinge (lateral) approach with patient in lateral position under spinal anesthesia after assessing the fracture anatomy and extraction of the femur head appropriate size of bipolar prosthesis was placed in 10 to 15 degree of anti-version in case of postero medial comminution, reconstruction using stainless steel wire, kirschner wire or ethibond suture were done before insertion of the final bipolar prosthesis. Greater trochanter comminution was also reconstruction with the help of K-wire & TBW wound was closed in layers over a suction drain which is removed at first change of dressing after 48 hours Post operatively adequate analgesic & antibiotic was given. Post-operative x-ray were done operative limb was kept in 30° abduction. All the patients undergoes a routine post-operative physiotherapy which includes gate training in form of walking with help of walker from 2<sup>nd</sup>- 3<sup>rd</sup> post of day till full weight bearing was allowed as per pain tolerance. Suture were removed after two weeks of surgery. Patient were examined post-operatively at six weeks, three months, six months, one year. At each follow-up clinic-radiological examination was done & patient was evaluated using Harris hip score are graded as < 70 poor, 70 – 79 fair, 80-89 good, 90-100 excellent.

**Result**

The following observation were made from the data collected during the study of 15 cases of intertrochanteric fracture treated by bipolar hemi arthroplasty in department of Orthopaedics of Muzaffarnagar Medical College, Muzaffarnagar during period of 18 months between 2019 to 2020. Out of 15 patients there were 9 female & 6 male, the

mean age was 70.26 years, most common of injury was trival fall 86.67% followed by Road traffic accident t 13.33%. hypertension 60 % was most common comorbidity in this study followed by chronic pulmonary disease 40% and 13.33 % had diabetes.

Total of 7 patients operated within 7 days, & 8 patients in 7 to 14 days due to morbidities. The average surgery time was 82.29 minute (68-110 minutes) average blood loss was 402cc range (125 to 700cc). 6 patients need blood transfusion

All the patient started partial weight bearing from 2<sup>nd</sup>-3<sup>rd</sup> post day. There was no incidence of post-operative dislocation of prosthesis in the study. 1 patient expired on 4<sup>th</sup> post-operative day due to sudden cardiopulmonary arrest.

Patient were followed up at 6 weeks, 3 months, 6 months, 12 months. Majority of the patient had a pain free mobile hip, will full range of abduction, flexion and adequate amount of rotation and adduction. There was no incidence of revision surgeries. The final result were good to excellent according to Harris Hip Score.

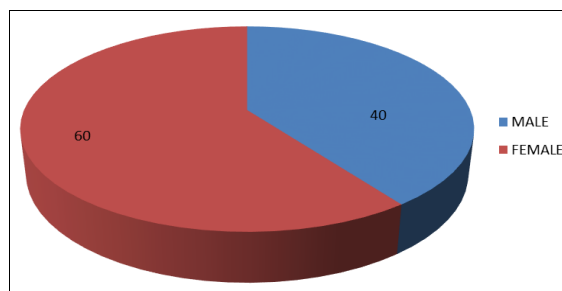
According to Harris Hip Score at 6 months (Table 1), 2 patients were graded as excellent, 10 patients as good, 2 patients as fair. At 1-year follow-up (Table 2), 4 patients were graded as excellent, 9 patients as good, 1 as fair

**Table 1:** Functional results at 3 months after surgery using Harris Hip Score.

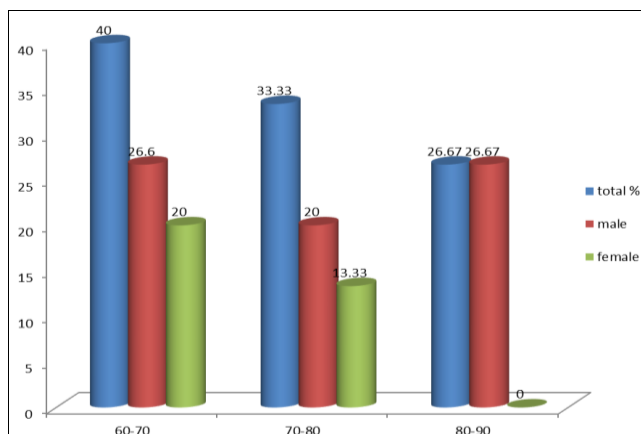
Results	Number of cases (%)
Excellent	2 (14.28)
Good	10 (71.42)
Fair	2 (14.28)

**Table 2:** Functional result 1 year after surgery using Harris Hip Score

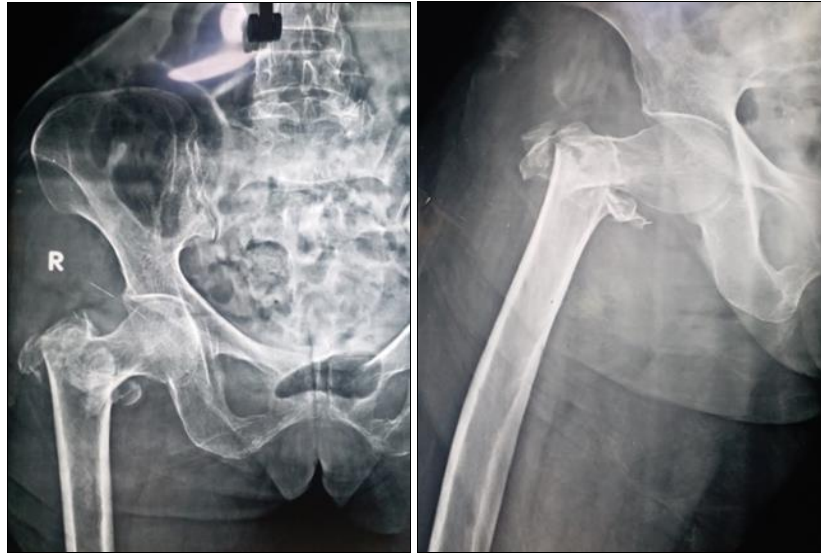Results	Number of cases (%)
Excellent	4 (28.57)
Good	9 (64.28)
Fair	1 (7.14)



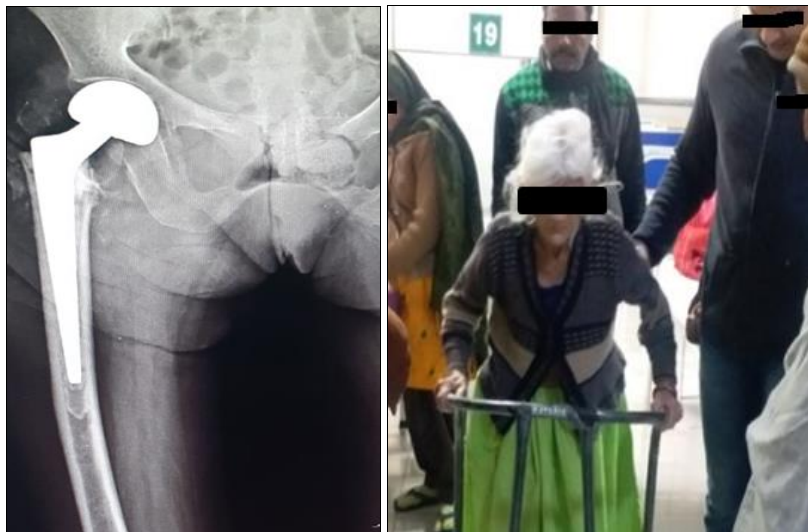**Fig 1:** Sex distribution



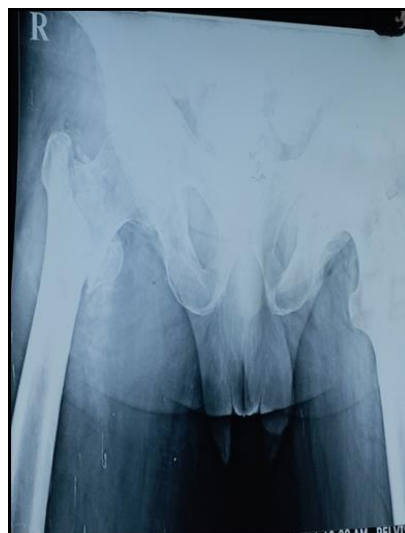**Fig 2:** Age distribution



**Fig 3: Pre-Operative**



**Fig 4: Post-Operative**



**Fig 5: Pre-Operative**



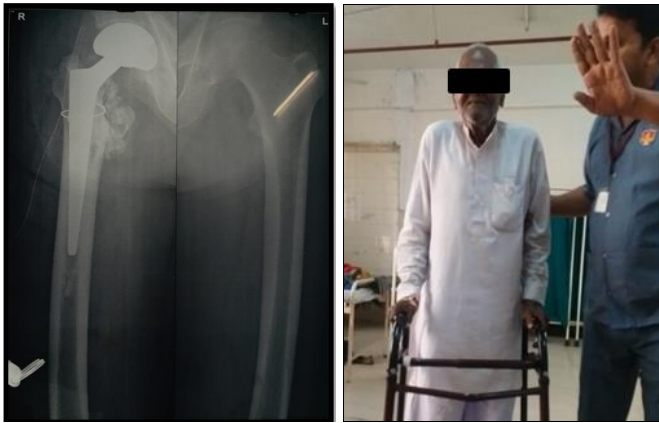

Fig 6: Post-Operative

## Discussion

Hip fractures are associated with notable morbidity and mortality mainly in elderly patients. Internal fixation has reduced the mortality associated with intertrochanteric fractures<sup>[10]</sup>. Often because of poor bone quality that is age related osteoporosis there is a high failure rate of internal fixation methods<sup>[11]</sup> and early mobilisation is difficult. Incidence of general complications such as pulmonary embolism, DVT and pneumonia ranges from 22% to 50% when internal fixation was adopted because of delayed mobilisation<sup>[12, 13]</sup>. Although there are some fixation methods such as fixed nail plate which was used in past, sliding hip screw and intramedullary interlocking devices, which does not give absolute fracture stability and complete bone union in elderly patients<sup>[14-16]</sup>. Literature concerning the treatment and results of comminuted intertrochanteric fracture of the hip are extensive. Massie, Hoit, Dimon and Hughston, Sarmento and Williams have done outstanding work in attempt to change an unstable intertrochanteric fracture into a stable one and fix it with a device until it heals. The reported complication rate for treating unstable intertrochanteric fractures ranges from 18% to 50%<sup>[17, 18]</sup>.

Despite the fact that union rates of as high as 100% have been published in cases of stable well-reduced fractures that had ideal implant placement, at the same time up to 56% of failure rate has been associated with comminuted, unstable fractures in osteoporotic elderly people with suboptimal fracture fixation<sup>[19]</sup>.

Intertrochanteric fractures in the elderly pose certain special problems. In this age group, the fracture configuration is generally comminuted, with extensive osteoporosis being present. Because of extensive osteoporosis and consequent poor mechanical property of bone, frequently inability to get good purchase of screws is encountered leading to subsequent implant failure. This leads to collapse and varus malposition of femoral head causing dysfunction of abductor mechanism manifesting as limping<sup>[20]</sup>. As there are problems of correct and accurate placement of the implant and hold of the implant, hence prolonged immobilization for achieving bony union is advised. On the other hand, there is a need for rapid full weight-bearing mobilization of this group of patients as they are generally medically compromised due to age and associated diseases. In addition, these patients may not have adequate psychomotor skills required for graded and protected weight bearing. Hence, there are two conflicting requirements that need to be addressed to, in a balanced way.

We believe that treating unstable intertrochanteric fractures in a selected group of physiologically elderly group of patients with compromised general health and comminuted fractures

in osteoporotic bone stock by primary hemiarthroplasty, the phase of fracture healing is essentially bypassed and a stable, mobile, relatively pain-free joint is immediately provided. This eliminates the need for prolonged immobilization and permits early ambulation. This gives an edge over internal fixation/osteosynthesis in which there is a dilemma between the need of early mobilization versus protection of the hip for bony union. And also, the fears of implant failures and cutouts are eliminated.

Essentially in these patients, there is a need for rapid pain-free full weight-bearing mobilization to restore them to their pre-injury level of activity.

There are multiple studies showing good results with hemiarthroplasty. Liang *et al.*<sup>[21]</sup> in their study of unstable intertrochanteric fractures concluded that it is an effective method to treat the unstable intertrochanteric fractures in elderly patients with hemiarthroplasty. The result was satisfactory. It can decrease the complications, reduce the mortality, improve the patients living quality, and reduce the burden of the patient's family.

Grimsrud *et al.*<sup>[22]</sup> studied 39 consecutive patients of unstable intertrochanteric fractures treated with a cemented bipolar hemiarthroplasty. They concluded that these fractures can be treated with a standard femoral stem and cerclage cabling of the trochanters. The technique allows safe early weight bearing on the injured hip and had a relatively low rate of complications.

Rodop *et al.*<sup>[23]</sup> in a study of primary bipolar hemiarthroplasty for unstable intertrochanteric fractures in 54 elderly patients obtained 17 excellent and 14 good results after 12 months according to the Harris Hip-Scoring system.

In a comparative study of cone hemiarthroplasty versus internal fixation, Kayali *et al.*<sup>[24]</sup> reached the conclusion that clinical results of both groups were similar. Hemiarthroplasty patients were allowed full weight-bearing significantly earlier than the internal fixation patients. Cone hemiarthroplasty can be an alternative treatment for unstable intertrochanteric fractures in elderly patients so as to achieve earlier mobilization.

Stern and Goldstein<sup>[25]</sup> reported on 29 patients with intertrochanteric fractures treated with Leinbach prosthesis with excellent results.

Proponents of conventional internal fixation have raised the issues of increased blood loss, infection, and dislocation associated with bipolar hemiarthroplasty. However, Stappaerts *et al.*<sup>[26]</sup> found that there was no difference between two groups except high requirement of blood transfusion in replacement group. In our study, 9 out of 32 patients (28.12%) required intraoperative or post-operative blood transfusion. Haentjens *et al.*<sup>[27]</sup> found a significant reduction in incidence of pressure sore and pneumonia in patients undergoing prosthesis replacement surgery. In our study, as our emphasis was on faster rehabilitation; out of total 32 patients, only 1 patient (3.12%) developed pressure sore and another 1 patient (3.12%) developed pneumonia.

The Indian perspective of using primary hemiarthroplasty as treatment option for unstable intertrochanteric fractures is explored by few authors. Sancheti *et al.*<sup>[28]</sup> concluded that hemiarthroplasty for unstable osteoporotic intertrochanteric fractures in elderly results in early ambulation and good functional results.

Kumar *et al.*<sup>[29]</sup> also concluded that unstable intertrochanteric fractures in elderly are better treated with cemented hemiarthroplasty than with internal fixation. Besides an early ambulation and less hospital stay, cemented hemiarthroplasty

provides stable and mobile hips. Weight bearing can be started earlier than in other methods of treatment, which prevents any recumbency related complications.

In our study, all the patients were initiated on static exercises on the 2nd post-operative day for the glutei, hamstrings, and quadriceps and the patients were allowed partial weight bearing by 2-5 days.

In our study, early walking with full weight bearing was possible in most 12/15 patients with unstable intertrochanteric fracture who were previously mobile with or without support within 10 days of surgery.

In the present series, the incidence of complications was significantly less possibly due to faster rehabilitation.

### Conclusion

Though the sample size of study is small and period of follow up to assess the result & complication is short even it can be concluded that hemiarthroplasty a stable, pain free and mobile joint with early mobilization. It can be a good alternative for management of unstable Trochanteric fracture in elderly patients. Good clinical and functional outcomes assessed as per Harris hip score were obtained with 92.85% patients showing good to excellent results. Still, a more extensive study containing a larger population is needed to make firm commitment for this modality.

### References

- Canale ST. Campbell's operative orthopaedics. 12th ed.
- White BL, Fisher WD, Laurin CA. Rate of mortality for elderly patients after fracture of the hip in the 1980's. *J Bone Joint Surg Am* 1987;69:1335-40.
- Zuckerman JD. Comprehensive care of orthopaedic injuries in the elderly. Baltimore: Urban and Schwarzenberg 1990.
- Kim WY, Han CH, Park JI, Kim JY. Failure of intertrochanteric fracture fixation with a dynamic hip screw in relation to pre-operative fracture stability and osteoporosis. *Int Orthop* 2001;25:360-2.
- Karsson S. Treatment of osteoporotic fractures. *Scand J Surg* 2002;91:140-6.
- Jensen JS, Tondenvold E, Mossing N. Comminuted trochanteric fractures treated with the sliding screw - plate system: A biochemical study of comminuted trochanteric fractures. III. *Acta Orthop Scand* 1978; 49:392-7.
- Broos PL, Rommens PM, Greens VR, Stappaerts KH. Peritrochanteric fractures in the elderly. Is the Belgium VDP prosthesis the best treatment for unstable fractures with sever comminution? *Acta Chir Belg* 1991;91:242-249.
- Harwin SF, Stern RE, Kulick RG. Primary bateman-Leinbach bipolar prosthetic replacement of the hip in the treatment of unstable intertrochanteric fracture in the elderly. *Orthopedics* 1990;13:1131-1136.
- Greens Moore T, Proano F. Bipolar prosthetic replacement for the management of unstable intertrochanteric hip fractures in the elderly. *Clin orthop Relat Res* 1987;224:169-77.
- White BL, Fisher WD, Laurin CA. Rate of mortality for elderly patients after fracture of the hip in the 1980's. *J Bone Joint Surg Am* 1987;69:1335-40.
- Haidukewych GJ, Berry DJ. Hip arthroplasty for salvage of failed treatment of intertrochanteric hip fractures. *J Bone Joint Surg Am* 2003;85-A:899-904.
- Kenzora JE, McCarthy RE, Lowell JD, Sledge CB. Hip fracture mortality. Relation to age, treatment, preoperative illness, time of surgery, and complications. *Clin Orthop Relat Res* 1984;186:45-56.
- Baumgaertner MR, Curtin SL, Lindskog DM. Intramedullary versus extramedullary fixation for the treatment of intertrochanteric hip fractures. *Clin Orthop Relat Res* 1998;348:87-94.
- Kim SY, Kim YG, Hwang JK. Cementless calcarreplacement hemiarthroplasty compared with intramedullary fixation of unstable intertrochanteric fractures. A prospective, randomized study. *J Bone Joint Surg Am* 2005;87:2186-92.
- Habernek H, Wallner T, Aschauer E, Schmid L. Comparison of ender nails, dynamic hip screws, and Gamma nails in the treatment of peritrochanteric femoral fractures. *Orthopedics* 2000;23:121-7.
- Papasimos S, Koutsojannis CM, Panagopoulos A, Megas P, Lambiris E. A randomized comparison of AMBI, TGN and PFN for treatment of unstable trochanteric fractures. *Arch Orthop Trauma Surg* 2005;125:462.
- Sarmeinto A. Intertrochanteric fractures of femur, 150-degree angle nail plate fixation and early rehabilitation, a preliminary report of 100 cases. *J Bone Joint Surg* 1963;45-A:706-22.
- Dimon JH, Hughston JC. Unstable intertrochanteric fractures of hip. *J Bone Joint Surg* 1969;49A:440.
- Haidukewych GJ, Israel TA, Berry DJ. Reverse obliquity fractures of the intertrochanteric region of the femur. *J Bone Joint Surg Am* 2001;83:643-50.
- Sinno K, Sakr M, Girard J, Khatib H. The effectiveness of primary bipolar arthroplasty in treatment of unstable intertrochanteric fractures in elderly patients. *N Am J Med Sci* 2010;2:561-8.
- Liang YT, Tang PF, Guo YZ, Tao S, Zhang Q, Liang XD *et al*. Clinical research of hemiprosthesis arthroplasty for the treatment of unstable intertrochanteric hip fractures in elderly patients. *Zhonghua Yi Xue Za Zhi* 2005;85:3260-2.
- Grimsrud C, Monzon RJ, Richman J, Ries MD. Cemented hip arthroplasty with a novel cerclage cable technique for unstable intertrochanteric hip fractures. *J Arthroplasty* 2005;20:337-43.
- Rodop O, Kiral A, Kaplan H, Akmaz I. Primary bipolar hemiprosthesis for unstable intertrochanteric fractures. *Int Orthop* 2002;26:233-7.
- Kayali C, Agus H, Ozluk S, Sanli C. Treatment for unstable intertrochanteric fractures in elderly patients: Internal fixation versus cone hemiarthroplasty. *J Orthop Sure (Hong Kong)* 2006;14:240-4.
- Stern MB, Goldstein TB. The use of the Leinbach prosthesis in intertrochanteric fractures of the hip. *Clin Orthop Relat Res* 1977;128:325-31.
- Stappaerts KH, Deldycke J, Broos PL, Staes FF, Rommens PM, Claes P. Treatment of unstable peritrochanteric fractures in elderly patients with a compression hip screw or with the Vandeputte (VDP) endoprosthesis: A prospective randomized study. *J Orthop Trauma* 1995;9:292-7.
- Haentjens P, Casteleyn PP, de Boeck H, Handelberg F, Opdecam P. Treatment of unstable intertrochanteric and subtrochanteric fractures in elderly patients. Primary bipolar arthroplasty compared with internal fixation. *J Bone Joint Surg Am* 1989;71:1214-25.
- Sancheti K, Sancheti P, Shyam A, Patil S, Dhariwal Q, Joshi R. Primary hemiarthroplasty for unstable osteoporotic intertrochanteric fractures in the elderly: A retrospective case series. *Indian J Orthop* 2010;44:428-34.
- Kumar GN, Meena S, Kumar NV, S M, Raj MK. Bipolar hemiarthroplasty in unstable intertrochanteric fractures in elderly: A prospective study. *J Clin Diagn Res* 2013;7:1669-71.