

E-ISSN: 2395-1958
P-ISSN: 2706-6630
IJOS 2021; 7(1): 28-33
© 2021 IJOS
www.orthopaper.com
Received: 08-11-2020
Accepted: 23-12-2020

Dr. PG Jagannath
Assistant Professor, Department
of Orthopedics, Esic Medical
College and Hospital, Chennai,
Tamil Nadu, India

Dr. SN Lokesh Kumar
Assistant Professor, Department
of Orthopedics, Srm Medical
College and Hospital Srmist
University, Kattankulathur,
Chennai, Tamil Nadu, India

Dr. PG Vijay Karthik
Assistant Surgeon, Government
Medical College, Thiruvallur,
Chennai, Tamil Nadu, India

Dr. M Durai Kumar
Associate Professor, Department
of Orthopaedics, Esic Medical
College and Hospital, Chennai,
Tamil Nadu, India

Dr. SP Ilangovan Subbiah
Senior Resident, Department of
Orthopaedics, Esic Medical
College and Hospital, Chennai,
Tamil Nadu, India

Corresponding Author:
Dr. SN Lokesh Kumar
Assistant Professor, Department
of Orthopedics, Srm Medical
College and Hospital Srmist
University, Kattankulathur,
Chennai, Tamil Nadu, India

Uncemented acetabular component placement in developmental dysplasia of the hip (DDH) – time tested method revisited-medial protrusio technique

Dr. PG Jagannath, Dr. SN Lokesh Kumar, Dr. PG Vijay Karthik, Dr. M Durai Kumara and Dr. SP Ilangovan Subbiah

DOI: <https://doi.org/10.22271/ortho.2021.v7.i1a.2456>

Abstract

Introduction: Proper positioning of the acetabular cup is pivotal in any total hip arthroplasty. Cases of DDH have shallow acetabulum which is deformed and oblong and the femur head corresponds to it. Identifying the correct centre of hip rotation is difficult. In this study we highlight the easy technique of “Medial protrusion technique” for cup placement.

Materials and Methods: Skeletally mature patients with developmental dysplasia of hip showing clinical and radiological hip arthritis were included. Total of ten hips with DDH and hip arthritis underwent THA using this technique. Radiological evaluation with X ray and CT was done and the Harris hip score was calculated preoperatively and subsequently in all follow ups.

Results: The average follow up period was 5.5 ± 1.3 years. The mean Harris hip score in these patients was 86.5 ± 1.4 . Two patients out of 10 patients had excellent results, while 8 patients were rated as having good results. The average pain score was 41.6. The x-rays demonstrated good overall alignment and fixation of the acetabular cup. All cups were integrated well.

Conclusion: Our study confirms that this technique is simple safe and easily reproducible and time reliable technique providing superior outcomes in uncemented THA in DDH cases.

Keywords: Developmental dysplasia of the hip, medial protrusion technique, THA in developmental dysplasia of the hip

Introduction

Total Hip Arthroplasty is a successful surgical treatment modality for treating arthritis of the hip joint due to Developmental Dysplasia of Hip. The challenging aspect in such cases of DDH lies in both the acetabulum and in the proximal femur^[1]. Particular difficulties are especially faced by the surgeon in Crowe Type I and Type II forms of acetabulum because of the anatomical variation and distortion. In this article the successful placement of uncemented acetabular cup in the native acetabulum by novel Protrusio method is discussed^[2].

Materials and Methods

This is a prospective study carried out in a tertiary care centre analyzing the functional and radiological outcomes of Total Hip Arthroplasty in cases of hip joint arthritis in patients with developmental dysplasia of hip where the uncemented acetabular cup was positioned using the medial protrusion technique. The study was carried out from 2015 to 2020 in a single institute and all the surgeries were carried out by a single surgeon at one institute.

Inclusion criteria

1. Skeletally mature patients
2. Patients with clinical and radiological hip arthritis in developmental dysplasia of hip
3. Patients who have given consent for surgery

Exclusion criteria

1. Skeletally immature patients

2. Previously operated patients

All patients were clinically examined by two senior orthopedic surgeons with experience in hip arthroplasty and all clinical findings were noted including deformity, range of motion and degree of rotation. All patients were subjected to routine pelvis AP and lateral x-ray views and were followed up by a CT scan of the pelvis to further delineate the anatomy of the hip joint. All routine investigations needed for surgery was carried out. The index diagnosis in all the patients was hip arthritis secondary to DDH. After getting the anesthesia fitness, the patients underwent Total Hip Arthroplasty successfully under epidural and spinal anesthesia.

At initial evaluation all of the patients were assessed for hip arthritis and functional restriction clinically. All the patients were given the same medical treatment initially which included NSAIDS thrice a day for 2 weeks and assisted physiotherapy. Even after medical treatment the patients continued to have pain with restriction of activities of daily living. The patients were counseled and they gave consent for undergoing total hip arthroplasty. The indication for surgery was hip pain, failure of conservative management.

All the patients underwent a CT scan to assess the status of the medial wall for adequate depth. All the patients underwent evaluation by the primary surgeon and the Harris hip score was evaluated pre operatively and post operatively at 1 year follow up. Functional information that was assessed addressed the following: presence of hip pain, presence of a limp, use of ambulation support, ability to use stairs, ability to put on shoes and socks, ability of sitting, ability to use public transportation, number of blocks the patient was able to walk. Our post operative protocol of rehabilitation was in the order of Non-weight bearing mobilization for 3 months with the help of four point walker, Quadriceps strengthening exercises done by the bedside this followed by gradual weight bearing after 3 months.

Postoperatively, all patients were placed on appropriate deep venous thromboembolism prophylaxis according to our institution protocol and underwent standard physical therapy protocols and hip precautions. All patients were placed on non weight-bearing restrictions initially for two weeks and gradually progressed to toe touch walking. At every follow up functional evaluation and radiographic assessment was done. The follow ups were, for the most part, 4 weeks postoperatively, 6 to 8 weeks postoperatively, 3 months postoperatively, 6 months postoperatively, 9 months postoperatively, 1 year postoperatively and annually thereafter.

Their functional outcome was assessed using the Harris hip score and periodic x rays were taken at each follow up to ascertain the implant position, to assess for any signs of implant loosening or any other abnormality related to in situ implant.

A standard anteroposterior radiograph of the pelvis and lateral radiographs of the hip at the most recent follow-up were reviewed. Acetabular cup bony ingrowth was evaluated by bony apposition of the cup and the absence of significant radiolucencies at the cup bone interface.

Any radiolucent line was recorded. If there was a complete radiolucent line around the acetabular component and the radiolucent line width was 2 mm or greater, the hip was deemed loose, as described by Dorr^[10]. All the radiographs were reviewed by an author who was blinded to the clinical results and recorded the measurements.

Surgical Technique

Anaesthesia: Epidural and Spinal Anesthesia

Position: Lateral decubitus Position

Approach: Posterior Kocher Langenbeck approach of the hip (3).

Surgical method

Skin incision of around 15 cm given centering over the greater trochanter. Skin subcutaneous tissue dissected and the tensor fascia lata is identified and is incised over the lower part of the incision. Dissection extends proximally along the anterior border of gluteus maximus. The gluteus maximus muscle is split along the avascular plane. A partial release of gluteal sling is made to help in anterior retraction of muscle belly. The short external rotators are identified and released after tagging. The hip joint capsule is identified and capsular incision is given. The femoral head is identified within the socket of the acetabulum. Acetabular cavity is exposed. Transverse Acetabular Ligament is identified and the hip is dislocated. Acetabular cavity is shallow and oblong antero-posteriorly (usual contour is spherical). Also the corresponding osteotomised head size is also oblong as opposed to normal spherical size.

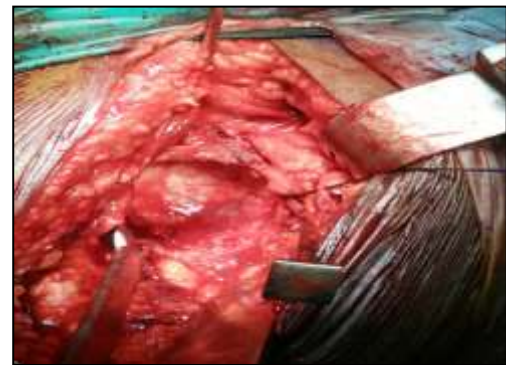


Fig 1: Ovoid' shaped acetabular cavity in ddh as compared to the normal spherical cavity

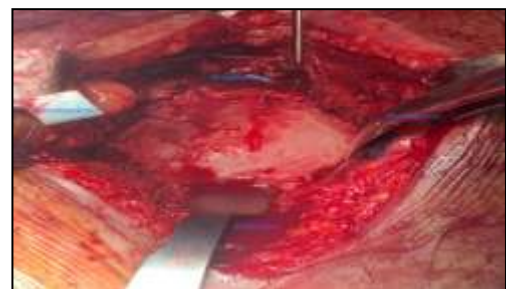

Fig 2: acetabulum end on view showing the ovoid acetabulum

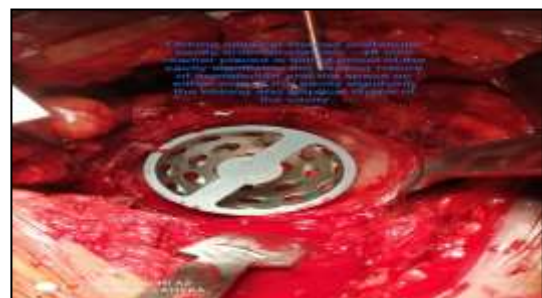


Fig 3: Placement of acetabular cup using the 'medial protrusion technique'. There is complete coverage of the cup with no necessity for any bone graft

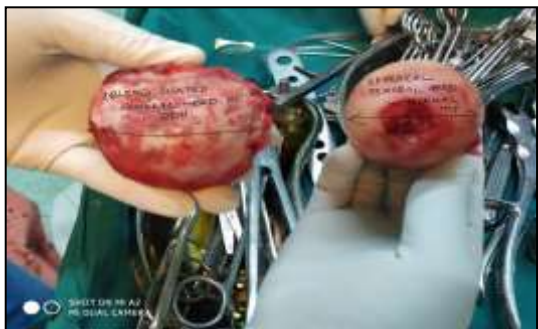

Fig 4: The femoral head which is distorted and oblong shaped- from a patient with DDH as compared to a normal spherical femoral head on the right side.

Deepening of Acetabular cavity – “Protrusio technique” Surgical Steps

At first with smallest size reamer in appropriate version and inclination, the Acetabular cavity is deepened carefully (ream-stop-assess the medial wall and then ream-stop technique) till the medial most wall is reached (not necessary to breach the periosteum). Then with serial reaming the cavity is enlarged and when we get the tight fit with the reamer – trial implantation of acetabular component is done. Once the cup fit and inclination is satisfactory and aligned, the original cup with appropriate version and inclination is inserted and mostly press fit can be obtained with good bony coverage on all sides. (Direction of reaming is also very important as the acetabular wall in anterior aspect of DDH hip is thin so ream in such a way not to breach the anterior wall). The acetabulum is further stabilized with two cancellous screws and then the highly cross linked polymer acetabular liner is inserted. Then femur is prepared for the trial stem insertion and after trial implantation the stability, the anteverision and combined anteversion are checked. The final femoral stem is seated into position and the joint is reduced with excellent stability. After final closure with a negative suction drain the total blood loss is calculated. The average surgery time for this procedure was 2.30 hours (150 minutes). In our patients

acetabulum was deepened by protrusio technique with press fit stability of acetabular cup without the need for any bone graft as the cup is having coverage 180 degree with native acetabulum with no cup uncoverage.

Results

A total of 10 patients who satisfied the inclusion criteria underwent total hip arthroplasty for chronic secondary hip osteoarthritis due to DDH. In all the six patients the acetabular component was placed using the medial protrusio technique. The age group of the included patients was in the range of 31 – 59 years with the youngest hip to be operated was 31 years of age. There were a total of 7 male patients and 3 female patients all of whom were medically fit for surgery and with no other congenital abnormalities.

Six patients had a type 3 hip and four patients had a type 2 hip according to Crowe’s classification for DDH. The average surgery time is 2.5 hours. In all the six patients the acetabular cavity was found to be shallow and ovoid as expected and evident in the CT scans. All the patients underwent total hip arthroplasty with acetabular cup placement with protrusion technique as described earlier. The acetabular cups used were from Depuy –Synthesis. All the acetabular cups had complete press fit with excellent stability. The cup coverage was good and snug fit and hence there was no need of bone grafting in any of the operated cases for cup placement.

There were 7 men (7 hips) and 3 women (3 hips). The mean follow-up was 5.5 ± 1.3 years (range, 1-5 years). Of the 10 patients (6 hips), one patient was lost to follow-up and not available for 2-year postoperative assessment. A review of these patients' clinical notes demonstrated that they were doing well overall at the last follow-up.

Of the original 10 patients (10 hips), 9 patients (90%) were available for complete follow-up. The mean Harris hip score in these patients was 86.5 ± 1.4 (range, 82- 91). A score above 90 is considered excellent, and a score above 80 is considered good. Two patients out of 10 patients had excellent results, while 8 patients were rated as having good results.

Table 1: Patient Characteristics

CASE no.	Crowe type	Age/sex	Side	Protrusio technique	Bone graft for superior coverage	Pre op Harris score	Post op Harris score at 1year
1.	Type 3	59/M	Right side	Yes	No	47	82
2.	Type 3	38/M	Right side	Yes	No	49	84
3.	Type 2	42/M	Left side	Yes	No	44	87
4.	Type 3	32/M	Left side	Yes	No	45	86
5.	Type 2	40/F	Left side	Yes	No	48	85
6.	Type 3	51/F	Left side	Yes	No	48	85
7.	Type 3	44/M	Right side	Yes	No	45	88
8.	Type 2	41/F	Right side	Yes	No	47	86
9.	Type 2	40/M	Right side	Yes	No	47	90
10.	Type 3	39/M	Left side	Yes	No	45	91

The average pain score was 41.6 (range, 20-44). Higher the score, less the pain. Four of the ten patients denied hip pain. No patient complained of marked/severe pain or totally disabling pain. Seven of the ten patients did not have a limp. There were no patients who demonstrated a severe limp. The mean limp score was 9.3 (range, 5-11). At final follow-up, 6 patients were able to walk unlimited distance and no patient was confined to a bed or chair.

Radiographs were obtained in all the patients available for full

follow-up. The x-rays demonstrated good overall alignment and fixation and to ascertain the implant position. All cups were integrated well. Only one patient x-ray showed a radiolucent line in one zone of size 1mm. There was only one post op complication reported in the case series which was a postoperative ileus resolved with medical treatment. There were no cases of surgical site infections or late deep wound infections. There were no cases of post operative dislocation and none of the cups had to be revised again.

Table 2: Harris Hip Score at Final Evaluation

	Excellent (>90 points)	Good (80-90 points)	Fair (70-80 points)	Poor (less than 70 points)	Total no of patients
No. of patients	2	8	0	0	10
Mean Harris hip score	86.5				

Table 3: Pain Score At Final Follow Up

	NO Hip pain (44points)	Mild hip pain (40 points)	Moderate hip pain (30 points)	Severe pain (20 points)	Marked pain (10 points)	Disabling pain (90 points)	Total no of patients
No. of patients	4	6	0	0		0	10
Mean Pain score	41.6						

Case illustrations

Case 1

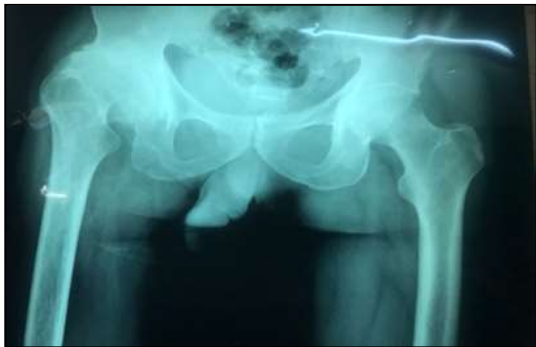

Fig 5: CASE 1. pre op xray showing rt hip arthritis with high hip centre

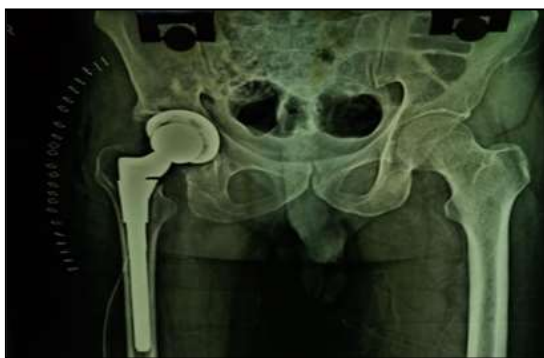

Fig 6: CASE 1- post op xray showing perfect hi centre and adequate medial wall with no bone graft

Case 2

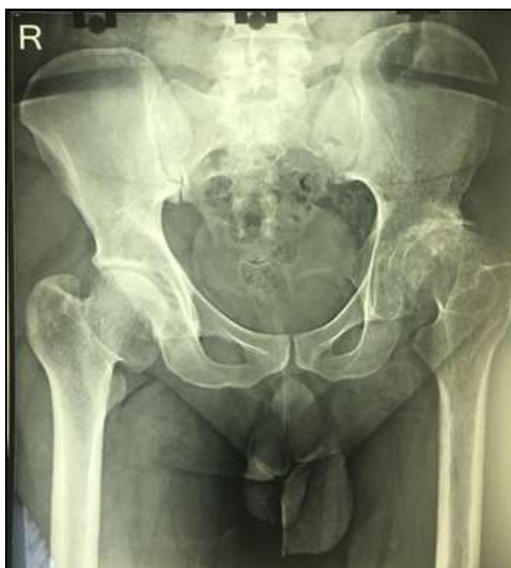

Fig 7: Case 2 - Showing A Type 3 Crowe Hip

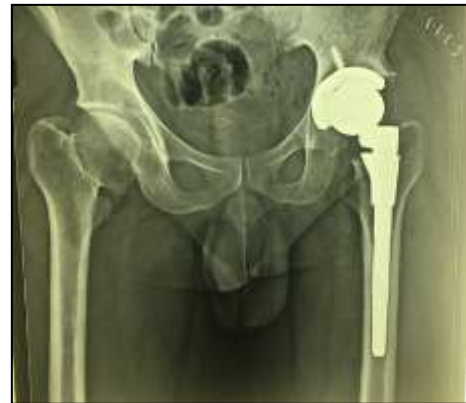

Fig 8: Case 3 Post Op Case Left Thr Done With Perfect Acetabular Cup Placement

Case 3

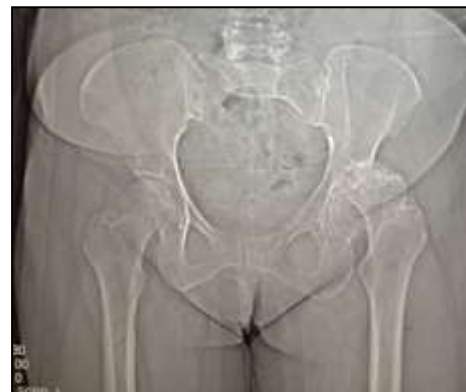

Fig 9: CASE 3 – Pre-op Type 3 Crowe Hip

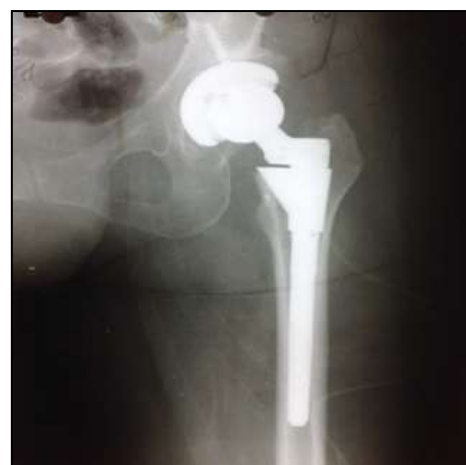

Fig 10: Post Op Case with Good Acetabular Coverage

Discussion

Dunn and Hess were the first authors to describe the medial protrusion technique in their work on the treatment of

degenerative joint disease secondary to congenital hip dysplasia [2]. The challenges especially with Type I and Type II DDH is the acetabulum is shallow, oblong and real challenge is placement of the acetabulum cup in native hip with good press fit. Use of a cementless cup in total hip arthroplasty necessitates adequate bone cup coverage to permit bony ingrowth and adequate stability [2]. In the medial protrusion technique the cup is placed medial to Kohler's line to achieve bony contact [3].

Where there is a deficient bone stock or lack of adequate bony coverage structural bone grafting has been used to facilitate long term fixation of the implant. The indications for structural grafting are a deficient acetabular rim that will not provide adequate support or stability to an uncemented component [4]. The long-term survival of the graft and the revision component is largely dependent on the incorporation and revascularization. The use of structural grafts on acetabulum has decreased because of late biologic failures and technical difficulties have made surgeons give a second thought to pursue alternatives [4].

During surgery tackling the problem of rim-deficient acetabulum has always been difficult even for the experienced surgeon. The medial protrusion technique has the advantage of incorporating a press fit bone cup contact with adequate coverage and stability thereby eliminating the need for a structural bone graft. This technique drives the surgery from a complicated to a less complicated surgery and also shortening the surgical duration [5]. The main objective of the medial protrusion technique is to medialize the center of rotation of the hip joint. This in turn decreases the abductor lever arm and the moment of the center of gravity of the body acting on the hip joint. This, results in a decrease in the resultant force required to support the body in single leg stance. Charnley [6] advocated medial placement of the cup to decrease forces acting on the hip joint in an attempt to decrease polyethylene wear.

Added advantage with this technique is that there occurs a change in the vector of pull of the abductors. The long term implication of this on the hip biomechanics seems unclear but there is a decrease in incidence of post operative dislocation and polyethylene wear associated problems.

This surgical technique provides the choice of implanting the acetabular cup without bone cement and avoids the need for a structural bone graft. The basic principle of this technique is overreaming of the native acetabular shell beyond the Kohler's line to achieve adequate cup coverage and improved stability [7]. Two processes go in hand using this technique, mainly improved stability of the acetabular cup and improved surface area contact of the porous acetabular shell with the native acetabular bone. This finally results in a good stable hip with good bony integration of the implant [8].

Various techniques [7] for acetabular reconstruction is mentioned such as

1. Standard metal augments (prefabricated)
2. Custom made acetabular augments (3D printing)
3. Roof reconstruction with vascularized fibula
4. Roof reconstruction with pedicled iliac graft
5. Roof reconstruction with autologous bone graft
6. Roof reconstruction with homologous bone graft
7. Roof reconstruction with auto/homologous spongy bone
8. Reinforcement ring with the hook in combination with autologous graft augmentation
9. Cranial positioning of the acetabulum
10. Medial protrusion technique (cotyloplasty) with chisel

11. Medial protrusion technique (cotyloplasty) with reaming
Cotyloplasty without spongioplasty.

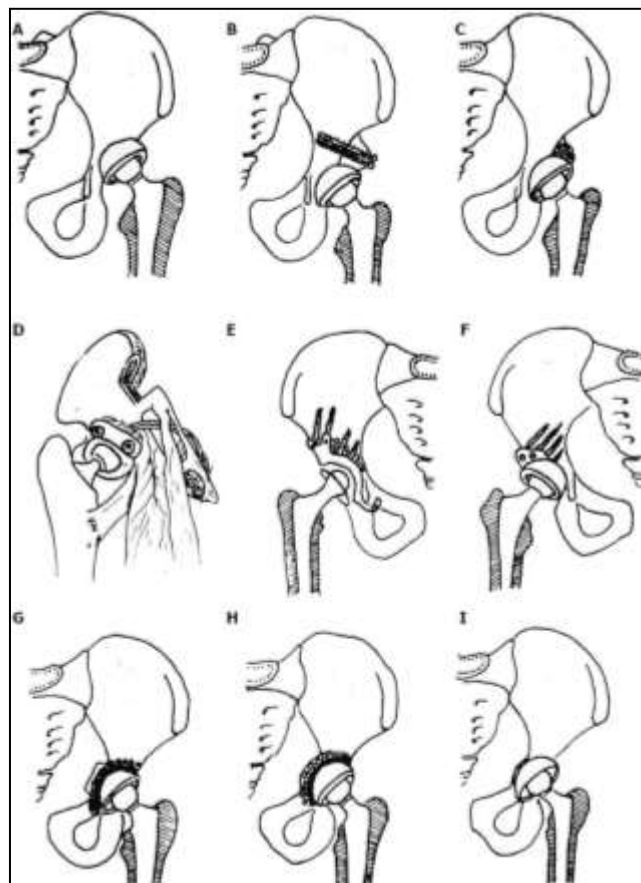


Fig 11: Different positions of acetabular cup placement in THA

Different options for acetabular reconstruction.

- a) Higher placement of the acetabular cup;
- b) Placement of the acetabular component in the anatomical position and augmentation of the superior segmental defect with structural autograft or allograft fixed with screws;
- c) Placement of the acetabular component in the anatomical position and spongioplasty of the acetabular roof for smaller uncovered areas (30%-40%);
- d) Anatomical position of acetabular cup and augmentation of the superior segmental defect with vascularised iliac graft;
- e) Reinforcement ring with the hook in combination with autologous graft augmentation for cases with severe bone-stock deficiencies. Anatomic hip centre is reconstructed by positioning the hook around the inferior margin of the acetabular floor. The hook prevents high or lateral placement of the ring and helps adequate coverage of the polyethylene liner, regardless of the degree of anatomical deformity;
- f) Acetabular bone stock deficiency can be managed with specially constructed acetabular components or using special 3-dimensional porous materials which simulates bone structure and allow faster and better endoprosthesis-bone integration. For that purpose trabecular metal (tantalum) is used in form of acetabular cup or trabecular metal augments. Oblong-shaped cementless implants can be used for acetabular reconstruction;
- g) Cotyloplasty with chisel - intentional medial wall fracture using osteotome with cup placement beyond the ilioischial line with bone grafting;

- h) Cotyloplasty with reamer - first, perforation of the medial acetabular wall with a reamer is performed, then acetabulum is filled with a large amount of autogenous cancellous bone graft and cup is cemented in position without pressure;
- i) Cotyloplasty without spongionasty - implantation of porous-coated cementless acetabular components without spongionasty.

Hess^[5] and Umber and Hartofilakidis *et al.*^[7] showed success with medial wall violation beyond the Kohler's line-87 and fixation of a Charnley cup with cement. Dorr^[2] in his study on 139 porous-coated revision acetabular components, in 26 hips the cup was placed through the medial wall through the medial protrusion technique. Follow-up of these averaged 3.8 years, and the overall Harris hip score was 87.6 points. They concluded that the medial protrusion technique is a good technique to facilitate rim fixation of the acetabular cup. Dorr^[2] also studied this technique in patients with acetabular dysplasia without cement and reported successful outcomes. The results of the study by Dorr *et al.* corroborate with the results of our study. Our study had very similar results with 10 hips having a mean Harris hip score of 86.5 points with an average follow up of 5.5 years.

One of the disadvantages of placement of a cemented acetabular cup using the medial protrusion technique created high peak stresses in the cement mantle and was avoided^[8]. The technique of undereaming the acetabulum is carried out in placing the uncemented cup because the major stresses are distributed peripherally in the rim and not concentrated in the dome. Finite element analysis shows that the medial acetabulum actually has minimal stress when press fit is achieved as evident in the medial protrusion technique^[8].

Our results demonstrate that the medial protrusion technique is a viable option in acetabular cup placement in THA of DDH cases. Our study expands on the results exhibited by Dorr *et al.*^[2], it eliminates the need for structural bone graft, as well as cement, because the use of each poses its own complications.

Like any technique this method also has its disadvantages. The major complications associated with overreaming are intrapelvic vessel complications, urogenital tract complications, nervous system complications, and intrapelvic mass formation. The external iliac artery and vein, internal iliac artery and vein, obturator vessels and nerve, ureter, deferent duct, and the superior umbilical artery are the structure in close proximity to the medial wall which are at risk structures^[9].

McQueary and Johnston^[10] recommended medialization of the femoral head approximately 25 mm. Dorr *et al.*^[2] stated that for ideal fixation of the cup perforation of no more than 25% of the acetabular area. Because of the close proximity of vital intrapelvic structures, reaming should be limited to no more than a few millimeters. Ideally the surgeon's goal should be to protect the internal layer of the medial wall periosteum. For proper application of this technique, the reaming of the medial wall should be carried out with utmost attention and without any haste taking care not to breach the internal layer of the periosteum.

THA in patients with DDH is a complex procedure that requires an understanding of the complex acetabular and proximal femoral anatomy of each patient. The complex anatomy dictates what surgical techniques are necessary to create a mechanically stable and functional outcome.

Conclusion

The Medial Protusio technique of acetabular cup placement in DDH patients is a time proven technique requiring less technical expertise. It provides for good acetabular component placement and stability even in the hands of an inexperienced surgeon. By medial protrusion technique the acetabular cup is safely seated with the native acetabulum with good coverage and fit.

Funding: No funding sources

Conflict of interest: None declared

References

1. Current concept in dysplastic hip arthroplasty: Techniques for acetabular and femoral reconstruction Goran Bicanic, Katarina Barbaric, Ivan Bohacek, Ana Aljinovic, Domagoj Delimar *World J Orthop.* Sep 18 2014;5(4):412-424
2. Dorr, Lawrence MD† D, Tawakkol Samer MD†, Moorthy Murali MD†, Long William MD†, Wan Zhinian MD†. Los Angeles California Medial Protrusion Technique for Placement of a Porous-Coated, Hemispherical Acetabular Component without Cement in a Total Hip Arthroplasty in Patients Who Have Acetabular Dysplasia*, *JBJS: January 1999;81(1):83-92.*
3. *JBJS Essent Surg Tech.* 2018 Jun 13;8(2):e18. doi: 10.2106/JBJS.ST.16.00102. eCollection, 2018, 27. PMID: 30233990
4. Hartofilakidis G, Karachalios T, Georgiades G, Kourlaba G. Total hip arthroplasty in patients with high dislocation: a concise follow-up, at a minimum of fifteen years, of previous reports. *J Bone Joint Surg Am* 2011;93:1614-1618.
5. Harris WH, Crothers O, Oh I. Total hip replacement and femoral-head bone-grafting for severe acetabular deficiency in adults. *J Bone Joint Surg Am* 1977;59:752-759. [PubMed]
6. Charnley J. Low friction arthroplasty of the hip: theory and practice. Berlin, Germany: Springer-Verlag 1979.
7. Hartofilakidis G, Georgiades G, Babis GC, Yiannakopoulos CK. Evaluation of two surgical techniques for acetabular reconstruction in total hip replacement for congenital hip disease: results after a minimum ten-year follow-up. *J Bone Joint Surg Br* 2008;90:724-730.
8. Crowninshield RD. A stress analysis of acetabular reconstruction in protrusion acetabuli. *J Bone and Joint Surg* 1983, 65.
9. Fabi D, Gonzalez M, Goldstein W, Ahmed M. Acetabular cup revision with the use of the medial protrusion technique at an average follow-up of 6.6 years *J Arthroplasty.* 2010;25(2):197-202. doi:10.1016/j.arth.2009.01.019
10. Johnston RC. Reconstruction of the hip. A mathematical approach to determine optimum geometric relationships. *J Bone and Joint Surg* 1979, 61.