

E-ISSN: 2395-1958
P-ISSN: 2706-6630
IJOS 2021; 7(1): 22-27
© 2021 IJOS
www.orthopaper.com
Received: 05-11-2020
Accepted: 21-12-2020

Dr. Ravish VN
Principle Investigator, Kempegowda Institute of Medical Science, Bangalore, Karnataka, India

Dr. Bharat Raju
Principle Investigator, Kempegowda Institute of Medical Science, Bangalore, Karnataka, India

Dr. Ram Khemka
Co-investigator, Kempegowda Institute of Medical Science, Bangalore, Karnataka, India

Corresponding Author:
Dr. Ram Khemka
Co-investigator, Kempegowda Institute of Medical Science, Bangalore, Karnataka, India

Primary union with external fix in open both bone leg fracture as definitive management

Dr. Ravish VN, Dr. Bharat Raju and Dr. Ram Khemka

DOI: https://doi.org/10.22271/ortho.2021.v7.i1a.2455

Abstract
These days RTA and violence are on the rise and accounting for more cases of trauma in which bony injuries are common. Fracture of the tibial shaft is due to its subcutaneous location is very often involved in this kind of injuries. This study was done to evaluate the effectiveness of an external fixator as a primary and definitive treatment for open tibia fractures, fractures with severe soft tissues injuries, threatened compartment syndrome, and in multiply injured patients [1].
Intramedullary nailing is considered the method of choice for the treatment of closed diaphyseal fractures of long bones. However, there is controversy in the literature regarding the best way of managing open type II and type III fractures, tibial shaft fractures with severe soft tissue injuries or compartment syndrome, multiply injured patients.
Material and Methods: A total of 16 patients who satisfied our inclusion and exclusion criteria were taken and were treated with AO external fixator as primary or secondary to failed Intramedullary nailing. Patients were assessed radiologically and clinically.
Results: as per the clinical parameters of Karlstrom and Olerud, 37% of patients had excellent outcomes, 31% had a good outcome, 18% had fair outcomes and 12% had a poor outcomes.
Conclusion: Meticulously, primary wound debridement at the earliest is an absolute. Which augments prognosis and prevents complications. An external fixator is now an accepted, reliable and convenient method to manage open Long Bones fracture.

Keywords: Primary union, open bothbone, RTA

Introduction
Diaphyseal tibial fractures are the most common long bone fracture. There are a variety of treatment options, both operative and non-operative, and satisfactory outcomes are reliant on a thorough understanding of the strengths and weaknesses of the different treatment modalities, and their most useful applications. Compartment syndrome can be a devastating complication and must be kept in mind at all times. Insufficient blood flow and lack of soft tissues in the antero-medial aspect of tibia length predisposes tibia open fracture to non-union and development of infection. Treatment of open tibial fractures has controversy among the orthopedics surgeons. Currently, non-surgical procedures like using casts, braces or interventional attempts like inserting of the plate, intramedullary nailing and external fixators are used for the treatment of open tibial fractures. The selection of any of the above methods are correlated with surgeon decision and the economic status of patients. Intramedullary nailing is considered the method of choice for the treatment of closed fractures of long bones. However, there is controversy in the literature regarding the best way of managing open type IIIa and type IIIb fractures, tibial shaft fractures with severe soft tissue injuries or compartment syndrome, and tibial fractures in multiply injured patients. Primary IM nailing, primary external fixation followed by conversion to IM nailing, or external fixation as definitive treatment is the ideal surgical management for these types of long bone shaft fractures.An attempt to understand the biomechanics of external fixators and their vast use.
To evaluate the outcome of open long bone fracture in relation to use of external fixator in relation with healing time, hospital stay, types and degree of different complications.

Material and Methods

The fact that open fracture of long bones is usually caused by high-energy trauma makes it imperative to assess both the patient and the fracture as a whole.

Study setting: The study was conducted in the Dept. of Orthopaedics, KIMS Bangalore from (2012-2019).

Subjects: Patient Attending Dept. of Orthopaedics, KIMS Bangalore from (2012-2019).

Study Population: Patients of age 18-60 were considered for the study.

Type of study design: the study was conducted in two parts.in the 1st part of the study, the retrospective data of all the patients of open long bone fractures were collected and analysed. In the 2nd part, we continued the study prospectively, to diagnose, analyse and study the patients coming to the Orthopaedic Department on regular OPD and emergency days.

Sample size: 16 patients (by using non-randomise purposive sampling, we selected 16 patients in the study).

Radiological Method: X-ray reports

Inclusion criteria

1. Failed intramedullary nailing in compound type 2, 3a &3b within 7 days of surgery
2. Primary Gastillo Anderson type 2, 3a and 3b
3. Primary closed fracture with compartment syndrome
4. patients between 18-60 years of age
5. patients unwilling for Ilizarov due to compliance

Exclusion criteria

1. Gustillo Anderson type 1 & type 2 with less soft-tissue involvement
2. Patients below the age of 18, Patients above 60 years of age.
3. Pathological fractures

Consent: Prior to the examination of each patient, consent was taken.

Data collection procedures: All the patients coming to the department of Orthopaedics with complaints of open long bone fracture.

Plan of analysis: All patients who met the inclusion criteria were included in the study. The clinical history of each patient was recorded as per the proforma. Clinical details, including risk factors, complete Haemogram and other biochemical parameters were also recorded. Diagnostic clinical tests were performed on the included patients. After the clinical and radiological diagnosis, patients were subjected to external fix. After the procedure, the patients were followed up for 6-18 months for evaluation.

Statistical analysis: The tabulation and cross-tabulation was done. Results are expressed in percentages. Statistical analysis was performed on the intent-to-treat (ITT) population. For statistical analysis, data were first entered into Microsoft excel database and subsequently processed by standard statistical software: Statistica version 6.

Operative procedure

In the operating room, under spinal anaesthesia and with a tourniquet in situ (where feasible), thorough irrigation and debridement of the wound were done. External fixation and secondary debridement. After aggressive primary wound debridement a decision, in a few cases where soft tissue involvement was extensive, external fixator application was delayed by 48 to 72 hours.

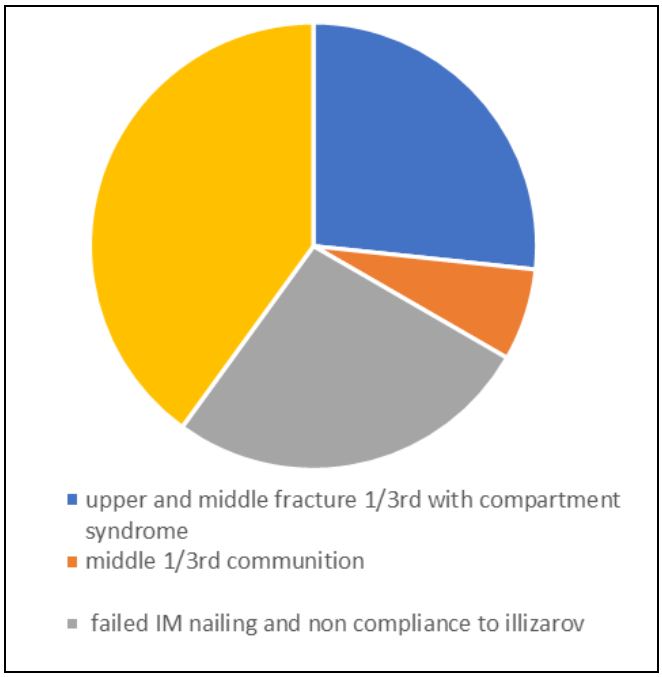

Fig 1: Type of Fractures

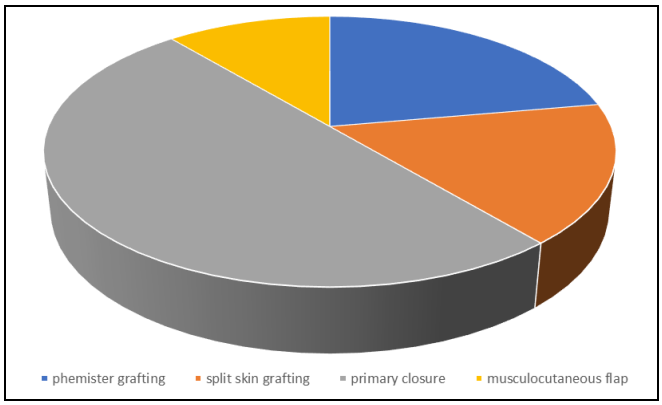

Fig 2: Type of Management

The wound was primarily closed when feasible, with preference given to covering the bones with minimal tension. Dressing of Open wounds was done u at appropriate intervals of 12-24 hours according to need.

Results

In this study, the maximum follow-up was for 18 months and the minimum follow-up was 6 months. The majority of the cases were followed up for 10 months making an average follow-up period of 7.5 months. Definition of parameters in the follow-up examination.

Factors were as follows. Ankle joint symptoms, aching or pain in the fracture site, difficulty in walking, work and sports, skin condition, deformity, muscular atrophy and loss of knee movement. Grading A as negligible or none, B as moderate/mild symptoms, and C as severe loss of function/pain.

Table 1: Symptoms according to the severity

FACTORS	A	B	C
SYMPTOMS			
1. Ankle joint symptoms	None or negligible	Moderate: some loss of function	Severe: clear loss of function
2. Aching or pain in fracture	None or slight on	Moderate symptoms	Severe: pain at rest
3. Difficulty in walking	None	Mild subjective symptoms	Severe limp
4. Work and sports	Activities unchanged	Works as before incapacitated for some sport	Stopped working due to injury

Table 2: Signs according to the severity

FACTORS	A	B	C
SIGNS			
1. Skin condition	Normal	Slightly discoloured	Ulcer or sinus persistent infection
2. Deformity	None	Slight or not noticeable	Considerable shortening > 1 cm
3. Muscular atrophy	0 to 1 cm	1 to 2 cm	> 2 cm
4. Loss of knee movement	0 to < 10 degrees	10 to 20 degrees	> 20 degrees

Overall evaluation of results according to Karlstrom and Olerud:

Excellent: All factors listed in the table were graded A.

Good: All factors listed in the table were graded B.

Acceptable: One factor was graded C and the rest were graded A or B without significant subjective symptoms.

Poor: Here, more than one factor was graded C.

- A total number of cases managed with this modality were 16. Here the majority of the cases were in the 3rd decade, followed by the 4th and 5th decade. Age is of prognostic value following chart shows the gender proportion of the study.

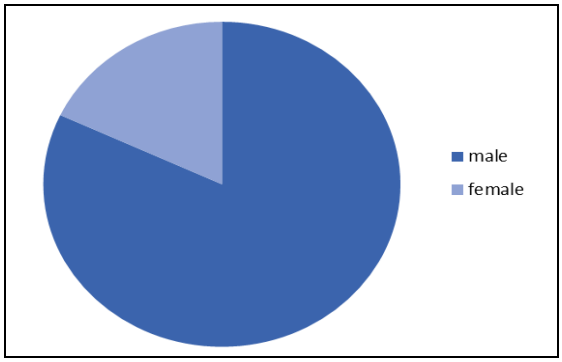

Fig 3: Male is to female ratio

- 75% of cases were Road traffic accidents. 25% were agriculture injuries. 37% of patients had shock, 31% of patients had associated skeletal injury.

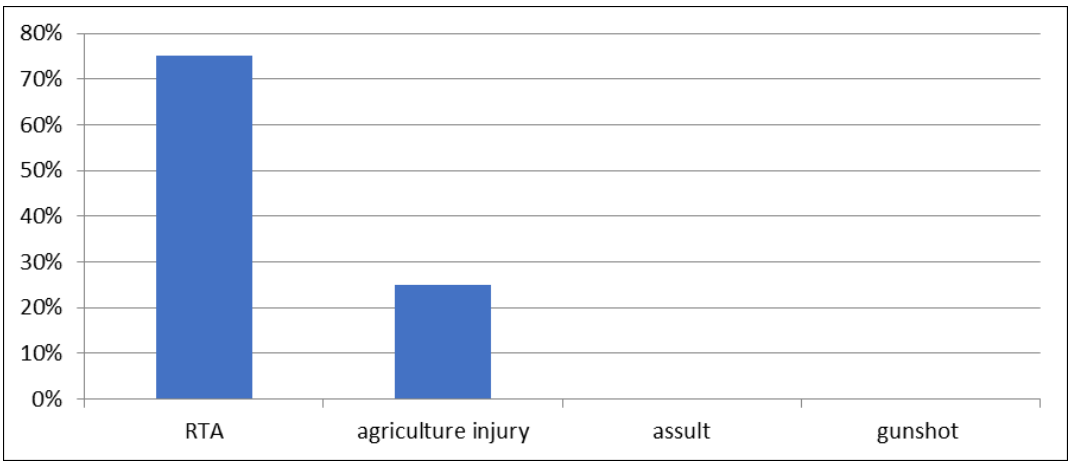

Fig 4: Mode of Injury

- Total type III fractures = 14constituting 90% of the cases.
- In this study, type III fractures are more predominant, which shows that most cases have sustained high-energy trauma.
- 4 patients went for phemister grafting and 3 went for split skin grafting due to compartment syndrome.
- as per the clinical parameters of Karlstrom and Olerud, 37% of patients had excellent outcome, 31% had good outcome, 18% had fair outcome and 12% had a poor outcome

Meticulously primary wound debridement at the earliest is an absolute, which augments prognosis and prevents complications. An external fixator is now an accepted, reliable and convenient method to manage open Long Bones fracture.

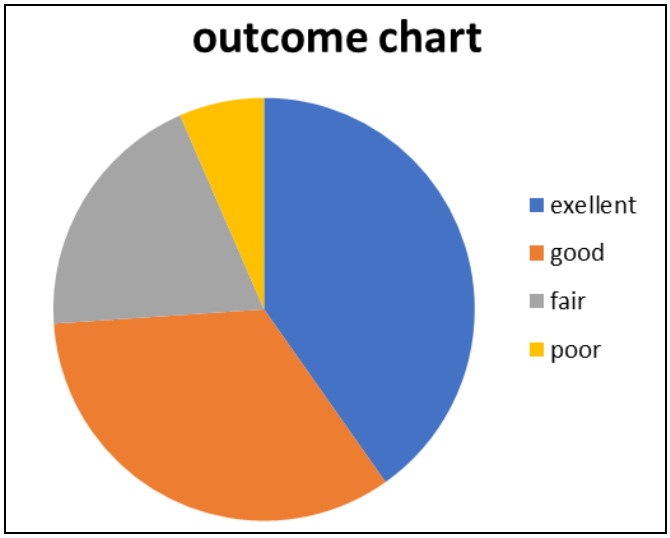

Fig 5: Outcome Chart

Discussion

This study evaluates the result of surgical management of open long bone fractures by using an AO external fixator.

The study consists of 16 cases with ages ranging from 18-60 years.

The incidence of the fracture was more in male, the majority of the patients mode of injury was RTA. The preliminary assessment of the patients reveal the presence of shock in 6 and associated skeletal injuries in 5 patients.

For patients with severe injuries and those in uncertain or critical conditions, general surgeons modified their surgical treatment strategy for multiply injured patients more than a decade ago. A temporizing approach (damage control) was developed to focus on initial hemorrhage control only, followed by definitive care of the lesion once the patient had been stabilized. The clinical course of patients undergoing the temporizing approach has been so convincing that a prospective randomized study has not been required to achieve these management changes.

Image 1: Pre-op X-ray

Image 2: Post-op X-ray

Image 3: Post-op follow up X-ray

Image 4: Follow up X-ray

Image 5: Follow up X-ray

Image 6: Follow up X-ray

Systemic support is beneficial to mitigate inflammatory reactions resulting from ischemic reperfusion, prevent organ complications, and improve the tolerance to surgery [2]. Both necrotic muscle tissues and their catabolic products could activate the endogenous coagulate system and release inflammatory mediators [2]. All patients in this study had wound debridement 2–4 times to remove necrotic tissues. We speculate that these procedures largely contribute to satisfactory clinical outcomes. No systemic inflammatory response, infection or secondary organ damage was found throughout the course of treatment [3].

Operative treatment of the tibial shaft fractures usually leads to healing without any consequences on life and working ability [4]. The most common methods used in treating tibial shaft fractures are intramedullary nail, conventional, AO compression plates and external fixator [5-7]. When a surgeon is to choose an operative method for the treatment of tibial shaft fractures, they have to pay attention not only to the fracture but also to the state of the soft tissue of the injured extremities, including vascular status, muscles, and the state of the cutaneous cover. Attitudes of schools with regard to indications for operative treatment of closed tibial shaft fractures are different. The external fixation is an excellent method for the treatment of not only open, but also closed tibial shaft fractures. Due to its subcutaneous localization, the tibia is often exposed to injury, but subcutaneous localization is very suitable for the external fixation. The external fixation used for treating unstable tibial shaft fractures minimizes the possibility of the appearance of postoperative osteitis. The application of an external fixator enables an almost perfect control of the fracture, owing to the possibility of intraoperative and postoperative fracture reduction. During the healing of the fracture treated with the external fixation method, there is a possibility of adapting the biomechanical condition of healing- dynamization of the external fixator. The external fixation method enables early postoperative rehabilitation and functioning of extremities, reducing the treatment time and providing good results [8]. Shaw *et al.* obtained 100 percent union in a group of 44 closed tibial shaft fractures and open fractures Gustilo type I and Gustilo type II, treated with the external fixation method [9]. Keating *et al.* obtained a 95 percent union rate after the external fixation of 100 tibial shaft fractures (47 closed and 53 open) with the Orthofix external fixator. The same authors had 6 percent nonunion in the same series after the external fixation, 14 percent malunion after the external fixation of closed tibial shaft fractures, and 32 percent malunion after the external fixation of open fractures [5]. The application of the external fixator is simple and does not require any special guidance due to clamps which allow moving along the clamp carrier. The apparatus allows three-dimensional stability simulating natural bone mechanics. The application of the external fixator lasts briefly, there is no blood loss, bone vascularization is minimally aggravated, postoperative hospitalization is short [10].

Conclusion

Open long bone fractures are a common occurrence in high-velocity trauma. Young males in their 3rd decade are commonly affected due to their active ambulant lifestyle. Meticulously, primary wound debridement at the earliest is an absolute. Which augments prognosis and prevents complications. An external fixator is now an accepted, reliable and convenient method to manage open Long Bones fracture.

Early and active mobilization of joints prevents deformities and stiffness. Most of the open long bone fractures in our institute were treated with exfix for 6 weeks and then converted to definitive measurement with IM nailing.

But these patients were treated with AO Exfix.

- Due to failed IM nailing within the first 7 days of surgery
- Poor skin and soft tissue conditions
- Poor compliance of the patient for Ilizarov ex fix.
- Poor socioeconomic status.

Note: In our institution, for almost all the compound fractures, we either do primary IMIL nail or 6 weeks Exfix and then conversion to IMIL nail or primary Ilizarov, but this study was conducted in patients who had failed IMIL nail or with noncompliance to Ilizarov and poor socioeconomic status not willing for multiple surgical interventions.

References

1. Beltsios M, Savvidou O, Kovanis J, Alexandropoulos P, Papagelopoulos P. External fixation as a primary and definitive treatment for tibial diaphyseal fractures. Strategies Trauma Limb Reconstr. 2009;4(2):81-7. Doi: 10.1007/s11751-009-0062-3. Epub 2009 Aug 28. PMID: 19714440; PMCID: PMC2746273.
2. Togrul C, Dogan AC, Baser E, Dogan M, Albayrak A, Caglar M *et al*. The effects of sildenafil and tadalafil on ischemia-reperfusion injury in rat ovarian torsion model. Clin Exp Obstet Gynecol. 2017;44:535-539.
3. Reverte MM, Dimitriou R, Kanakaris NK, Giannoudis PV. What is the effect of compartment syndrome and fasciotomies on fracture healing in tibial fractures?. Injury. 2011;42(12):1402-7.
4. Trafton PG. Closed unstable fractures of the tibia. Clin Orthop 1988;230:58-67.
5. Keating JF, Gardner E, Leach WJ, Macpherson S, Abrami G. Management of tibial fractures with the orthofix dynamic external fixator. J R Coll Surg Edinb 1991;36(4):272-7.
6. Horas U, Popa RB, Kilian O, Stahl JP, Heis C, Schnettler R."Biorigid" interlocking after undreamed intramedullary nailing of tibial shaft fractures. Unfallchirurg 2002;105(9):797-803.
7. Jensen JS, Hansen FW, Johansen J. Tibial shaft fractures. A comparison of conservative treatment and internal fixation with conventional plates or AO compression plates. Acta Orthop Scand 1977;48(2):204-12.
8. Mitkovic M. New concepts in external fixation. Prosveta, Nis, 1993.
9. Shaw DL, Lawton JO. External fixation for tibial fractures: clinical results and cost effectiveness. J R Coll Surg Edinb 1995;40(5):344-6.
10. Mitkovic BM, Bumbasirevic ZM, Lesic A *et al*. Dynamic external fixation of comminuted intraarticular fractures of the distal tibia (type C pilon fractures). Acta Orthop Belg. 2002;68:508-514.