



E-ISSN: 2395-1958  
P-ISSN: 2706-6630  
IJOS 2020; 6(4): 965-968  
© 2020 IJOS  
[www.orthopaper.com](http://www.orthopaper.com)  
Received: 17-08-2020  
Accepted: 26-09-2020

**Dr. Neilakuo Kire**  
Consultant, Department of  
Orthopaedics, NHAK, Kohima,  
Nagaland, India

**Dr. G Thong**  
Head of Orthopaedics  
Department, NHAK, Kohima,  
Nagaland, India

**Dr. V Viiprii**  
Consultant, Department of  
Orthopaedics, NHAK, Kohima,  
Nagaland, India

**Dr. K. Kuotsu**  
Consultant, Department of  
Orthopaedics, NHAK, Kohima,  
Nagaland, India

**Corresponding Author:**  
**Dr. Neilakuo Kire**  
Consultant, Department of  
Orthopaedics, NHAK, Kohima,  
Nagaland, India

## Result of hemiarthroplasty and internal fixation in trochanteric fractures in elderly

**Dr. Neilakuo Kire, Dr. G Thong, Dr. V Viiprii and Dr. K. Kuotsu**

**DOI:** <https://doi.org/10.22271/ortho.2020.v6.i4n.2446>

### Abstract

**Background:** There is no specific protocol as to whether internal fixation or hemiarthroplasty is more appropriate for the treatment of intertrochanteric femur fractures in elderly patients. Hemiarthroplasty offers early mobilization, internal fixation preserves the hip joint and avoids long-term complications associated with the prosthesis.

A large number of patients with trochanteric fractures are admitted in our hospital including those cases referred from peripheral hospitals. Considering the superior infrastructural set up in our hospital in terms of pre-operative planning and rehabilitations, comparative study was conducted between cemented hemiarthroplasty and internal fixations in unstable trochanteric fractures in elderly to dictate a treatment protocol.

**Objective:** To compare the post operative clinical and functional outcome between hemiarthroplasty and internal fixation.

**Method:** 75 patients, all of who were more than 60 years of age, with trochanteric fractures and comminution were treated between 2015 to 2017 (45 women, 30 men; 50 hemiarthroplasty, 25 internal fixation). 22 of 25 patients in the internal fixation group (G1) and 41 of 50 patients in the hemiarthroplasty group (G2) were alive at the final follow-up. The mean follow up was at 10+/-3 months. In both the groups the post operative ambulation capacity were assessed according to Clawson classification and complications related to implant were evaluated with radiographic examination.

**Results:** At the end of the follow up clinical comparison in both the groups were done through the ambulatory capacity which were found more to be in class 4 with G2 according to Clawson classification.

**Conclusion:** Primary cemented hemiarthroplasty as a treatment for unstable trochanteric fractures is a viable option for the elderly population. It results in early mobilization which avoids the hazards of prolonged inactivity and prevents implant failure due to osteoporosis.

**Keywords:** Trochanteric fractures, hemiarthroplasty, internal fixation, osteoporosis, elderly

### Introduction

Trochanteric fractures are one of the most common causes of high morbidity and mortality in elderly patients. Before the introduction of suitable fixation devices in the 1960s, treatment for trochanteric fractures was essentially non-operative, consisting of prolonged bed rest in traction until fracture healing occurred (usually 10 to 12 weeks), followed by a lengthy program of ambulation training [1]. Conservative treatments were seen to have a high complication rate with typical problems including decubiti, urinary tract infection, joint contractures, pneumonia, and thromboembolic complications, resulting in a high mortality rate [1]. Operative management consisting of fracture reduction and stabilization, which permits early patient mobilization and minimizes any of the complications of prolonged bed rest, has consequently become the treatment of choice for trochanteric fractures [2]. Most of the treatment methods of osteosynthesis in trochanteric fractures in elderly patients with gross comminution along with osteoporosis does not provide fracture stability and bony union, leading to complications like non union, implant failure and femoral head perforation [2, 3].

A large number of patients with trochanteric fractures are admitted in our hospital including those cases referred from peripheral hospitals. Considering the superior infrastructural set up in our hospital in terms of pre-operative planning and rehabilitations, comparative study was conducted between cemented hemiarthroplasty and internal fixations in unstable trochanteric

fractures in elderly over the course of 24 months (2015-2017), to dictate a treatment protocol.

**Patients and methods**

After Ethical approval and patient informed consent was taken. The proposed study was conducted in the Department of Orthopaedics, Naga Hospital Authority Kohima.

75 patients, all of who were more than 60 years of age, with trochanteric fractures and comminution were treated between 2015 to 2017 (45 women, 30 men; 50 hemiarthroplasty, 25 internal fixation). 22 of 25 patients in the internal fixation group (G1) and 41 of 50 patients in the hemiarthroplasty group (G2) were alive at the final follow-up. The mean follow up was at 10+/-3 months.

In this study, the patients treated with hemiarthroplasty or internal fixation, post operative ambulation capacity were assessed according to Clawson classification and complications related to implant were evaluated with radiographic examination.

**Procedure**

Total of 75 patients, all of who were more than 60 years of age, with trochanteric fractures and comminution were treated between 2015 to 2017 (45 women, 30 men; 50 hemiarthroplasty, 25 internal fixation).

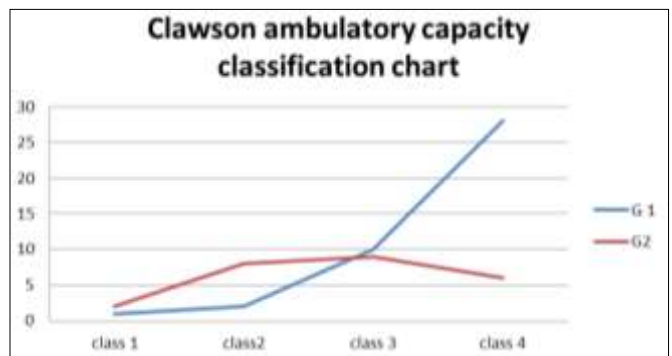
Cemented bipolar prosthesis through standard posterior approach for hemiarthroplasty and contra-lateral distal

femoral locking plate through lateral approach was used for internal fixation. Using Clawson classification as the ambulatory capacity for post operated patients in both groups were assessed.

**Table 1:** Clawson classification

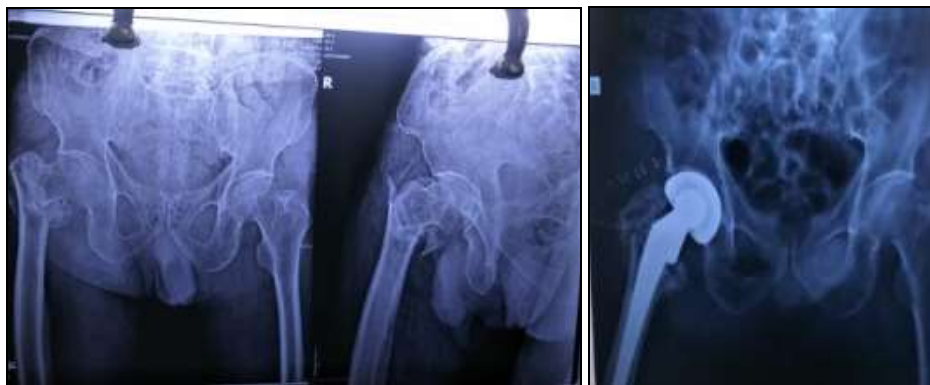Class 1	Wheelchair ambulation
Class 2	Crutch, two cane
Class 3	One cane or simple brace
Class 4	Self ambulation

**Table 2:** Data of postop function in from both the groups at the end of final follow-up

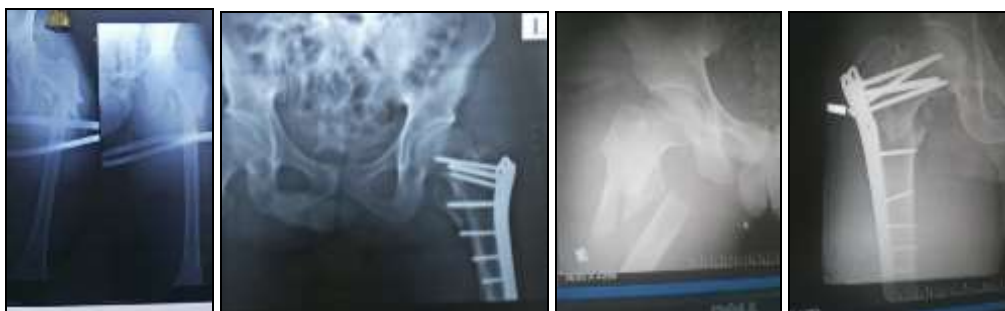

G1- Hemiarthroplasty group (41 patients)

G2- internal fixation group (22 patients)



**Fig 1:** Pre and post op bipolar hemiarthroplasty



**Fig 2:** Pre and post op internal fixation

With 41 patients from G1 at final follow up, 28 patients were class 4, 10 patients were class 3, 2 patients were class 2 and 1 patients was class1.

Whereas 22 patients from G2, 6 patients were class 4, 8 patients were class 3, 7 patients were class 3 and 1 patients was class 1.

With the different number of patients compared in both the groups through the ambulatory capacity more were found to be in class 4 with G2 according to Clawson classification.

**Discussion**

In elderly patients, conservative approach was associated with high complication rates; typical problems included decubiti, urinary tract infection, joint contractures, pneumonia, and thromboembolic complications, resulting in a high mortality rate. Techniques of operative fixation have changed dramatically since the 1960s. and the problems associated with early fixation devices have largely been overcome. Operative management consisting of fracture reduction and

stabilization, which permits early patient mobilization and minimizes many of the complications of prolonged bed rest, has consequently become the treatment of choice for intertrochanteric fractures [3].

Although it is unnecessary to review each and every type of implant that has been used to stabilize intertrochanteric fractures unstable intertrochanteric (Evans type II or IV and AO/OTA type 31-A2.2 and 2.3), it is important to understand the principles behind their evolution. Stable fractures can be easily treated with osteosynthesis with predictable results. The first successful implants was fixed-angle nail plate devices (e.g., Jewett nail, Holt nail) consisting of a triflanged nail fixed to a plate at an angle of 130 to 150 degrees [1]. While these devices provided stabilization of the femoral head and neck fragment to the femoral shaft, they did not allow fracture impaction. If significant impaction of the fracture site occurred, the implant would either penetrate into the hip joint or cut-out through the superior portion of the femoral head and neck. If, on the other hand, no impaction occurred, lack of bony contact could result in either plate breakage or separation of the plate and screws from the femoral shaft. These complications occurred much more frequently when these devices were used to treat unstable fractures [3].

Excessive collapse, loss of fixation and cut-out of the lag screw resulting in poor function remains problems associated with internal fixation of unstable intrtrochanteric fractures in elderly with osteoporotic bone. To allow early post operative weight-bearing and to avoid excessive collapse at the fracture site, some surgeons have recommended prosthetic replacement for the treatment of unstable intertrochanteric fractures [4].

Haentjens et al. reported a prospective series comparing 37 consecutive patients older than 75 years of age who were managed by either bipolar arthroplasty or internal fixation. They concluded that the arthroplasty group had an easier and faster rehabilitation, with a lower incidence of pressure sores, pulmonary infection, and atelectasis, which they attributed to earlier return to full weightbearing. A 5% dislocation rate was noted in the arthroplasty group [5].

Harwin et al. reported on fifty-eight elderly patients with osteoporosis in whom a comminuted intertrochanteric femoral fracture had been treated with a bipolar Bateman-Leinbach prosthesis and who were followed for an average of twenty-eight months. The average patient age was seventy-eight years, and 91% walked prior to discharge. Two patients had a nonunion of the greater trochanter. There were no deep infections, dislocations, acetabular erosions, or cases of stem loosening [6].

Broos et al. reported on ninety-four elderly patients treated with a bipolar Vandeputte prosthesis. They found that the average operating time was shorter, the mortality rate was lower, and the functional results were better in the group treated with the bipolar hemiarthroplasty than in groups treated with Ender nailing, an angled blade-plate, or a dynamic hip screw [7].

Early postoperative full weight bearing in the hemiarthroplasty group compared with early partial or non-weightbearing in the internal fixation group was the main reason for significant reduction in postoperative complications such as pressure sores and pulmonary complications [8, 9, 10]. In addition, calcar reconstruction had the potential advantage of improved trochanteric healing, restoration of bone stock, re-establishment of proper limb length and reduced implant cost. This mechanism was properly efficient for elderly patients with low functional

demands [11].

Most intertrochanteric hip fractures can be treated successfully with internal fixation [12]. Dynamic devices, also known as a sliding screw/side plate, sliding nail, telescoping nail, dynamic hip screw, and sliding hip screw, are currently in wide use as reliable methods of internal fixation although the operative technique is not always easy and postoperative regimens cannot be standardized [13-15]. The poor mechanical properties of the weak and porotic bone in these elderly patients do not usually provide a firm purchase for the screws leading to early biomechanical failure [15]. This will lead to collapse with migration of the femoral head into varus and retroversion resulting in limping due to shortening and decreased abductor muscle lever arm. Another complication of internal fixation in porotic weak bone is cutting-out of the implant from the femoral head leading to profound functional disability and pain [16].

K. Casey Chan and Gurdevs. Gill [17] found that Use of standard cemented hemiarthroplasty is a reasonable alternative to a sliding screw device for the treatment of intertrochanteric fractures to achieve less postoperative complications.

Bipolar arthroplasty group as compare to internal fixation had a lower postoperative complication rate and resulted in earlier weight bearing, which was also reported by others. There was a significant differences in full weight bearing time between the 2 groups. Though more costly, bipolar arthroplasty is a treatment option for patients with unstable Intertrochanteric fractures, which can achieve earlier mobilization [18].

When the concept of prosthetic replacement was first introduced, this perhaps was the most important advantage. As patients with internal fixation devices are more aggressively mobilized than in the past and the majority are allowed at least partial immediate weight-bearing. Primary hemiarthroplasty offers a modality of treatment that provides adequate fixation and early mobilization in these patients thus preventing post operative complications. This advantage is less distinct than previously thought. This finding has a definite selection bias because patients undergoing hemiarthroplasty tend to be more elderly and have more medical co-morbidities. The Indian perspective regarding the use of primary arthroplasty as a modality of treatment for comminuted unstable intertrochanteric fractures is been commented on by few authors [18].

Jotanovic Z et al. believe that in selected very old patients, with co-morbidities and obvious osteoporosis (which can imperil internal fixation), hemiarthroplasty is much safer than internal fixation which can be compromised with poor bone stock. Given that that these fractures usually occur in the elderly, who are less mobile and less demanding and therefore put less strain on the endoprosthesis, we believe that this kind of treatment is the treatment of preoperative activity level with fast mobilization, which imply satisfactory hip function [19].

In our study, more patients were ambulatory which was observed in hemiarthroplasty compared to internal fixation group however, could not give further comments because of sample size and duration of follow-up, one of the limitations of this study. Thus in conclusion, primary hemiarthroplasty thus provide a stable, pain-free, and mobile joint in this study.

## Conclusion

Cemented bipolar hemiarthroplasty as a treatment for unstable trochanteric fractures is a viable option for the elderly population. It results in early mobilization which avoids the

hazards of prolonged inactivity and prevents implant failure due to osteoporosis. Hemiarthroplasty decreases chances of complications resulting from prolonged incumbency such as pulmonary embolism, deep vein thrombosis, hypostatic pneumonia, and decubitus ulcer.

Good functional results were obtained by cemented bipolar hemiarthroplasty which can therefore be considered as a preferential method for unstable trochanteric fractures in elderly, although further prospective randomized trials are required to support our conclusion.

## References

- Zuckerman JD. Comprehensive care of orthopaedic injuries in the elderly. Baltimore: Urban and Schwarzenberg 1990.
- Haidukewych GJ, Berry DJ. Hip arthroplasty for salvage of failed treatment of intertrochanteric hip fractures. *J Bone Joint Surg Am* 2003;85(5):899-904.
- Haidukewych GJ, Berry DJ. Salvage of failed internal fixation of intertrochanteric hip fractures. *Clin OrthopRelatRes.* 2003; (412):184-188Z ein elabdien B, Olerud S, Karlstrom G, Smedby B. Rising incidence of hip fracture in Uppsala 1965-1980. *ActaOrthopScand* 1984;55:284-289.
- Koval KJ, Aharonoff GB, Rokito AS, et al. Patients with femoral neck and intertrochanteric fractures. Are they the same? *ClinOrthop* 1996;330:166-172.
- Haentjens P, Casteleyn P, Opdecam P. Primary bipolar arthroplasty or total hip replacement for the treatment of unstable intertrochanteric and subtrochanteric fractures in elderly patients. *ActaOrthopBelg* 1994;60:124-128.
- Harwin SF, Stern RE, Kulick RG. Primary Bateman-Leinbach bipolar prosthetic replacement of the hip in the treatment of unstable intertrochanteric fractures in the elderly. *Orthopedics* 1990;13:1131-1136.
- Zukerman JD. Comprehensive care of orthopaedic injuries in the elderly. Baltimore: Urban and Schwarzenberg 1990.
- Broos PL, Rommens PM, Geens VR, Stappaerts KH. Pertrochanteric fractures in elderly. Is Belgian VDP prosthesis the best treatment for unstable fractures with severe comminution? *ActaChirBelg* 1991;91:242-249.
- Stern MB, Angerman ALEX. Comminuted Intertrochanteric Fractures Treated with Leinbach Prosthesis. *ClinOrthop* 1987;218:75-80.
- Kayali C, Agus H, Ozluk S. Treatment for unstable intertrochanteric fractures in elderly patients: internal fixation versus cone hemiarthroplasty. *Journal of Orthopaedic Surgery* 2006;14(3):240-244.
- Bucholz Robert W, Heckman James D, Court-Brown Charles M. Rockwood & Green's Fractures in Adults, 6<sup>th</sup> Edition, 2006;45:1794.
- Harwin SF, Stern RE, Kulick RG. Primary Bateman-Leinbach bipolar prosthetic replacement of the hip in the treatment of unstable intertrochanteric fractures in the elderly. *Orthopedics* 1990;13:1131-1136.
- Kyle RF, Cabanela ME, Russell TA, Swiontkowski MF, Winquist RA, Zuckerman JD, *et al.* Fractures of the proximal part of femur. *Instr Course Lect* 1995;44:227-253.
- Cobelli NJ, Sadler AH. Ender Rod versus Compression Screw Fixation of Hip Fractures. *ClinOrthop* 1985;201:123-129.
- Stern MB, Angerman A. Comminuted intertrochanteric fractures treated with a Leinbach prosthesis. *ClinOrthop* 1987;218:75-80.
- Heyse-Moore GH, Maceachern AG, Jameson Evans DC. Treatment of Intertrochanteric Fractures of the Femur. A Comparison of the Richards Screw-Plate with the Jewett Nail-Plate. *J Bone Joint Surg* 1983;65-B(3):262-267.
- Mariani EM, Rand JA. Nonunion of intertrochanteric fractures of the femur following open reduction and internal fixation. Results of second attempts to gain union. *ClinOrthop* 1987;218:81-89.
- Grimsrud C, Monzon R, Richman J, Ries M. Cemented Hip Arthroplasty With a Novel Circlage Cable Technique for Unstable Intertrochanteric Hip Fractures *The Journal of Arthroplasty.* 20(3):337-343.
- Casey Chan K, Gurudev Gill S. Cemented Hemiarthroplasty for Elderly Patients eith Intertrochanteric Fractures *Clinical Orthopaedic and Related Research* 371:206-215.
- Patil Suresh, Panghatev Atul. Unstable Intertrochanteric Freacture In Elderly Patients – Bipolar Arthroplasty Or Internal Fixation?-A Matched Pair Analysis of High Risk Cohort To Compare Mortality And Morbidity In Two Group. *J Orthopaedics* 2008;5(3)e7.
- Jotanovic Z, I Jurdana H, Sestan B, SasaRapan Vladimir Bosch, Gulan G. Hemiarthroplastyis an Effective Surgical Method to Manage Unstable Trochanteric Fractures in Elderly People. *Coll. Antropol.* 2011;35(2):427-431.