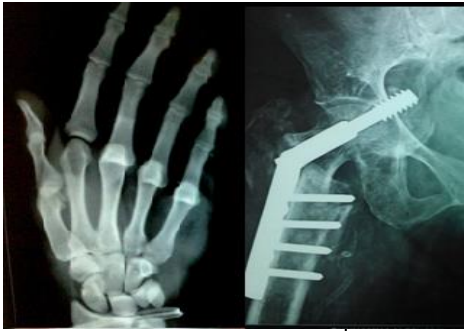

International Journal of Orthopaedics Sciences

E-ISSN: 2395-1958
P-ISSN: 2706-6630
IJOS 2020; 6(4): 949-953
© 2020 IJOS
www.orthopaper.com
Received: 03-09-2020
Accepted: 11-10-2020

Akshay Bhandari
Senior Resident, Department of
Orthopaedics, NDMC medical
college and Hindu Rao Hospital,
Delhi, India

Prateek Girotra
Senior Resident, Department of
Orthopaedics, BPS Government
medical college, Khanpur,
Sonapat, Haryana, India

Avadhesh Bhati
Senior Resident, Department of
Orthopaedics, Government
Medical College, Ratlam,
Madhya Pradesh, India

Harshwardhan Dawar
Senior Resident, Department of
Orthopaedics, Government
Medical College, Ratlam,
Madhya Pradesh, India

Corresponding Author:
Prateek Girotra
Senior Resident, Department of
Orthopaedics, BPS Government
medical college, Khanpur,
Sonapat, Haryana, India

Outcomes of K-wire pinning in supracondylar fractures of humerus in pediatric age group: A comprehensive study

Akshay Bhandari, Prateek Girotra, Avadhesh Bhati and Harshwardhan Dawar

DOI: <https://doi.org/10.22271/ortho.2020.v6.i4n.2443>

Abstract

Supracondylar fractures, one of the most common elbow injury in children, involves the lower end of the humerus, usually affecting the thin portion of humerus through olecranon fossa or just above the fossa through the metaphysis. Considering the high frequency and the complications that can occur, great diligence is required to secure an excellent result and to avoid or minimize any complications.

Objectives: The present study was done to assess the result of the surgery concerning the restoration of function, deformity and about prevention of complications of the fracture

Methodology: The prospective study, conducted on 40 cases of supracondylar fractures (Type II and Type III), who underwent open/closed reduction with K-wire fixation b/w August 2019 to August 2020, at NDMC medical college and Hindu Rao hospital, Delhi, India. It included 30 males and 10 females and the average age of presentation was 7.3 years. 30 patients had left-sided and 10 of them had right-sided fractures. Type 3 fracture was seen in 28 (24 posteromedial and 4 posterolateral) and Type 2 in 12 patients. Two patients had radial nerve injury, 2 had median nerve injury and 1 had distal end radius fracture. All the 12 cases with type II underwent closed reduction, while of the type III cases, 10 of them underwent closed and 18 of them underwent open reduction. 16 patients underwent 2 cross-wired pinning, 2 of them underwent lateral pinning and 22 of them underwent 3 wire pinning. Post-operatively, 1 patient developed pin tract infection and 1 had cubitus varus. All the patients were reviewed at 3, 6 and 12 weeks postoperatively and assessed for range of movements and deformity.

Results: Based on Flynn's criteria, of the 40 cases, 34 patients obtained excellent results, 4 of them had good results and 2 of them had fair results.

Conclusion: This study shows that anatomical reduction and K-wire pinning in the management of supracondylar fracture provides good results and minimal loss in the range of movement with relatively fewer complications. Thus, we conclude that percutaneous pinning with either lateral entry K-wires or cross k-wires or a combination of lateral wires with medial wire is an appropriate treatment of choice for displaced supracondylar fracture of the humerus in children either by closed reduction or open reduction.

Keywords: Antero-posterior, closed reduction internal fixation, internal fixation, kirschner wire, open reduction internal fixation

Introduction

Supracondylar fracture of humerus is an extra-articular fracture occurring in the distal metaphyseal region of humerus. It is almost exclusively a fracture of the immature skeleton, seen in children and young teenagers [1]. Fractures around the elbow are a great challenge to orthopaedicians. An exact clinical diagnosis may be difficult due to non-cooperative patient mass and massive swelling around the elbow. Displaced supracondylar fractures are notorious for the difficulty in reduction, maintenance of reduction and frequent involvement of neurovascular structures [2, 3]. Supracondylar fracture of the humerus is the second most common fracture of limbs in children, accounting for 16.64% of all limb fractures in children with the distal radial fractures being the commonest (19.97% of all limb fractures in children) [4]. It comprises 60-75% of all elbow fractures in children [5]. The rate of incidence of this fracture increases steadily in the first 5 years of life, attains a peak between 5 and 8 years of age and decreases thereafter [6].

Incidence of sex predominance is variable in different studies, however, most studies show male preponderance [5, 7]. The fracture has a left-sided predominance due to the fact when a child falls from a height, there is an attempt to hold on to something with the dominant arm and thus lands on the ground with the non-dominant arm [5]. According to the direction of the distal fragment, supracondylar fractures of humerus in children are divided into two types i.e. Extension type (97.8%) and Flexion type (2.2%).1 (figure 1)

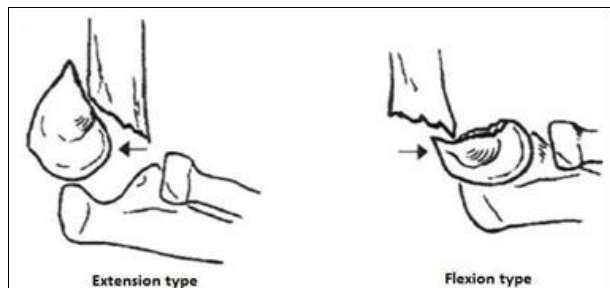


Fig 1: Types of supracondylar fracture of humerus according to direction of displacement

Complications are fairly common. Treatment is controversial and often technically difficult.8 Previous studies suggest vascular injury occurs in 0.5%-0.8% of cases; nerve injury incidence is 6-16%, cubitus varus is 30%, which doesn't remodel with growth [9, 10]. The Modalities of treatment include Immobilisation in plaster of Paris slab in undisplaced fracture, Closed Reduction (CR) and immobilization, Traction by various methods, Closed Reduction and K-wire pinning under C-Arm, Open Reduction and Internal Fixation (ORIF) with K-wire pinning for comminuted fracture. In Closed Reduction and immobilization or traction, redisplacement with varus or valgus, deformity is common. In ORIF, infection and stiffness, long post-operative stay in hospital, high cost, children's and parent's apprehension are the problems [11]. If image intensifier is available, CR gives good results and is the preferred, accepted and the proposed method [16].

Objectives

To study functional outcome after percutaneous pinning or open reduction internal fixation of type III (Gartland classification) supracondylar humerus fracture or unstable displaced or irreducible type II (Gartland classification) fractures in children by assessing the accuracy of reduction and its radiological evaluation by Baumann's angle and to find out a final range of movements of the elbow joint in terms of flexion and extension; Comparison of carrying angle of both elbows in final follow up.

Methodology

This is a prospective study, consisting of 40 cases of fresh supracondylar fracture of humerus in children who were treated by closed or open reduction and stabilized by Kirschner's wires. This study was conducted at the Department of Orthopaedics, NDMC medical college and Hindu Rao hospital, Delhi, India between August 2019 and August 2020.

Inclusion Criteria: Age group 5 – 12 years; Type III (Gartland classification) supracondylar humeral fractures; Children with unstable displaced or irreducible type II (Gartland classification) fractures.

Exclusion Criteria: Undisplaced fractures; Pathological fractures; Comminuted type 3C (Gustilo and Anderson classification) open fractures.

All the patients selected for this study were admitted with a detailed history and examination of the patient. Patients were initially immobilized using an arm sling and analgesics were given for pain relief. The patients' radiograph was taken in Antero-posterior and lateral views. The diagnosis was established by clinical and radiological examination. In this study, the supracondylar fracture of the humerus was classified according to Gartland's classification.

Type 1: Undisplaced Supracondylar fracture of the humerus.

Type 2: Displaced Supracondylar fracture with the intact posterior cortex. Type

Type 3: Displaced Supracondylar fracture with no cortical contact which can be further divided into a) Postero-medial b) Postero-lateral.

All patients were taken for elective or emergency surgery as soon as possible after necessary routine investigations and radiographic preoperative work-up. Written and informed consent was obtained from the parents of the children before surgery. All patients were started on prophylactic antibiotic therapy. An intravenous antibiotic was administered according to the bodyweight of the children, before induction of anesthesia and continued post-operatively for 3 days in closed reduction cases and 5 days in open reduction cases. In closed reduction cases, antibiotics were withdrawn after 3 days and oral antibiotics were given for further 4 days, while in open reduction cases after I.V. antibiotics for 5 days, oral antibiotics were given till suture removal.

Surgical Procedure

All patients were induced under suitable Anaesthesia. Patient positioning for closed reduction: Supine with the ipsilateral shoulder at the edge of the table (figure 1). For open reduction: Lateral position with the fractured elbow facing the surgeon, sandbags were placed beneath the arm, the forearm was left to hang freely with the elbow flexed.

Technique of closed reduction and internal fixation

Traction along the longitudinal axis with the elbow in extension and supination given. At the same time counter traction was given by an assistant by holding the proximal portion of the arm. Medial or lateral displacements were corrected by valgus or varus forces respectively. After that, posterior displacement and angulation were corrected by flexing the elbow and applying posteriorly directed force from the anterior aspect of the proximal fragment and anteriorly directed force from the posterior aspect of the distal fragment. Reduction was confirmed under image intensifier in two views: Anteroposterior view Lateral view. After confirming satisfactory alignment, reduction was maintained by percutaneous K-wire fixation. Above elbow posterior POP splint in 90° elbow flexion of forearm was applied.

The technique of open reduction (Figure 2)

Open reduction internal fixation done under suitable anesthesia, closed reduction will be attempted first; in the event of its failure, a pneumatic tourniquet will be applied and posterior midline incision about 6-7cm will be made. Ulnar nerve will be identified and isolated. After elevating triceps muscle, the fracture site will be cleared, reduced, and fixed either with cross K-wires or lateral K-wires of appropriate diameter under c-arm fluoroscopy through the medial and

lateral epicondyles. The ends of the wires will be left outside the skin for easy removal later on. Skin will be closed and posterior slab will be applied. Postoperative check X-ray both

anteroposterior as well as lateral views will be taken to confirm the reduction. Distal pulse is monitored throughout the procedure.

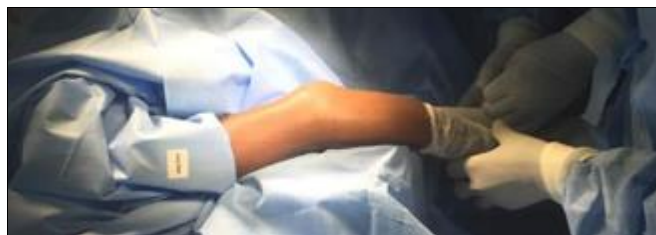

Fig 2: Technique of positioning, painting, and draping

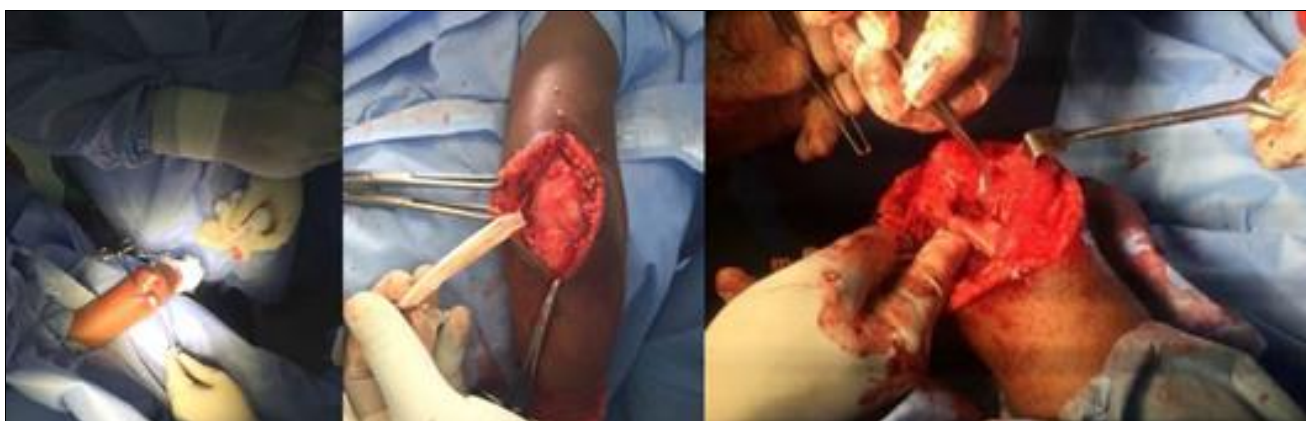

Fig 3: Technique of open reduction and internal fixation

Introduction of K-wires

K-wires of about 1.2mm to 2.0mm were used. Either 2 criss-cross pins were used, one from medial epicondyle and one from lateral epicondyle, or 3 K-wires were used and at times 2 lateral K-wires were used. After achieving satisfactory reduction, either closed or by open technique, K-wires were introduced with the help of a drill. Medial pin entry was from tip of the medial epicondyle and the lateral pin was introduced from the center of the lateral condyle. Both pins were directed 40° to the humeral shaft in sagittal plane and 10° posteriorly. K-wire placement was checked in image intensifier in Anteroposterior and lateral views in case of closed reduction (figure 3). And precautions were taken to engage both cortices to cross above the fracture site and not to cross the olecranon fossa. K-wires were bent and kept at least 1 cm outside the skin. Sterile dressing was applied.

observation for any neurovascular deficit was observed at regular intervals. Appropriate antibiotics and analgesics were used. On 2nd postoperative day, check dressing was done and the condition of the operative wound or pin site was noted. Check X-rays in AP and lateral views were taken. Patients in whom closed reduction was done were discharged on 3rd or 4th postoperative day with oral antibiotics. Patients in whom open reduction was done, were discharged after 5 days with oral antibiotics.

Follow up

These patients were reviewed on the 12th post-operative day on an outpatient basis for suture removal in patients who underwent open procedures. Wires were removed at 3 weeks post-operatively after X-ray confirmation of satisfactory callus formation. POP splint was discarded at the same time and the patient was encouraged to do active elbow flexion-extension and supination-pronation exercises. Patients were advised to avoid massage and passive stretching and not to lift heavy weights till 12 weeks post-operatively. Follow up was done on an OPD basis at 3rd, 6th, and 12th-week postoperatively. The follow up was done by clinical and radiological evaluation, and results were assessed based on Pain, Swelling, Tenderness at the fracture site, Movements of the elbow, Carrying angle of the elbow compared with normal elbow, Union of the fracture, Baumann’s Angle, and Flynn’s criteria³⁰. (Table 1)

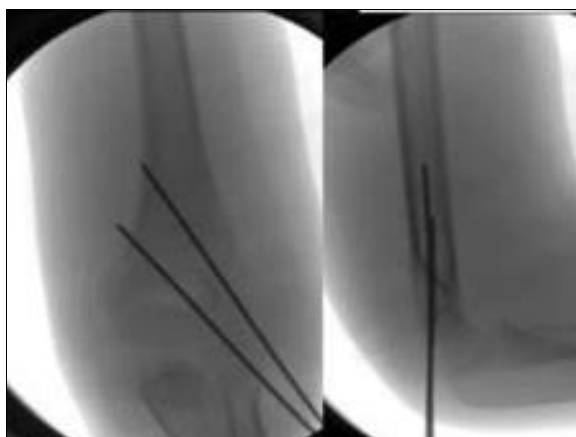


Fig 4: Lateral and AP views under image intensifier of 2 lateral K-wires after fixation

Table 1: Flynn’s Criteria

| Outcome | Cosmetic factor carrying-angle loss (degrees) | Functional factor movement loss (degrees) |
|-----------|---|---|
| Excellent | 0° to 5° | 0° to 5° |
| Good | 5° to 10° | 5° to 10° |
| Fair | 10° to 15° | 10° to 15° |
| Poor | >15° | >15° |

Results: Functional results are mentioned as observed at the 12th postoperative week follow-up

Age Distribution: The age of patients ranged from 5-12 years. The average age was 7.35 years. (Table 2)

Post-operatively, Patient was encouraged to move fingers. Careful

Table 2: Age Distribution The χ^2 value was 7.4 and the p-value was 0.025, which is significant

| Age (years) | Number of patients (%) |
|-------------|------------------------|
| 5-8 | 26 (65%) |
| 9-12 | 14 (35%) |
| Total | 40 |

Sex distribution: Table 3 shows the gender distribution among the cases.

Table 3: Sex distribution the χ^2 value is 4.356 and the p-value is 0.037, making it significant

| Sex | Number of patients (%) |
|--------|------------------------|
| Male | 30 (75%) |
| Female | 10 (25%) |
| Total | 40 |

Type of Fracture: Based on Gartland’s classification, 12 patients had Type 2 fracture and 28 of them had Type 3 fracture. The χ^2 value is 0.317 and the p-value is 0.573, which makes it insignificant.

Type of Displacement: Of the 14 cases who had Type 3 fracture, 12 of them had posteromedial displacement and 2 of them had posterolateral displacement. The χ^2 value is 9.0 and the p-value is 0.003, making the values significant.

Associated Injuries: Of the 20 patients, 1 patient had radial nerve injury and 1 patient had medial nerve injury. In all these cases, nerve functions improved by 6-8 weeks. One patient had a distal radius fracture, which improved following closed reduction and pinning.

Type of Reduction: Of the 40 cases, 22 patients underwent closed reduction, of which 12 belonged to Type 2 and 10 belonged to Type 3 fractures. All the 18 patients who underwent open reduction, had Type 3 fractures. (Table 4)

Table 4: Distribution by type of reduction achieved

| Type of Fracture | Closed Reduction | Open Reduction | Total |
|------------------|------------------|----------------|-------|
| TYPE 2 | 12(54.5%) | - | 6 |
| TYPE 3 | 10(45.5%) | 18 (100%) | 14 |

Pinning Method: (Table 5) of the 20 cases, 8 of them underwent 2 cross-wired pinning, 1 of them underwent lateral pinning and 11 of them underwent 3 K-wire pinning. Of the 6 patients who had type II fracture, 5 of them underwent 2 K-wire crossed pinning configuration and 1 of them underwent 2 lateral pinning configuration. Of the 14 patients, who had type III fracture, 11 of them underwent 3 K-wire pinning and 3 of them underwent 2 K-wire crossed pinning configuration.

Table 5: Pinning method used according to fracture type

| | 2-cross wire | 2 lateral | 3 k-wire | total |
|----------|--------------|-----------|------------|-------|
| Type II | 10 (83.3%) | 2 (16.7%) | - | 12 |
| Type III | 6 (21.4%) | - | 22 (78.6%) | 28 |

Movement Loss: Of the 20 cases, according to Flynn’s criteria 16 Patients had a limitation of 0-5 degree, 3 patients had 5-10 degree, 1 patient had 10-15 degree° and no patient had a limitation of movement >15 degree. (Table 6) The χ^2 value 19.900 and the p-value is 0.000, making this result significant.

Table 6: Movement loss range

| Movement loss | Number of patients |
|---------------|--------------------|
| 0° to 5° | 32 |
| 5° to 10° | 6 |
| 10° to 15° | 2 |
| >15° | 0 |
| Total | 40 |

Change in Carrying Angle: (Table 7) of the 20 patients, 17 patients had changes in carrying angle between 0-5°, 2 of them had changes between 5-10° and 1 of them had changes between 10-15°.

Table 7: Changes in carrying angle and number of associated patients.

| Change in carrying angle | Number of patients (%) |
|--------------------------|------------------------|
| 0-5° | 34 (85%) |
| 5-10° | 4 (10%) |
| 10-15° | 2 (5%) |
| >15° | 0 |
| Total 40 (100%) | |

The χ^2 value is 24.100 and the p-value is 0.000, making this a significant result.

Change in Baumann’s Angle: Of the 20 patients, 17 patients had changes in Baumann’s angle up to 5°, 3 of them had changes above 5°. The χ^2 value is 9.80 and the p-value is 0.002, making this a significant result.

Flynn’s Criteria: Of the 20 cases, 17 patients obtained excellent results, according to the Flynn’s criteria, 2 of them had good results, 1 of them had fair results and 0 patient had poor result. The χ^2 value is 25.4 and the p value is 0.000, making this a significant result.

Discussion

A supracondylar fracture of the humerus is one of the most common injuries in children. Difficulty in treating this fracture lies in the fact that this gets complicated very often. Initial treatment and definitive treatment of this fracture is of utmost importance. In this study, 40 cases of supracondylar fracture were treated either with closed or open reduction and K-wire pinning. The purpose of this study was to evaluate the result of the surgery with reference to the restoration of function and prevention of complications of the fracture. In the present study, the average age was 7.3 years, which is similar to the average age in other studies. (7 years in Ramsey *et al.* [15], 7.3 in Ippolito *et al.* [1, 6, 7] in Wilkins *et al.*) [3]. Sex Distribution in the present study, 30 (75%) were male patients and 10 (25%) were female patients, which is similar to other studies, showing a male preponderance [1, 3].

Type of Fracture of the 40 cases in this study, 12 (30%) had type II fracture and 28 (70%) of them had type III fracture. Table 8 shows Comparison of the type of fracture with other studies. As in the other studies, there is a preponderance of type III fractures in this study.

Table 8: Comparison of type of fracture with other studies

| Series | Type II | Type III |
|---------------------------|---------|----------|
| Zamzam <i>et al.</i> [17] | 37.9% | 62.03% |
| Zhong <i>et al.</i> [18] | 80 35% | 64.95% |
| Present Study | 30% | 70% |

Type of Displacement: In this study, of the 28 cases who had type III fracture, 24 (85.7%) had posteromedial displacement and 4 (14.3%) of them had posterolateral displacement. Table 9 shows a comparison of the type of displacement with other studies.

Table 9: Comparison of type of displacement with other studies

| Series | Posteromedial (%) | Posterolateral (%) |
|----------------------------|-------------------|--------------------|
| Pirone <i>et al.</i> [2] | 81% | 22% |
| Wilkins <i>et al.</i> [16] | 75% | 25% |
| Saad <i>et al.</i> [13] | 90% | 10% |

Posteromedial displacement is much more common than posterolateral displacement, as is seen in other studies.

Conclusion

An overall analysis of the study leads us to the following inferences. Supracondylar fractures of humerus are more common in boys than girls possibly due to more activity in boys. Extension type of fractures are more frequent than flexion type. Adequate reduction can be achieved by closed manipulation and monitored under fluoroscopy. But maintenance of reduction in displaced fractures requires K-wire fixation before the elbow can be brought into less flexion. Anatomical reduction is the key to obtaining good results, which is possible both through open or closed reduction. Lateral entry K-wires, cross k wires and combined techniques provide stable fixation when observing the guidelines for wire placement. By the aforementioned surgical methods, early mobilization of the elbow with good range of movement and fewer complications were achieved. The results obtained in this study shows that anatomical reduction (closed/open) with K-wire fixation is the treatment of choice for Type II and Type III fractures. Thus, we conclude that percutaneous pinning with either lateral entry K-wires or cross K-wires or a combination of lateral wires with medial wire is an appropriate treatment of choice for displaced supracondylar fracture of the humerus in children either by closed reduction or open reduction.

Summary

The data was assessed, analyzed and results were evaluated according to the criteria described by Flynn. This study shows that anatomical reduction and K-wire pinning in the management of supracondylar fracture provides good results and minimal loss in range of movement with relatively fewer complications.

References

1. Wilkins KE. The operative management of supracondylar fractures. *Orthop Clin North Am* 1990;21:269.
2. Bachman D, Santora S. Orthopedic trauma. In: Fleisher GR, Ludwig S, Henretig FM (eds.), *Textbook of Pediatric Emergency Medicine*. Philadelphia: Lippincott Williams and Wilkins 2006,1538.
3. Lins RE, Simovitch RW, Waters PM. Pediatric elbow trauma. *Orthop Clin North* 1999;30:119.
4. Cheng JC, Shen WY. Limb fracture pattern in different pediatric age groups: a study of 3350 children. *J Orthop Trauma* 1993;7(1):15-22.
5. Lord B, Sarraf KM. Paediatric supracondylar fractures of the humerus: acute assessment and management. *British Journal of Hospital Medicine* 2011;72(1):M8-M11.
6. Landin LA. Fracture patterns in children. *Acta Orthop Scand* 1983;202:13

7. Farnsworth CL, Silva PD, Mubarak SJ. Etiology of supracondylar humerus. *Ediatr Orthop* 1998;18(1):38-42.
8. James RK, James HB. *Rockwood Wilkin's fractures in children*. 5th ed. Philadelphia: Lippincott, William and Wilkins 2001.
9. John AH. *Tachdjian's pediatric orthopaedics*. 3rd ed. Philadelphia: Saunders 2002.
10. Jeffrey LN, Malcolm LE, Stanley MK, Paul AL, Marianne D. Supracondylar fractures of humerus in children treated by closed reduction and percutaneous pinning. *Clinical Orthopaedics and Related Research* 1983;177:203-9.
11. Attenborough CG. Remodelling of humerus after supracondylar fractures in childhood. *The Journal of Bone and Joint Surgery* 1953;35-B:386-95.
12. Madsen E. Supracondylar fractures of the humerus in children. *The Journal of Bone and Joint Surgery* 1955;38-B:241.
13. Schunk VK, Grossholz M, Schild H. Der Supinatorfettkörper bei Frakturen des Ellbogengelenkes. *Fortschr Röntgenstr* 1989;150:294-6.
14. Flynn JC, Mathew JC, Beoit RL. Blind pinning of supracondylar fractures of humerus in children. *The Journal of Bone and Joint Surgery* 1974;56-A:263-71.
15. Rogers LF. Fractures and dislocations of the elbow. *Semin. Roentgenol* 1978;13:97-107.
16. Gartland JJ. Management of supracondylar fractures of humerus in children. *Surg Gyneco Obstet* 1949;109:145-54.
17. El-Hawney. Supracondylar fractures of humerus in children with a note on surgical correction of cubitus varus. *Injury* 1974;6:45-6.
18. Jones KG. Percutaneous pin fixation of fractures of the lower end of the humerus. *Clinical Orthopaedics and Related Research* 1967;50:53-69.