



International Journal of Orthopaedics Sciences

E-ISSN: 2395-1958
P-ISSN: 2706-6630
IJOS 2020; 6(4): 827-830
© 2020 IJOS
www.orthopaper.com
Received: 22-08-2020
Accepted: 30-09-2020

Dr. Yogesh Gangurde
Assistant Professor, Department
of Orthopaedics, Government
Medical College, Jalgaon,
Maharashtra, India

Dr. Nilesh Indulal Kachnerkar
Associate Professor, Department
of Orthopaedics, Government
Medical College and Hospital
Aurangabad, Maharashtra, India

Dr. Neetin Mahajan
Associate Professor, Department
of Orthopaedics, Grant
Government Medical College and
Hospital Mumbai, Maharashtra,
India

Dr. Rajendra Agarwal
Assistant Professor, Department
of Orthopaedics, Government
Medical College, Jalgaon,
Maharashtra, India

Corresponding Author:
Dr. Nilesh Indulal Kachnerkar
Associate Professor, Department
of Orthopaedics, Government
Medical College and Hospital
Aurangabad, Maharashtra, India

Study of anatomy & dimension of anterior cruciate ligament and hamstrings tendon graft in cadavers

Dr. Yogesh Gangurde, Dr. Nilesh Indulal Kachnerkar, Dr. Neetin Mahajan and Dr. Rajendra Agarwal

DOI: <https://doi.org/10.22271/ortho.2020.v6.i4l.2426>

Abstract

There has been increase in the cases of anterior cruciate ligament injury and multiple ligament injuries of the knee which result in the damage to the active and passive stabilisers of the knee, thereby hampering the normal biomechanics of the knee joint along with the neurovascular compromise due to increase in sporting activities and increased road traffic accidents. Reconstruction of the damaged ligaments of the knee poses problem even to experienced surgeons. Therefore the operating surgeon should have the complete knowledge of the anatomy of ligaments of the knee, graft used for reconstruction and normal biomechanics so as to reduce the operative timing and better postoperative functional outcome. Length and diameter of the native anterior cruciate ligament play an important role in selection and preparation of graft for reconstruction. Our study reveals the details of the dimensions of the mid substance, footprints of the anterior cruciate ligament and the quadrupled hamstring tendon graft used for the reconstruction. The hypothesis of this study is that there is mismatch between the dimensions of mid substance of the anterior cruciate ligament and the quadrupled hamstring tendon graft for the reconstruction of the anterior cruciate ligament.

Keywords: Anatomical dimension, cadaver study, anterior cruciate ligament, hamstring tendon graft

Introduction

There has been increase in the cases of anterior cruciate ligament injury and multiple ligament injuries of the knee which result in the damage to the active and passive stabilisers of the knee, thereby hampering the normal biomechanics of the knee joint. Reconstruction of the damaged ligaments of the knee poses problem even to experienced surgeons. Therefore the operating surgeon should have the complete knowledge of the anatomy of ligaments of the knee, graft with the newer technique of the anterior cruciate ligament reconstruction like double bundle technique, the main aim was to reproduce the anterior cruciate ligament footprint so as to restore the kinematics. But it is also important to study that whether there is any oversizing of the graft as compared to the native anterior cruciate ligament mid substance so as to avoid the chances of the impingement of the graft. This study reveals the details of the dimensions of the mid substance, footprints of the anterior cruciate ligament and the quadrupled hamstring tendon graft used for the reconstruction.

Material and Methods

Permission from ethical committee was taken. This study includes prospective study on 22 cadavers.

Study design

Study had 22 cadavers included for the measurement of the dimensions of the anterior cruciate ligament and hamstring tendon graft.

Inclusion criteria

Age Group 20 years to 70 years. Non operated and non-injured knee joint with intact anterior cruciate ligament

Exclusion criteria

Cadavers having previously operated knee joint. Cadavers with torn anterior cruciate ligament. Significant Osteoarthritis

Study period

Jan 2015 to Dec 2018. The cadaveric study included the 44 paired knees from 22 fresh frozen cadavers. The average conservation time from death to dissection was 50 days. The range of age of the cadavers was 35-40 years to 60-65 years. Full extension was possible in all the knees whereas the flexion ranges from 120 to 135 degree.

Surgical procedure

The cadaver is placed in supine position on table. The knee was opened by para median incision. Soft tissue and capsule was cut and patella was everted so as to expose the anterior cruciate ligament. Anteromedial and posterolateral bundles were visible all the time. The measurement of the anterior cruciate ligament is taken before cutting the ligament so as to maintain the native tensioning of the graft. Soft tissue including synovial membrane around the anterior cruciate ligament was removed and knot was applied about 1.5cm proximal to the tibial insertion by applying 25 gm weight on the either side of the knot, so as to maintain the constant tension while applying knot all the times. The diameter was taken with digital vernier calliper. The anterior cruciate ligament was released from its tibial and femoral insertion. The femoral and the tibial insertion sites were stained and the length and width measurement was taken, considering the geometric insertion as ellipses. The length measurements were taken from the major axis of the insertion area and the width was calculated at perpendicular to the length axis at its widest point the incision was extended till the insertion of semi tendonosus and gracilis on the medial upper part of the shaft of tibia and they were separated by open release procedure. The graft was cleaned and prepared as quadrupled tendon graft and the cross sectional diameter was taken with digital vernier calliper by applying 25 gm weight on the either side of the knot. Cross sectional area and diameter was calculated by using geometrical calculation used to calculate the area of cylinder and ellipse.

Area of the circle = $\pi \times (\text{diameter}/2)^2$

Area of the ellipse = $\pi \times \text{length of the major axis (Length)} \times$

length of the minor axis (Width)/4

All continuous data are expressed as mean (SD) and two sided *t* tests were used for statistical analysis. Chi square test was used for nominal data. $P < 0.05$ was considered significant.

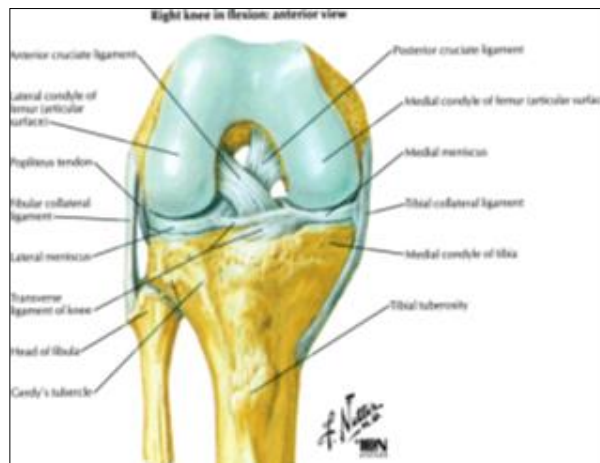


Fig 1: Attachment points of each bundle of the anterior cruciate ligament in tibia

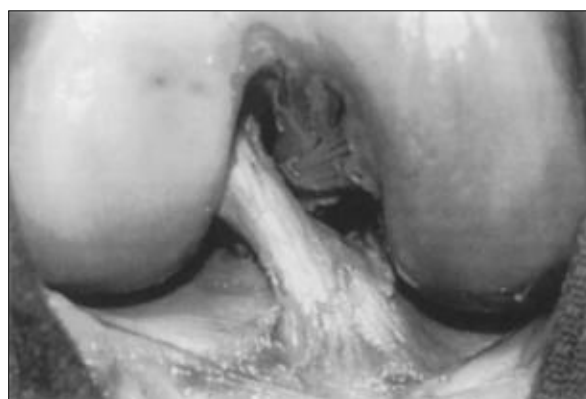

Fig 2: Cadaveric demonstration of ACL attachments on tibia and femur

Results

Table 1: Results of anatomy and dimensions of ACL (A)

	Mean diameter of the ACL mid portion in mm	Mean diameter of the quadrupled hamstring tendon graft in mm	Mean cross sectional area of the ACL mid portion in mm ²	Mean cross sectional area of the quadrupled hamstring tendon graft in mm ²
Mean	6.7	7.3	33.35	42.27
Male	6.39	7.46	34.10	41.94
Female	6.23	6.64	32.81	36.33
Right	6.54	7.20	33.71	41.59
Left	6.46	7.20	34.97	41.16

Table 2: Results of anatomy and dimensions of ACL (B)

	Tibial insertional length/width (mm)	Tibial insertional area (mm ²)	Femoral insertion length/width (mm)	Femoral insertional area (mm ²)
Mean	14.32/11.47	128.63	12.56/9.54	96.23
Male	14.81/12.06	141.83	13.76/10.12	111.78
Female	13.45/10.62	111.46	11.31/8.53	76.66
Right	14.47/11.55	132.10	12.59/9.52	95.68
Left	14.35/11.39	127.14	12.53/9.51	94.78

Discussion

We find in study that there is good correlation between the mid portion of the anterior cruciate ligament and the

quadrupled hamstring tendon graft with the constant oversizing of the quadrupled hamstring tendon graft as compared to the mid portion of the anterior cruciate ligament.

In studies done till now on the anterior cruciate ligament reconstruction, the study of the tunnel placement and the biomechanical testing has been done [1, 2, 3, 4]. As the anterior cruciate ligament reconstruction is the type of graft transplantation, the dimensions of the native anterior cruciate ligament and the graft need to be studied.

This study drawback that the evaluation is done by the macroscopic examination only. There might be human errors and the bias.

Dimension of the anterior cruciate ligament were measured manually with the digital vernier calliper. But as the anterior cruciate ligament is the three dimensional structure [5], better dimensions would have been obtained with the three dimensional camera or the computer graphics. Some authors have taken dimensions with the x ray [13] and MRI [14].

Draget *et al.*, [15] measured the dimensions of the anterior cruciate ligament after removing the ligament from the footprints. Therefore in this study dimensions of the mid portion was taken with the intact anterior cruciate ligament.

In this study, the dimensions of the anterior cruciate ligament were taken after the removal of synovial membrane so as to get the more accurate dimensions. Results obtained by this method are comparable with those obtained after the removal of the synovial membrane [8, 16, 17].

In most of the cases of the anterior cruciate ligament reconstruction, the size of the reconstructed anterior cruciate ligament is determined by the mid substance of the anterior cruciate ligament. This finding is similar with our study.

As per the previous studies, the area of the anterior cruciate ligament femoral footprint ranges from 83 to 198 mm² and the tibial foot footprint ranges from 114 to 229 mm² [5, 6, 7, 8, 9, 10]. The area of the quadrupled hamstring tendon graft ranges from 20 mm² to 50 mm² and the area of the mid portion of the anterior cruciate ligament ranges from 20 mm² to 38.9 mm² [21]. The findings in our study are similar to the previous studies.

As described by Mochizuki *et al.*, [11] and Hara *et al.*, [12], ACL is attached at the femoral origin as the fan shaped structure. Therefore the insertional area at the femoral footprint is bigger than the anterior cruciate ligament mid substance. These findings are similar to our study.

The ACL is the narrowest at its mid portion. The ACL footprints are 3.5 times bigger as compared to the mid portion [18].

For clinical relevance, there is good correlation between the anterior cruciate ligament and the mid portion of the anterior cruciate ligament but there is no correlation between the anterior cruciate ligament footprints and the quadrupled hamstring tendon graft. Therefore it is unlikely to reproduce the femoral and tibial anterior cruciate ligament footprints with the quadrupled hamstring tendon graft. Also Bedi *et al.*, [19] stated in his study that the restoration of the anterior cruciate ligament foot in reconstruction is of paramount importance.

Conclusion

Correlation between the cross sectional area of the mid substance of the anterior cruciate ligament and cross sectional area of the quadrupled hamstring tendon graft has been found in Indian population. With the use of quadrupled hamstring tendon graft for the reconstruction of the anterior cruciate ligament, the graft is oversized at the mean of 16%. Anterior cruciate ligament dimensions are more in males as compared to females and more on right side as compared to left side. Use of current reconstruction technique of the quadrupled

hamstring tendon graft, it is unlikely to reproduce the footprints of the anterior cruciate ligament.

References

1. Brophy RH, Selby RM, Altchek DW. Anterior cruciate ligament revision: double-bundle augmentation of primary vertical graft. *Arthroscopy* 2006;22(683):e1–e5.
2. Darcy SP, Kilger RH, Woo SL, Debski RF. Estimation of ACL forces by reproducing knee kinematics between sets of knees: a novel noninvasive methodology. *J Biomech* 2006;39:2371-2377.
3. Iriuchishima T, Tajima G, Shirakura K *et al.* *In vitro* and *in vivo* AM and PL tunnel positioning in anatomical double bundle anterior cruciate ligament reconstruction. *Arch Orthop Trauma Surg* 2011;131:1085-1090.
4. Iriuchishima T, Ingham SJ, Tajima G *et al.* Evaluation of the tunnel placement in the anatomical double-bundle ACL reconstruction: a cadaver study. *Knee Surg Sports Traumatol Arthrosc* 2010;18:1226-1231.
5. Ferretti M, Ekdahl M, Shen W, Fu FH. Osseous landmarks of the femoral attachment of the anterior cruciate ligament: an anatomic study. *Arthroscopy* 2007;23:1218-1225.
6. Harner CD, Baek GH, Vogrin TM *et al.* Quantitative analysis of human cruciate ligament insertions. *Arthroscopy* 1999;15:741-749.
7. Muneta T, Takakuda K, Yamamoto H. Intercondylar notch width and its relation to the configuration and cross-sectional area of the anterior cruciate ligament. A cadaveric knee study. *Am J Sports Med* 1997;25:69-72.
8. Siebold R, Ellert T, Metz S *et al.* Tibial insertions of the anteromedial and posterolateral bundles of the anterior cruciate ligament: morphometry, arthroscopic landmarks, and orientation model for bone tunnel placement. *Arthroscopy* 2008;24:154-161.
9. Siebold R, Schuhmacher P. Restoration of the tibial ACL footprint area and geometry using the Modified Insertion Site Table. *Knee Surg Sports Traumatol Arthrosc* 2012;20:1845-1849.
10. Takahashi M, Doi M, Abe M *et al.* Anatomical study of the femoral and tibial insertions of the anteromedial and posterolateral bundles of human anterior cruciate ligament. *Am J Sports Med* 2006;34:787-792.
11. Hara K, Mochizuki T, Sekiya I, Yamaguchi K, Akita K, Muneta T. Anatomy of normal human anterior cruciate ligament attachments evaluated by divided small bundles. *Am J Sports Med* 2009;37:2386-2391.
12. Mochizuki T, Fujishiro H, Nimura A *et al.* Anatomic and histologic analysis of the mid-substance and fan-like extension fibres of the anterior cruciate ligament during knee motion, with special reference to the femoral attachment. *Knee Surg Sports Traumatol Arthrosc* 2013. DOI:10.1007/s00167-013-2404-4
13. Colombet P, Robinson J, Christel P *et al.* Morphology of anterior cruciate ligament attachments for anatomic reconstruction: a cadaveric dissection and radiographic study. *Arthroscopy* 2006;22:984-92.
14. Cohen SB, VanBeek C, Starman JS, Armfield D, Irrgang JJ, Fu FH. MRI measurement of the 2 bundles of the normal anterior cruciate ligament. *Orthopedics* 2009;32.
15. Dargel J, Feiser J, Gotter M, Pennig D, Koebke J. Side differences in the anatomy of human knee joints. *Knee Surg Sports Traumatol Arthrosc* 2009;17:1368-76.
16. Siebold R, Ellert T, Metz S, Metz J. Femoral insertions of the anteromedial and posterolateral bundles of the

- anterior cruciate ligament: morphometry and arthroscopic orientation models for double-bundle bone tunnel placement—a cadaver study. *Arthroscopy* 2008;24:585-92.
17. Mochizuki T, Muneta T, Nagase T, Shirasawa S, Akita KI, Sekiya I. Cadaveric knee observation study for describing anatomic femoral tunnel placement for two-bundle anterior cruciate ligament reconstruction. *Arthroscopy* 2006;22:356-61.
 18. Harner CD, Baek GH, Vogrin TM, Carlin GJ, Kashiwaguchi S, Woo SL. Quantitative analysis of human cruciate ligament insertions. *Arthroscopy* 1999;15:741-9.
 19. Bedi A, Maak T, Musahl V *et al.* Effect of tunnel position and graft size in single-bundle anterior cruciate ligament reconstruction: an evaluation of time-zero knee stability. *Arthroscopy* 2011;27:1543-1551.
 20. Takanori Iriuchishima, Keinosuke Ryu, Hiroshi Yorifuji, Shin Aizawa, Freddie Fu H. Commonly used ACL autograft areas do not correlate with the size of the ACL footprint or the femoral condyle. *Knee Surg Sports Traumatol Arthrosc* 2014;22:1573-1579.
 21. Nicolas Pujol, Steffen Queinnec, Philippe Boisrenault, Ali Maqdes, Philippe Beaufils. Anatomy of the anterior cruciate ligament related to hamstring tendon grafts. A cadaveric study *The Knee* 2013;20:511-514.
 22. Marshall JL, Monajem A. The cruciate ligaments of the knee joint. Anatomical, functional and experimental analysis 1975.
 23. Thore Zantop, Wolf Petersen, Freddie Fu H. Anatomy of the Anterior Cruciate Ligament Oper Tech Orthop 2005;15:20-28.
 24. Anatomy of the anterior cruciate ligament. *Knee Surg Sports Traumatol Arthrosc* 2006;14(3):204-13.
 25. Nathan Mall A, Geoffrey Van Thiel S, Asheesh Bedi, Brian Cole J 2012.