



E-ISSN: 2395-1958
P-ISSN: 2706-6630
IJOS 2020; 6(4): 771-773
© 2020 IJOS
www.orthopaper.com
Received: 18-09-2020
Accepted: 24-10-2020

Dr. Amit M Bilagi
3rd Year Resident, Department
of Orthopedics, RGUHS
University, KIMS Hospital,
Bengaluru, Karnataka, India

Dr. Somashekar
Professor and Unit Chief,
RGUHS University, KIMS
Hospital, Bengaluru, Karnataka,
India

Dr. Vinaykumar Gunjalli
Senior Resident, RGUHS
University, KIMS Hospital,
Bengaluru, Karnataka, India

Corresponding Author:
Dr. Amit M Bilagi
3rd Year Resident, Department
of Orthopedics, RGUHS
University, KIMS Hospital,
Bengaluru, Karnataka, India

Rarest of the bone tumors: Chondromyxoid fibroma

Dr. Amit Bilagi, Dr. Somashekar and Dr. Vinaykumar Gunjalli

DOI: <https://doi.org/10.22271/ortho.2020.v6.i4k.2419>

Abstract

Chondromyxoid fibromas are extremely rare benign cartilaginous neoplasms with incidence <1% of all bone tumours. Most commonly seen before 30 years of age (75%) with slight male predilection. Most common location is proximal tibia (25%). Malignant degeneration is rare and high recurrence with curettage alone (80%) and four times lesser with curettage and bone grafting (20%). Case report: A 22 year old male presented with pain in the left knee since 1 year and swelling in the left leg since 6 months with no restriction of movements. Patient was investigated and lesion was confirmed to be chondromyxoid fibroma. Intraoperatively, mass was greyish with variable consistency. Curettage was done and the cavity was filled with cortico-cancellous bone graft. Histopathological examination confirmed it to be chondromyxoid fibroma and negative for malignancy. The intra and post-operative periods were uneventful. Limb was supported with long posterior slab post-operatively. Conclusion: Chondromyxoid fibromas are rare benign cartilaginous neoplasms. Hence, it is important to consider differentials. Core needle biopsy of lesion is helpful before planning the procedure as the treatment options change significantly. Counselling for recurrence and malignant transformation to sarcomas is advisable.

Keywords: Rare, neoplasm, benign

Introduction

Chondromyxoid fibroma is a rare benign cartilaginous bone tumor first described by Jaffe and Lichtenstein in 1948 [1]. Accounts for about 1% of all bone tumors and mainly affects long bones (65%), in adolescents and young adults. WHO defines it as a benign tumor characterized by lobules of spindle or stellate shaped cells with abundant myxoid or chondroid intracellular material. It is mainly composed of hydrated proteoglycans and only minor amounts of collagen which are responsible for the myxoid matrix appearance not seen in other cartilaginous tumors and hence is a different biological and clinical entity.

Most commonly seen in 2nd and 3rd decades but can be seen in any age group with slight male predominance. Metaphyseal regions of the long bones are most commonly affected (65%). Proximal tibia being the most common location (Tibia> Femur> Fibula). Approximately 20% of appendicular involvement arises in foot (phalanges and metatarsals), about 95% lesions are medullary in location. Clonal abnormalities involving Chromosome 6 have been detected.

Case History

A 22 year old male presented to outpatient with pain in the left knee since 1 year and swelling in the left leg since 6 months. Pain was dull aching in nature, non radiating and increased on running, jumping, climbing up and down stairs and relieved on rest and medications. Swelling was insidious onset, non-progressive in size, there was no history of trauma, fever, loss of appetite or loss of weight.

On examination

Fusiform swelling noted over the anteromedial aspect of left leg just below the knee measuring about 8cmx5cm with regular margins, firm to hard in consistency, non-mobile, arising from the underlying bone, skin above the swelling was pinchable. No scars, sinuses or dilated veins noted. Movements of left knee full range not associated with pain, crepitus or spasm.

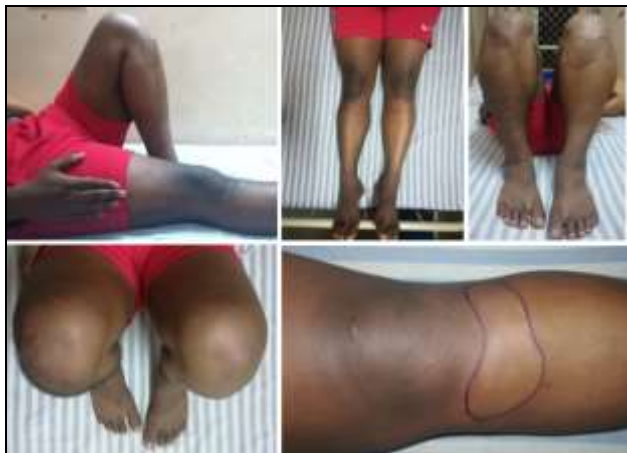

Fig 1: Clinical pictures showing extent of the lesion and movements

Investigations

X-Ray

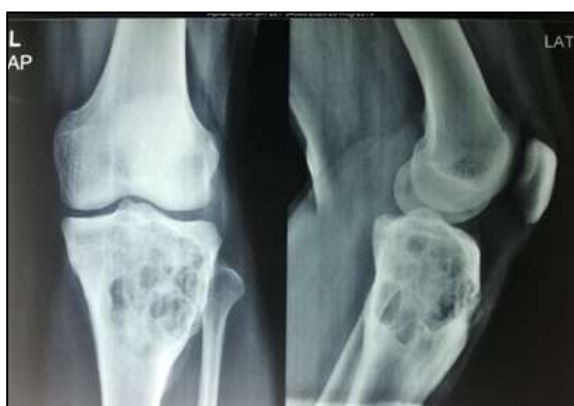

Fig 2: Fig: Pre-op X-ray

Large well defined expansile osteolytic lesion with multiple thin internal septations noted across epi and metaphysis of tibia with narrow zone of transition. No periosteal reaction or involvement of soft tissues.

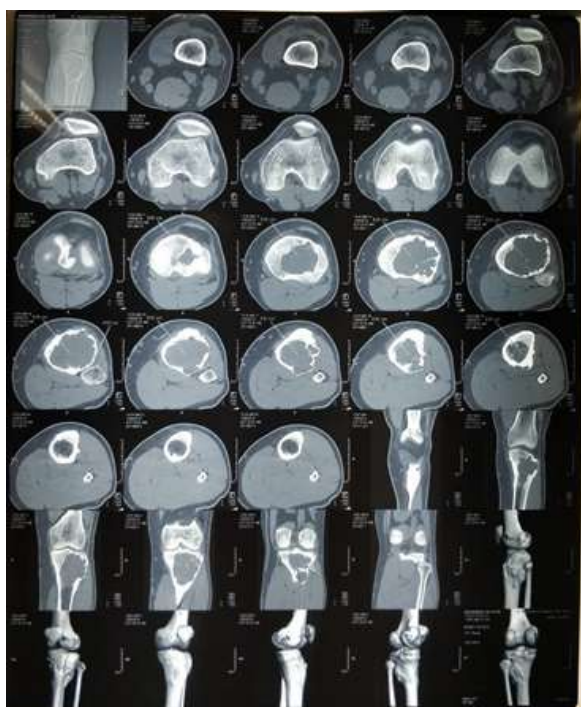

Fig 3: CT with 3D reconstruction

Computed Tomography (CT)

A well defined cystic lesion measuring 7x5.7cm noted in the metaphysis of left tibia extending into epiphysis causing cortical thinning with few internal septations. No surrounding soft tissue swelling noted, joint appears normal.

Magnetic Resonance Imaging (MRI)

A well-defined lobulated sub-articular, epi-metaphyseal, osseous lesion measuring 7.1x5x0.5 (Sagittal*transverse*AP) noted in the proximal end of tibia. The lesion is T1 hypointense, T2 hyperintense with few hypointense septations within and showing sclerotic margins. Lesion has a narrow zone of transition. Contrast study shows minimal peripheral enhancement. Superiorly the lesion is abutting the articular surface. Significant cortical thinning along postero-lateral aspect. Normal flow in the popliteal artery. Ligaments and joint appears normal.

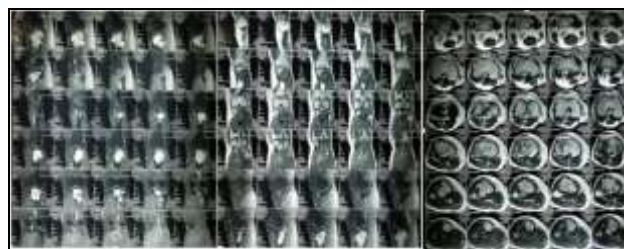


Fig 4: MRI images showing the lesion

Biopsy

Show a benign neoplasm comprising of chondromyxoid tissue arranged in lobules. The myxoid areas show stellate cells in a basophilic matrix and the chondroid areas show lacunae with chondrocytes. The periphery is hypercellular with few polyhedral cells and multinucleated giant cells.

Procedure

Under spinal anaesthesia, in supine position, with application of pneumatic tourniquet, using lateral incision, curettage done and gap filled with cortico-cancellous bone graft using fibula and iliac crest harvest.

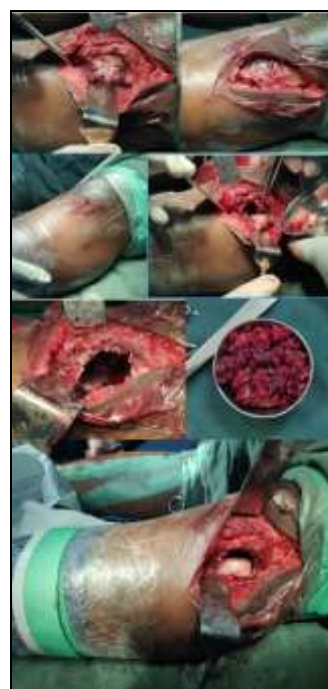

Fig 5: Intra operative pictures of curettage and bone grafting

Post-operatively limb was immobilized in long posterior slab and static quadriceps exercises begun for 4 weeks and short posterior slab for another 2 weeks and non weight bearing mobilization started. Then hinged knee brace was applied and

knee mobilization was started with partial weight bearing. At 12 weeks graft was taken up well and full weight bearing mobilization was started with no pain on weight bearing.

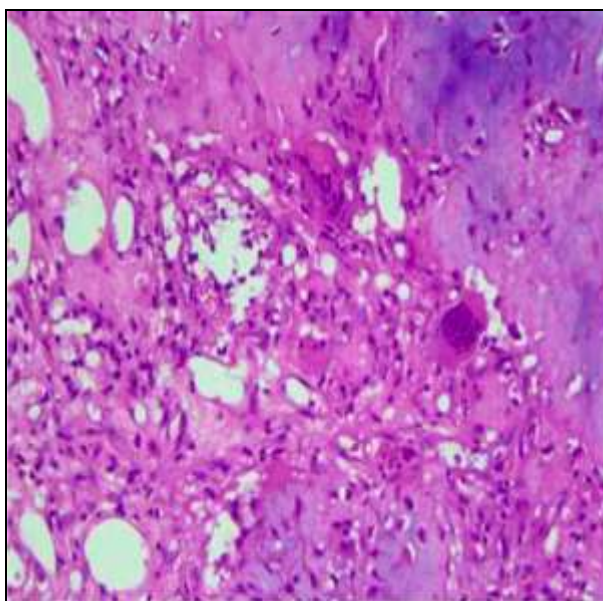
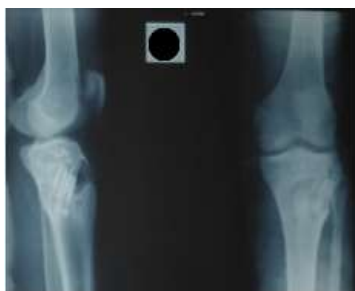

Fig 6: Histopathology of excised tumor

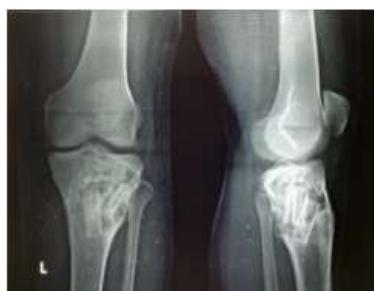Histopathology

Fragments of tumor tissue with multilobular growth pattern composed of hyaline cartilage and myxoid matrix. Focal areas with increased cellularity are noted at the periphery of lobules containing stellate to fusiform cells and osteoclast type

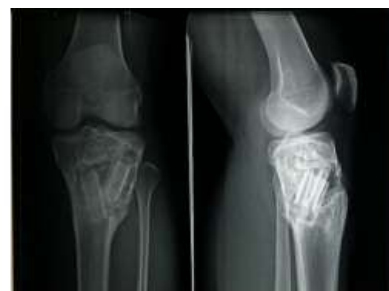multinucleated giant cells. Few larger cells with hyperchromatic nuclei are noted surrounded by increased basophilic deposits. Areas showing degenerated bone tissue are seen within tumor tissue. Rare mitosis noted. Sections are negative for granuloma or malignancy.



Immediate post-op



6 weeks post-op



12 weeks' post-op

Discussion

Chondromyxoid fibroma is a rare benign bone tumor, it is important to go ahead with the biopsy for confirmation as the treatment options change significantly. Surgery is the mainstay of treatment. Intra-lesional curettage with bone grafting is the accepted best treatment modality for this tumor. Local recurrence rate is known to be from 3% to 22% and reported to be as late as 19 years. High recurrence rate with curettage alone (80%) and 4 times lesser with curettage and bone grafting (20%). Large or recurrent lesion with an extraosseous soft tissue component may occasionally require en bloc excision to achieve adequate oncological clearance. Malignant transformation to sarcomas, even though rare, is seen in 1-2% of cases. No distant metastasis have been noted.

References

1. Jaffe H, Lichtenstein L. Chondromyxoid fibroma of bone. *Arch Pathol* 1948;45:541.
2. Campanacci M, Bertoni F, Bacchini P. *Bone and Soft Tissue Tumors*. New York: Springer-Verlag 1990.
3. Brat HG, Renton P, Sandison A, Cannon S. Chondromyxoid fibroma of the sacrum. *Eur Radiol* 1999;9:1800-1803. doi: 10.1007/s003300050925.
4. Schajowicz F, Gallardo H. Chondromyxoid fibroma of bone. A

clinico-pathological study of thirty-two cases. *J Bone Joint Surg* 1971;53:198-216.

5. Wilson AJ, Kyriakos M, Ackerman LV. Chondromyxoid fibroma: radiographic appearance in 38 cases and in a review of the literature. *Radiology* 1991;179:513-518. doi: 10.1148/radiology.179.2.2014302.
6. Durr HR, Lienemann A, Nerlich A, Stumpfenhausen B, Refior HJ. Chondromyxoid fibroma of bone. *Arch Orthop Trauma Surg* 2000;120:42-47.
7. Hau MA, Fox EJ, Rosenberg AE, Mankin HJ. Chondromyxoid fibroma of the metacarpal. *Skel Radiol*. 2001;30:719-721. doi: 10.1007/s002560100428.
8. Enneking WF, Dunham W, Gebhardt MC, Malawar M, Pritchard DJ. A system for the functional evaluation of reconstructive procedures after surgical treatment of tumors of the musculoskeletal system. *Clin Orthop Relat Res* 1993;286:241-246.