

# International Journal of Orthopaedics Sciences

E-ISSN: 2395-1958  
P-ISSN: 2706-6630  
IJOS 2020; 6(4): 395-401  
© 2020 IJOS  
[www.orthopaper.com](http://www.orthopaper.com)  
Received: 13-07-2020  
Accepted: 18-08-2020

**Dr. P Jayaram Reddy**  
Assistant Professor,  
Department of Orthopaedics,  
SVS Medical College,  
Mahabubnagar, Telangana,  
India

**Dr. KL Jagadishwer Rao**  
Professor and HOD, Department  
of Orthopaedics, SVS Medical  
College, Mahabubnagar,  
Telangana, India

**Dr. Sushruth C**  
Resident, Department of  
Orthopaedics, SVS Medical  
College, Mahabubnagar,  
Telangana, India

**Dr. KJ Reddy**  
Professor, Department of  
Orthopaedics, SVS Medical  
College, Mahabubnagar,  
Telangana, India

**Corresponding Author:**  
**Dr. KL Jagadishwer Rao**  
Professor and HOD, Department  
of Orthopaedics, SVS Medical  
College, Mahabubnagar,  
Telangana, India

## Cubitus varus deformity correction by uniplanar supracondylar humeral osteotomy with preset k-wires fixation: Our experience

**Dr. P Jayaram Reddy, Dr. KL Jagadishwer Rao, Dr. Sushruth C and Dr. KJ Reddy**

**DOI:** <https://doi.org/10.22271/ortho.2020.v6.i4f.2364>

### Abstract

**Introduction:** Cubitus varus deformity is the late complication after malunited supracondylar fracture of humerus in children. Various Osteotomies have been described in the literature and are associated with complications like nerve palsies, persistent varus deformity, infection, lateral condylar prominence, unsightly scar and loss of fixation. We report our experience for correction of cubitus varus deformity by uniplanar supracondylar humeral osteotomy and preset k-wires fixation with least complications.

**AIM:** To study the results of cubitus varus deformity correction by uniplanar supracondylar humeral osteotomy and preset k-wires fixation with least complications.

**Materials and Methods:** A prospective study of 15 cases of cubitus varus deformity were included in the study. Pre-operative assessment of Carrying Angle and Elbow ROM was done. Uniplanar supracondylar humeral osteotomy and preset k-wires fixation was done in all cases. Results were evaluated using Mitchell and Adams criteria.

**Results:** The average age at the time of injury was 5 years. The average age at corrective surgery was 6 years. The average operative time was 70 minutes. All cases were followed up till 1 year. All patients had increased carrying angle, increased elbow ROM and improved cosmetic outcome. The results were evaluated using Mitchell and Adams criteria. 1 patient had superficial pin tract infection, 1 pt had re-injury due to fall. The overall assessment showed excellent results in 80% and good results in 20% as per Mitchell and Adams criteria.

**Conclusion:** From our study we conclude that cubitus varus deformity correction by uniplanar supracondylar humeral osteotomy with preset k-wires fixation is stable, simple, effective and safe method with least complications. Hence three dimensional tri planar correction of the deformity is not required for cubitus varus deformity correction.

**Keywords:** Cubitus varus, gun stock deformity, corrective osteotomy, supracondylar humerus fracture, malunion, K-wires

### Introduction

Cubitus varus deformity is also called gun-stock deformity or bow elbow [Fig 1]. The deformity occurs as a late complication due to malunited supracondylar humerus fracture of elbow in children, with an incidence ranging from 3% to 57%. The deformity is a triplanar deformity. As the supracondylar fractures are more common in children between 5-15 years of age, the cubitus varus deformity is also common in this age group. The deformity includes internal rotation of the distal fragment (horizontal plane), medial tilting (coronal plane) and hyperextension (sagittal plane). The deformity occurs in extension type of supracondylar fracture of humerus. The internal rotation of the deformity is compensated by shoulder movements. Hyper-extension deformity remodels well. But the coronal plane varus deformity neither remodels itself nor is compensated by shoulder movements, causing cosmetic dysfunction and affecting the range of motion. Hence mainly the varus deformity (medial tilting) in coronal plane needs to be corrected. Correction of all the deformities in three planes is a technically demanding surgery and also leads to instability of the osteotomy site. Various studies also indicate no added advantages of three dimensional triplanar osteotomies over uniplanar osteotomies.

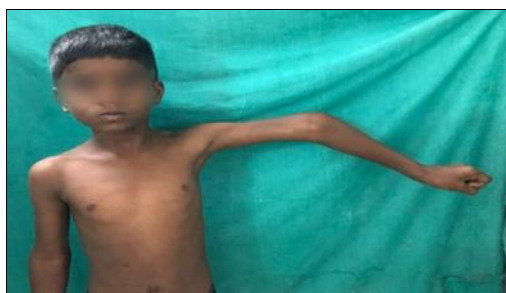There is reduction of physiological valgus with forearm deviation inwards resulting in lateral angulation at the elbow [Fig 2]. The etiology of cubitus varus includes malunited supracondylar humerus fracture (most common cause), osteonecrosis of trochlea, medial growth plate damage, secondary to exostosis in distal humerus and epiphyseal dysplasias. The malunion of the fracture occurs mostly in rotationally unstable fractures, poorly stabilised fractures, delayed neglected fractures, comminuted fractures and inadequate surgical fixation. Due to the varus deformity there is cosmetic deformity, functional limitation of elbow ROM, lateral condyle prominence, elbow instability and tardy ulnar nerve palsy. Hence surgical correction is required to avoid above complications. The deformity is graded by severity:

Grade 1 - loss of physiological valgus angle

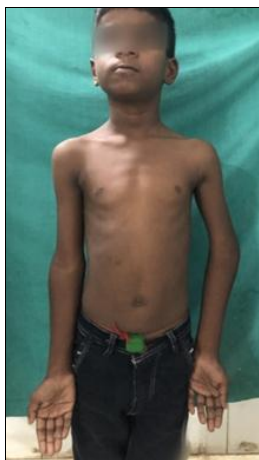Grade 2- 0 to 10 degrees of varus

Grade 3-11 to 20 degrees of varus

Grade 4-more than 20 degrees



**Fig 1:** Cubitus varus deformity



**Fig 2:** Obliteration of carrying angle with lateral angulation at left elbow.

Most of the cubitus varus deformity cases are static, triplanar and extra-articular. The deformity may be progressive in cases due to osteonecrosis of trochlea or growth arrest of medial condyle. The deformity becomes evident usually, ten to twelve weeks after the initial fracture. The deformity is noted by a definite varus with more than three months of history causing cosmetic deformity due to lateral condyle prominence. To manage this deformity various techniques of corrective osteotomies and fixation have been described. The corrective osteotomy options include medial opening wedge osteotomy [1], lateral closing wedge osteotomy (French Osteotomy) [10], dome osteotomy [18], step cut osteotomy, oblique osteotomy with derotation [7], penta lateral osteotomy [32]. The different methods of fixation of osteotomy include k-

wires, screws, plate and staples. The various approaches used are medial, lateral, anterior and posterior.

French performed lateral closing wedge osteotomy and fixation with two screws. Bellemore [11] modified French's technique by leaving the medial cortex intact. Voss *et al.*, [3] performed uniplanar supracondylar closing wedge osteotomy and fixed it with pre-set K-wires. Oblique osteotomy fixation with cortical screws was described by Amaspacher and Messenberg [7]. Three-dimensional osteotomy was described by Uchida, Ogota and Sugioka [27]. Derosa and Gaziano [8] reported good results with step-cut osteotomy and fixation with cortical screws. Song *et al.* [29], and Karatosun *et al.*, [9] used Ilizarov's technique with lateral closing wedge osteotomy in adults. Sharma *et al.*, [32] had performed pentalateral osteotomy; Rai [16] used valgus rotation osteotomy; Levine *et al.*, [28] Usai *et al.*, Handelsman *et al.*, Jain *et al.* and Goyal *et al.*, [33] used unilateral external fixator to stabilize distal fragment after wedge osteotomy; Agarwal *et al.*, [25] used biaxial external fixation.

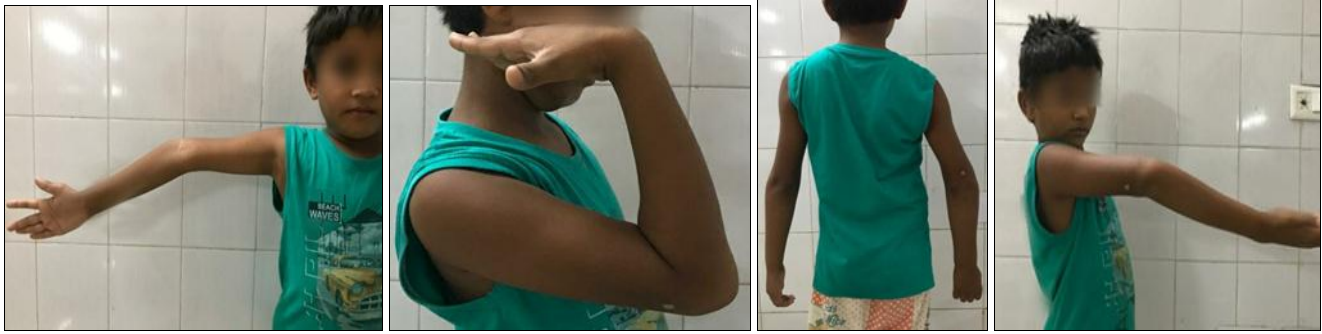Carrying angle is measured between the longitudinal axis of arm and longitudinal axis of forearm in supinated and extended position of elbow.

In order to perform a multiplanar correction, a complete osteotomy is required but this is associated with complications like nerve palsies, infection, loss of fixation, persistence of varus deformity. Hence cubitus varus deformity correction by uniplanar supracondylar humeral osteotomy with preset k-wires fixation has least complications and is stable, simple, effective and safe method.

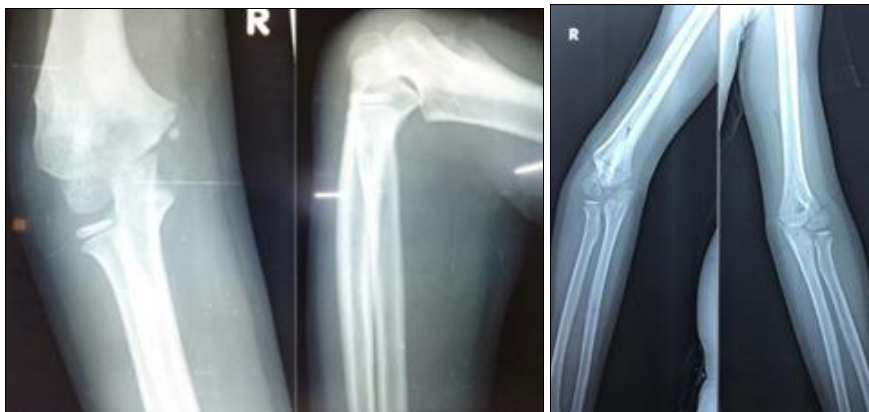In our study we are reporting a series of cubitus varus deformity cases managed by uniplanar supracondylar humeral osteotomy with preset k-wires fixation.

### Materials and Methods

Fifteen cases of cubitus varus deformity are included in our prospective study. The study includes 9 males and 6 females. The average age at the time of injury was 7 years (range four to ten years) and at the time of corrective surgery was 8 years (range five to twelve years). The deformity involved the left elbow in ten patients and right elbow in five patients. The average age of the patients in our study is 9.5 years. The inclusion criteria in our study are-age of patient 5-15 years, varus deformity due to malunited supracondylar humerus fracture. The exclusion criteria in our study are-age less than 5 years and more than 15 years, cubitus varus deformity due to other causes. Informed written consent was obtained from the parents, and ethical committee approval was taken for the study. Clinical History is obtained from the parents, physical and local examination were done, and all the cases were operated between 2015-2019. Majority of the patients underwent native treatment in the form of massages and bandages initially at the time of injury. Cosmetic deformity is the main indication for surgery. Few patients had limitation of elbow ROM. Pre-operative assessment [Figure 3] of Carrying Angle and Elbow ROM was done for all the patients and compared with the contra lateral side. Standard true antero posterior and lateral radiographs of the affected elbow [Figure 4] and normal elbow are taken. Pre-operative templating is done in every case. Post-operative radiographs are taken and, follow-up was done at 1,3,6,12 months and assessment of the cases done by Mitchell and Adams criteria [2].



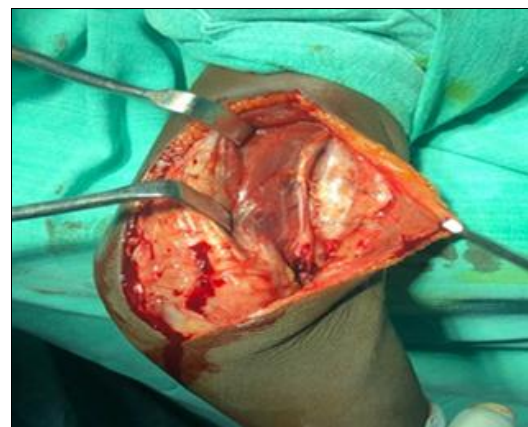**Fig 3:** Pre-operative Clinical pictures



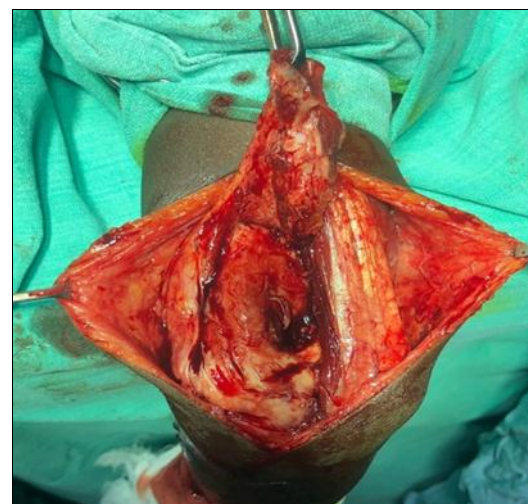**Fig 4:** Pre-operative radiograph of affected and normal elbow.

### Operative procedure

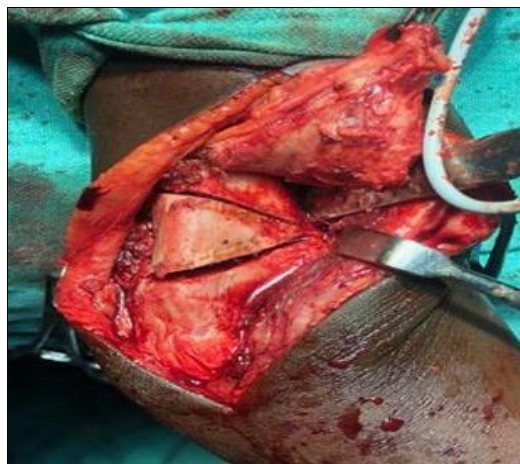
The patient is positioned in lateral decubitus position. Tourniquet is applied to the upper arm of the affected elbow. Posterior approach is used and the incision begins 5cm proximal to the olecranon in the midline of the posterior distal humerus and is extended 2cm distally below the tip of olecranon. Ulnar nerve is identified and separated [Fig 5]. The Triceps muscle is split (triceps split approach) in the midline and the reflection of the half of the triceps is done on the lateral side [Fig 6]. Under fluoroscopic guidance, one or two k-wires were preset-inserted into the lateral condyle prior to the osteotomy. An incomplete wedge of the bone was then removed, leaving the medial cortex intact [Fig 7]. With the appropriate size wedge removed from the template, an assessment for prominence of the lateral condyle could be made. If more flexion is required, more of the anterior cortex is removed. The lateral condyle prominence can be avoided by making the osteotomy more oblique and by medialisation of the distal fragment. The distal cut of the osteotomy is placed superior to the olecranon fossa. Reduction of the osteotomy is performed with a forceful valgus stress with forearm in pronation and elbow flexion. Two k-wires are then advanced from the lateral condyle into the medial cortex of the proximal fragment [Fig 8]. One k-wire is advanced from the medial condyle into the lateral cortex of the proximal fragment. Intra-operative radiographic assessment of k-wires is done [Fig 9]. Excessive periosteum is not stripped. Precautions are taken to protect the ulnar nerve and damage to the physis. All three k-wires are buried under the skin. The wound is closed in layers, and the elbow is splinted with above elbow cast in 90 degrees flexion and full pronation. Post-op radiograph taken. [Figure 10]. Elbow exercises are started as early as possible. K-wires are removed at around 4-6 weeks. Follow-up done at 1,3,6,12 months.



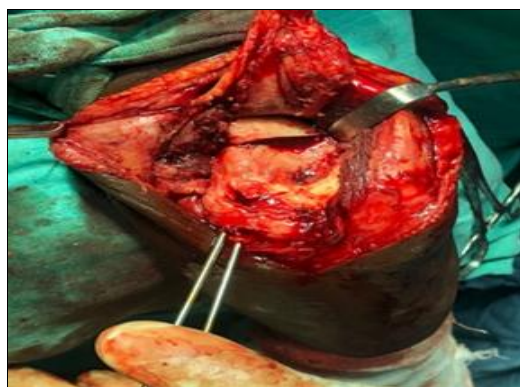**Fig 5:** Isolation of ulnar nerve on the medial side




**Fig 6:** Posterior Triceps splitting approach with reflection of half of triceps on lateral side



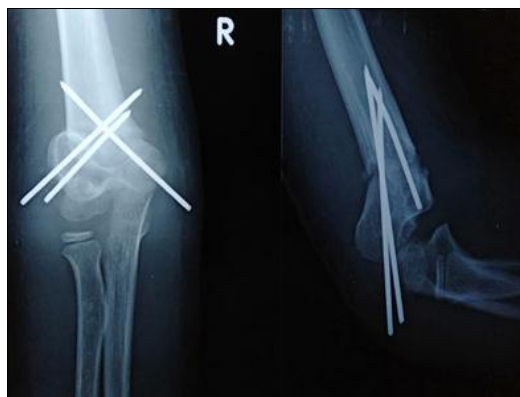**Fig 7:** Incomplete wedge of the bone is removed with intact medial cortex



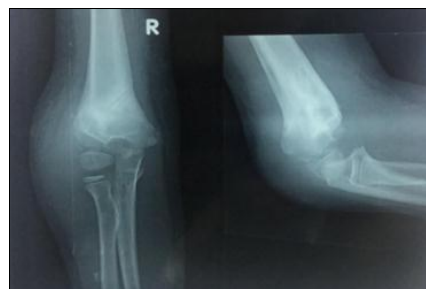**Fig 8:** K-wires fixation to the osteotomy site



**Fig 9:** Intra-operative assessment of k-wires



**Fig 10:** Post-operative radiograph



**Fig 11:** (6 months) follow up radiograph

**Results**

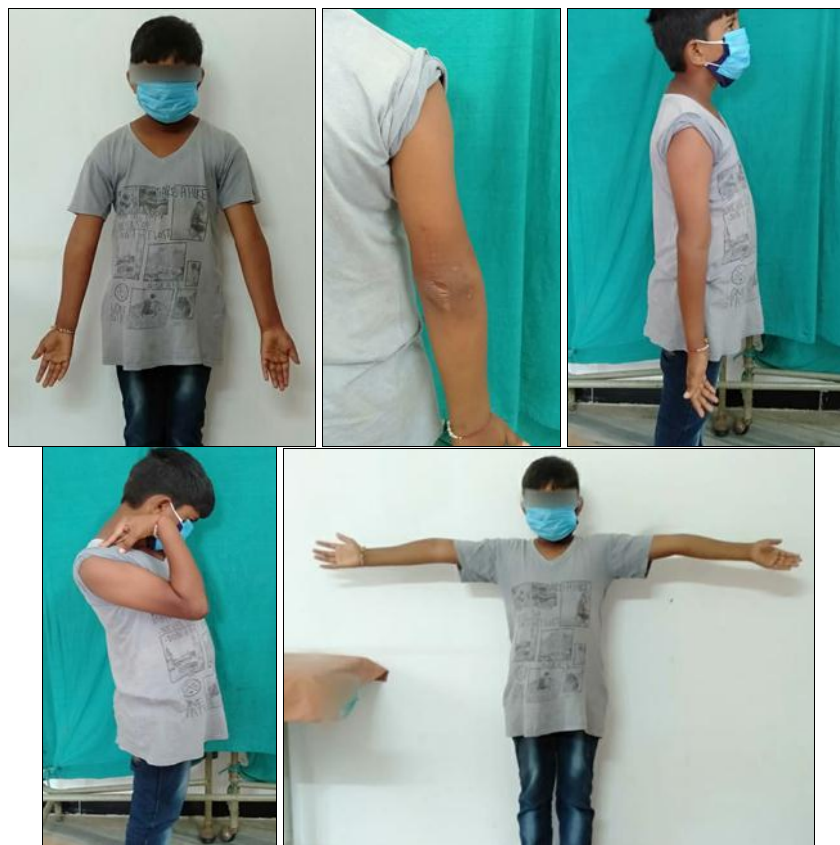All the 15 cases were followed up to an average period of 15 months (range eight months to two years)[Figure 12]. One patient had superficial pin tract infection. One patient had re-fracture. The osteotomy site was united radiologically within a mean period of six weeks (range five to eight weeks). The average carrying angle of the deformed elbow was -16.6 degrees, whereas the contra lateral elbow was 9 degrees. The average pre-operative Elbow ROM was -15 to +115. All patients achieved near normal carrying angle of the opposite elbow. There is improvement in the flexion of the elbow and there is decrease in the lateral condyle prominence. The average post-operative carrying angle was 8.7. The results of pre-operative and post-operative carrying angle are compared in the [Table 1]. The average post-operative Elbow ROM was -5 to + 125 degrees. The results of pre-operative and post-operative Elbow ROM are given in [Table 2]. No patient had scar problems.

**Table 1:** Comparison of pre-operative and post-operative Carrying angle

| S. No. | Age      | Pre-operative carrying angle | Post-operative carrying angle |
|--------|----------|------------------------------|-------------------------------|
| 1      | 5 years  | -11                          | 9                             |
| 2      | 9 years  | -20                          | 6                             |
| 3      | 7 years  | -12                          | 10                            |
| 4      | 9 years  | -18                          | 0                             |
| 5      | 8 years  | -13                          | 10                            |
| 6      | 8 years  | -15                          | 12                            |
| 7      | 6 years  | -19                          | 7                             |
| 8      | 11 years | -20                          | 13                            |
| 9      | 13 years | -14                          | 11                            |
| 10     | 14 years | -15                          | 7                             |
| 11     | 12 years | -20                          | 5                             |
| 12     | 9 years  | -25                          | 8                             |
| 13     | 15 years | -16                          | 13                            |
| 14     | 11 years | -12                          | 11                            |
| 15     | 6 years  | -19                          | 9                             |

**Table 2:** Comparison of pre-operative and post-operative Elbow ROM

| S. No. | Age      | Pre-operative elbow ROM | Post-operative elbow ROM(1 Year) |
|--------|----------|-------------------------|----------------------------------|
| 1      | 5 years  | -10 to 80               | -5 to 115                        |
| 2      | 9 years  | -20 to 100              | -10 to 120                       |
| 3      | 7 years  | -10 to 110              | -10 to 130                       |
| 4      | 9 years  | -15 to 120              | 0 to 130                         |
| 5      | 8 years  | -20 to 130              | -10 to 130                       |
| 6      | 8 years  | -15 to 120              | -10 to 125                       |
| 7      | 6 years  | 0 to 130                | 0 to 130                         |
| 8      | 11 years | -20 to 115              | -10 to 120                       |
| 9      | 13 years | -15 to 120              | 0 to 125                         |
| 10     | 14 years | 0 to 130                | 0 to 130                         |
| 11     | 12 years | -20 to 85               | -5 to 110                        |
| 12     | 9 years  | -25 to 110              | -10 to 120                       |
| 13     | 15 years | 0 to 120                | 0 to 130                         |
| 14     | 11 years | -10 to 115              | -5 to 120                        |
| 15     | 6 years  | -10 to 120              | -5 to 125                        |



**Fig 12:** Post-operative Clinical Pictures

Results were graded according to Mitchell and Adams criteria [2] as under:

**Excellent:** Change in the carrying angle of less than 5°, restriction of movement in any plane less than 10°.

**Good:** Change in the carrying angle from 5° to 15° (i.e., not beyond cubitus rectus), restriction of flexion, extension or rotation by 10° to 20°.

**Unsatisfactory:** When the changes cross the above mentioned limits.

14 patients achieved cosmetically acceptable deformity .One case had lateral condylar prominence.13 patients had normal

elbow ROM [Fig 11] and 2 patients had elbow stiffness and were later put on CPM machine and gained near normal elbow ROM.12 patients showed excellent results, 3 patients showed good results and none showed unsatisfactory results [Table 3]. No other complications like nerve palsies, persistent varus deformity, loss of fixation were noted in the study.

**Table 3:** Results according to Mitchell and Adams criteria

| Results   | No. of patients | Percentage (%) |
|-----------|-----------------|----------------|
| Excellent | 12              | 80             |
| Good      | 03              | 20             |
| Poor      | 00              | 00             |
| Total     | 15              | 100            |

**Table 4:** The results of various studies using different modes of fixation and associated complications

| Study                                  | Fixation                      | Complications                       |
|--|-------------------------------|-------------------------------------|
| Graham <i>et al.</i> , [16] cases      | LCW, and cast                 | 2 varus                             |
| Gao, 15 cases                          | LCW, and suture               | 3 undercorrected                    |
| Oppenheim <i>et al.</i> , [14]         | LCW, K-wires                  | 5 nerve palsies                     |
| Lanenskiold (23), [11] cases           | LCW, unicortical plate, rot   | 2 varus, 2 neutral, 2 re-operations |
| Labelle <i>et al.</i> , 15 cases       | LCW, K-wires, rot             | 3 loss of fixation, 3 nerve palsies |
| Rang, 20 cases                         | LCW, K-wires                  | 6 varus, 2 stiff                    |
| Carlson <i>et al.</i> [6], 12 cases    | LCW, staple                   | None                                |
| Bellemore <i>et al.</i> [11], 27 cases | LCW, K-wire, French technique | 4 infections, 3 varus, 4 scar       |
| King and Secor [1], 12 cases           | MOW                           | 3 neutral, 3 ulnar palsies          |
| DeRosa and Graziano [8], 11 cases      | SC, screw                     | 1 loss of fixation                  |
| Uchida <i>et al.</i> [27], 12 cases    | SC, screws                    | None                                |
| Kanaujia <i>et al.</i> [30], 11 cases  | Dome, K-wires                 | 2 stiff                             |

[MOW- medial opening wedge, LCW-lateral closing wedge, rot.-rotational correction, SC- step cut osteotomy.]

**Complications**

One patient had pin tract infection, other patient had re-fracture.The pin tract infection subsided sooner after antibiotics usage. The other patient with refracture was

managed by a splint for two weeks and later on had a mild varus deformity. There are no cases reported of nerve injuries and loss of fixation. Recurrence of the deformity is also not noted in any patient.

## Discussion

Cubitus varus deformity occurs most commonly due to inadequate reduction of supracondylar fracture at the time of injury. Majority of the supracondylar fractures are treated by quacks or local bone setters in the form of massages and bandages. Apart from the cosmetic deformity and functional limitation, the deformity requires surgical correction to avoid further possible complications such as ulnar neuropathy, posterolateral rotatory instability and secondary lateral condyle fractures. Remodeling of the deformity is good in children of less than ten years. O'Driscoll *et al.* reported 25 cases of adult elbows with cubitus varus who developed symptomatic posterolateral rotatory injury (PLRI) years later after their initial injury. The biomechanics are also disturbed in cubitus varus. Varus malalignment causes medial shift of mechanical axis of the upper extremity. Due to prolonged varus strain, the lateral collateral ligament complex experiences increased tensile forces, leading to further displacement of mechanical axis. The triceps is displaced medially in cubitus varus, and this displaced triceps force vector leads to an external rotation (supination) moment arm on the ulna. Chronic medial triceps forces on the olecranon lead to medial elongation of the olecranon and external rotation of the ulna, further leading to radial head subluxation. Few series found that increased cubitus varus correlated to increased proximal ulna varus as well as younger age of injury, suggesting that earlier correction of cubitus varus in the growing child may prevent other morphologic changes in the elbow.

Many corrective osteotomies have been reported in the literature for the management of post-traumatic cubitus varus deformity. Gao has operated on 15 cases with Lateral Closing Wedge osteotomy & sutures and 3 patients were undercorrected. Langenskiold [23], operated on 11 cases with Lateral Closing Wedge osteotomy (rotation correction) with unicortical plate fixation and noted 2 varus, 2 neutral and 2 re-operations. Labelle *et al.*, operated on 15 cases with Lateral closing wedge osteotomy (rotation correction) with K-wires fixation and noted 3 loss of fixation, and 3 nerve palsies. Bellemore *et al.* [11], operated on 27 cases with Lateral closing wedge osteotomy with K-wire fixation and reported 4 infections, 4 loss of fixation, 3 varus, 4 poor scars. King and Secor [1], operated on 12 cases with medial open wedge osteotomy and reported 3 ulnar palsies. Laupattarakasem *et al.* [15], operated on 57 cases with step cut osteotomy & screws fixation and noted 3 loss of fixation, 2 re-operations, 2 prominent condyles. Kanaujia *et al.* [30], operated on 11 cases with Dome osteotomy & K wires and reported 2 stiff elbows. Various complications have been noted like nerve palsies, persistent varus deformity, infection and loss of fixation with these osteotomies. French osteotomy also called the lateral closing wedge osteotomy is commonly used to correct this deformity. There is lateral condyle prominence noted post-operatively due to this procedure. This osteotomy is also unstable if not fixed adequately due to larger rotation arc for the correction. Medial opening wedge osteotomy leads to ulnar injuries. Hence we performed a safe, stable, simple and effective method for the correction of the post traumatic cubitus varus deformity by uniplanar supracondylar humeral osteotomy with preset k-wires fixation with least complications. The main indication for cubitus varus deformity is of cosmetic appearance due to prominence of the lateral condyle which is of main concern to the patient. Majority of the cases have mild functional impairment. The main goal here is to achieve a cosmetically acceptable

deformity with functional elbow ROM. The placement of preset k-wires into the distal fragment before the osteotomy with an intact medial cortex hinge allows more control of the osteotomy site. The preset k-wires fixation also reduces the chances of nerve injuries and hence is safe from nerve palsies. Though the cubitus varus deformity is a three dimensional deformity, this osteotomy is an uniplanar osteotomy. Varus malalignment can be corrected effectively, and remodeling of the flexion can be accounted upto twenty three degrees. Rotational deformity also can be corrected by this technique but complete osteotomy without any medial hinge is required for the rotational deformity correction.

Cubitus varus deformity can also occur due to growth arrest. If medial growth arrest is present, a lateral epiphysiodesis is done to reduce the risk of recurrence of the deformity. Metaphyseal osteotomy can also be done in cases with medial growth arrest.

The lateral condyle prominence, which is of major cosmetic concern to the patient can be decreased by making the osteotomy more oblique, by placing the centre of rotation closer to the joint. The distal end of the osteotomy should not traverse the olecranon fossa, as this may impair the elbow range of motion. Pre-operative templating is necessary to know the appropriate size of the wedge to be removed, and to ensure proper positioning for the osteotomy and fixation. If, on a preoperative templating, the predicted step-off appears greater than acceptable, this type of osteotomy is not used.

In our study, we found that our results are comparable to other studies in terms of improvement in carrying angle, Elbow ROM and also cosmetic appearance. The complication rates are also least in our study. The main limitations of our study are short number of cases, less follow up period of the patients and long term results need to be further evaluated.

## Conclusion

Uniplanar supracondylar humeral osteotomy with Preset Kirschner wires fixation for post traumatic cubitus varus is a safe, stable, simple and effective method with least complications. Hence three dimensional triplanar correction of the deformity is not required for cubitus varus deformity correction.

## References

1. King D, Sector C. Bow elbow (cubitusvarus) J Bone Joint Surg Am. 1951; 33:572-76.
2. Mitchell WJ, Adams JP. Supracondylar fractures of the humerus in children, a ten years review. J Am Med Assn. 1961; 175:573.
3. Kasser JR, Voss FR. Uniplanar Supracondylar osteotomy with pre-set K-wire for cubitus varus. J Paediatr Orthop. 1994; 14:47.
4. Devnani AS. Lateral closing wedge osteotomy of humerus for post traumatic cubitusvarus in children. Injury. 1997; 28:643-47.
5. Lateral closing isosceles triangular osteotomy for the treatment of a post-traumatic cubitus varus deformity in children. Su Y, Nan GBone Joint J. 2016; 98-B(11):1521-1525.
6. Carlson CS Jr, Rosman MA. Cubitusvarus: A new and simple technique for correction. J Paediatr Orthop. 1982; 2(2):199-201.
7. Amspacher JC, Messenbaugh JE. Supracondylar osteotomy of the humerus for correction of rotational and angulation deformity of elbow. South Med J. 1964; 57:845.

8. Derosa GP, Graziano GP. A new osteotomy for cubitus varus. *Clin Orthop Relat Res.* 1988; 236:160-5.
9. Karatosun V, Alekberov C, Alici E, Ardiç CO, Aksu G. Treatment of cubitus varus using the Ilizarov technique of distraction osteogenesis. *J Bone Joint Surg Br.* 2000; 82:1030-3.
10. French PR. Varus deformity of the elbow following supracondylar fracture of the humerus in children. *Lancet.* 1959; 1:439-41.
11. Bellemore M, Barrett I, Middleton R. Supracondylar osteotomy of the humerus for correction of cubitusvarus. *J Bone Joint Surg.* 1984; 66:566-72.
12. Matsushita T, Nagano A. Arc osteotomy of the humerus to correct cubitusvarus. *Clin Orthop.* 1997; 336:111-15.
13. Wong HK, Lee EH, Balasubramaniam P. The lateral condylar prominence. A complication of supracondylar osteotomy for cubitus varus. *J Bone Joint Surg Br.* 1990; 72(5):859-61.
14. Oppenheim WL, Clader TJ, Smith C, Bayer M. Supracondylar humeral osteotomy for traumatic childhood cubitusvarus deformity. *Clin Orthop Relat Res.* 1984; (188):34-39.
15. Laupatlaraksem W, Mahaisavariya B, Kowsuwon W. Pentalateral osteotomy for cubitus varus: clinical experience of new technique. *J Bone Surg Br.* 1989; 71:667-70.
16. Rai PK. Correction of cubitus varus by supracondylar valgus osteotomy. *Indian J Orthop.* 1988; 22:169.
17. Higaki T, Ikuta Y. The new operational method of the closed osteotomy for children with varus deformity of the elbow joint. *J Jpn Orthop.* 1982; 31:300-05.
18. Tien YC, Chin HW, Lin GT. Dome corrective osteotomy for cubitus varus deformity. *Clin Orthop Rel Res.* 2000; 380:158-66.
19. Noonan KJ, Jones JW. Recurrent supracondylar humerus fracture following prior malunion. *Lowa Orthop J.* 2001; 21:8-12.
20. El-Adl W. The equal limbs lateral closing wedge osteotomy for correction of cubitusvarus in children. *Acta Orthop Belg.* 2007; 73(5):580-87.
21. Kumar D, Singh S, Kumar S, Srikant TH, Rai T. Clinical outcome of dome osteotomy in cubitus varus. *MOJ Orthop Rheumatol.* 2014; 1(4):00022.
22. Hayer A. Treatment of supracondylar fracture of the humerus by skeletal traction in abduction splint. *J Bone Joint Surg Am.* 1952; 54:623-37.
23. Langenskiold A, Kivilaakso R. Varus and valgus deformity of the elbow following supracondylar fracture of the humerus. *Acta Orthop Scand.* 1967; 38:313-20.
24. Pankaj A, Dua A, Malhotra R, Bhan S. Dome osteotomy for post traumatic cubitusvarus: A Surgical technique to avoid lateral condylar prominence. *J Pediatr Orthop.* 2006; 26(1):61-66.
25. Agarwal NK, Agarwal G, Mishra AK. Bi axial external fixations of corrective osteotomy in cubitus varus. *Indian J Orthop.* 1998; 32:147.
26. Lateral closing wedge osteotomy for treatment of traumatic cubitus varus deformity in children. Yang J, He T, Liu S, Peng M, Liu M. *Zhongguo Xiu Fu Chong Jian Wai Ke Za Zhi.* 2012; 26(6):657-60. PMID: 22792757 Chinese.
27. Uchida Y, Ogota K, Sugioka Y. A new three dimensional osteotomy for cubitus varus deformity following Supracondylar fracture of humerus in children. *J Paediatr Orthop.* 1991; 11:327.
28. Levine MJ, Horn BD, Pizzutilo PD. Treatment of post traumatic cubits varus in paediatric, population with humeral osteotomy and external fixator. *J Paediatr Orthop.* 1996; 16:597-601.
29. Song SR, Cho SH, Jeong ST, Park YJ, Koo KH. Supracondylar osteotomy and Ilizarovs fixation for elbow deformity in adults. *J Bone Joint Surg Br.* 1997; 79:748-52.
30. Kannujia RR, Ilcuta Y, Muneshige H, Higaki T, Shimogaki K. Dome osteotomy for cubits vans in children. *Acta Orthop Scand.* 1988; 59:314-7.
31. Jain AK, Dhammi IK, Arora A, Singh MP, Luthra JS. Cubitus varus: Problem and solution. *Arch Orthop Trauma Surg.* 2000; 120:420-5.
32. Sharma S, Modi U, Sangwan SS, Mudgal KC. Pentalateral osteotomy for correction of cubitus varus. *Indian J Orthop.* 1995; 29:52.
33. Goyal RK, Chanda H, Pruthi KK, Sharma A. External fixator after corrective osteotomy for cubitus varus. *Indian J Orthop.* 1997; 31:159.