



# International Journal of Orthopaedics Sciences

E-ISSN: 2395-1958  
P-ISSN: 2706-6630  
IJOS 2020; 6(4): 372-379  
© 2020 IJOS  
[www.orthopaper.com](http://www.orthopaper.com)  
Received: 22-06-2020  
Accepted: 05-08-2020

**Senthilnathan Arumugam**  
Professor of Orthopaedics, Rajah Muthiah Medical College and Hospital, Annamalai University, Tamil Nadu, India

**Purushothaman Navaneethan**  
M.S Ortho-Postgraduate Student, Department of Orthopaedics, Rajah Muthiah Medical College and Hospital, Annamalai University, Tamil Nadu, India

**Prabhakar Ramabadrnan**  
Lecturer, Department of Orthopaedics, Rajah Muthiah Medical College and Hospital, Annamalai University, Tamil Nadu, India

**Vijayashankar Kaliyaperumal**  
Assistant Professor, Department of Orthopaedics, Rajah Muthiah Medical College and Hospital, Annamalai University, Tamil Nadu, India

**Corresponding Author:**  
**Purushothaman Navaneethan**  
M.S Ortho-Postgraduate Student, Department of Orthopaedics, Rajah Muthiah Medical College and Hospital, Annamalai University, Tamil Nadu, India

## Comparative study on the complications of antebrachium fractures treated with flexible nailing in paediatric and adolescent age group

**Senthilnathan Arumugam, Purushothaman Navaneethan, Prabhakar Ramabadrnan and Vijayashankar Kaliyaperumal**

DOI: <https://doi.org/10.22271/ortho.2020.v6.i4f.2360>

### Abstract

**Background:** Antebrachium fractures in paediatric age group, which are unstable are more commonly treated nowadays using intramedullary titanium elastic nailing. Recent studies have showed a higher complication rates in adolescent population when compared to the paediatric counterpart. The aim and objective of this study is to compare the complication rates and outcome in paediatric and adolescent population treated using flexible nail.

**Methods:** An ethical committee approved study was conducted in Rajah Muthiah Medical College, Chidambaram from May 2018 to September 2020 on both bone forearm fractures in paediatric and adolescent population. In our study 20 cases of both bone forearm fractures, of which 10 belonging to paediatric age group (age less than 10 years) and 10 cases belonging to adolescent age group (age more than 10 years) treated with flexible intramedullary nail (TENS). These cases were followed up for period of 1 year and complications were quantified on the basis of Clavien – Dindo classification. Outcomes were analysed based on Martus *et al.* grading system.

**Results:** Out of 20 forearm fractures treated with tens nail in each age group, mean age was found to be 13.6 years in adolescent group and 9.2 years in paediatric group. Mean follow up period were 42 weeks in adolescent category and 40 weeks in paediatric category. Average time and duration from the point of injury to the surgical procedure was 2 to 3 days in both groups. Closed reduction and internal fixation with tens nailing was done in 13 cases (8 paediatric and 5 adolescent group) and open reduction was needed in the remaining 7 cases (2 paediatric and 5 adolescent). The overall result of our study showed that complications were slightly higher in adolescent age group, when compared to the paediatric counterparts. P value between the two groups was not significant.

**Conclusion:** Tens nailing is an excellent technique for paediatric and adolescent fractures of forearm with very good functional outcome. Even though complications were seen in adolescent age group, it was significantly lower than those associated with other surgical techniques. However, with lesser complication rate in paediatric age group, we conclude that in fractures requiring surgical fixation, TENS nailing is more advantageous than other surgical options.

**Keywords:** antebrachium fractures, TENS, adolescent, paediatric, complications

### Introduction

In paediatric population, forearm fractures are one of the commonest injuries. The main goal in the treatment of these fractures is to attain an acceptable alignment which gives a good functional ROM with minimal complications. The greater number of these injuries are treated by closed reduction, followed by the application of the plaster cast. Nevertheless, when the reduction is not adequate and when there is increased deformity in angular or rotational component, which leads to the loss of movements of the forearm. In various studies, the forearm movements essential for the activities of daily living (ADL) as been mentioned [1, 2]. All these similar studies advocated that a 5° to 30° loss in pronation and 8° to 35° loss in supination will affect the ADL.

In our study, the inclusion criteria for operative treatment of these fractures were compound fractures and fractures which are not able to reduce by closed reduction methods. Based on the current guidelines, we adhere to the existing criteria for the alignment of these fractures [3].

Previous studies have already shown about the excellent efficacy of intramedullary nailing in forearm fractures [4-7]. There is no well-defined age limit upto when IM nailing can be done, but in our study, we selected patients based on physeal closure. There are many advantages of intramedullary nailing over conventional plating methods. Intramedullary nailing with TENS has the advantages of smaller incision, less operative time, shorter stay in hospital and implant removal is much easier. Nevertheless, in other studies it has been noted that patients with closed fractures treated with TENS nailing also have complications like compartment syndrome of about 10% [8]. In our study, patients with both bone forearm fractures treated with TENS nailing were taken and complications were noted in the followup. These complications were graded based on the modified Clavien-Dindo classification [9, 10] and a new grading system by Martus *et al.* [11]. Further we compared the complications between the two groups based on age (less than 10 years and more than 10 years) and assessed which age group has more complication rates.

**Methods**

Paediatric cases of age 5 to 20 years with both bone forearm fractures, admitted in RMMCH from June 2018 till September 2020 were taken in our study. 20 paediatric patients with both bone forearm fractures fulfilling the inclusion criteria were treated with intramedullary TENS nailing. Fracture is considered unsatisfactory alignment when there is cortical contact of less than 50 percent and angulation

of more than 10° in both coronal and sagittal component. Post operatively all patients were immobilised in a slab for 4 to 6 weeks. Iv antibiotics were given for three days followed by oral antibiotics for subsequent 2 days. 13 cases (8 paediatric and 5 adolescent group) were treated by closed reduction with TENS under c-arm guidance. 7 cases (2 paediatric and 5 adolescent) where closed reduction cannot be achieved open reduction was done by giving a mini incision over the fracture site. These cases were followed up for a period of 1 year. Documentation of elbow and forearm movements of flexion, extension, supination, pronation were done at the terminal follow-up. Pain with daily activities, functional disability and postoperative complications were also noted. Refracture, if any in the operated cases was considered as a complication, when it was associated with delayed union. Schmittenebecher *et al.* [12] defined delayed union as, when there is incomplete consolidation of the fracture even at 90 days. Incomplete union even after 6 months was taken as non-union. Complications were graded using a modified Clavien – Dindo classification [9, 10]. Complications which are just a deviation from the usual postoperative course and does not require an intervention are considered as grade 1. Complications which resolved with close monitoring, drug therapy and does not require any inpatient treatment are considered as grade 2. Inpatient management and reoperation which was not planned are considered as grade 3 complications. Limb or life threatening complications and treatment which resulted in an indefinite functional deficit were taken as grade 4 complications. Mortality was taken as grade 5 (Table 1).

**Table 1:** Modified Clavien-Dindo classification

Complication grade	Definition	
1	Deviation from a routine postoperative course without the need for intervention	Asymptomatic delayed union Prominent implant
2	Resolution after outpatient management, pharmacologic therapy, or close observation	Superficial infection Transient nerve palsy
3	Requiring inpatient management or reoperation	Deep infection Implant migration requiring early removal
4	Complication that is limb threatening, life threatening, or resulting in a permanent deficit	Compartment syndrome Permanent nerve palsy Radioulnar synostosis Tendon rupture
5	Death of patient	Postoperative mortality secondary to anaesthetic reaction

The outcomes were graded by a new grading system created by Martus *et al.* which takes into account both the postoperative complications graded by the modified Clavien-Dindo system [5, 13] and also the range of movements in the final follow up. 70° pronation and 85° supination was considered as a normal range [14-15]. Outcomes were said to be excellent if there was full ROM and complications less than

or equal to grade 1 as occurred. If there was less than 10° loss of movements and complications which were not more than grade 2 were considered to have good outcome. Fair outcome was said when there is a significant loss in ROM of about 10° to 30° with a complication of about grade 3 or less. Results with complications of about grade 4 or 5 and loss of ROM of more than 30° were considered to be poor outcomes. (Table 2)

**Table 2:** Martus *et al.* grading system

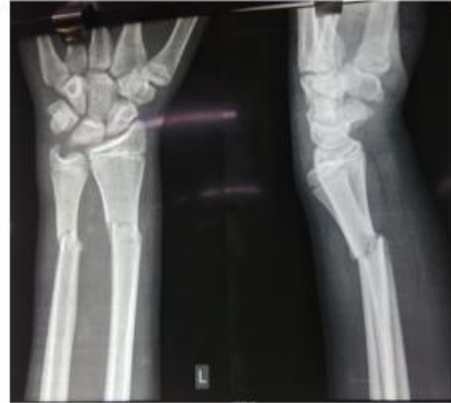Outcome Grade	Range of Motion	Complication
Excellent	Full	Grade 1 or none
Good	Loss of <10 degrees pronation and/or supination	Grade 2 or less
Fair	Loss of 10-30 degrees pronation and/or supination	Grade 3 or less
Poor	Loss of >30 degrees pronation and/or supination	Up to grade 5

Patients were grouped into two categories based on the age group, below 10 years of age as group 1 and more than 10 years of age as group 2. By statistical analysis two groups were compared and the risk factors for the particular

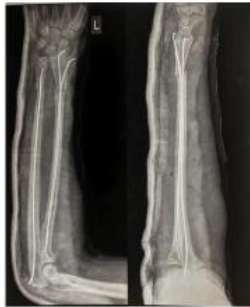complications were evaluated. Continuous variables were compared using Wilcoxon rank-sum test. Categorical variables were compared by using pearson x²test. Statistical significance was said when there was P-value of less than 0.05.

- 15 years / male
- h/o fall

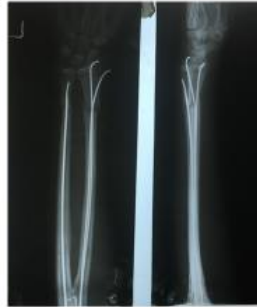PRE OP XRAY



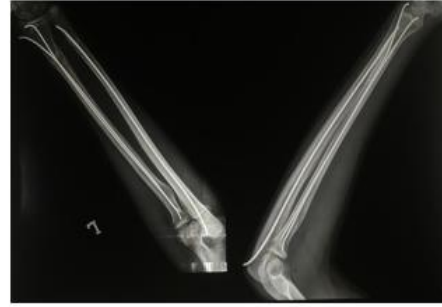Immediate Post Op



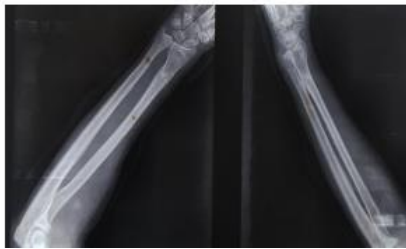1 Month Old



4 Months Old



Implant Exit

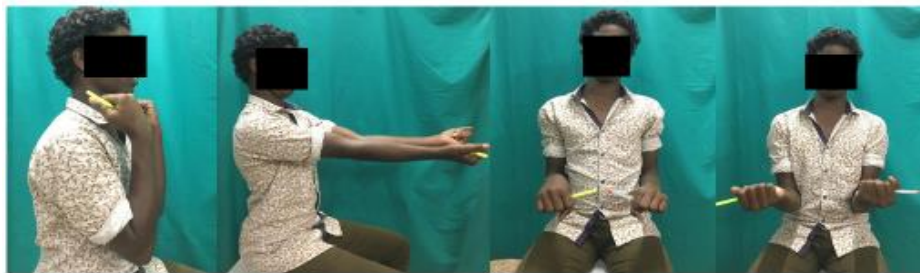

FLEXION

EXTENSION

PRONATION

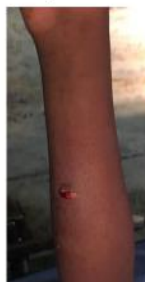SUPINATION



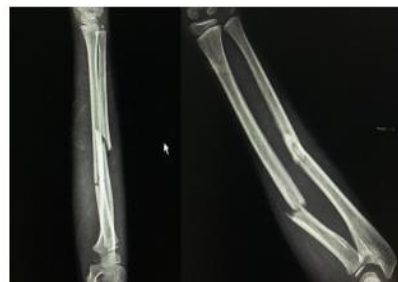**Case 1: (Adolescent group)**

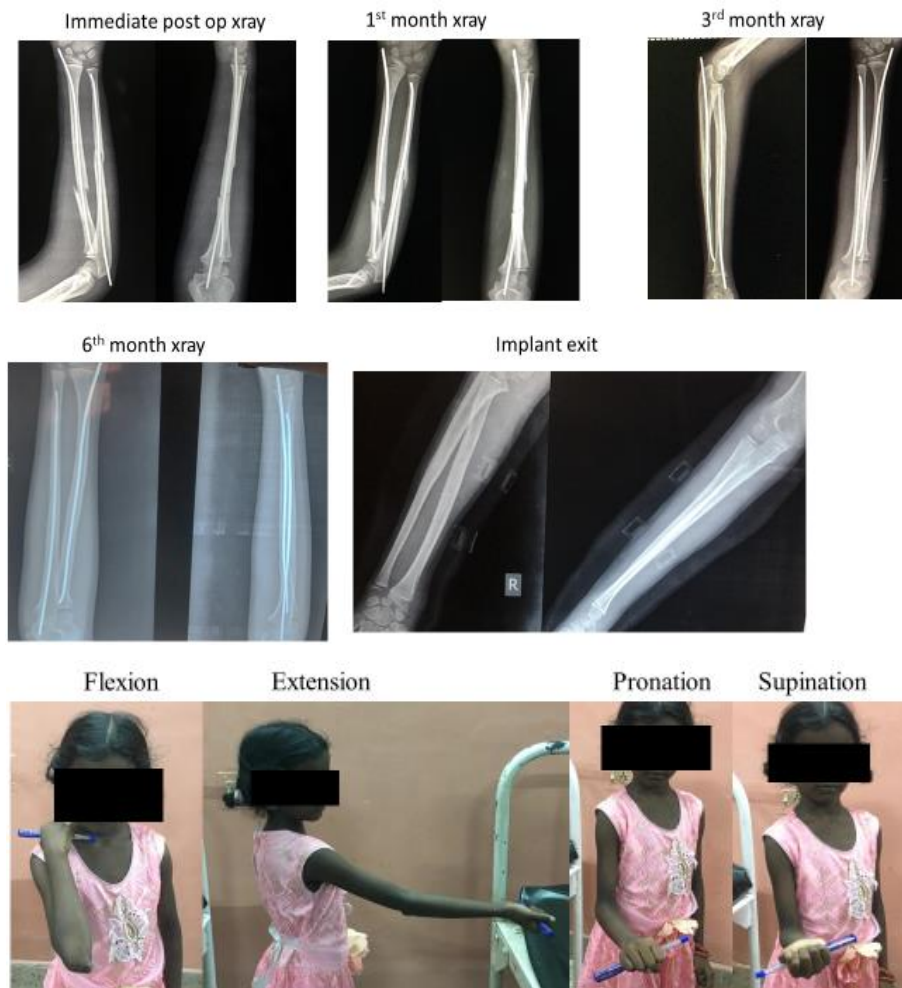- 6 years/ fch
- h/o fall

Compound wound



Pre op xray





Case 2: (Paediatric group)

## Results

20 patients of both bone forearm fractures treated operatively using titanium elastic nailing were included in our study. These patients were divided into two groups based on the age. Each group has 10 patients. Those cases which are treated by other methods are excluded from the study. Single bone fixation of both bone forearm fractures are also excluded from our study. The mean age in our study were 13.6 years in adolescent group and 9.2 years in paediatric group. The mean follow-up in our study were 42 weeks in adolescent category and 40 weeks in paediatric category. All 20 patients had unilateral forearm fractures only. Left sided fractures were predominant in our study accounting to about 65% (7 adolescent and 6 paediatric). Remaining 35% (3 adolescent and 4 paediatric) were right sided fractures. In our study male patients were predominant in both age category. 4 cases (2 adolescent and 2 paediatric) had compound injury. All compound cases were not more than grade 1.

In paediatric age group, the mechanism of injury in most of the cases were fall, followed by road traffic accident and sports injury. In adolescent age group, the mechanism of injury were road traffic accidents, followed by fall and sports injury. There were no associated injury or fracture of other long bones. Most common site of injury was middle 3<sup>rd</sup> in both adolescent and paediatric cases. In all cases, neurological deficit was not present both pre and post operatively. Compartment syndrome was not present in any case. Operative management for these fractures were commonly indicated in cases where there was a failure in conservative management or when it was a compound injury. Average time

from the point of injury to surgery was 3.2 days in both age group. Average duration of surgery was approximately 1 hour in both groups. In all cases, the ulnar entry was taken from tip of the olecranon process. Radial entry was taken at two sites, depending on the surgeon's preference, the two being lister's tubercle and a point on the lateral aspect of distal radius just proximal to the physis.

All cases were operated using titanium elastic nails, of which 2.5 mm nails were predominantly used in adolescent age group and 2.0mm nails were most commonly used in paediatric age group. Out of the 20 cases, seven cases (35%, 5 cases of adolescent and 2 cases of paediatric group) required open reduction. In our study, the ideal implant removal time was 6 months after visualising sound osseous union in radiographs. The term refracture refers to a fracture occurring after delayed union or non-union. In our study we recorded one case in adolescent group, which had refracture following delayed union with implants in situ, which was managed conservatively. This case had a pronation deficit of about 30<sup>o</sup> which improved with physiotherapy. It was classified under grade 3 complication. There was no refracture following implant removal. In our study the complication rate was 45% (3 complications in paediatric group and 6 complications in adolescent group). Out of this grade 2 complications were 35% (3 in paediatric and 4 in adolescent) followed by grade 1 and grade 3. In adolescent age group, complications were little higher than paediatric age group (P= 0.4780). Grade 2 complications like superficial pin infection (2) and implant prominent (2) complications were higher in adolescent age group. In our study there was no analytical correlation of

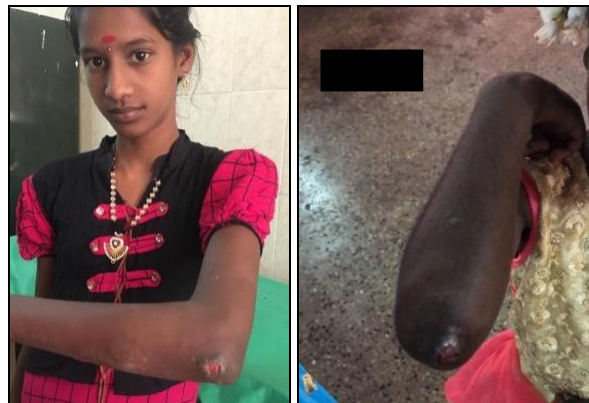delayed union with a compound fracture, location of the fracture and necessity for open reduction. The forearm rotation arc was normal in 19 cases (95%, 10 patients in paediatric group and 9 patients in adolescent group). There was deficit in motion of about 30° pronation in one patient in adolescent group (5%). In more than 95% of cases there was less than 10° of deformity at the fracture site.

There was 1 case of delayed union in adolescent group which was asymptomatic and classified as grade 1, for which no treatment was necessary. There were 3 cases of superficial infections (grade 2), out of which 1 belongs to paediatric group and remaining 2 belongs to adolescent group which was managed successfully with antibiotics. Prominent implants (grade 2) were noted in 4 cases, out of which 2 where adolescent and 2 in paediatric group. There were no neurological deficit in any patients. There were no cases of any implant migration. There were no cases of deep infections or osteomyelitis (grade 3). One case in adolescent group had delayed union which went for refracture (grade 3) and was managed conservatively in a plaster cast. There were no cases of post-operative compartment syndrome, radio-ulnar synostosis or EPL tendon rupture (grade 4) in both groups. Post-operative mortality (grade 5) was not seen in either of the age groups.

Based on Martus *et al.* grading system, 12 cases, 7 (70%) patients in paediatric group and 5 (50%) patients in adolescent

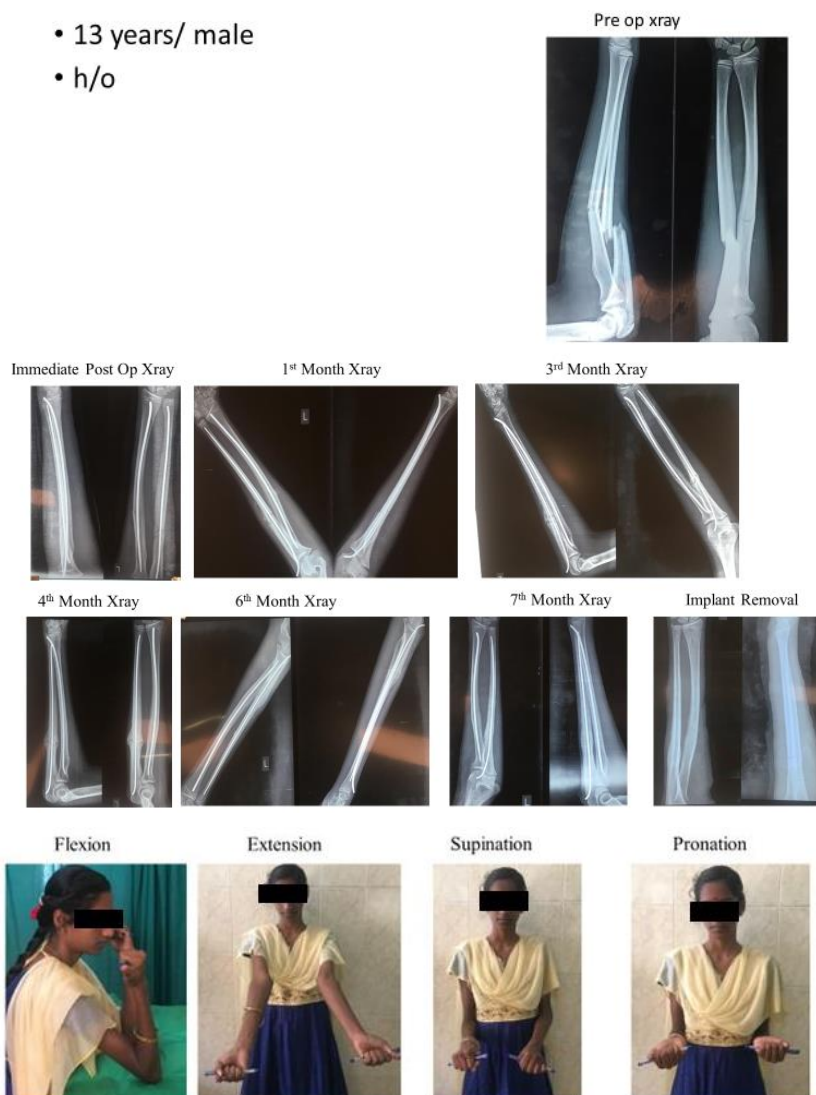
group had excellent functional outcomes. Totally 7 (35%) cases had good functional outcome, out of which 3(30%) belongs to paediatric and 4(40%) belongs to adolescent age group. One (5%) case had fair outcome which was seen in adolescent group. The P value was 0.478 and hence there was no statistical difference between the two groups.

**Grade 2 complication:**



Superficial pin infection at the ulnar entry site seen in both the age groups.

- 13 years/ male
- h/o

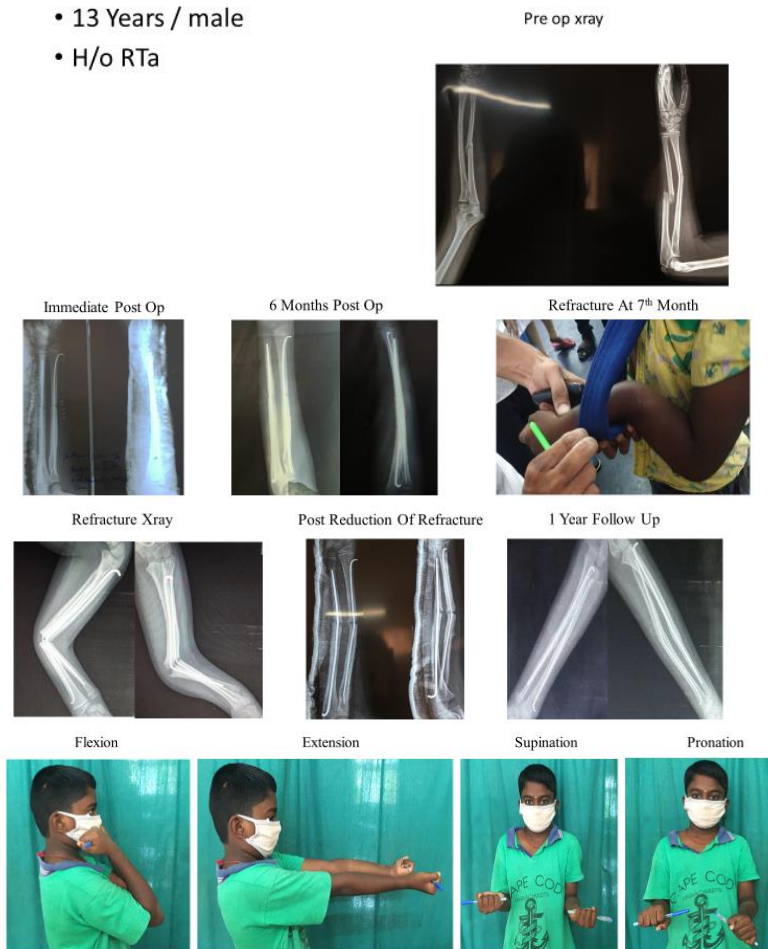


**Case 3:** (Adolescent group)

**Case 3:** A case of asymptomatic delayed union belonging to Grade 1 complication in adolescent group, which healed with conservative management and also had full range of motion.

Classified as excellent outcome according to Martus *et al.* grading system.

- 13 Years / male
- H/o RTa



**Case 4:** (Adolescent group)

**Case 4:** A case of 13 years male child belonging to adolescent group, had delayed union presented with refracture at 7<sup>th</sup> month belongs to grade 3 complication managed

conservatively with closed reduction and plaster casting and also pronation deficit classified as fair outcome.

**Table 3:** Complications and outcomes

	Age < 10 years Paediatric group N= 10 cases	Age >10 years Adolescent group N = 10 cases	P value
<b>Grade 1 complications:</b>			
Asymptomatic delayed union	0	1	
<b>Grade 2 complications:</b>			
Superficial infection	1	2	
Prominent implant	2	2	
Post-operative neuropraxia (transient)	0	0	
Implant migration	0	0	
<b>Grade 3 complications:</b>			
Deep infection	0	0	
Delayed union with refracture	0	1	
Implant migration requiring early removal	0	0	
Olecranon bursitis after removal requiring bursectomy	0	0	
<b>Grade 4 complications:</b>			
Compartment syndrome	0	0	
Radioulnar synostosis	0	0	
Extensor pollicis longus tendon rupture	0	0	
<b>Grade 5 complication:</b>			
Death	0	0	
Overall complications	3	6	0.64

Outcomes by Martus <i>et al.</i> grading system			
Excellent	7	5	0.478
Good	3	4	
Fair	0	1	
Poor	0	0	

## Discussion

Despite a significant increase in internal fixation for the treatment of diaphyseal forearm fractures, conservative management still remains the treatment of choice [8]. In our study, the complication rate was calculated at 45% (3 complications in paediatric group and 6 complications in adolescent group). This was found to be in accordance with recent studies which showed complication rates between 14% to 45% [5, 7, 16]. Clavien – Dindo classification was used to grade the complications, with appropriate changes (table 1). The defining feature of this classification was its uniformity in reporting complications and it was most commonly used in the field of general surgery [17]. Recently this classification has been used in orthopaedic studies with main regards to complications following surgical dislocation of hip [18]. This classification has the advantage in that it eliminates subjective bias related to grouping complications. The drawback of this classification was that, it has been widely accepted in general surgical studies [9, 10], however its validation in orthopaedic – paediatrics has not been well accepted. Regardless, this classification has been used in the postoperative complications of paediatric surgery [19, 20].

The most commonly used classification for diaphyseal forearm fractures was given by price *et al.* [13], which was similar to Daruwalla, Grace and Eversmann. A patient was said to have excellent functional outcome when there was no complaints and deficit in motion was less than 10°. Good result was documented, when the patient had mild discomfort with strenuous activity and the deficit in motion was in the range of 11° to 30°. Fair result was reported, when the patient had difficulties with day to day activities and the deficit in motion was between 30° to 90°. Poor result was suggested when there were more complaints and severe restriction in movements. Limitation of price *et al.* grading was that, it was basically designed for classifying results of conservative management and that it failed to take into account the post-operative complications in the final outcome. Additionally, a drawback of price grading was that deficit in forearm motion in the range of 30° to 90° was considered to be a fair outcome, however this fair grade was in reality a poor outcome with considerable disability in function with regards to ADL.

Another recent addition to these classifications was the children's hospital of Philadelphia forearm outcome score described by Flynn *et al.* [5]. According to this classification, a patient was said to have excellent functional outcome if ROM was full, which means the loss of supination and pronation was less than 10° with no complaints. A patient was said to have a fair outcome when the deficit in range of motion was less than 30° with or without a complication which was minor and resolving. Poor result was said when the deficit in motion was more than 30° with a major complication. Our study was in accordance with Flynn *et al.* in that, the deficit in motion greater than 30° was considered to be a poor outcome. Another classification called CHOP classification classified complications into major and minor categories but however we were concerned regarding their influence in the final outcome. Martus *et al.* suggested that a classification that has to be used, should not affect the final result, it should be transient and should avoid preclusion of a good final outcome.

An ideal example would be a superficial infection, resolving with oral antibiotic therapy, would not affect the final outcome and should not be classified as a fair outcome. Additionally, a delayed union which is asymptomatic and eventually unites without any surgical intervention should not be classified as a poor outcome. The basis of this system was taken from prior classifications and took into account the minimal pronation and supination needed for ADL. Raiss *et al.* [1] and Sardelli *et al.* [2] in their studies of ADL using 3D analysis came to the conclusion that, the minimum forearm rotation that was required was between 55° pronation to 72° supination. A basic definition suggested that, the normal forearm range of motion would be between 70° pronation to 85° supination [14, 15], and according to these studies a deficit of 5° to 30° pronation and a deficit of 8° to 35° supination significantly interfered with ADL and the outcome of our study was based on these data. The advantages of Martus *et al.* [11] grading system when compared with previous ones were (1) a strong emphasis that a deficit of greater than 30° means a poor outcome, (2) an objective means for stratifying complications, (3) classifying an outcome as good, if the deficit in motion was less than 10° with self-limiting post-operative complications or complications that subside on an outpatient basis. Grade 2 complications were seen in four patients of which 3 (1 in paediatric and 2 in adolescent) of them had superficial infection. There were no cases of post-operative neuropraxia or any neurological deficit.

Delayed union following TENS nailing of paediatric forearm was well documented previously and was mostly seen in the ulna, in ages above ten years, surgeries involving open reduction of the fracture site or a compound fracture [5, 7, 12, 21, 22]. Similarly, our study found correlation of delayed union with age greater than 10 years, but not with compound fracture or fractures involving open reduction.

In our study a refracture occurred in one patient with implant in-situ and it was related to a delayed union which was classified under grade 3 complication. We treated the fracture conservatively by plaster casting with the implant in-situ until the fracture united.

Radio-ulnar synostosis is a very infrequent complication of diaphyseal paediatric forearm fractures, usually seen in cases with high velocity trauma. However, we did not encounter any such complication. EPL rupture is a known complication following dorsal entry of the TENS nail in the radius [23, 24, 25]. In our study, in 6 cases (2 adolescent and 4 paediatric), the point of entry in the radius was in the dorsal aspect, however we did not encounter any case of post-operative EPL rupture. Closely associated with this entry site, is the superficial radial nerve and it is frequently affected in dorsal entry nails, nevertheless we noted no such case of post-operative neuropraxia. There were no cases of compartment syndrome neither preoperatively nor post operatively. This could be attributed to shorter operative duration which was in accordance with Yuan *et al.* [8], who suggested early conversion of closed to open reduction when the former failed.

To conclude, our study showed that the incidence in complications were slightly higher in the adolescent age group. However statistically (P= 0.478) there were no

significance between these groups. The limitation of this study was a smaller sample size, less duration of the study. A larger sample size with an extensive follow-up could yield different results. Based on our results, the usage of TENS as intramedullary nail fixation in adolescent age group yields good results even with minimal complications. Preoperative counselling regarding the possible complications should be explained to the patient before surgery.

## References

1. Raiss P, Rettig O, Wolf S *et al.* Range of motion of shoulder and elbow in activities of daily life in 3D motion analysis. *Z Orthop Unfall* 2007;145:493-498.
2. Sardelli M, Tashjian RZ, MacWilliams BA. Functional elbow range of motion for contemporary tasks. *J Bone Joint Surg Am* 2011;93:471-477.
3. Noonan KJ, Price CT. Forearm and distal radius fractures in children. *J Am Acad Orthop Surg* 1998;6:146-56.
4. Amit Y, Salai M, Chechik A. Closed intramedullary nailing for the treatment of diaphyseal forearm fractures in adolescence: a preliminary report. *J Pediatr Orthop* 1985;5:143-146.
5. Flynn J, Jones KJ, Garner MR *et al.* Eleven years experience in the operative management of pediatric forearm fractures. *J Pediatr Orthop* 2010;30:313-318.
6. Lascombes P, Prevot J, Ligier JN. Elastic stable intramedullary nailing in forearm shaft fractures in children: 85 cases. *J Pediatr Orthop* 1990;10:167-171.
7. Kang SN, Mangwani J, Ramachandran M *et al.* Elastic intramedullary nailing of paediatric fractures of the forearm: a decade of experience in a teaching hospital in the United Kingdom. *J Bone Joint Surg Br* 2011;93:262-265.
8. Yuan P, Pring ME, Gaynor TP *et al.* Compartment syndrome following intramedullary fixation of pediatric forearm fractures. *J Pediatr Orthop* 2004;24:370-374.
9. Clavien P, Barkun J, de Oliveira ML *et al.* The Clavien-Dindo Classification of surgical complications. *Ann Surg* 2009;250:187-196.
10. Dindo D, Demartines N, Clavien P. Classification of surgical complications: a new proposal with evaluation in a cohort of 6336 patients and results of a survey. *Ann Surg* 2004;204:205-213.
11. Martus JE, Preston RK, Schoenecker JG, Lovejoy SA, Green NE, Mencia GA. Complications and outcomes of diaphyseal forearm fracture intramedullary nailing: a comparison of pediatric and adolescent age groups. *J Pediatr Orthop* 2013;33(6):598-607.
12. Schmittbecher P, Fitze G, Godeke J *et al.* Delayed healing of forearm shaft fractures in children after intramedullary nailing. *J Pediatr Orthop* 2008;28:303-306.
13. Price C, Scott DS, Kurzner ME *et al.* Malunited forearm fractures in children. *J Pediatr Orthop* 1990;10:705-712.
14. Wagner C. Determination of rotatory flexibility of the elbow joint. *Eur J Appl Physiol Occup Physiol* 1977;37:47-59.
15. Youm Y, Dryer RF, Thambyrajah K *et al.* Biomechanical analyses of forearm pronation-supination and elbow flexion-extension. *J Biomech* 1979;12:245-255.
16. Smith VA, Goodman HJ, Strongwater A *et al.* Treatment of pediatric both-bone forearm fractures: a comparison of operative techniques. *J Pediatr Orthop* 2005;25:309-313.
17. Clavien P, Strasberg S. Severity grading of surgical complications. *Ann Surg* 2009;250:197-198.
18. Sink EL, Beaulé PE, Sucato D *et al.* Multicenter study of complications following surgical dislocation of the hip. *J Bone Joint Surg Am* 2011;93:1132-1136.
19. Soon IS, Wrobel I, deBruyn JC *et al.* Postoperative complications following colectomy for ulcerative colitis in children. *J Pediatr Gastroenterol Nutr* 2012;54:763-768.
20. Harraz AM, Shokeir AA, Soliman SA *et al.* Toward a standardized system for reporting surgical outcome of pediatric and adolescent live donor renal allotransplantation. *J Urol* 2012;187:1041-1046.
21. Lobo-Escolar A, Roche A, Bregante J *et al.* Delayed union in pediatric forearm fractures. *J Pediatr Orthop* 2012;32:54-57.
22. Fernandez FF, Eberhardt O, Langendoerfer M *et al.* Nonunion of forearm shaft fractures in children after intramedullary nailing. *J Pediatr Orthop B* 2009;18:289-295.
23. Pugh DM, Galpin RD, Carey TP. Intramedullary steinmann pin fixation of forearm fractures in children. Long-term results. *Clin Orthop Relat Res* 2000;376:39-48.
24. Kravel T, Sher-Lurie N, Ganel A. Extensor pollicis longus rupture after fixation of radius and ulna fracture with titanium elastic nail (TEN) in a Child: a case report. *J Trauma* 2007;63:1169-1170.
25. Cumming D, Mfula N, Jones JW. Paediatric forearm fractures: the increasing use of elastic stable intramedullary nails. *Int Orthop* 2008;32:421-423.
26. Blakemore L, Cooperman DR, Thompson GH *et al.* Compartment syndrome in ipsilateral humerus and forearm fractures in children. *Clin Orthop Relat Res* 2000;376:32-38.