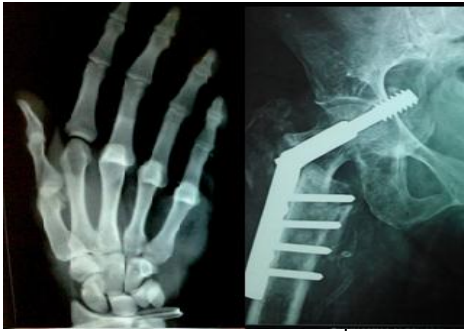

International Journal of Orthopaedics Sciences

E-ISSN: 2395-1958

P-ISSN: 2706-6630

IJOS 2020; 6(4): 415-420

© 2020 IJOS

www.orthopaper.com

Received: 26-07-2020

Accepted: 29-08-2020

Dr. Juzer Hamid

Assistant Professor, Department
of Orthopaedic, IMCHRC
Indore, Madhya Pradesh, India

Dr Susheel Kumar Soni

Assistant Professor, Department
of Orthopaedic, IMCHRC
Indore, Madhya Pradesh, India

To evaluate the treatment modality by CE angle of Wiberg in various hip joint pathologies

Dr. Juzer Hamid and Dr. Susheel Kumar Soni

DOI: <https://doi.org/10.22271/ortho.2020.v6.i4f.2368>

Abstract

Objective: To evaluate the treatment modality by CE angle of Wiberg in various Hip joint pathologies.
Method: This is a non-Randomised Prospective, observational study carried out at Department of Orthopaedics, Index medical college hospital and research centre, Indore (M.P.) during the period of 15 months from January 2018 to March 2019. Ethical clearance taken by Ethical Committee. In this study 35 hips of 28 patients who fulfilled our inclusion criteria were included. In our study patients with hip pathologies with age more than 5 years of both genders, hip pathologies like CAM and/or Pincer type of Femoroacetabular impingement, Acetabular retroversion, Perthes like deformity, Osteoarthritis Hip, Avascular necrosis of femoral head, Developmental dysplasia of hip, Patients who are doubtful for hip preservation or salvage procedure, who were willing to provide their voluntary written informed consent were included. Patients with congenital hip pathologies were excluded. In this study, we assessed the CE angle of Wiberg, in various aspheric hip conditions and formulate a protocol for further management of these Hip pathologies.

Result: In this prospective study total 28 patients (35 Hips) of various hip pathologies 21 males (25 hips) 75% and 7 females (10 hips) 25% with age range of 5 years - 65 years with mean age of 41.32 ± 18.50 years out of which males were from 5 - 65 years with mean age 40.86 ± 20.44 and females were in the age range of 23 - 52 years with mean age 42.71 ± 12.04 . Out of 28 patients 9 (32.14%) were FAI, 8 (28.57%) were OA hip, 8 (28.57%) were Avascular necrosis of Femoral head and 3 case (10.71%) is of Perthes' disease. In FAI cases 4(44.44%) patients were of Pincer type, 5(55.55%) were of Combined type with no any case of isolated CAM form. All were unilateral involvement with average CE angle of $32.67^\circ \pm 11.67^\circ$. In Pincer type mean CE angle was $36.25^\circ \pm 7.5^\circ$ while in combined form the mean CE angle was $29.8^\circ \pm 14.4^\circ$. Out of 4 patients of Pincer FAI, 3 patients of Pincer type had CE angle between $25^\circ - 40^\circ$ which comes under normal range of CE angle so all were planned for non-operative management.

Conclusions: We have found that all the hip pathologies reported to us had spectrum of variations in CE angle depending on the severity of disease. Variation was maximum seen in Osteoarthritis and Femoroacetabular impingement, in the cases of FAI maximum were of Pincer type.

Keywords: Hip joint, trendelenberg gait, CE angle of Wiberg, osteoarthritis

Introduction

Hip joint is a ball and socket variety of synovial joint. The head of femur forms more than half a sphere, sphericity of head of femur is very important aspect in function and biomechanics of hip joint. Biomechanically, a round head act as a fulcrum. The factors influencing both the magnitude and the direction of the compressive forces acting on the femoral head are

- (1) The position of the center of gravity
- (2) The abductor lever arm, which is a function of the neck-shaft angle
- (3) The magnitude of body weight. Shortening of the abductor lever arm through coxa valga or

Excessive femoral anteversion will result in increased abductor demand and therefore increased joint loading. If the lever arm is so shortened that the muscles are overpowered, then either a gluteus medius lurch (the center of gravity is brought laterally over the supporting hip) or a pelvic tilt (Trendelenberg gait) will occur. Aspheric head leads to weak abductor lever arm, and the sphericity has to be corrected or abductor lever arm is to be corrected, for deciding upon this we need to see the CE angle of Wiberg.

Corresponding Author:

Dr Susheel Kumar Soni

Assistant Professor, Department
of Orthopaedic, IMCHRC
Indore, Madhya Pradesh, India

The CE angle of Wiberg is an excellent method of studying the development of hip joint in radiograms [1]. It is simple and unlike other measurements, Bruckl *et al.*, (1972) [2] showed that only a few lines to be drawn on the radiogram [1].

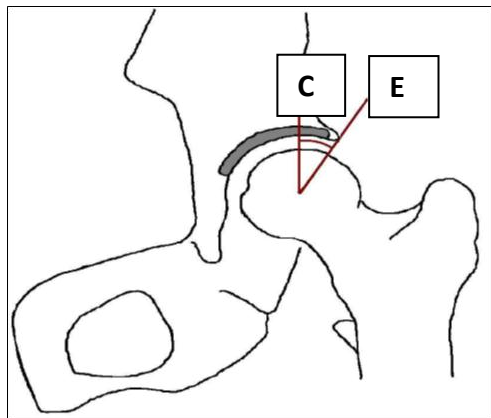


Fig 1: Showing CE angle of Wiberg

The center edge angle (CE) was introduced by Wiberg in 1939 as a measure of acetabular development and high degree of displacement of femoral head. It has been employed almost exclusively in relation to developmental dysplasia of hip previously called as congenital dislocation of hip and CE angle here distinguishes normal and so called dysplastic hips. Wiberg (1939) [3] stated that values over 25° were normal in adults and values between 20° and 25° were uncertain. This has been confirmed in other investigations. Severin (1941) [4], Wiberg (1944) (1953) [5, 6], Davis W (1970) [7], Fredensborg (1976) [1]. In children under 15 years of age, 20° or more should be considered as normal with a range of 15° to 20° [1]. By noting the CE angle we are able to decide upon the further management of the affected Hip. In this study, we assessed the CE angle of Wiberg, in various aspheric hip conditions and formulate a protocol for further management of these Hip pathologies.

Material and Method

This is a non-Randomised Prospective, observational study carried out at Department of Orthopaedics, Index medical college hospital and research centre, Indore (M. P.) during the period of 15 months from January 2018 to March 2019. Ethical clearance taken by Ethical Committee. After getting their due approval the study was initiated in their institution. Total 36 patients of non-traumatic pathological hip pain had reported to us and out of which only 35 hips of 28 patients who fulfilled our inclusion criteria were included. In our study patients with hip pathologies with age more than 5 years of both genders, hip pathologies like CAM and/or Pincer type of Femoroacetabular impingement, Acetabular retroversion, Perthes like deformity, Osteoarthritis Hip, Avascular necrosis of femoral head, Developmental dysplasia of hip, Patients who are doubtful for hip preservation or salvage procedure, who were willing to provide their voluntary written informed consent were included. Patients with congenital hip pathologies were exclude. The patients were examined in OPD and after examination were sent for radiographs. Which were done under supervision. Plain upright Antero-posterior Pelvis views were obtained with legs positioned in neutral abduction-adduction along the functional axis. The x-ray beam was centered two finger breadths above the symphysis pubis in the vertical midline with a source to film distance of 120 cm in all cases. All the 28 patients with plain upright AP

pelvis, their radiographs were obtained with the neutral rotation of femurs. When measuring the lateral center edge angle the pelvic obliquity is adjusted. Lateral center edge angle is formed by line perpendicular to the tilt of the pelvis and through the center of femoral head, for correct measurement draw a right angled line through the inferior aspect of the obturator foramina and the center of the femoral head and a line from the center of the femoral head to the lateral aspect congruent sourcil. Sourcil is the lateral acetabular border at the lateral margin of the dense zone of acetabular roof.

Measurements on radiographs

The center of femoral head was determined with a spherical template on digital radiographs by placing the radius of the template congruent with the aspect of head contained by the acetabulum while ignoring the increasing lateral and anterior radius associated with CAM type femoroacetabular impingement deformities. AP radiographs were corrected for leg- length inequality or obliquity by determining the vertical bases on a plane perpendicular to a line through the ischial tuberosities, tear drops or inferior border of the obturator foramina depending on which was more symmetric and assessable. The CE angle was formed by the intersection of vertical line through the center of the femoral head with the line extending to the lateral edge of the sourcil. In addition, a note was made on the presence of coxa profunda, Protrusio and a retroverted acetabulum. Coxa profunda was identified when the floor of the acetabulum was on or medial to the ilio-ischial line [8]. Protrusio was identified when the femoral head was on or medial to the ilio-ischial line [8]. Acetabular retroversion was identified when a crossover sign was present. The crossover sign was present when the anterior wall of the acetabulum crossed the posterior wall of the acetabulum [9].

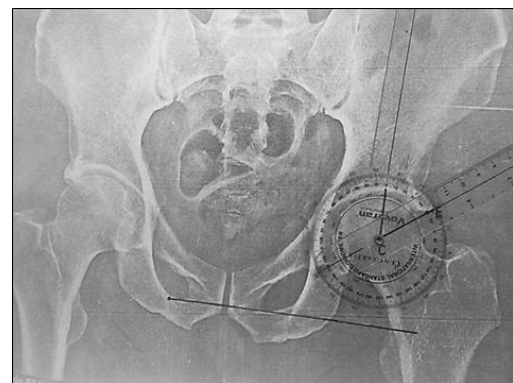


Fig 3: Method of measurement of CE angle by goniometer

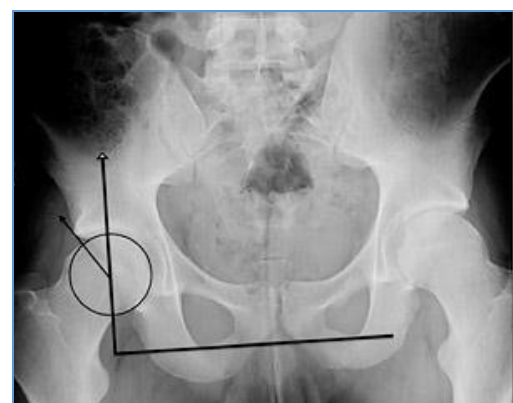

Fig 4: Measurement of CE angle on the x-ray mouse template

On the next follow-up, the X-rays were repeated, but were blinded and randomized from the examiner and presented as a fresh case, after one week cases were examined by other colleague x-rays are repeated in same manner and then after measurements these cases were matched with the previous X-ray readings. Both the x-rays are discussed in our clinical meetings of our institute for decision making according to the CE angle of the patient.

Statistical analysis

Appropriate statistical analysis was done by using MS-OFFICE 2010 and SSPS version 21. ANOVA test was applied for the comparison of CE angle between Hip pathologies and CHI-SQUARE test was applied for the association between the hip pathologies and treatment applied.

p value of <0.05 was considered as statistically significant.

Result

In this prospective study total 28 patients (35 Hips) of various hip pathologies 21 males (25 hips) 75% and 7 females (10 hips) 25% with age range of 5 years - 65 years with mean age of 41.32 ± 18.50 years out of which males were from 5 - 65 years with mean age 40.86 ± 20.44 and females were in the age range of 23 - 52 years with mean age 42.71 ± 12.04. Out of 28 patients 9 (32.14%) were FAI, 8 (28.57%) were OA hip, 8 (28.57%) were Avascular necrosis of Femoral head and 3 case (10.71%) is of Perthes' disease. In FAI cases 4 (44.44%) patients were of Pincer type, 5 (55.55%) were of Combined type with no any case of isolated CAM form. All were unilateral involvement with average CE angle of 32.67 ° ± 11.67 °. In Pincer type mean CE angle was 36.25 ° ± 7.5 ° while in combined form the mean CE angle was 29.8 ° ± 14.4 °. Out of 4 patients of Pincer FAI, 3 patients of Pincer type had CE angle between 25 - 40 ° which comes under normal range of CE angle so all were planned for non-operative management. One patient had CE angle of >40 ° so he is planned for periacetabular osteotomy. No patients found of CE angle <20 ° and 20 - 25 ° in Pincer FAI. Five patients were of combined FAI of which 2 patients had CE angle of <20 ° so they were planned for Total Hip Replacement procedure. One patient had CE angle between 20 - 25 ° so that he was planned for hip salvage procedure. One patient had CE angle in range of 25 - 40 ° which undergone non operative management. Single patient had CE angle of >40 ° which shows acetabular over coverage had planned for Total hip Replacement. Eight cases (12 hips) were of OA, four patient (50%) cases were of unilateral involvement and 4 (50%) cases had bilateral involvement. Mean CE angle in OA hip is 40.42 ° ± 10.54 ° in males mean CE angle is 35 ° and in females mean CE angle is 44.29 °. Out of 8 cases (12 hips) one patient had CE angle between 20 - 25 ° were planned for hip replacement procedure. Four patients (5 hips) had CE angle of 25- 40 °

which falls under normal range were managed by non-operative treatment except one case in which hip replacement done due to Protrusio acetabuli. Five patients (6 hips) had CE angle of >40 ° which shows over coverage had undergone hip replacement procedure. Eight patients (11 hips) of avascular necrosis of femoral head with 5 (62.5%) cases were unilateral affection and 3 (37.5%) cases were bilateral affection, all the cases were males. Average CE angle in AVN is 36.64 ° ± 16.5 °. Out of eight, two patients had CE angle <20 ° were planned for hip replacement procedure, one patient had CE angle between 20 - 25 ° which falls below normal range but due to Protrusio acetabuli, Hip replacement procedure was planned. Three patients (4 hips) had CE angle in range of 25 - 40 ° of which two hips were treated by Core decompression and fibular grafting and two hips were underwent Rotational femoral osteotomy procedure. Three patients (4 hips) had CE angle of >40 ° of which three hips which have CE angle ≤45 ° were treated by osteotomy procedure and one hip which had CE angle of >50 ° was planned for hip replacement procedure. In our present study period of 15 months, three male patient of Perthes' disease were seen, all the patients had unilateral affection, with a mean CE angle of 13.67 ° ± 4.04 °. Two patients were in the age group of 5-8 years, one had CE angle of 10 ° for which the principle of treatment is containment of head so he was planned for osteotomy procedure, other one had CE angle of 18 ° was continued with abduction braces, after 3 consecutive follow-ups of 6 - 8 weeks his CE angle remains same. One patient is of 11 years of age and had CE angle of 26 ° at time of presentation, which falls under the normal range so non operative treatment was planned till further follow-up. After 12 weeks of follow-up his CE angle was progressively decreases to 15 °, again after 4 weeks CE angle reduced by 2 ° so for the containment of head, patient was planned for Varus osteotomy procedure. After hip salvage surgery CE angle was maintained at 13 ° on follow-up of 36 weeks.

Table 1: Hip pathologies

S. No.	Hip pathology	No. of cases	Percentage
1	Femoroacetabular impingement	9	32.15
2	Osteoarthritis	8	28.6°
3	Avascular necrosis of femoral head	8	28.6°
4	Perthes' Disease	3	1°7°
	Total	28	1°°

Table 2: Femoroacetabular impingement

Types of femoroacetabular impingement	No.	Percentage
Pincer	4	44.44%
CAM	°	°
Combined	5	55.55%
Total	9	1°°%

Table 3: Comparison in the center edge angle (statistical analysis)

Hip pathology	Mean CEA (in degrees)	Standard deviation (in degrees)	ANOVA test P. value
Femoroacetabular impingement	32.67	11.67	°.°23*
Osteoarthritis hip	4°.42	1°.54	
Avascular necrosis of femoral head	36.64	16.5°	
Perthes' disease	13.67	4.°4	

* P value < 0.05 statistically significant. (CE Angle between the groups of hip pathologies is statistically significant p = 0.023.)

Table 4: Center edge angle (statistical analysis)

S. No.	Hip Pathology CE Angle Mean \pm SD(in Degrees)	Hip Pathology CE Angle Mean \pm SD(in Degrees)	Post Hoc Bone Ferroni Test Significance	ANOVA Test
1.	FAI 32.67 \pm 11.67	OA 4 $^{\circ}$.42 \pm 1 $^{\circ}$.54	1. $^{\circ\circ}$	$^{\circ}$.23*
2.	FAI 32.67 \pm 11.67	AVN 36.64 \pm 16.5 $^{\circ}$	1. $^{\circ\circ}$	
3.	FAI 32.67 \pm 11.67	Perthes' 13.67 \pm 4. $^{\circ}$ 4	$^{\circ}$.199	
4.	OA 4 $^{\circ}$.42 \pm 1 $^{\circ}$.54	AVN 36.64 \pm 16.5 $^{\circ}$	1. $^{\circ\circ}$	
5.	OA 4 $^{\circ}$.42 \pm 1 $^{\circ}$.54	Perthes' 13.67 \pm 4. $^{\circ}$ 4	$^{\circ}$.17*	
6.	AVN 36.64 \pm 16.5 $^{\circ}$	Perthes' 13.67 \pm 4. $^{\circ}$ 4	$^{\circ}$.58	

*P value < 0.05 is statistically significant (CE Angle between the groups of hip pathologies is statistically significant p = 0.023.)

Table 5: Treatment plan (statistical analysis)

Hip pathology	Treatment plan			Total no. of hips
	Non-operative	Hip salvage	Hip replacement	
Femoroacetabular impingement	4	2	3	9
Osteoarthritis hip	4	$^{\circ}$	8	12
Avascular necrosis of femoral head	$^{\circ}$	7	4	11
Perthes' disease	1	2	$^{\circ}$	3
Total	9	11	15	35

Chi-Square test value 16.397 (Association between all the hip pathologies and the different modalities of treatment done is statistically significant p = 0.012.)

Discussion

The center edge angle of Wiberg is a measure of depth of the acetabulum and the cover of femoral head. Wiberg, first described the center edge angle as a measurement of acetabular coverage using transparent spherical templates, of Mose circles, with angles in 5 $^{\circ}$ increments from 0 - 45 $^{\circ}$ [9]. He stated that, "In a normal hip joint and in the joints with a maldeveloped acetabular roof, the femoral head is always spherical enough to enable practically exact determination of its center [10]. Wiberg originally described the center edge angle in adults that has been used as index of hip dysplasia since it was first reported. He showed a direct correlation between the degree of dysplasia and subsequent rate of osteoarthritis development [10]. In our present series we observed that male: female distribution is 75%: 25% as compared to the series of Mandal *et al.*, (1996) [11]. Where it was 69%: 31%, it concurrence with the fact that etiologically also in these conditions male preponderance is common. In our series we had 21 males and 7 females in the age group of 5 - 65 years and mean age of males was 40.86 \pm 20.44 years and mean age in females found to be 42.71 \pm 12.04 years. While in Mandal *et al.*, (1996) [11] series the age group found was between 18 - 73 years. He found in their study that the distribution of CE angles was similar in males and females and the expected shift to the left in the distribution curve of females not occur in Indian adult hip population [11]. The clinical usage of Wiberg's center edge angle has evolved to differentiate not only between normal and deficient acetabuli but also over covered acetabuli. The lateral center edge angle measured on the AP radiograph may distinguish between acetabular insufficiency (<20 $^{\circ}$; 21 - 24 $^{\circ}$ = borderline) [11 - 14] versus lateral acetabular over-coverage (>40 $^{\circ}$) on the other extreme [15, 16]. Our series also showed a spectrum of variations in the CE angle measurement.

The CE angle of Wiberg studied in the adult Indian population by Mandal *et al.*, (1996) [11] found that in 83% the CE angle was between 28 - 42 $^{\circ}$ and none of the hips had CE angle of <20 $^{\circ}$, whereas in our series 37.5% of patients had

CEA between 25 - 40 $^{\circ}$ and 34% patients had CEA of >40 $^{\circ}$, 20% of the patients had CEA <20 $^{\circ}$ and 8.5% had CEA between 20 - 25 $^{\circ}$. In our series of various Hip pathologies we found that distribution of FAI: 32%, OA: 29%, AVN: 28% and Perthes' disease: 11% had great variation in the Mean CE angle, it is highest in OA: CEA 40.42 \pm 10.54 $^{\circ}$ and lowest in Perthes' disease: CEA 13.67 \pm 4.04 $^{\circ}$ whereas in FAI mean CEA was found to be 32.67 \pm 11.67 $^{\circ}$ and in AVN it is 36.64 \pm 16.50 $^{\circ}$. We found that variations in the CE angle among the hip pathologies is statistically significant p = 0.023. Femoroacetabular Impingement was most commonly encountered problem in our series with 32% cases with mean CE angle of 32.67 \pm 11.67 $^{\circ}$. Osteoarthritis hip, (29%) was next most common pathology found, with mean CE angle of 40.42 \pm 10.54 $^{\circ}$. Harris M *et al.*, (2011) [17] found in their study that insufficient acetabular coverage of the femoral head associated with acetabular dysplasia, excessive acetabular coverage of femoral head associated with Pincer FAI or an abnormally shaped proximal femur associated with the Cam FAI are proposed to contribute the abnormal stress patterns within the Hip joint, Leading to degeneration of articular cartilage And eventually OA. In our series we found that in Femoroacetabular impingement, Pincer FAI was more common than the CAM FAI. Pincer FAI results from a general or a localized over coverage of femur, general over coverage may be caused by global acetabular retroversion or a deep acetabulum, represented by Coxa profunda or Protrusio acetabuli [17]. Pincer FAI was more common condition encountered because many of these patients are engaged In the activities that require extreme range of motion, especially squatting position, yoga, which in mainly prevalent in Indian Population.

Chung *et al.*, (2010) [17, 18] reported that, In Pincer FAI people with CE angle >40 $^{\circ}$ have 2.3 times higher risk of developing OA than the people with CE angle between 20 $^{\circ}$ and 40 $^{\circ}$. Gossvig *et al.*, (2010) [19] similarly reported that those with CE angle >45 $^{\circ}$ have 2.4 times higher risk of developing OA. Boone GR *et al.*, (2012) [20] studied that Lateral center edge angle of Wiberg greater than or equal to 40 $^{\circ}$ accurately

predicts acetabular over coverage and the need for chilectomy for the treatment of Femoroacetabular impingement. In our series all the patients of FAI and OA which had CEA of $>40^\circ$ are considered as pathological, so in these patients of FAI, Hip salvage procedure in the form of osteotomy had been done, and in OA, amongst these patients increased acetabular reaming across the rim was done during Total Hip Arthroplasty. It was useful to note that the change in the CE angle in cases where THA is contemplated, Pre-operatively helps us to determine the need of reaming or additional acetabular fixation, for ex. In cases of Protrusio, the amount of graft or mesh to be incorporated can be assessed pre-operatively. Osteonecrosis of the femoral head or AVN is a condition where head is usually deformed, and it leads to OA hip if remain untreated. Here the CE angle changes are attributed to diagnose the early stage of disease and changes seen in the CE angle will help us to determine, how long can we wait for alternative hip salvage management or replacement procedure. In our series the mean CE angle in AVN was $36.64 \pm 16.50^\circ$ the patients with CE angle $\leq 20^\circ$ and $\geq 45^\circ$ were undergone Total hip arthroplasty and patients which had CE angle between $35 - 45^\circ$ were undergone Rotational femoral osteotomy. Tonnis D (1976) [21] stated that the Wiberg angle is an index of the utilization of the acetabulum. In the transmission of the vertical pressure, the only part of the acetabulum that is of importance is that which covers the cranially-directed part of the femoral head. If the acetabulum is considered a hemisphere, how much of the hemisphere covering the vertical directed part of the femoral head can be determined, for ex. With a CE angle of 36° it would be 79 per cent, with a CE angle of 31° it would be 76 per cent.

Amanatullah DF *et al.*, (2011) [22] demonstrated that in osteonecrosis of femoral head center-edge hip angle of 30° or less increases the risk for femoral head collapse and conversion to THA. We found that the osteotomy did not adversely change the acetabular anatomy or present technical difficulties that would have compromised the results of total hip arthroplasty. The osteotomy preserves excellent bone stock. After early to intermediate-term follow-up, Rotational acetabular osteotomy for the treatment of extensive osteonecrosis with collapse of the femoral head in young patients was associated with improvement in symptoms and a delay in the need for total hip arthroplasty [23]. Longer follow-up will be necessary to document the persistence of these results over time. Nozawa M *et al.*, (2005) [23] says that we believe in achieving adequate acetabular coverage of the viable lateral portion of the femoral head was the most important factor in achieving a good clinical result. In comparison with varus osteotomy, the rotational acetabular osteotomy is not associated with shortening of the involved limb, and full coverage of the femoral head (by a mean post-operative center-edge angle of 55°) can be achieved without abduction insufficiency.

Lastly in our study series very few cases of Perthes' disease were found in limited study time, Perthes' disease usually affects the young children, and adolescents, and bearing on hip is determined by CE angle. Wiberg (1939) [3] states that an effort to define the response of the acetabulum, the initial and final femoral epiphyseal width, the initial and final center-edge angle calculated. The aim of treatment in Perthes' disease is to maintain hip motion whilst providing containment of the soft femoral head. This may be accomplished by shelf acetabuloplasty, a varus osteotomy or abduction plasters [24]. In our short series of 3 patients with the

mean CE angle of $13.67 \pm 4.04^\circ$, two patients in the age group of 5-8 years, of which one had CE angle of 18° and a well contained head, was treated by abduction plasters, and other one had CE angle of 10° , so for head containment varus osteotomy procedure had been done. One patient was of adolescent age group and on subsequent follow-up his CE angle reduced to 13° so the operative treatment in the form of varus osteotomy was performed. On statistical analysis we found that in all the hip pathologies the spectrum of variations seen in the CE angle was statistically significant $p = 0.023$ and association found between various hip pathologies and treatment modalities done in all the cases was statistically significant $p = 0.017$.

Conclusion

1. We have found that all the hip pathologies reported to us had spectrum of variations in CE angle depending on the severity of disease. Variation was maximum seen in Osteoarthritis and Femoroacetabular impingement, in the cases of FAI maximum were of Pincer type.
2. In adult patients, 9 hips where hip salvage procedure were contemplated was those where CE angle is between $>20^\circ$ to $\leq 45^\circ$. In cases where total hip replacement were contemplated, preoperative CE angle helps us need of increased acetabular reaming specially in cases of combined FAI where acetabular over coverage is present. CE angle in all the cases had helped us in determining the exact course of action taken, for proper planning of management.
3. Limitation of our study was the limited sample size, and shorter duration of time, so we were not able to comment on the outcome of CE angle in those patients which needs longer follow-up.

References

1. Fredensborg N. The CE angle of normal hips. Acta Orthop Scand 1976;47:403-405.
2. Bruckl R, Hepp WR, Tonnis D. Eine Abgrenzung normaler und dysplastischer jugendlicher Hüftgelenke durch den Huftwert. Arch Unfall-Chir 1972;74:13-3.
3. Wiberg G. Studies on dysplastic acetabula and congenital subluxation of the hip joint. Acta Chir Scand 1939;S58:1-130.
4. Severin E. Congenital dislocation of the hip joint. Late results of closed reduction arthrographic studies of recent cases. Acta Chir Scand 1941;S63:1-142.
5. Wiberg G. Pfannendachplastik bei Dysplasia acetabuli, Subluxatio und Luxatio coxae unter besonderer Berücksichtigung der Entwicklung des oberen Pfannenrandes. Arch Orthop Unfall-Chir 1944;43:314-369.
6. Wiberg G. Shelf operation in congenital dysplasia of the acetabulum and in subluxation and dislocation of the hip. JBJS 1953;35(1):65-80.
7. Davies WR. Acetabular dysplasia and familial joint laxity: two etiological factors in congenital dislocation of the hip. JBJS Br 1970;52B:704-16.
8. Kutty S, Schneider P, Faris P, Kiefer G, Frizzell B, Park R *et al.* Powell. Reliability & predictability of center edge angle in the assessment of pincer femoroacetabular impingement. Int Orthop 2012;36(3):505-510.
9. Jamali AA, Mladenov K, Meyer DC, Martinez A, Beck M, Ganz R, Leunig M. Anteroposterior pelvic radiographs to assess acetabular retroversion: high validity of the "cross-over-sign". J Orthop Res

- 2007;25(6):758-765.
10. Wiberg G. Studies on dysplastic acetabula and congenital subluxation of the hip joint with special reference to the complication of osteoarthritis. *Acta Chir Scandinavica* 1953;83(S58):1-135.
 11. Mandal S, Bhan S. The center edge angle of Wiberg in the adult Indian population. *JBJS* 1996;78:320-1.
 12. Ito K, Minka MA, Leunig S, Werlen S, Ganz R. Femoroacetabular impingement and the cam-effect. A MRI-based quantitative anatomical study of the femoral head-neck offset. *JBJS Br* 2001;83:171-176.
 13. Beaulé PE, Zaragoza EJ, Motamedi K, Copelan N, Dorey FJ. Three-dimensional computed tomography of the hip in the assessment of femoroacetabular impingement. *J Orthop Res* 2005;23:1286-1292.
 14. Beck M, Leunig M, Parvizi J, Boutier V, Wyss D, Ganz R. Anterior femoroacetabular impingement: part II. Midterm results of surgical treatment. *Clin Orthop Relat Res* 2004;418:67-73.
 15. Wagner S, Hofstetter W, Chiquet M, Mainil-Varlet P, Stauffer E, Ganz R *et al.* Early osteoarthritic changes of human femoral head cartilage subsequent to femoroacetabular impingement. *Osteoarthritis Cartilage* 2003;11(7):508-518.
 16. Klauke K, Durnin CW, Ganz R. The acetabular rim syndrome. A clinical presentation of dysplasia of the hip. *JBJS Br* 1991;73(3):423-429.
 17. Hayes MH, Royer NK. The Relationship of acetabular dysplasia and femoroacetabular impingement to hip osteoarthritis. *PMR* 2011;3(11):1055-1067.
 18. Chung CY, Park MS, Lee KM. Hip Osteoarthritis and risk factor in elderly Korean population. *Osteoarthritis & Cartilage* 2010;18(3):312-6.
 19. Gosvig KK, Jacobsen S, Sonne Holm S, Palm H, Troelsen A. Prevalence of malformation of hip joint and their relationship to sex, groin pain and risk of OA: A population based survey. *JBJS Am* 2010;92(5):1162-9.
 20. Boone GR, Pagnotto MR, Walker JA, Trousdale RT, Sierra RJ. Lateral center Edge angle is predictive of acetabular over coverage in Femoroacetabular impingement. AAOS Annual Meeting presentation 2014. <http://www.abstractsonline.com/plan/abstract/.....b0de>.
 21. Tonnis D. Normal values of the hip joint for the evaluation of x-rays in children and adults. *Clin Orthop Relat Res* 1976;119:39-47.
 22. Amanatullah DF, Strauss EJ, Di Cesare PE. Current management options for osteonecrosis of femoral head. *Am J Orthop* 2011;40(10):E217-26.
 23. Nozawa M, Enomoto F, Shitoto K, Matsuda K, Maezawa K, Kurosawa H. Rotational Acetabular Osteotomy for Osteonecrosis with Collapse of the Femoral Head in Young Patients. *JBJS Am* 2005;87(3):514-520.
 24. Osman MK, Martin DJ, Sherlock DA. Outcome of late-onset Perthes' disease using four different treatment modalities. *J Child Orthop* 2009;3(3):235-242.