

E-ISSN: 2395-1958
P-ISSN: 2706-6630
IJOS 2020; 6(4): 335-342
© 2020 IJOS
www.orthopaper.com
Received: 26-06-2020
Accepted: 11-08-2020

Dr. A Manikandarajan
Assistant Professor, Department
of Orthopaedics, Rajah Muthiah
Medical College, Chidambaram,
Tamil Nadu, India

Dr. M Balakamesh
Post Graduate, Department of
Orthopaedics, Rajah Muthiah
Medical College, Chidambaram,
Tamil Nadu, India

Corresponding Author:
Dr. M Balakamesh
Post Graduate, Department of
Orthopaedics, Rajah Muthiah
Medical College, Chidambaram,
Tamil Nadu, India

Study on functional outcome of primary closed nailing in compound diaphyseal fractures of tibia

Dr. A Manikandarajan and Dr. M Balakamesh

DOI: <https://doi.org/10.22271/ortho.2020.v6.i4e.2358>

Abstract

Introduction: Open fractures of the tibia are among the most common of serious skeletal injuries, can cause permanent sequelae if not managed timely and precisely.

Material and Methods: The study group comprised of 30 patients who underwent closed locked intramedullary nailing. Follow up done for period of one year from July 2019 to June 2020 in prospective and retrospective manner at Department of Orthopaedics, Rajah Muthiah Medical College, Annamalai University.

Results: The Mean time of union was found to be 14 weeks 4 days for all compound fractures, for grade I compound – 13 weeks 3 days, for grade II cases – 15 weeks, and for grade IIIA cases – 17 weeks 1 day. Based on Johner-Wruhs criteria 90% and 10% of grade I cases had excellent and good outcome. 80% and 20 % of grade II cases had excellent and good outcome. 75% and 25% of grade IIIA patient had excellent and good outcome. Overall 83.3% of compound fracture had excellent outcome and 16.7% of compound fractures had good outcome respectively. Complication encountered was superficial infection (6.6%) in 2 patients, 3 (10%) patients had anterior knee pain, non union in 2 patients and delayed union in 1 patient.

Conclusion: our study concluded that in Grade I, II and Grade IIIa tibial diaphyseal fracture, treated with closed intramedullary interlocked nail had excellent to good functional outcome with proper alignment, good range of motion, low infection rate and less patient morbidity.

Keywords: open tibial fractures, closed intramedullary interlocked nailing, functional result

Introduction

Tibia fractures are the commonest long bone fractures, most commonly resulting from high velocity injury. There has been an exponential increase in vehicles in India in the last decade, which has ultimately become the most common cause for high velocity injury. Tibia being a superficial bone has become vulnerable for such injuries. Injuries occurring here are classified based on soft tissue injury as open or closed^[1].

- Open tibial fractures are often associated with severe soft tissue and bone injury^[2].
- The management of open fractures is regarded as an orthopaedic emergency^[3].
- The primary objective in managing an open fracture is union with prevention or eradication of wound sepsis^[4].
- In orthopaedic traumatology, the method of soft tissue stabilization and skeletal stabilization are still debated^[5].
- Intramedullary nailing in open fractures of the tibia is a well-accepted treatment modality in the developing world. References are scanty regarding the incidence of infection or nonunion related to specific type of open injury with this background^[6].
- In this study we investigated whether primary nailing in compound tibia fractures were producing satisfactory outcomes and we compared the outcomes in terms of fracture union and rates of infection.

Wound management and antibiotic prophylaxis

In the emergency department patients were given a stat dose of tetanus toxoid and a third-generation cephalosporin, aminoglycosides, metrogyl (after test dose). Wounds were cleaned, irrigated and dressed, and the limb splinted prior to urgent surgical debridement. Debridement done and after observation for 24 to 36 hrs with varies of each patients,

stabilisation with a locked intramedullary nail was performed based on wound status for open tibial fractures. The transpatellar tendon approach was used under guidance of an image intensifier. The injury was classified intra-operatively according to Gustilo and Anderson. The decision to ream the intramedullary canal was undertaken by the operating surgeon. Distal fragment reaming was not done for all grade IIIA cases during intra operatively Wounds were opened wash given edges trimmed, wound covered with oppsite primary nailing done then after wound approximated with 2.0 ethylon interrupted sutures.

Type	Description
Type I	Clean wound <1 cm in diameter with simple fracture pattern and no skin crushing
Type II	A laceration >1 cm and <10 cm without significant soft tissue crushing. The wound bed may appear moderately contaminated
Type III	An open segmental fracture or a single fracture with extensive soft tissue injury >10 cm. Type III injuries are subdivided into three types
Type IIIA	Adequate soft tissue coverage of the fracture despite high energy trauma or extensive laceration or skin flaps
Type IIIB	Inadequate soft tissue coverage with periosteal stripping
Type IIIC	Any open fracture that is associated with vascular injury that requires repair

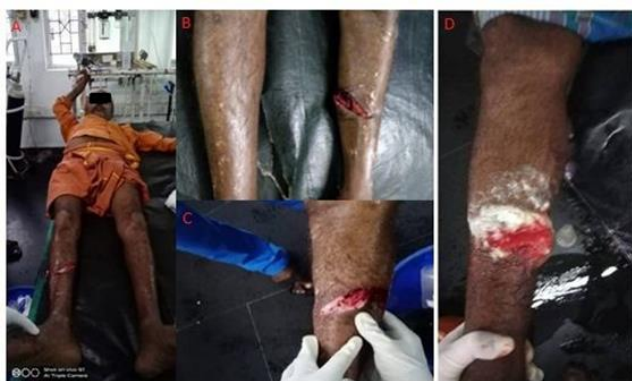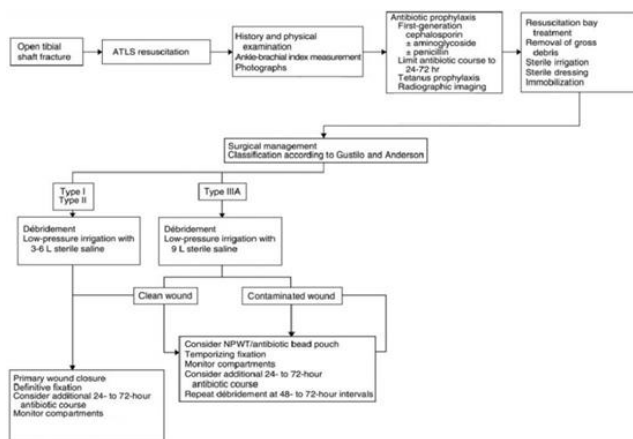


Fig 1: (A and B -Patient received; C- Wound wash; D- Post wound wash)

Timing of Débridement and Irrigation: Débridement and irrigation are vitally important to the successful management of open tibia fractures. Most current guidelines recommend that débridement be performed within 6 hours of injury [23]. Although the details and methods of irrigation are debated, the role of careful and complete débridement is clear. Gustilo

stated that adequate débridement is the single most important factor in the attainment of a good result in the treatment of an open fracture [26]. Systematic débridement, beginning with removal of gross contamination and debris, should be done as soon as possible in the casualty room. All necrotic tissue is excised, and muscle viability is determined by the four Cs: contractility, color, consistency, and capacity to bleed [26]. Completely free, large cortical bone fragments may be preserved in a sterile fashion to aid in determining length and rotation at the time of fracture stabilization. However, these fragments should be removed before definitive fixation and closure. Significant articular fragments should be thoroughly cleansed and retained when possible. In high-energy injuries, it is often difficult to fully determine the viability of all tissues within the zone of injury at the time of initial débridement. Repeat débridement at 48- to 72-hour intervals should be done to eliminate devitalized tissue that subsequently develops. Irrigation is used to supplement systematic and thorough débridement in removing foreign material and decreasing bacterial load. Based on the widespread availability of 3-L bags of normal saline, Anglen [27] recommended using 3 L of irrigation for type I fracture, 6 L for type II fracture, and 9 L for type III fracture.

Antibiotic Prophylaxis: Antibiotic prophylaxis should be initiated as soon as possible after injury. The benefit of early antibiotic prophylaxis was demonstrated by Patzakis and Wilkins,⁸ who showed a significantly increased rate of infection in fractures managed with antibiotic prophylaxis >3 hours after injury compared with <3 hours after injury (7.4% versus 4.7%, respectively). However, the appropriate duration of antibiotic prophylaxis is less clear. Coagulase positive Staphylococcus aureus and β-hemolytic streptococci were the most common pathogens isolated. Open tibia fracture was the most common fracture associated with this pathogen. This study established strong evidence for the efficacy of third-generation cephalosporins in the management of open fractures. Quinolones have been used as an alternative to intravenous cephalosporins for infection prophylaxis [20]. This class of drugs is attractive for several reasons. These drugs offer broad- spectrum bactericidal coverage, they can be administered orally also. They require less frequent administration, they achieve good bone penetration, and can provide prophylaxis for patients who are allergic to penicillin.

Pre-operative planning: A written, informed consent was taken from all the patients for their inclusion in this study. All the patients were explained in detail the available methods of treatment, with the final treatment decision left to the patient. A detailed history was taken, ascertaining the mode of injury, with particular emphasis placed on ruling out injuries to other areas. AP and lateral views of the involved leg with knee joint were taken. Routine blood and radiological investigations were done, as required for anaesthetic clearance.

Methods

The study group comprised of 30 patients who underwent closed locked intramedullary nailing. Follow up done for period of one year from July 2019 to June 2020 in prospective and retrospective manner at Department of Orthopaedics, Rajah Muthiah Medical College, Annamalai University. The inclusion criteria in this study were research literatures that were published; adult patients with open tibia fractures of Gustilo types I, II, IIIA, except for Gustilo type IIIB & IIIC; all randomized controlled clinical trials; and the interventional studies on primary nailing and their outcomes on fracture union and rate of infections

Inclusion Criteria

1. >20 years of age
2. Acute fractures of diaphysis of tibia.
3. Gustillo Anderson grade I, II, III a compound fracture
4. Communitated fractures.

Exclusion Criteria

1. Age <20 yrs.
2. Grade III b, IIIc gustillo Anderson compound fractures.
3. Associated with head injury.
4. Associated with fractures in any of 4 limbs.
5. Pathological fractures, fracture non-union and delayed union.
6. Patients not willing and medically unfit for surgery

Operative procedures

Operative Procedure positioning of the Patient All patients are operated under spinal/epidural anaesthesia. Under tourniquet control Patient is operated with his knee flexed to 70 degrees on a bolster for entry and by leg hanging reaming and nail insertion made. Assistant forearm is used to support the distal femur at a sufficient distance from the popliteal artery and vein, if it is not properly positioned, circulation is inhibited by the force used to insert the nail and damages the vascular wall. The injured leg is scrubbed, painted with betadine, spirit and draped. Longitudinal incision over the patellar ligament at the level of joint, 5 to 6 cm long is used, splitting the tendon longitudinally. Entry portal is made in saggital plane in line with medial slope of lateral tibial eminence, in coronal plane just anterior to anterior tibial articular surface.

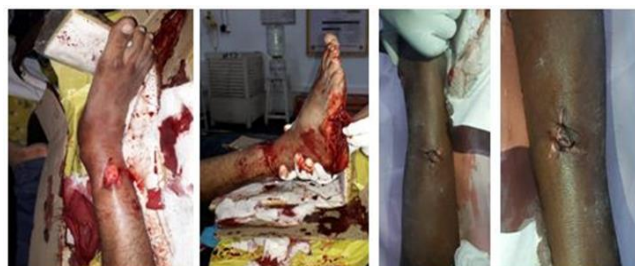A curved awl is used to open the medullary canal and is pushed as far as possible into the medullary canal, while the handle should be in line with the axis of the shaft. 3.2 mm guide wire is pushed into the canal, past the fracture site into

the malleolar region (0.5 to 1 cm proximal to ankle joint) assisted by reduction manually. Next step is to ream the medullary canal. Reaming is done with the help of solid reamers. Normally we start from 8 mm and increase by increments of 0.5 mm. The medullary canal is reamed 1 mm more than the diameter of measured at isthmus an X-ray lateral view. Determination of the length of nail is done preoperatively and intraoperatively another nail of same size, which is used with C-arm assistance. The nail with the proximal insertion handle and jig is passed over the guide wire and is inserted as far as possible, measured hammering is done to drive the tip of nail to the distal metaphysis and proximal end should be flush with the surface of cortex at the point of insertion. The nail should be centralized as far as possible, the guide wire is removed. For distal locking done using jig and checked by C-arm. Drill bit is inserted through the skin incision down to the bone near the locking holes and drilled under C-arm with axis of drill centered on the locking hole with a 4.0 mm drill bit. Drilling hole is done through both cortices, across locking holes. The length is determined with a depth gauge and confirmed with the C-arm. The distal locking is done. Proximal locking is done with proximal jig and insertion handle. Stab-incision is done over appropriate locking hole. A 8 mm protection sleeve is inserted and trocar through it, till the cortex is contacted. Trocar is removed and 4.5mm diameter drill sleeve is inserted and drilled with 4 mm drill bit. The drill sleeve is removed, depth of hole is measured with a depth gauge and a screw/ bolt is inserted which is confirmed with the C-arm. The C-arm is used to confirm the locking and nail position and fracture alignment. The wound is closed and dressing is done, compression crepe bandage is applied to control postoperative swelling. Postoperatively the limb is elevated on a pillow

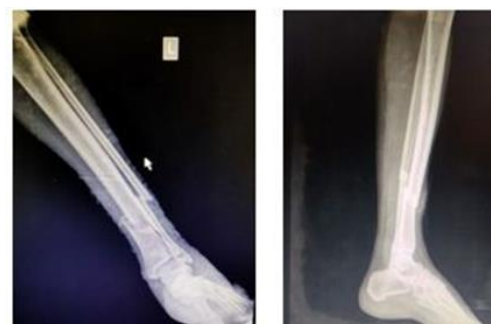	Excellent (left = right)	Good	Fair	Poor
Non-union, osteomyelitis, amputation	None	None	None	Yes
Neurovascular disturbances	None	Minimal	Moderate	Severe
Deformity				
Varus/valgus	None	2-5°	6-10°	>10°
Anteversion/recurvation	0-5°	6-10°	11-20°	>20°
Rotation	0-5°	6-10°	11-20°	>20°
Shortening	0-5 mm	6-10 mm	11-20 mm	>20 mm
Mobility				
Knee	Normal	>80%	>75%	<75%
Ankle	Normal	>75%	>50%	<50%
Subtalar joint	>75%	>50%	<50%	
Pain	None	Occasional	Moderate	Severe
Gait	None	Normal	Insignificant limp	Significant limp
Strenuous activities	Possible	Limited	Severely limited	Impossible

Fig 2: Operative procedures

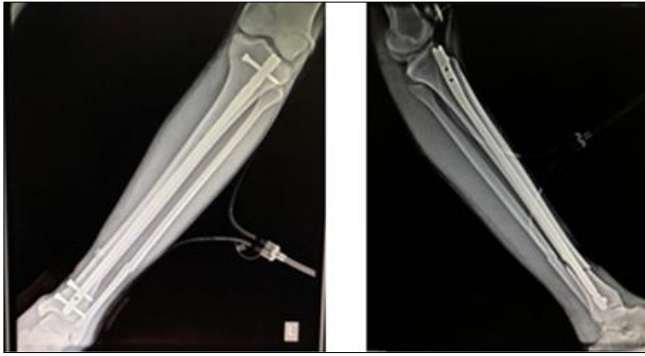Case Illustration 1



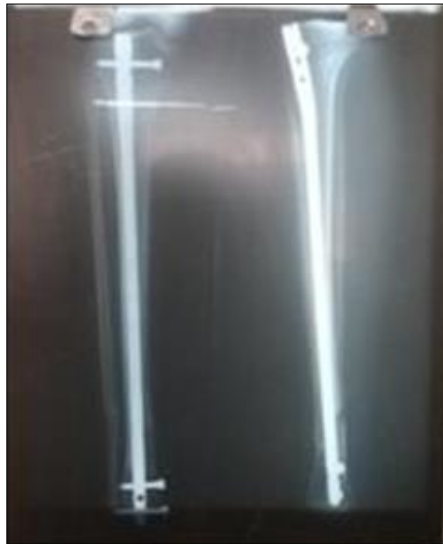Wound Picture



Pre-Operative X-Ray



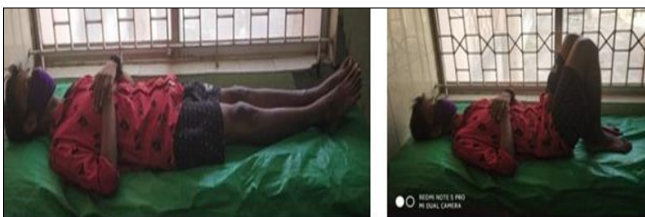Immediate Post Operative X-Ray



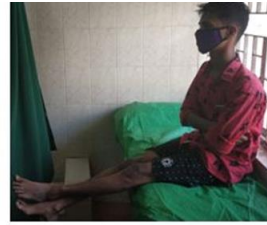5 Months Follow up X-Ray



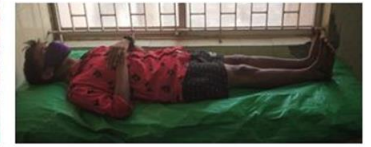Standing



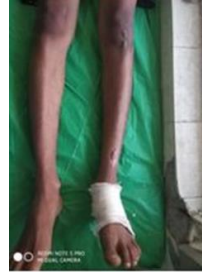Knee flexion



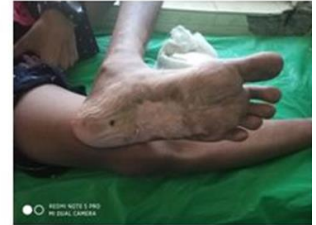Knee Extension



Dorsi Flexio

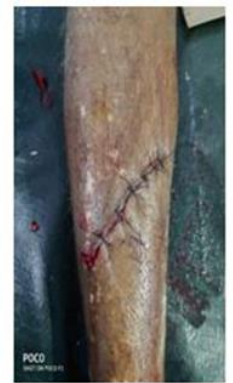
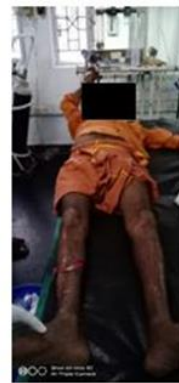
Healed wound

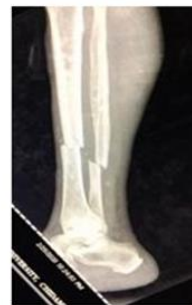

Plantar surface

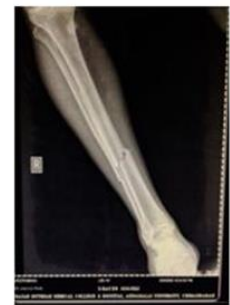Case Illustration 2



Wound Picture

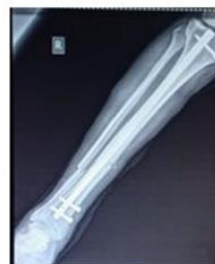

Antero-Posterior View

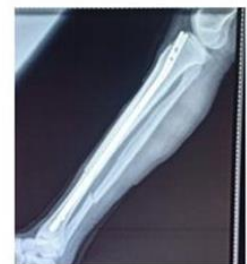

Lateral View

Pre Op X-ray

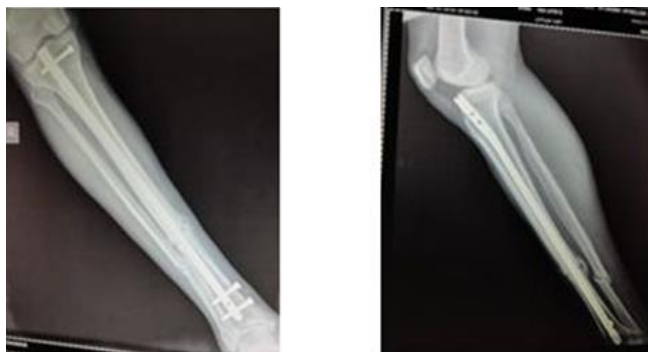

Antero – posterior view

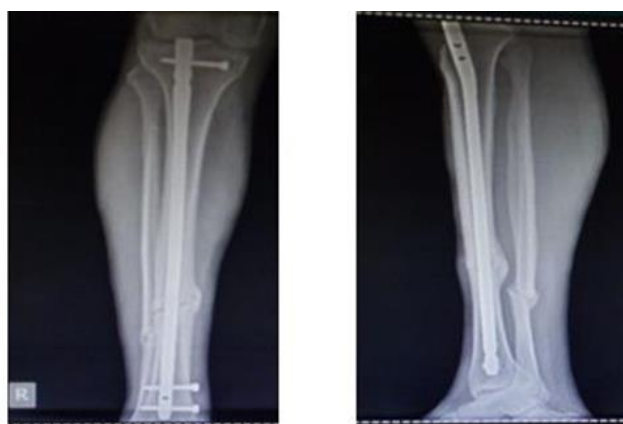

Lateral view

Immediate post op X-ray



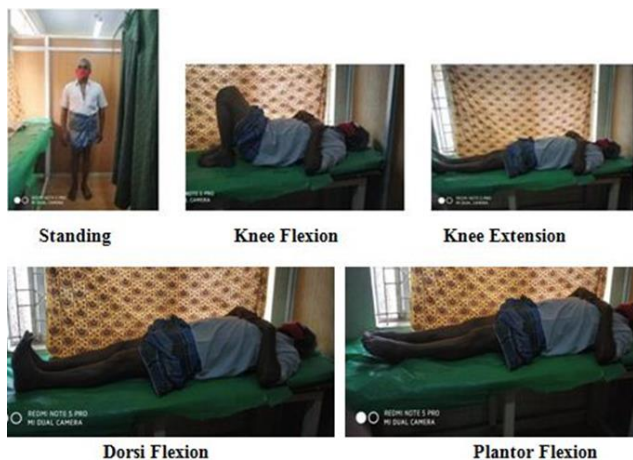2nd Month Follow-up



Antero-Posterior View

Lateral View

4th Month Follow up



Standing

Knee Flexion

Knee Extension

Dorsi Flexion

Plantor Flexion

The Postoperative Healing Rates in Patients with Fracture. All the four studies reported the effect of primary nailing for compound diaphyseal fractures of tibia. All four analysis was made between the groups and we observed almost similar time period for the fracture to unite. Delay in union was correlating directly with the grade of injury in each reference. Some of these patients underwent secondary procedure as dynamization, for improved fracture union for certain patients.

The Postoperative Infection

All the four studies reported infection, more evident in Grade III compound fractures. All superficial and deep wound infections were identified differentiated and managed accordingly. Fractures failing to show any clinical or roentgenographic evidence of healing by 3 months after injury were considered to have delayed union. The complications (infection, delayed union, and secondary surgeries)

encountered in each study group are listed in Table 2.

Results

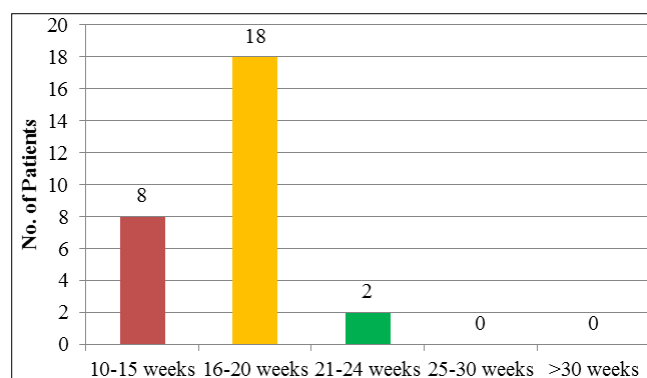
In our study 30 patients of Grade I, II and IIIA open fracture of tibia were followed in prospective and retrospective manner. Average age for fracture shaft tibia was 40.33 years. Vehicular accident in 30 (n=30) patients was observed to be the main cause of fracture in the study and more common in males 80%. Grade II injury 43.3% (n=13) was found to be more common than grade I (36.6%) and IIIA (20.1%).

In the study mean time injury surgery interval was found to be 42.4 hours (Table-2). Majority of patients operated by tibial interlocking nail were started with partial weight bearing within 4 weeks and full weight bearing as tolerated by patient. Maximum patient were able to bear full weight between 6 to 8 weeks with mean (±S.D) of weeks.

The union of the fracture was assessed by standard radiological and clinical criteria. Due to presence of nail we could not give stress to the fracture site, hence loss of pain on walking was considered as clinical indicator of union. Mean time of union rate was found to be 14 weeks 2 days. based on johner-wruhs criteria 90% and 10 % of grade I cases had excellent and good outcome. 80% and 20 % of grade II cases had excellent and good outcome. 75% and 25% of grade IIIa patient had excellent and good outcome, overall 73% excellent outcome and 27% good outcome. Post operative complications like compartment syndrome, neurovascular deficit, thromboembolism, shortening, stiff knee joint, was not observed in any of the patients. Superficial infection was observed in 2% (6.6%) patients, patient only. Non-union was observed in 1 patient. Anterior knee pain was observed in 20% (i.e. 6 pat.) of total cases in the study. Implant failure in form of broken screw was seen in 1 patient.

Table 1: Time of Union

S. No	Time of Union	No. of Patients
1	10-15 weeks	8
2	16-20 weeks	18
3	21-24 weeks	2
4	25-30 weeks	0
5	>30 weeks	0



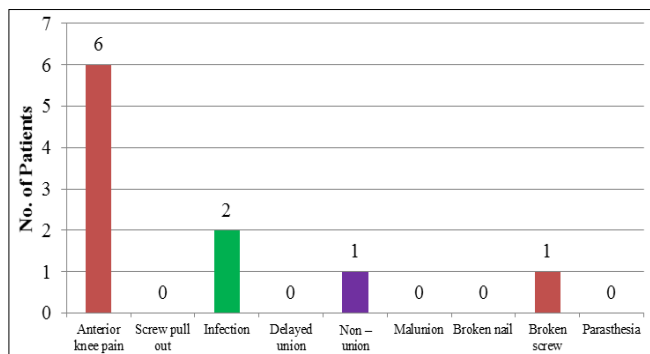
Graph 1: Time of Union

Table 2: Union Rate for Compound Fractures

S. No	Compound Fractures Grades	Average Union Rate
1	Grade I compound	13 weeks 3 days
2	Grade II compound	15 weeks
3	Grade IIIA compound	17 weeks 1 days
4	OVERALL	14 weeks 4 days

Table 3: Complication

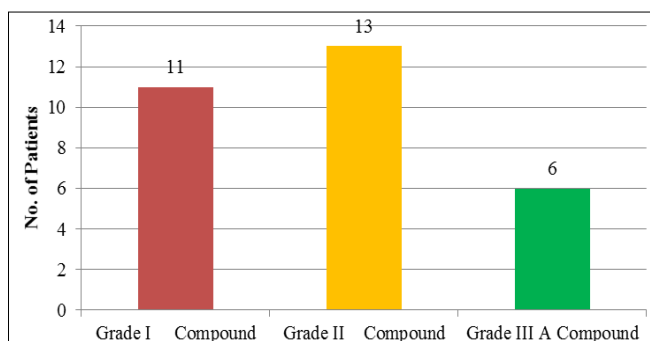
S. No	Complications	No. of patients
1	Anterior knee pain	6
2	Screw pull out	Nil
3	Infection	2
4	Delayed union	Nil
5	Non – union	1
6	Malunion	Nil
7	Broken nail	Nil
8	Broken screw	1
9	Parasthesia	Nil



Graph 2: Complications

Table 4: Open Fractures Grades

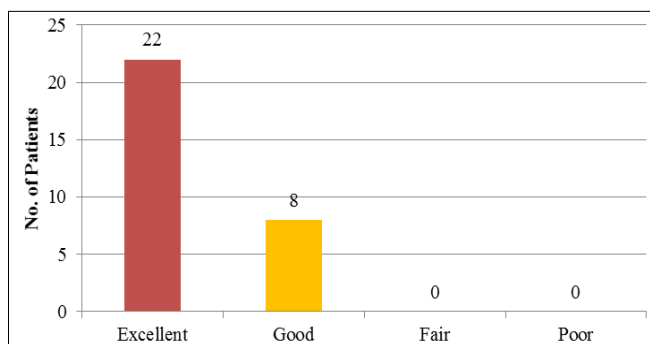
S. No	Grades	No. of Patients
1	Grade I Compound	11
2	Grade II Compound	13
3	Grade III A compound	6



Graph 3: Open Fractures Grades

Table 5: Outcome

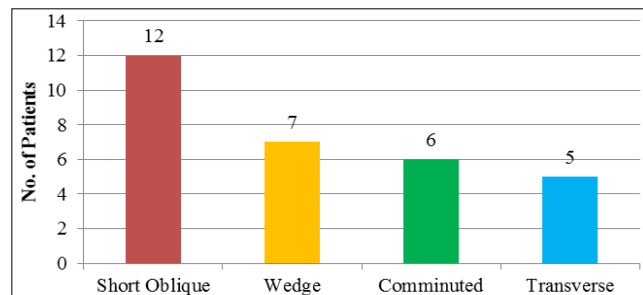
S. No	Outcome	No. of Patients
1	Excellent	22
2	Good	8
3	Fair	Nil
4	Poor	Nil



Graph 4: Outcome

Table 5: Fracture Pattern

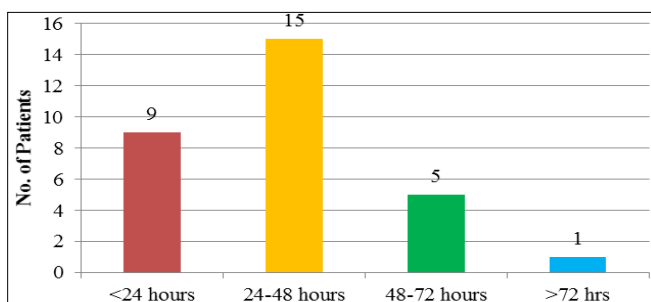
S. No	Fracture pattern	Total no.
1	Short Oblique	12
2	Wedge	7
3	Comminuted	6
4	Transverse	5



Graph 5: Fracture Pattern

Table 6: Duration time Interval between Injury and Surgery

S. No	Time interval	No. of patients
1	<24 hours	9
2	24-48 hours	15
3	48-72 hours	5
4	>72 hrs	1



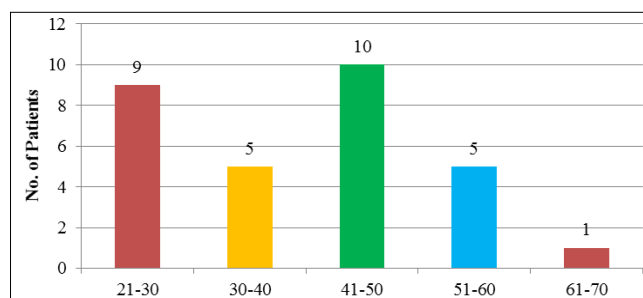
Graph 6: Duration time Interval between Injury and Surgery

Table 7: Outcome of Compound Injury

S. No	Grade-compound injury	Outcome
1	Grade I compound	90% Excellent, 10% Good
2	Grade II compound	80% Excellent, 20% Good
3	Grade III compound	75% Excellent, 25% Good
4	Overall	83% Excellent, 17% Good

Table 8 - Mean Age

S. No	Mean age	No. of patient
1	21-30	9
2	30-40	5
3	41-50	10
4	51-60	5
5	61-70	1



Graph 7: Mean Age

Table 9: Comparative Study

Study	Union time (weeks)	Non-union (%)	Infection (%)
Our study	14.4	5	6.6
Choudhary <i>et al.</i> ⁸	45.2	38	9.5
Seron <i>et al.</i> ⁹	36.7	36	17.6
Abdelaal <i>et al.</i> ¹⁰	38.2	32	11.1
Joshi <i>et al.</i> ¹¹	27.3	54	44

Discussion

Tibia fractures are one of the commonest fractures encountered in high velocity trauma. At present, early and repeated wound debridement, immediate rigid skeletal stabilization, and early wound coverage in combination with antibiotic therapy are the preferred treatment modality for open tibia fractures. The methods used for skeletal stabilization for these injuries still remains debated, with several options such as intramedullary rods, bone plates, external fixations, and intramedullary nailing^[12-18]. Donally *et al.* showed 28.6% of incidence of infection in his study for primary nailing in compound tibia fractures, 22% was seen in Henkelmann *et al.* and 25% in Mudiganty *et al.* and 30.3% in Wei *et al.*^[19-22]. Smokers had a relatively increased risk of infection and delayed wound healing in other studies, 24.7% has been documented by Hao *et al.*^[22]. In our review, personal habits such as smoking, substance abuse and comorbidities such as diabetes and hypertension were not discussed.

Operative duration didn't influence significantly in infection rate and there was no significant difference in timing of surgery among these references. The time duration between the injury and operative intervention was from <8 hours to 48 hours in these studies. The initial basic interventions play more of a role in limiting the risk of infections^[23]. In general, prolonged operative duration has an increased chance of surgical site infection of 13%, 17% and 37% for every 15mins, 30mins and 60 min of surgery Cheng *et al.*^[24]. Brown *et al.* reported union time of 36.7 weeks in his study^[25]. Union occurred between 34.2 weeks in Olerud *et al.* and 38.1 weeks in Chan *et al.*, all three had used external fixators for open fractures of tibia^[26, 27]. In this series nailing resulted in better union rates. Delayed union was noted up to 18.5% in Fong *et al.* and 18.95% in Mehmood *et al.*^[28, 29]. Factors which influenced delayed union in this

In a study by Westgeest *et al.* with a study of 736 subjects concluded that higher Gustilo grade fractures were associated with non-union and delayed union^[30]. Delayed union was equally encountered in operative duration of surgery >60 mins and <60mins. Other studies also showed similar result with not much significant difference in the operative duration Lua *et al.*^[31]. In literature distal 1/3rd fractures were reported with delayed union because of the poor blood supply compared to proximal 1/3rd due to absence of muscle attachment at distal 1/3rd of tibia. A study by Teitz *et al.* had 26% delayed union with intact fibula^[32]. This is due to the tibiofibular discrepancy that occurs and cause altered strain patterns in the tibia and fibula. A routine dynamization was not done in this studies.

Dynamization was done in cases where no signs of union were present at 6 weeks to 12 weeks who were on appropriate follow up in each study. Patients who underwent dynamization showed signs of union on their next follow-ups. There were also other factors, which influenced delayed fracture union and the chances of infection. These were delay in early debridement, injury-surgery interval, duration of

surgery, associated injuries, personal habits, comorbidities such as hypertension, diabetes and other medical conditions, which were not evaluated in these studies.

There were also other complications in the intraoperative period, early and late postoperative periods during the management of these fractures, for which further studies are still required. The economic burden drastically influences the patient's surgical outcome with open tibia fractures. In this review article one study showed no significant difference in the costs of index hospital stay, index procedure, and fracture-associated medications; however, the re-operation costs have to be considered based on the types of complications.

Three goals must be met in open tibial fractures: (a) Prevention of infection, (b) Achievement of fracture union (c) Restoration of function. These goals are interdependent and usually are achieved in the chronological order given.

For good bony union and functional limb, management of wound and prevention of infection plays the key role for successful treatment for compound fractures. When compared to other study groups our study showed better functional outcome (83%), union rate (14 weeks 4 days) with low infection (6.6%) and non union rate (5%).

Conclusion

Thus it was concluded that in Grade I,II and Grade IIIa tibial diaphyseal fracture, treated with closed intramedullary interlocked nailing had excellent to good outcome, gives satisfactory results with proper alignment, good range of motion, and low infection rate leading to proper union and less patient morbidity

References

- Briel M, Sprague S, Heels-Ansdell D, Guyatt G, Bhandari M, Blackhouse G, *et al.* Economic evaluation of reamed versus unreamed intramedullary nailing in patients with closed and open tibial fractures: results from the Study to Prospectively Evaluate Reamed Intramedullary Nails in Patients with Tibial Fractures (SPRINT). *Value Health* 2011;14:450-7.
- Melvin JS, Dombroski DG, Torbert JT, Kovach SJ, Esterhai JL, *et al.* Open tibial shaft fractures: I. Evaluation and initial wound management. *J Am Acad Orthop Surg* 2010;18:10-9.
- Fischer MD, Gustilo RB, Varecka T. The timing of flap coverage, bone-grafting, and intramedullary nailing in patients who have a fracture of the tibial shaft with extensive soft-tissue injury. *J Bone Joint Surg Am* 1991;73:1316-22.
- Gustilo RB, Anderson JT. Prevention of infection in the treatment of on thousand and twenty five open fractures of long bones: retrospective and prospective analyse. *JBJS Am* 1976;58:453-8.
- Gustilo RB, Mendoza RM, Williams DN. Problems in the management of type 3 (Severe) open fractures: a new classification of type 3 open fractures. *J Trauma* 1984;24:742-6.
- Bone LB, Johnson KD. Treatment of tibial fractures by reaming and intramedullary nailing. *J Bone Joint Surg* 1986;68:877-87.
- Jadad AR, Moore RA, Carroll D, Jenkinson C, Reynolds DJM, Gavaghan DJ, *et al.* Assessing the quality of reports of randomized clinical trials: is blinding necessary? *Control Clin Trials* 1996;17:1-12.
- Choudhary BM, Amer S, Kumar RD, Vanchi PK. Management of Open Tibial Shaft Fractures Treated By

- Primary Intramedullary Interlocking Nailing. IOSR-JDMS 2015;14:52-6.
9. Seron S, Rasool MN. Outcomes of intramedullary nailing for open fractures of the tibial shaft. SA Orthop J 2018;17(1):24-9.
 10. Abdelaal M, Kareem S. Open Fracture Tibia Treated by Unreamed Interlocking Nail. Long Experience in El-Bakry General Hospital. Open J Orthop 2014;4:60-9.
 11. Joshi D, Ahmed A, Krishna L, Lal Y. Unreamed interlocking nailing in open fractures of tibia. J Orthop Surg (Hong Kong) 2004;12(2):216-21.
 12. Keating JF, O'Brien PJ, Blachut PA, Meek RN, Broekhuysen HM. Locking intramedullary nailing with and without reaming for open fractures of the tibial shaft. J Bone Joint Surg 1997;79:334-41.
 13. Bach AW, Hansen ST. Plates versus external fixation in severe open tibial shaft fractures: A randomized trial. Clin Orthop Relat Res 1989;241:89-94, 1.
 14. Henley MB, Chapman JR, Agel J, Harvey EJ, Whorton AM, Swiontkowski MF. Treatment of II, IIIA and IIIB open fractures of the tibial shaft: A prospective comparison of unreamed interlocking intramedullary nails and half-pin external fixators. J Orthop Trauma 1998;12:1-7.
 15. Hobbrook JL, Swiontkowski MF, Sanders R. Treatment of open fractures of the tibial shaft: Ender nailing versus external fixation: A randomized, prospective comparison. J Bone Joint Surg Am 1989;71:1231-9.
 16. Tornetta P, Bergman M, Watnik N, Berkowitz G, Steuer J. Treatment of grade IIIB open tibial fractures: A prospective randomized comparison of external fixation and non-reamed locked nailing. J Bone Joint Surg Br 1994;76:13-9.
 17. Wanson TV, Spiegel JD, Sutherland TB, Bray TJ, Chapman MW. A prospective evaluation of the Lottes nail versus external fixation in 100 open tibial fractures. Orthop Trans 1990;14:716.
 18. Finkemeier CG, Schmidt AH, Kyle RF, Templeman DC, Varecka TF. A prospective, randomized study of intramedullary nails inserted with and without reaming for treatment of open and closed fractures of the tibial shaft. J Orthop Trauma 2000;14:187-93.
 19. Donnally CJ, Lawrie CM. Primary Intra-Medullary Nailing of Open Tibia Fractures Caused by Low Velocity Gunshots: Does Operative Debridement Increase Infection Rates? Surgical Infections 2018;19(3):273-7.
 20. Henkelmann R, Frosch KH, Glaab R, Lill H, Schoepp C, Seybold D, *et al.* Infection following fractures of the proximal tibia. A systematic review of incidence and outcome. BMC Musculoskelet Disord 2017;18(1):481.
 21. Mudiganty S, Daolagupu AK. Treatment of infected non-unions with segmental defects with a nail fixation system. Strategies Trauma Limb Reconstr 2017;12(1):45-51.
 22. Singh A, Jiong-Hao JT, Wei DT, Liang CW, Murphy D, Thambiah J. Gustilo IIIB Open Tibial Fractures: An Analysis of Infection and Nonunion Rates. Indian J Orthop. 2018;52(4):406-10. Theepainthan P *et al.* Int J Res Orthop 2019;5(6):xxx-xxx. International Journal of Research in Orthopaedics | November-December 2019 | Vol 5 | Issue 6 Page 5
 23. Young S, Lie SA. Risk Factors for Infection after 46,113 Intramedullary Nail Operations in Low- and Middle-income Countries. World J Surg 2013;37(2):349-55.
 24. Cheng H, Chen BP. Prolonged Operative Duration Increases Risk of Surgical Site Infections: A Systematic Review. Surg Infect (Larchmt) 2017;18(6):722-35.
 25. Court Brown CM, Christie J, McQueen MM. Closed Intramedullary Tibial Nailing: Its use in closed and Type I open fractures. J Bone Joint Surg 1990;72B:605-11.
 26. Karlström G, Olerud S. Ipsilateral fracture of the femur and tibia. J Bone Joint Surg Am 1977;59:240-3.
 27. Lefaivre KA, Guy P, Chan H, Blachut PA. Longterm follow-up of tibial shaft fractures treated with intramedullary nailing. J Orthop Trauma 2008;22(8):525-9.
 28. Fong K, Truong V. Predictors of non-union and reoperation in patients with fractures of the tibia: an observational study. BMC Musculoskelet Disord 2013;14:103.
 29. Mehmood M, Deshpande S, Khan SM, Singh PK, Patil B, Rathi R. Epidemiology of Delayed Union of Long Bones. J Trauma Treat 2017;6:370.
 30. Weber WJ. Factors Associated with Development of Nonunion or Delayed Healing After an Open Long Bone Fracture: A Prospective Cohort Study of 736 Subjects. J Orthop Trauma 2016;30(3):149-55.
 31. Lua JYC, Tan VH, Sivasubramanian H, Kwek EBK. Complications of Open Tibial Fracture Management: Risk Factors and Treatment. Malaysian Orthop J 2017;11:18-22.
 32. Teitz C, Carter C, Dennis H, Frankel V. Problems associated with tibial fractures with intact fibulae. J Bone Joint Surg 1980;62:770-6.