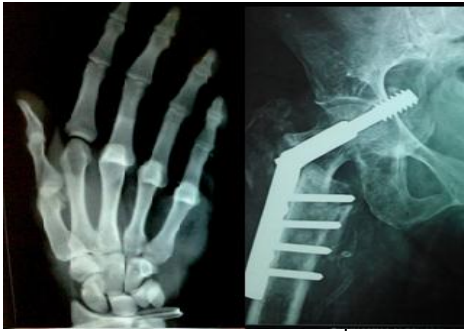

# International Journal of Orthopaedics Sciences

E-ISSN: 2395-1958  
P-ISSN: 2706-6630  
IJOS 2020; 6(4): 281-284  
© 2020 IJOS  
[www.orthopaper.com](http://www.orthopaper.com)  
Received: 26-06-2020  
Accepted: 09-08-2020

**Limbu A**  
Assistant Professor,  
Department of Orthopaedics,  
BP Koirala Institute of Health  
Sciences, Dharan, Nepal

**Khanal GP**  
Department of Orthopaedics,  
BP Koirala Institute of Health  
Sciences, Dharan, Nepal

**Adhikari SA**  
Department of Orthopaedics,  
BP Koirala Institute of Health  
Sciences, Dharan, Nepal

**Baral B**  
Department of Orthopaedics,  
BP Koirala Institute of Health  
Sciences, Dharan, Nepal

**Shah AB**  
Department of Orthopaedics,  
BP Koirala Institute of Health  
Sciences, Dharan, Nepal

**Khadka S**  
Department of Orthopaedics,  
BP Koirala Institute of Health  
Sciences, Dharan, Nepal

**Corresponding Author:**  
**Limbu A**  
Assistant Professor,  
Department of Orthopaedics,  
BP Koirala Institute of Health  
Sciences, Dharan, Nepal

## A RCT comparing the outcome of standard wound care and standard wound care combined with longitudinal distractive osteogenesis in chronic non-healing wounds of foot and ankle secondary to chronic limb ischemia

**Limbu A, Khanal GP, Adhikari SA, Baral B, Shah AB and Khadka S**

**DOI:** <https://doi.org/10.22271/ortho.2020.v6.i4e.2351>

### Abstract

**Objective:** To compare the outcome of standard wound care vs standard wound care with transverse distractive osteogenesis in chronic non-healing wounds of foot and ankle secondary to chronic limb ischemia.

**Design:** A Prospective Randomized Controlled Trial

**Settings:** Department of Orthopedics, Department of Surgery, Department of Emergency Medicine, BPKIHS, Dharan.

**Background:** Many options are available for treatment of chronic wounds. The major hurdle for non-healing chronic wounds is the reduced vascular supply to the affected limb. This study tries to find out the true beneficial effect of transverse distractive osteogenesis which is proposed to increase vascularity and thus helping in healing of wounds.

**Methodology:** 24 patients (From April 2017 – April 2018) were randomized to fall into two equal groups (12 each) for intervention. Group A wound receive standard wound care and Group B wound receive standard wound care combined with transverse distractive osteogenesis with Ilizarov apparatus. They were followed 3 months and assessed for various parameters for wound improvement.

**Results:** There were total 24 patients (male n=13 and female n=11) with 12 in each group. There was no difference in age, gender, cause, timing of presentation between the two groups. Diabetic foot (75%, n=18) dominated the main cause. There was no statistical significance in Bates-Jensen wound Assessment score in initial 1 month of assessment. However, at 3 months, the mean BWAT score was 22.91 in distraction group vs 35.25 in standard wound care group; which was statistically significant ( $p=0.001$ ). In the distraction groups, 2 patients had major complication of pin-tract infection and osteotomized part being sequestrum and had to be removed at 3 months. Definitive Wound closure was possible with split skin graft in 14 cases (37.5% vs 20%) and 2 reverse sural flaps (8.3%). All patients had positive culture result with monomicrobial status (74%) vs polymicrobial status (36%). No significant improvement in pain in patients with Burger's disease was obtained.

**Conclusion:** Distractive Angiogenesis greatly enhances the healing potential of wound secondary to chronic limb ischemia. However, the carries significant learning curve.

**Keywords:** Osteogenesis, Limb, Ischemia

### Introduction

Chronic lower extremity wounds that do not progress through the healing process in a timely manner and have become a major challenge to healthcare systems worldwide. Care of such conditions has been reported to cost 2% to 3% of the healthcare budgets in developed countries [1, 2].

Many options are available for these chronic wounds ranging from just topical treatments to complex revascularization procedures with unpredictable and variable results [3, 4, 5]. A solution with neo-vascularization will be effective for healing of such wounds which was originally described by Ilizarov via distractive osteogenesis [6, 7].

In the literature, there is lack of perspective randomized controlled trial with assessment of wound with validated wound assessment tool. This study aims to find if there is the benefit of distractive osteogenesis in chronic wounds comparing with simple wound care.

**Materials and Methodology**

Research hypothesis was made that standard wound care with longitudinally corticotomized fragment of tibia followed by lateral distraction would improve circulation and hence would be superior to standard wound care alone. 24 patients (From 2017 to April 2018) were prospectively randomized into two groups. Group A would receive standard wound care whereas Group B would receive standard wound care with longitudinal corticotomy of the tibial bone and with transverse distraction (0.25mm/day) with the principle of distractive osteogenesis with Ilizarov apparatus.<sup>[8]</sup> They would be followed for 3 months each after treatment and various parameters were assessed for wound improvement. Primary outcome was measured in terms of healing time. Secondary outcomes were measured in terms of Improvement in wound status as measured by validated freely available tool Bates Wound Assessment Tool (BWAT) scores, need for re-debridement, re-amputation level change, infections.<sup>[9, 10]</sup> Results were analyzed in Statistical Package for the Social Sciences (SPSS) program with significance level set at  $p <= 0.05$ .

**Results**

There were total 24 patients (male n=13 and female n=11) with 12 in each group. There were total 24 patients (male n=13 and female n=11) with 12 in each group. There was no difference in age, gender, cause, timing of presentation between the two groups, showing that the randomization was successful (Table 1). Diabetic foot (75%, n=18) dominated the main cause (Table 2).

**Table 1:** Distribution of qualitative variables in the Simple Wound Care (Group A) and Distractive Osteogenesis (Group B) groups

Variables	Groups		p value
	Group	Mean	
Age (years)	A	50.75	0.913
	B	51.16	
Sex	A	1.50	0.698
	B	1.42	
Cause	A	1.50	0.487
	B	1.92	
Time of Presentation (months)	A	5.50	0.283
	B	4.6	

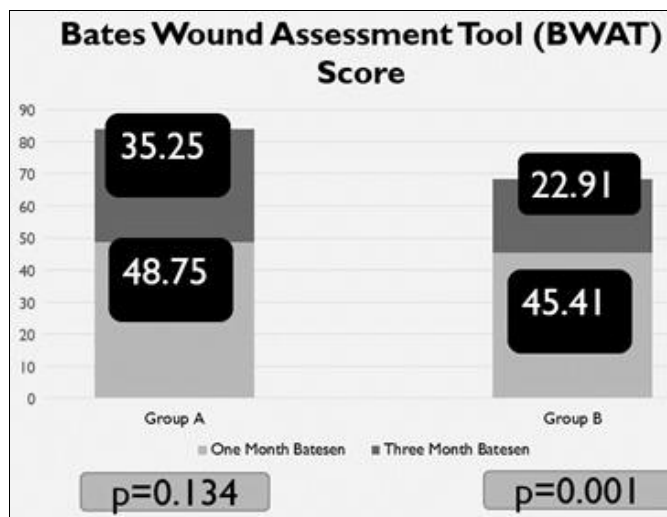
**Table 2:** Cause

Cause	Frequency	Percent (%)
Diabetic Foot	18	75
Traumatic Ulcer	2	8.3
Leprotic Ulcer	1	4.2
Burger's disease	3	12.5
	24	100

**Table 3:** Level of Wound

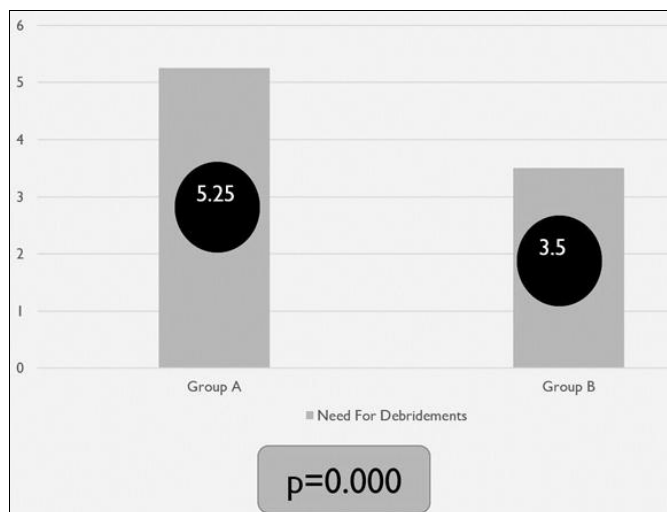
Level	Percentile (%)
Toes only	37.5
Upto Meta tarso-phalangeal joint	33.3
Upto Midtarsal	25.0
Whole Foot	4.2
	100

After the initial debridement and amputation where needed, the re-amputation level change was overall 45.83% (50% in Group A and 41.66% in Group B) which was statistically not significant. There was no statistical significance in Bates Wound Assessment Tool (BWAT) scores in initial 1 month of assessment. However, at 3 months, the mean Bates score was 22.91 in distraction group vs 35.25 in standard wound care group; which was statistically significant ( $p=0.001$ ) (Graph 1).



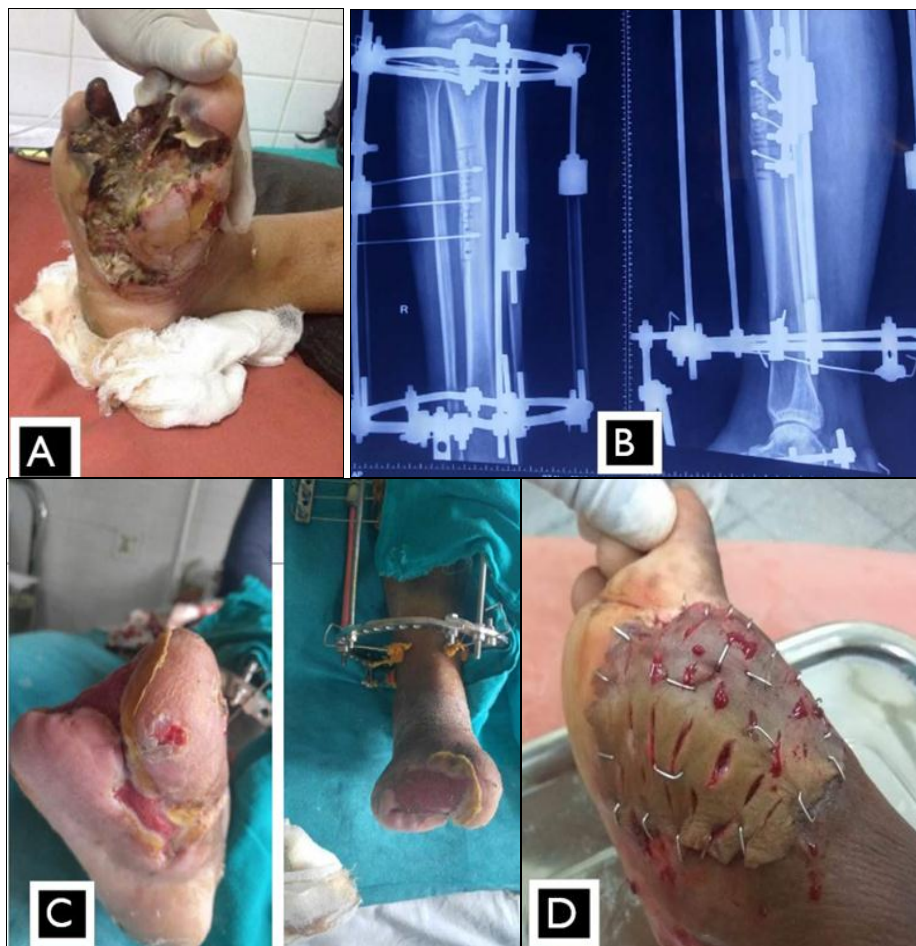
**Graph 1:** Improvement in Wound as assessed by Bates Wound Assessment Tool (BWAT) score. Lower is Better

The distractive osteogenesis (Group B) required fewer need for re-debridement compared to group A which was statistically significant (Graph 2).




**Graph 2:** Need for re-debridement.

Definitive Wound closure was possible with split skin graft in 14 cases (37.5% vs 20%) and 2 reverse sural flaps (8.3%) (Figure 1).



**Fig 1:** Case 35 year female with wound over foot. A) At presentation B) After Application C) At 6 weeks D) At 3 months with Skin Grafting possible

In the distraction groups, 2 patients had major complication of pin-tract infection and osteotomized part being sequestrum and had to be removed at 3 months (Figure 2). The wound was dressed after the removal of sequestered bone and suturing done of the wound. The wound healed well. However the patient had to be kept in non-weight bearing protection for a month.



**Fig 2:** Case 65 year male with Burger's disease. The corticotomized bone completed extruded through the wound.

All patients had positive culture result with monomicrobial status (74%) vs polymicrobial status (36%). No significant improvement in pain in patients with Burger's disease was obtained. At the end of treatment 70% percent of the patients were satisfied with the treatment whereas 29.2% of the patients were not satisfied with treatment more so with cumbersome apparatus that they had to bear and that to the Burger's patient where pain was relentless.

## Discussion

Our study predominately had diabetic foot (75%) followed by

Burger's disease (12.5%). In other studies there 13.6%, 20%, 60.70% occurrence of diabetic foot. Cornelia Guell *et al.* (2015) studied barriers in diabetic foot care in developing country and found that there is a high incidence of diabetic related amputation because of lack of care due to financial reasons [11, 12].

The mean number of need for re-debridement was 4.68 in monomicrobial vs 3.75 in polymicrobial organism. This was statistically significant in our study. Many studies have similar findings and one of major cause for amputation can be attributed to repeated infection [12, 13, 14]. Indeed infection do decrease with improve in circulation and good debridement.

We found statistically significant improvement in wound which was assed with Bates Wound Assessment Tool scores. Kulkarni *et al.* (2011) found significant improvement in 25 of 30 cases they performed with Ilizarov distraction [8]. Patwa *et al.* (2011) also found improvement in 48 cases of 60 cases performed. They showed 96% reduction in rest pain as compared with 66% in our cases. This might be due to less number of Burger disease cases in our study [15].

Thorud JC *et al.* (2016) studied the reoperation and re-amputation after trans-metatarsal amputation and found the re-amputation rate was estimated at 28.37% (95% confidence interval 19.56% to 37.19%) and the major amputation rate was estimated at 30.16% [16]. Our study had 45.83% re-amputation level change. Higher in treated with simple wound care compared with distractive osteogenesis.

Microcirculations disturbances play major role in ischemic disorders. The rate of debridement was significantly lower in cases treated with Ilizarov distraction ( $p=0.000$ ). This may be attributed to increased circulation. Shevstov *et al.* (1996), Bari

*et al.* (2015), conducted series of transverse distraction of longitudinally corticotomized fragment of tibia to increase vascularity and found improvement in about 80% of the patients<sup>[17, 18]</sup>.

### Conclusion

The wound healing potential of Ilizarov Distractive Angiogenesis is significant as compared to the simple wound care alone and thus is highly recommended in patients with chronic limb ischemia. As the sample size was relatively small, a larger study need to be evaluate further.

### Acknowledgement

We likely to express our sincere gratitude to Dr. Vinod Musale, Musale Hospital (Musale) for his valuable support and sharing his vast experience with us on application of ilizarov frames.

### References

1. Frykberg RG, Banks J. Challenges in the Treatment of Chronic Wounds. *Adv Wound Care* 2015.
2. Richmond NA, Maderal AD, Vivas AC. Evidence-based management of common chronic lower extremity ulcers. *Dermatol Ther [Internet]* 26(3):187-96. Available from: <http://www.ncbi.nlm.nih.gov/pubmed/23742279>
3. Lavery LA, Fulmer J, Shebetka KA, Regulski M, Vayser D, Fried D *et al.* The efficacy and safety of Grafix(®) for the treatment of chronic diabetic foot ulcers: results of a multi-centre, controlled, randomised, blinded, clinical trial. *Int Wound J [Internet]* 2014;11(5):554-60. Available from: <http://www.ncbi.nlm.nih.gov/pubmed/25048468>
4. Robson MC, Phillips TJ, Falanga V, Odenheimer DJ, Parish LC, Jensen JL *et al.* Randomized trial of topically applied repifermin (recombinant human keratinocyte growth factor-2) to accelerate wound healing in venous ulcers. *Wound Repair Regen [Internet]* 9(5),347-52. Available from: <http://www.ncbi.nlm.nih.gov/pubmed/11896977>
5. AVRT, VKP. Thromboangiitis obliterans (Buerger's Disease) - Current practices. *Int. J Inflam* 2013;
6. Birch JG. Transosseous Osteosynthesis. Theoretical and Clinical Aspects of the Regeneration and Growth of Tissue. *The Journal of Bone & Joint Surgery* 1992;74:1117:1118.
7. Shevtsov VI, Gordievskikh NI, Bunov VS, Petrovskaya NV. Changes in blood flow during tibial thickening by the Ilizarov method. *Bull Exp Biol Med [Internet]* 2002;134(6):525-7. Available from: <http://www.ncbi.nlm.nih.gov/pubmed/12660827>
8. Kulkarni S, Kulkarni GS, Shyam AK, Kulkarni M, Kulkarni R, Kulkarni V. Management of thromboangiitis obliterans using distraction osteogenesis: A retrospective study. *Indian J Ortho* 2011.
9. Harris C, Bates-Jensen B, Parslow N, Raizman R, Singh M KR. Bates-Jensen Wound Assessment Tool [Internet]. Available from: <https://www.woundcare.ca/Uploads/ContentDocuments/BWAT.pdf>
10. Harris C, Bates-Jensen B, Parslow N, Raizman R, Singh M, Ketchen R. Bates-Jensen wound assessment tool: pictorial guide validation project. *J wound, ostomy, Cont Nurs off Publ Wound, Ostomy Cont Nurses Soc [Internet]* 37(3),253-9. Available from: <http://www.ncbi.nlm.nih.gov/pubmed/20386331>
11. Sabharwal S, Zhao C, McKeon J, Melaghari T, Blacksin M, Wenekor C. Reliability analysis for radiographic measurement of limb length discrepancy: Full-length standing anteroposterior radiograph versus scanogram. *J Pediatr Orthop* 2007;27(1):46-50.
12. Al-Rubeaan K, Al Derwish M, Ouizi S, Youssef AM, Subhani SN, Ibrahim HM *et al.* Diabetic foot complications and their risk factors from a large retrospective cohort study. *PLoS One* 2015;
13. Pickwell K, Siersma V, Kars M, Apelqvist J, Bakker K, Edmonds M *et al.* Predictors of lower-extremity amputation in patients with an infected diabetic foot ulcer. *Diabetes Care* 2015.
14. Lipsky BA, Berendt AR, Cornia PB, Pile JC, Peters EJG, Armstrong DG *et al.* infectious diseases society of America clinical practice guideline for the diagnosis and treatment of diabetic foot infections. *Clinical Infectious Diseases* 2012.
15. Patwa JJ, Krishnan A. Buerger's Disease (Thromboangiitis Obliterans)- Management by Ilizarov's Technique of Horizontal Distraction. A Retrospective Study of 60 Cases. *Indian J Surg. [Internet]* 2011;73(1):40-7. Available from: <http://www.ncbi.nlm.nih.gov/pubmed/22211037>
16. Thorud JC, Jupiter DC, Lorenzana J, Nguyen TT, Shibuya N. Reoperation and Reamputation After Transmetatarsal Amputation: A Systematic Review and Meta-Analysis. *Journal of Foot and Ankle Surgery* 2016.
17. Shevtsov VI, Larionov AA, Pepeliaev AG, Petrovskaya NV. [Distraction osteosynthesis in occlusive diseases of the limb arteries]. *Khirurgiia (Sofia) [Internet]* 1998;(11):17-21. Available from: <http://www.ncbi.nlm.nih.gov/pubmed/9864978>
18. MM B. Management of Buerger's Disease (TAO) With Ilizarov (A Retrospective Study of 18 Cases). *MOJ Orthop Rheumatol [Internet]* 2015,3(4). Available from: <https://medcraveonline.com/MOJOR/management-of-buerger-s-disease-tao-with-ilizarov-a-retrospective-study-of-18-cases.html>