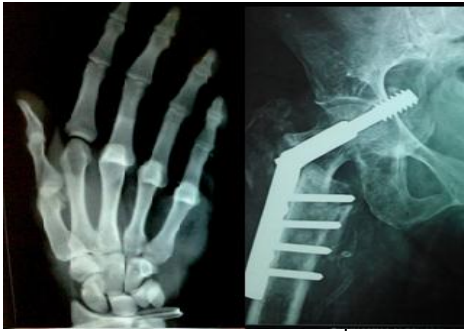

International Journal of Orthopaedics Sciences

E-ISSN: 2395-1958
P-ISSN: 2706-6630
IJOS 2020; 6(4): 274-280
© 2020 IJOS
www.orthopaper.com
Received: 19-06-2020
Accepted: 05-08-2020

Dr. Pranay Neerumala
Junior Resident, Department of
Orthopaedics, Medical Trust
Hospital, Kochi, India

Dr. Khaleel VM
MS Ortho, Head and Consultant
Orthopaedic Surgeon,
Department of Orthopaedics,
Medical Trust Hospital, Kochi,
India

Dr. Manoj Kanamarlapudi
MS Ortho, Assistant Professor,
Department of Orthopaedics,
ESIC Medical college and
hospital, Hyderabad, India

Corresponding Author:
Dr. Pranay Neerumala
Junior Resident, Department of
Orthopaedics, Medical Trust
Hospital, Kochi, India

Evaluation of functional and radiological outcome of type iii open distal tibial fractures treated with early internal fixation followed by soft tissue reconstruction [fix and flap]: A prospective study

Dr. Pranay Neerumala, Dr. Khaleel VM and Dr. Manoj Kanamarlapudi

DOI: <https://doi.org/10.22271/ortho.2020.v6.i4e.2350>

Abstract

The treatment of Gustilo Anderson type 3 open distal tibia intrarticular fractures is a major challenge to orthopaedic surgeons which needs aggressive debridement, adequate fixation, and early flap coverage of soft tissue defect through Osteoplastic approach rather than conventional orthopaedic approach alone. The incidence of these fracture are on surge due to urbanistaion and high velocity motor vehicle accidents. This study has been done to evaluate functional and radiological outcome in gustillo type 3b open fractures by early definitive fixation and soft tissue cover. Twenty six patients were operated by fix and flap protocol and evaluated at the end of one year with IOWA ankle scoring system and its radiological outcome and their complications. Among 26 patients treated with this protocol the union rate is 100% and the mean union time is 29weeks with 3 patients developed malunion and one patients presented with ankle arthritis. Two patients (7%) developed deep infection in which one patient also having delayed union and two patients (7%) developed superficial infection. Functional results were graded according to the IOWA ankle scoring system. 11 patients had excellent to good outcomes and 11 were fair outcome and remaining 4 patients shows poor outcome. Fix and Flap in the same sitting using immediate wound cover at the time of definitive fixation, has given good results in our hands despite the comminution at fracture site and open wound.

Keywords: Open intrarticular distal tibia fractures, early soft tissue cover

Introduction

Management of Gustilo Anderson type III open distal tibial fractures remain one of the major challenging problems for orthopaedic surgeons. The incidence of these fractures with intra-articular extension or Pilon fractures comprise 7% of tibial fractures and less than 1% of lower extremity fractures [1]. These are usually associated with high energy trauma being complicated by extensive soft tissue damage, gross contamination, vascular injury, leading to threatening complications like infection, nonunion and may even end up in amputation leading to significant morbidity and poor functional outcome [2].

In 1969, Ruedi and Allgower described a method of management of these fractures including restoration of length and axis of the fibula, reconstruction of articular surface of the distal end of tibia, bone grafting of the defect resulting from impaction using cancellous autografts and plating of tibia [3]. When the treatment principles of Ruedi and Allgower were extrapolated to high energy pilon fractures with associated soft-tissue injury and comminution, comparable results were not obtained [4]. In fact the prevalence of complications, including infection, wound dehiscence, nonunion, malunion, and posttraumatic arthritis, was markedly increased. Recent literature has emphasized the two factors that most closely correlated to wound problems are open fractures and degree of comminution. Both these factors are associated with higher levels of soft tissue injury resulting in periosteal stripping and devascularisation of bone [5, 6]. Several authors have demonstrated the benefits of bridging external fixation followed by definitive internal fixation once the soft tissue has healed completely, which will require prolonged hospitalization, multiple procedures, pin tract infections related to bridging external fixation [7, 8].

There is need for aggressive debridement, definitive fracture fixation, and early soft tissue cover in reducing the morbidity and possible good functional outcome for these fractures. This is possible only when there is a collective osteoplastic approach to the problem rather than the conventional orthopaedic approach alone.

In this prospective study we intend to study the functional outcome of Gustilo grade III open distal tibial pilon fractures treated with early internal fixation and soft tissue reconstruction {Fix and Flap protocol} and also the sequel and complications following these fractures.

Material and Methods

Methodology

We prospectively studied 26 patients with grade III open distal tibial pilon fractures treated with early internal fixation and soft tissue cover at Medical Trust Hospital, Kochi from September 2015 to December 2017. Of the 26 open fractures, 8 fractures belong to type III A and 18 fractures belong to type III B type of Gustilo Anderson classification. Patients age ranged from 18-60 years were included in the study. Extra-articular fractures, Gustilo type IIIC and associated long bone fractures were excluded. Road traffic accident and fall from height being the mode of injuries in these patients. The minimum period of follow up in our study was 1 year ranging from 12 to 18 months. The results were assessed using IOWA ankle scoring at the end of one year and at final follow up. Ethical clearance from the ethics committee of the institute for this study was obtained. Consent was taken from all the patients before enrolling for the study.

Management Protocol

A multidisciplinary team approach consisting of orthopaedics and plastic surgeon collectively managed all patients. Initial treatment in the emergency department include assessing the pulse and soft tissue status, x rays were taken and classify the fracture. Meticulous wound wash, antibiotics (Ceftiaxone, metronidazole and aminoglycoside) and tetanus prophylaxis were administered to all patients and stabilised with splint. Later patient shifted to Emergency OT by combined orthopaedic and plastic surgery teams as soon as possible following general surgical stabilization. Radical debridement and temporary ankle spanning external fixation using AO (Universal) system applied in a delta configuration.

CT scans were taken after ex fix application to assess fracture orientation, amount of comminution or impaction, and also for planning surgical approaches.

Serial debridement was performed every forty-eight to seventy-two hours until all obviously devitalized tissue and foreign bodies were removed and extended outside the zone of injury until adequate bleeding and viable tissues were encountered, to provide a healthy bed for tissue transfer. In some patients vacuum-assisted suction drains were used prior to delayed primary closure or flap coverage. Antibiotics were continued for forty-eight hours after it was determined that the wound was stable. The patients were taken for definitive fixation only when no signs of infection seen.

Definitive Management

During definitive fixation, the skin incision was modified to incorporate the initial wound where ever possible. Open reduction and internal fixation of the distal tibia with anterolateral plating or medial plating according to fracture pattern and fibula fixation carried out by low profile plates. Soft tissues were assessed on an ongoing basis with the help of Plastic surgeon. Soft-tissue reconstruction was typically performed on the day of definitive fixation in few patients, and within 72 hours of definitive fixation in few. The gracilis muscle was the donor of choice when the defect was small. For large defects, either a vastuslateralis or latissimusdorsi free flap was used. All patients were managed with a well-padded, posterior short-leg splint at the completion of definitive fixation and following soft-tissue reconstruction.

Post-operative protocol and rehabilitation

Post-operative intravenous antibiotics were continued in all patients for the initial five days, followed by oral antibiotics till sutures were removed. All patients remained in splint or cast immobilization until the wounds were healed and the sutures could be removed. When the soft tissues allowed, active and active-assisted range-of-motion exercises of the affected ankle and subtalar joint were initiated. Patients were advised to remain toe touch mobilization for a minimum of six to eight weeks, and then they progressed to full weight-bearing over four to twelve additional weeks.

Follow Up

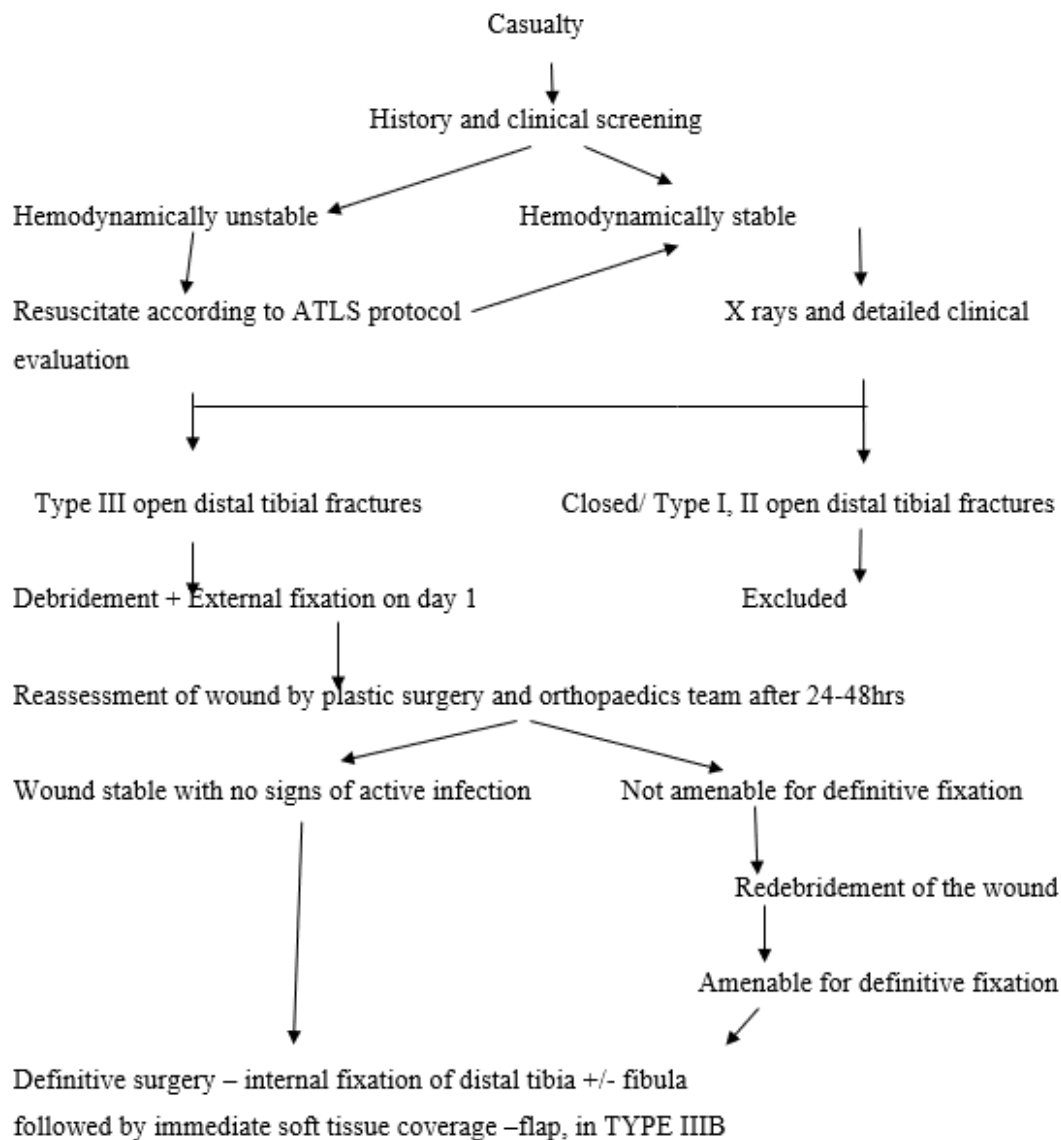
Patients were followed up at suture removal and every three weeks initially and every six weeks later till fracture union. At each visit, the physical examination included an assessment of wound-healing, status of soft tissues, and the range of motion. Routine clinical evaluation included documentation of the patient's subjective report of pain, medication requirements, range of movements, return to work, gait, ability to perform activities of daily living and ability to resume recreational activities. Union was assessed clinically and radiologically.

Assessment of results:

The results were assessed using IOWA ankle scoring system after union of fracture, in which points were assigned for function, freedom from pain, gait and range of motion, results were categorized into excellent, good, fair and poor ^[9]. (Table 1)

IOWA Ankle scoring system

| | |
|---------------------|--------|
| Points for Function | 40 |
| Freedom from Pain | 40 |
| Gait | 10 |
| Range of Motion | 10 |
| Excellent | 90-100 |
| Good | 80-90 |
| Fair | 70-79 |
| Poor | <70 |

Treatment Protocol**Results**

Patient demographics and injury details are shown in Table 2, Outcome and complications are reported in table 3.

All patients underwent wound debridement and external fixation for temporary stabilization on Day 1. Antibiotic bead insertion was done at fracture site during initial debridement till definitive fixation in 10 cases, whereas beads were reinserted in 7 patients at the time of definitive fixation which were removed after fracture union.

6 patients underwent flap coverage on the day of definitive fixation under same anaesthesia, whereas in 10 patients require flap coverage after 48-72 hours from time of internal fixation of distal tibia in whom vacuum dressing was used for the interval time till flap cover. Gracilis free muscle flap was used as donor of choice in majority of the patients i.e. 8 out of 16 flaps. Choice of flap cover was decided by the plastic surgeon based on the location and size of the defect to be cover and bulk of the donor muscle.

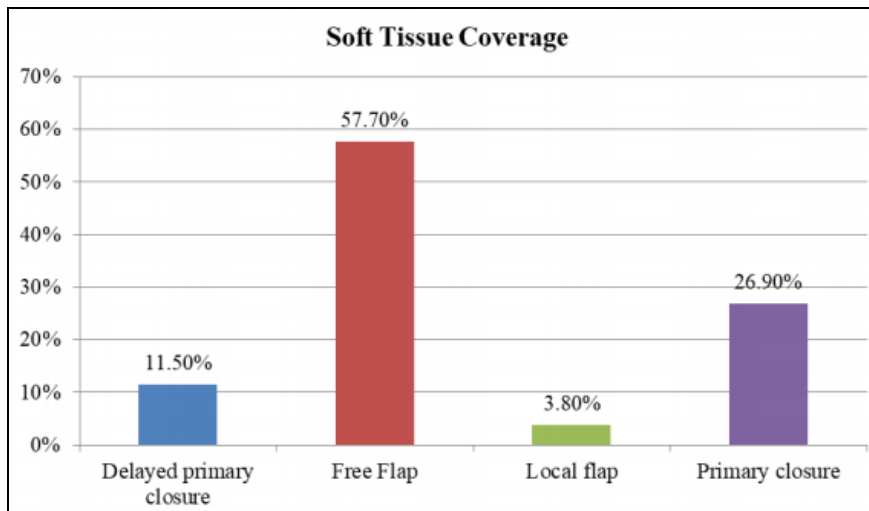


Fig 1: Bar diagram showing Soft Tissue Coverage distribution among subjects in the study

All the 26 cases had satisfactory reduction and alignment. Of 26 patients, in 22 patients fracture united between 18-36 weeks (overall mean union time 29.7weeks). (Fig 1) In 2 patients, progressive signs of union were delayed. One patient was lost to follow up. However after 6 months of surgery, he presented with non-union and implant failure which was managed by revision plating and bone grafting. One patient developed infection with delayed union which was managed by debridement and antibiotic bead insertion followed by antibiotic bead removal and bone grafting. Delayed union without any signs of infection was managed by bone grafting in one patient. One patient developed non-union without signs of infection treated with bone grafting. However all the fractures united subsequently.

Primary bone grafting was not considered in any case. In non-union and delayed union, autogenous cancellous bone grafting (harvested from iliac crest) done in 4 cases.

23 of 26 cases had satisfactory reduction and alignment. Three cases showed malunion with arthritic changes in one patient at the end of follow up. 4 patients underwent flap debulking by plastic surgeon for cosmesis.

The minimum period of follow up in our study was 1 year ranging from 12 to 18 months. A clinical assessment of ankle function was done for every patient at the end of 1 year follow-up using IOWA ankle scoring system, which showed

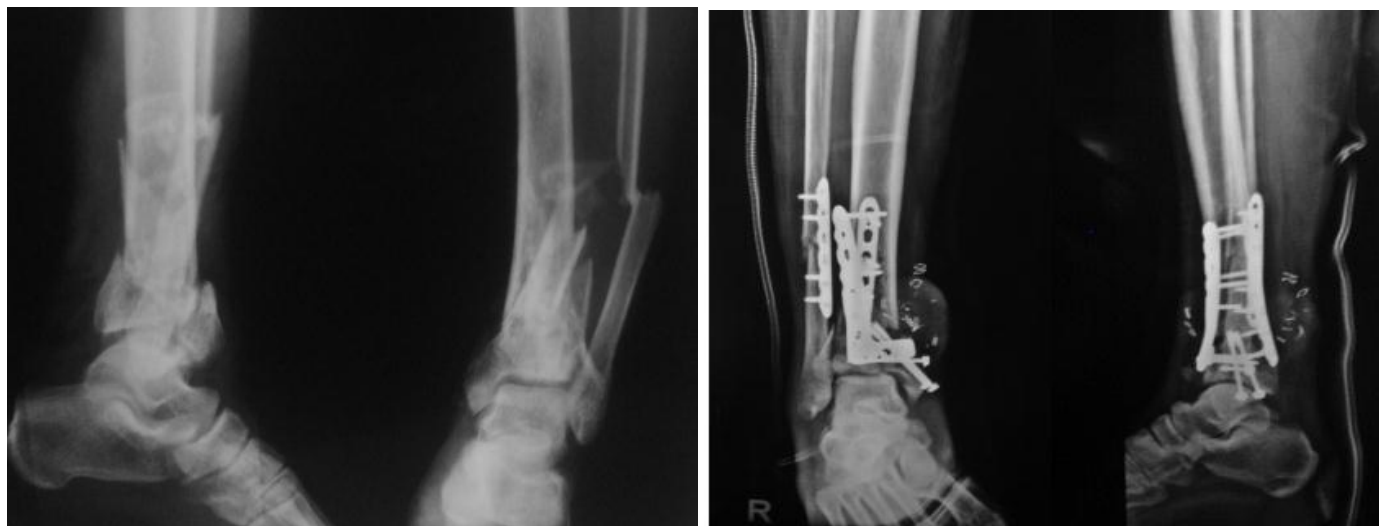excellent outcome in 2 patients, poor outcome in 4 patients, good outcome in 9 patients and fair outcome in 11 patients.

Table 2: Distribution of patients according to their demographic and clinical characteristics.

| Variables | N(%) |
|---|----------|
| Age distribution (in years) | |
| <40 years | 9(34.6) |
| 41 to 50 | 8(30.8) |
| 51 to 60 | 9(34.6) |
| Gender distribution | |
| Males | 20(76.9) |
| Females | 6(23.1) |
| Mode of Injury | |
| Fall from height | 11(42.3) |
| RTA | 15(57.7) |
| Side | |
| Right | 10(38.5) |
| Left | 16(61.5) |
| Gustillo Type | |
| Type III A | 8(30.8) |
| Type III B | 18(69.2) |
| Implant used for definitive fixation | |
| Anterolateral LCP | 9(34.6) |
| Distal medial tibial LCP | 17(65.4) |

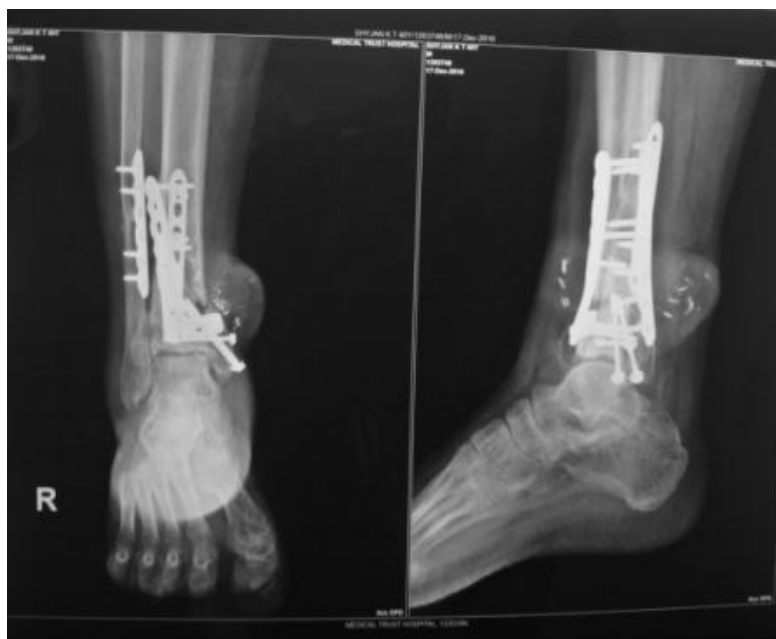Table 3: Clinical outcome at the end of follow up

| Variables | N(%) |
|----------------------------------|----------------------|
| Time to union | 18-36weeks(29 weeks) |
| Malunion | 3 |
| Ankle arthritis | 1 |
| Soft tissue complications | |
| Deep infection | 2(7) |
| Superficial wound infection | 2(7) |
| IOWA Ankle scoring system | |
| Excellent | 2(7.6) |
| Good | 9(34.6) |
| Fair | 11(42.3) |
| Poor | 4(15.3) |

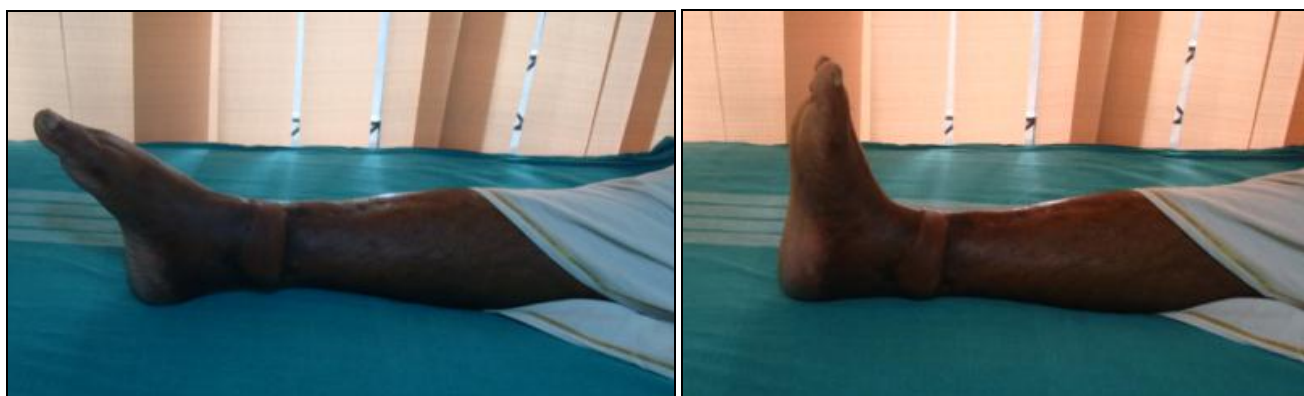

a) Pre op x ray grade 3 distal tibia and fibula fracture

b) Immediate post op x ray following ORIF for tibia and fibula



c) One year post op X ray showing union of tibia and fibula



d) Ankle ROM at the end of one year

Fig 2.

Discussion

Grade III open pilon fractures are difficult to manage and often result in a poor functional outcome. Published data pertaining to the treatment of open pilon fractures are found predominantly in small series of open injuries, or as a subset of series including both open and closed fractures [10-12].

A major advance in management came in 1973 with the introduction of microvascular free flaps by Daniel and Taylor [13] which decrease the time to union and the incidence of infection [14, 15]. Godina brought a new dimension to the treatment of these injuries by advocating the use of free tissue transfer very early, within five days of the injury [16]. Timing

of early soft tissue reconstruction is still in controversy. Our study support the observation that if the patients were hemodynamically stable, no active signs of infection delay in soft tissue cover was not helpful, as it could lead to additional soft tissue loss and a further increase in chances of wound contamination. Effective internal fixation facilitates soft-tissue cover which improved patient compliance [17]. We have successfully combined these two approaches in our unit to take Godina's concept to the extreme, advocating where possible immediate soft-tissue and bony reconstruction [18, 19]. We consider our aims in management of open tibialpilon fractures as early aggressive debridement with Exfix, followed by definitive fixation and soft tissue cover to prevent infection and to achieve bony union. Overall the primary rate of union was 100%. Mean time to union in this study is 29.7 ± 19 weeks (including three patients with delayed union). Conroy *et al* reported mean time to union of 35(12-78) weeks in their study of thirty-two patients with open distal tibialpilon fractures treated by early internal fixation and soft tissue cover which is comparable to our study. Bourne *et al.* reported a 25% non-union rate in type III fractures (Ruedi-Allgower) treated by ORIF. On the other hand Sands [20] reported only one case of non-union in 64 patients treated with ORIF. Other authors have reported non-union rates varying from 0 to 12% [21-24]. In our series three patients had malunion (11%), and one patient showed radiological evidence of osteoarthritis at final follow-up (at the end of 18 months). Other series have reported variable rates of malunion ranging from 3 to 42% [25, 26].

Prevention of infection and early fracture healing depend on the adequacy of the debridement, targeted antibiotic usage, stable skeletal fixation and immediate obliteration of the dead space by a healthy soft tissue cover. Factors associated with infection are gross contamination, delay presentation and systemic comorbidities. Our infection rate was low at 7.6%. In a series of fifty-six pilon fractures that included twenty-two open injuries Sirkin *et al.* reported an overall rate of infection of 5.3% and an 11% rate in the subset of patients with an open fracture. Chen *et al.* [27] reviewed the outcome of a series of thirty-eight open and ninety closed fractures treated with delayed open reduction and internal fixation, reported a 5.5% rate of deep infection and a 3.1% rate of osteomyelitis. Conroy *et al.* reported on a series of thirty-four grade-IIIB open pilon fractures that were managed with early open reduction and internal fixation and free tissue transfer with infection developed in 18.7% of the patients and amputation was required in 6.2% [28]. In our study, two (7%) of twenty-six patients were diagnosed as having a deep wound infection. No patient had development of chronic osteomyelitis. One patient developed deep infection with non-union which was managed by implant removal and debridement with antibiotic bead insertion followed by replating and bone-grafting and another patient had chronic infection with delayed union which was managed by plate removal and antibiotic bead insertion which was removed after fracture union. Two patients (7%) developed superficial infection which was managed by culture specific antibiotics.

We attribute this lower infection rate to aggressive initial debridement and provisional stabilization, routine second-look debridement, subsequent debridement as needed, stable definitive fixation, and an appropriate antibiotic regimen. We also maintained a low threshold for free tissue transfer as we believe that healthy vascularized free flaps obliterate dead space and increase local blood flow, thus aiding wound healing and decreasing the risk of infection [15, 29, 30].

Post-traumatic arthritis affecting the ankle joint may occur following pilon fractures. Studies have shown that the final functional result after pilon fractures correlates strongly with the accuracy of articular reduction [6, 22, 31]. One patient in our series had radiological evidence of ankle-joint arthritis at final follow-up (end of two years). A review of literature reveals that studies reporting results of ORIF for pilon fractures quote a salvage arthrodesis rate of 0–26% [32, 33, 12]. We assume that our use of internal fixation allowed accurate reconstruction of the articular surface thus reducing the incidence of joint problems.

In this study, we assessed functional outcome using a validated scoring system by IOWA ankle scoring system. Results based on IOWA ankle scoring system showed excellent outcome in 2 patients, poor outcome in 4 patients, good outcome in 9 patients and fair outcome in 11 patients.

The importance of this study in the developing countries emphasised that outcomes of severe Grade 3A/B open fractures managed with a standardised "fix and flap" protocol using emergency external fixator and immediate wound cover with definitive fixation is encouraging and improved patient compliance. This aggressive management protocol for complex open pilon fractures conventionally reduce multiple surgeries would be a good option to decrease hospital stay and financial burden to the society. Overall, the results show that in grade-III open fractures of the distal tibia, modern techniques of management combining the skills of experienced orthopaedic and plastic surgeons can consistently restore excellent limb function in a very high proportion of patients.

Conclusion

Open distal tibial fractures are not uncommon, treatment modality remains diverse and this should be individualised with individual fracture pattern and soft tissue condition. Immediate management with aggressive radical debridement outside the zone of injury and temporary stabilization with external fixator allows for soft tissue healing and prevention of infection. Open reduction and internal fixation allows for accurate articular reduction there by preventing early arthritis and achieving functional range of motion. Early soft tissue cover with healthy vascularized free flaps allows for reduction in deep infection rate and provides shorter time to fracture union. Combined orthopaedic and plastic surgery approach results in good functional outcome with less complication. All our patients were satisfied for retaining their limbs. Our protocol, consisting of early fracture stabilisation and soft-tissue cover, appears to provide good functional outcome with low infection and ankle-fusion rates.

References

1. Bourne RB, Rorabeck CH, Macnab J. Intra-articular fractures of the distal tibia: the pilonfracture. *J Trauma* 1983;23:591-6.
2. Pollak AN, McCarthy ML, Bess RS, Agel J, Swiontkowski MF. Outcomes after treatment of high-energy tibial plafond fractures. *J Bone Joint Surg* 2003;85(10):1893-1900
3. Rüedi TP, Allgöwer M. Fractures of the lower end of the tibia into the anklejoint. *Injury*.1969;1:92-9.
4. Pierce R, Heinrich J. Comminutedintraartic- ular fractures of the distal tibia. *J. Bone Joint Surg* 1979;19:828
5. Ovadia DN, Beals RK. Fractures of the tibial plafond. *J Bone Joint Surg Am* 1986;68:543-51.

6. Teeny SM, Wiss DA. Open reduction and internal fixation of tibial plafond fractures. *ClinOrthop* 1993;292:108-117
7. Anglen JO. Early outcome of hybrid external fixation for fracture of the distal tibia. *J Orthop Trauma* 1999;13(2):92-97.
9. Gustilo RB, Anderson JT. Prevention of infection in the treatment of one thousand and twenty-five open fractures of long bones: retrospective and prospective analysis. *J Bone Joint Surg [Am]* 1976;58-A:453-8.
10. Merchant TC, Dietz FR. Long-term follow-up after fractures of the tibial and fibular shafts. *J Bone Joint Surg Am* 1989;71(4):599-606.
11. Watson JT, Moed BR, Karges DE, Cramer KE. Pilon fractures. Treatment protocol based on severity of soft tissue injury. *ClinOrthop* 2000;375:78-90.
12. Schmutz B, Wullschlegel ME, Kim H *et al.* Fit assessment of anatomic plates for the distal medial tibia. *J Orthop Trauma* 2008;22(4):258-263.
13. Scheck M. Treatment of comminuted distal tibial fractures by combined dual-pin fixation and limited open reduction. *J Bone Joint Surg Am* 1965;47:1537-53.
14. Daniel RK, Taylor GI. Distant transfer of an island flap by microvascular anastomoses: a clinical technique. *Plast Reconstr Surg* 1973;52:111-17
15. Chang N, Mathes SJ. Comparison of the effect of bacterial inoculation in musculocutaneous and random pattern flaps. *Plast Reconstr Surg* 1982;70:1-10.
16. Mathes SJ, Alpert BS, Chang N. Use of the muscle flap in chronic osteomyelitis: experimental and clinical correlation. *Plast Reconstr Surg* 1982;69:815-29.
17. Godina M. Early microsurgical reconstruction of complex trauma of the extremity. *Plast Reconstr Surg* 1986;78:285-92.
18. Tornetta P, Weiner L, Bergman M, *et al.* Pilon fractures: treatment with combined internal and external fixation. *J Orthop Trauma* 1993;7(6):489-496.
19. Hertel R, Lambert SM, Muller S, Ballmer FT, Ganz R. On the timing of soft-tissue reconstruction for open fractures of the lower leg. *Arch Orthop Trauma Surg* 1999;119:7-12.
20. Gopal S, Majumder S, Batchelor AG, Knight SL, De Boer P, Smith RM. Fix and flap: the radical orthopaedic and plastic treatment of severe open fractures of the tibia. *J Bone Joint Surg [Br]* 2000;82:959-966.
21. Sands A, Grujic L, Byck DC, Agel J, Benirschke S, Swiontkowski MF. Clinical and functional outcomes of internal fixation of displaced pilon fractures. *ClinOrthop* 1998;347:131-7.
22. Wyrsch B, McFerran MA, McAndrew M, Limbird TJ, Harper MC, Johnson KD *et al.* Operative treatment of fractures of the tibial plafond. A randomized, prospective study. *J Bone Joint Surg [Am]* 1996;78:1646-1657.
23. Babis GC, Vayanos ED, Papaioannou N, Pantazopoulos T. Results of surgical treatment of tibial plafond fractures. *ClinOrthop* 1997;341:99-105.
24. Pugh KJ, Wolinsky PR, McAndrew MP, *et al.* Tibialpilon fractures: a comparison of treatment methods. *J Trauma* 1999;47(5):937-941.
25. Patterson MJ, Cole JD. Two-staged delayed open reduction and internal fixation of severe pilon fractures. *J Orthop Trauma* 1999;13(2):85-91.
26. Ruedi TP, Allgower M. The operative treatment of intra-articular fractures of the lower end of the tibia. *Clin Orthop Relat Res* 1979;(138):105-110.
27. Ovadia DN, Beals RK. Fractures of the tibial plafond. *J Bone Joint Surg Am* 1986;68(4):543-551.
28. Chen SH, Wu PH, Lee YS. Long-term results of pilon fractures. *Arch Orthop Trauma Surg* 2007;127(1):55-60.
29. Conroy J, Agarwal M, Giannoudis P, Matthews S. Early internal fixation and soft tissue cover of severe open tibialpilon fractures. *Int Orthop* 2003;27(6):343-347.
30. Boraiah S, Kemp TJ, Erwtaman A, Lucas PA, Asprinio DE. Outcome following open reduction and internal fixation of open pilon fractures. *J Bone Joint Surg Am* 2010;92(2):346-352.
31. Guzman-Stein G, Fix RJ, Vasconez LO. Muscle flap coverage for the lower extremity. *ClinPlast Surg* 1991;18:545-52.
32. Tornetta P, Gorup J. Axial computed tomography of pilon fractures. *Clin Orthop Relat Res* 1996;(323):273-276.
33. Bone L, Stegemann P, McNamara K, Seibel R. External fixation of severely comminuted and open tibialpilon fractures. *Clin Orthop* 1993;292:101-107.
34. Kellam JF, Waddell JP. Fractures of the distal tibial metaphysis with intra-articular extension—the distal tibial explosion fracture. *J Trauma* 1979;19(8):593-601.