

E-ISSN: 2395-1958
P-ISSN: 2706-6630
IJOS 2020; 6(4): 145-148

www.orthopaper.com
Received: 08-08-2020
Accepted: 13-09-2020

Dr. Sunil Gottipati
Assistant Professor, Department of Orthopaedics, Gitam Institute of Medical Sciences and Research (GIMSR), Visakhapatnam, Andhra Pradesh, India

Dr. Rajashekhar Tati
Assistant Professor, Department of Orthopaedics, Gitam Institute of Medical Sciences and Research (GIMSR), Visakhapatnam, Andhra Pradesh, India

Corresponding Author:
Dr. Rajashekhar Tati
Assistant Professor, Department of Orthopaedics, Gitam Institute of Medical Sciences and Research (GIMSR), Visakhapatnam, Andhra Pradesh, India

Is there a role of primary bone grafting for communited supracondylar femur fractures?

Dr. Sunil Gottipati and Dr. Rajashekhar Tati

DOI: https://doi.org/10.22271/ortho.2020.v6.i4c.2331

Abstract
The locking compression plate (LCP) forms a fixed angle construct and enables to achieve rigid fixation for a supracondylar fracture of distal femur. This however improved functional outcome owing to early return to function, but stiffness of construct also yielded non union as primary complication. We reviewed our experience with distal femur LCP in distal end femur fractures in this case series and evaluate the role of bone graft in communited supracondylar femur fractures. 22 patients included are those with supracondylar fractures and distal third fractures of femur with or without intra articular extension. Polytrauma and patients with injury to same limb earlier were excluded from the study. Results were discussed and analysed. We conclude that primary bone grafting at the time of initial fixation of such comminuted fractures by locking plates will fasten the healing process with early added protection of the construct leading to shorter union time and good functional outcome.

Keywords: Distal femur fractures, supracondylar fractures, bone grafting in supracondylar fractures, DF-LCP in supracondylar fractures

Introduction
About 30% of all femoral fractures occur in the supracondylar region [1, 2]. There is a bimodal distribution of fractures based on age and gender. Most high-energy supracondylar fractures occur in males between 15 and 50 years, while most low-energy fractures occur in osteoporotic women [3]. The most common high-energy mechanism of injury is a traffic accident and the most common low-energy mechanism is a fall at home. Anatomic and functional restoration of a distal femoral fracture is a challenge [4]. Various implants were used earlier but were now replaced by distal femur locking plates which are very successful in treating these injuries. The locking compression plate (LCP) forms a fixed angle construct and enables placement of the plate without any contact to the bone acting as internal fixator device. The pull-out strength of locking screws is substantially higher than that of conventional screws, and it is difficult for one screw to pull out or fail unless adjacent screws also do so. The preservation of osseous viability using indirect reduction methods has led to an increase in fracture union rates in distal femur fractures treated by MIPO. Interfragmentary compression is not obtained when these locked plates are used to bridge comminuted distal femur fractures; thus, healing must occur by secondary bone healing with callus formation between the fragments. Delayed or non union often results in cases treated with distal femur LCP. Recent clinical studies substantiate the concern that the inherently high stiffness of locked-plate constructs suppresses callus formation with deficient healing and may also contribute to late hardware failures seen with locking plates [5]. We review our experience with distal femur LCP in distal end femur fractures in this case series and evaluate the role of bone graft in communited supracondylar femur fractures.

Methodology
22 patients included are those with supracondylar fractures and distal third fractures of femur with or without intra articular extension. Polytrauma and patients with injury to same limb earlier were excluded from the study.

Surgical technique

The lateral approach provides easy access to the shaft of the femur, the incision is made beginning at the knee joint and extending proximally 4" – 6" depending upon the level of the fracture site. The ilio-tibial band and the vastus lateralis muscle are longitudinally incised. By dissecting close to the bone expose the antero- lateral surface of the femur at the fracture site by retracting the anterior part of the vastus lateralis muscle anteriorly and avoid the supra patellar pouch. The bone ends were trimmed. If there was reduced and fixed with a cancellous screw after making drill- holes, and the supra condylar element was reduced. The reconstituted condyles could then be aligned primarily with the femoral shaft. In fractures with more than two condylar fragments, extra screws were needed for fixation. After accurate reduction the distal part aligned to the diaphyseal fragment with the locking plate. The plate was fixed to the shaft with screws either by minimal invasive approach or in cases of compound fractures and bone loss by opening the fracture site. In some cases there was a gap after aligning the fragments. This gap was filled with autogenous bone grafts taken from the iliac crest. Then the tourniquet was released and haemostasis secured suction drain tube is kept inside the wound and the wound was closed in layers. Well-padded dressing was given. The blood loss is adequately replaced. The patients were reviewed every four weeks. The clinical radiological union of the fractures were assessed. At every follow up until 2 years, the functional outcome as measured by Schatzker and Lambert and radiological outcome was documented and analysed [6].

Results

A total of 22 patients with communited supracondylar fractures of distal femur with or without intercondylar extension are enrolled in the study. All the cases underwent ORIF with Distal femur LCP fixation. All the 22 cases had autografting of iliac crest bone graft in the communited fracture gap. Patients were followed up for a mean period of 13 months postoperatively (ranging from 7 to 28 months). Union was defined as the presence of bridging callus of three of the four cortices and disappearance of the fracture line on the plain radiographs for a patient who was able to bear full weight, with the area of comminution-bone graft completely incorporated, amalgamated, and remodelled with the proximal and distal ends of the comminuted fractures. Radiological results in this study were evaluated according to the ASAMI radiological scoring system [7]. Functionally, results were assessed according to the Schatzker and Lambert functional criteria [8]. All fractures united with acceptable alignment in AP, oblique, and lateral views, with a mean union time of 16.2 weeks (ranging from 13 to 28 weeks). Radiologically, excellent results were obtained in 22 cases (representing 100% of the studied cases). Functionally, excellent results were obtained in eighteen cases (representing 81.8% of the studied cases). Good results were obtained in four cases (representing 18.2% of the studied cases). No cases had fair or poor results. Thus, satisfactory results (excellent and good results) were obtained in all cases of the studied group.

Pre-op X-ray Immediate post-op X-ray 6 months follow up

Fig 1: Pre and post op X rays of communited distal femur fracture with intercondylar extension treated with ORIF and distal femur LCP + primary bone grafting. Note secondary brindging callus formed in 6 months follow up

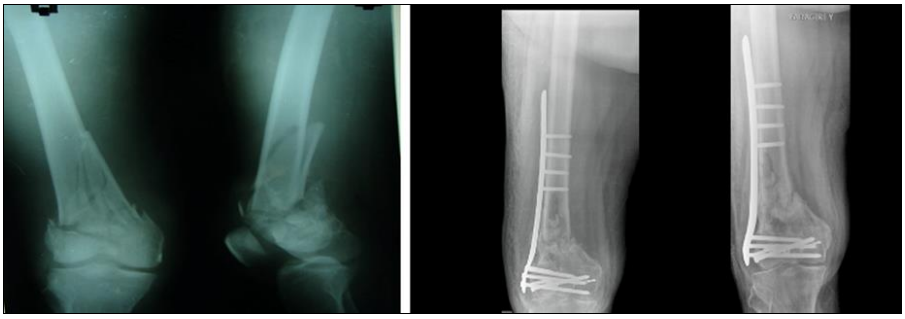

Pre-op X-ray Immediate post-op X-ray

Fig 2: Pre and post op X rays of communited distal femur fracture with intercondylar extension treated with ORIF and distal femur LCP + primary bone grafting

Fig 3: Pre and post op X rays of communited distal femur fracture with intercondylar extension treated with ORIF and distal femur LCP + primary bone grafting

Discussion

Distal end femur fractures treated with distal femur LCP have undoubtedly improved the outcome of the injuries returning to early function. These fixed angle constructs have been used to span an area of comminution with improved security at the screw-bone interface. Despite the widespread use and popularity of lateral locked-plate fixation of distal femur fractures, concern exists regarding the clinical outcomes achieved with these constructs. Recent clinical and basic science evidence suggests that the increased stiffness provided by the distal femur locked plates may lead to delayed union or nonunion, with up to 32% of patients having difficulty to achieve healing of their fracture [4]. Zlowodzki *et al.* [9] analyzed the outcome of many studies as part of a systematic literature review and concluded that average nonunion, fixation failure, deep infection, and secondary surgery rates were 5.5, 4.9, 2.1, and 16.2%, respectively. In this study, the fixation of these comminuted fractures with distal femoral locking plates through the standard open approach and indirect reduction using manual traction with preservation of the periosteal attachment of the comminuted fragments has the advantage of decreasing the incidence of malunion, with only one case (representing 9.1% of the studied cases) that had varus deformity of less than 7°.

Papakostidis *et al.* [10] reported a malunion rate of 0-29% for femur fractures treated with plate and screws using the biological fixation technique. They found that the cause of malunion was generally inadequate intraoperative reduction in some cases with displaced comminuted fractures fixed by LISS or MIPO. According to Schütz *et al.* [18] closed reduction of comminuted fractures may be difficult, and this could be the cause of malunion. They believed that the malunion rate correlates with inadequate intraoperative reduction rather than the selected fixation method of intramedullary nail or plate and screws [10]. Regarding the added role of primary grafting in fracture union, all cases united in a relatively short period of time (the mean union time was 16.2 weeks, ranging from 13 to 28 weeks) despite the high-energy nature of trauma and the fracture comminution compared with other studies. The addition of primary bone grafting to the area of comminution was the cornerstone for rapid and secure healing with no need for second open intervention, which is usually delayed grafting in many studies. The role of delayed bone grafting as a secondary procedure for treatment of cases with delayed union or nonunion was documented in a study presented by Philip *et al.* [11]. They documented that 7% of all fractures eventually failed to heal with secondary procedures including bone grafting. Another study attributed nonunion to the severity of comminution and bone loss and documented that it is better in these cases to perform primary grafting [12].

Zlowodzki *et al.* [9] declared that one of the technical errors that have been reported for fixation failure was waiting too long to bone graft the defects. Pascarella *et al.* [13] reported two patients in their study with nonunion who were treated with cancellous autograft 32 weeks after the first surgery and documented that both cases healed at about 3.5 months after the second surgery.The race between implant failure and bone healing is a standard rule in internal fixation. Whatever the strength and material modifications, implants will fail if healing is hindered by deficient callus formation. For a lateral distal femoral plate, plate bending induces more stresses medially leading to increased chances for implant failure. Thus, an intact or restored medial cortex of the femur is an important protector against implant failure. Numerous studies have shown that the mechanical conditions at the fracture site, principally the fixation stability, influences callus formation during fracture healing [14].

In comminuted fractures, locked plates function in a bridge plate mode that provides relative stability. Fracture healing in this situation will occur with callus formation through secondary or indirect fracture healing. When the fracture gap is too great or the amount of interfragmentary motion is too little, adequate callus formation cannot occur with high incidence of nonunion and implant failure [15]. Using the recommendations of Hak *et al.* [16] about the effect of large fracture gap and its role in decreasing callus formation, primary bone grafting can abolish these gaps and promote healing depending on the biological properties of bone grafting (osteogenesis, osteoinduction and osteoconduction). This can mechanically protect the construct with decreased incidence of implant failure. Even with the use of titanium plates with decreased number of screws to decrease the stiffness of locked plating constructs, asymmetric callus

formation with the largest periosteal callus was observed at the medial cortex with deficient callus formation laterally under the plate [11]. This also contributed to implant failure. By using primary bone grafting in the comminuted area medially and between the plate and lateral comminuted cortex of the femur also we can also overcome this problem.

The limitations of this study are the small number of patients included and the absence of a control group, which did not enable us to draw sound conclusions. However, these limitations do not undermine the results achieved by this study and by other presented studies [11-14].

Conclusion

Primary bone grafting can overcome the reported drawbacks of high stiffness of the locked constructs that hinders inter-fragmentary motion at the fracture site leading to deficient callus formation with subsequent high rates of non-union and failure. Whatever the strength of the construct, biological failure will inevitably lead to a mechanical failure. It is clear that primary bone grafting at the time of initial fixation of such comminuted fractures by locking plates will fasten the healing process with early added protection of the construct leading to shorter union time and good functional outcome.

References

1. Schatzker J, Home G, Waddell J. The Toronto experience with the supracondylar fracture of the femur, 1966-72. Injury. 1974; 6:113–28.
2. Martinet O, Cordey J, Harder Y, Maier A, Buhler M, Barraud GE. The epidemiology of fractures of the distal femur. Injury. 2000; 31(3):C62-C63.
3. Campbell WC. Campbell's orthopaedics. Canale ST, editor. St Louis: Mosby, 1998, 2686.
4. Nasr AM, McLeod I, Sabboubeh A, Maffulli N. Conservative or surgical management of distal femoral fractures. A retrospective study with a minimum five year follow-up. Acta Orthop Belg. 2000; 66:477-83.
5. Thomas TL, Meggitt BF. A comparative study of methods for treating fractures of the distal half of the femur. J Bone Joint Surg. Br. 1981; 63:3-6.
6. Perren SM. Evolution of the internal fixation of long bone fractures. The scientific basis of biological internal fixation: choosing a new balance between stability and biology. J Bone Joint Surg Br. 2002; 84:1093-110.
7. Chaddha M, Gulati D, Singh AP, Singh AP, Maini L. Management of massive posttraumatic bone defects in the lower limb with the Ilizarov technique. Acta Orthop Belg. 2010; 76:811-820.
8. Schatzker J, Lambert DC. Supracondylar fractures of the femur. Clin Orthop Relat Res. 1979; 138:77-83.
9. Zlowodzki M, Bhandari M, Marek DJ, Cole PA, Kregor PJ. Operative treatment of acute distal femur fractures: systematic review of 2 comparative studies and 45 case series (1989 to 2005). J Orthop Trauma. 2006; 20:366-371.
10. Papakostidis C, Grotz MR, Papadokostakis G, Dimitriou R, Giannoudis PV. Femoral biologic plate fixation. Clin Orthop Relat Res. 2006; 450:193-202.
11. Philip JK, James AS, Michael Z, Peter AC. Treatment of distal femur fractures using the less invasive stabilization system surgical experience and early clinical results in 103 fractures. J Ortop Trauma. 2004; 18:50-59.
12. Ahmed Mohamed MA. Biological fixation of closed comminuted distal femur fractures using the less invasive stabilization system (LISS). El-Minia Med Bull. 2008; 19:33-39.
13. Pascarella R, Bettuzzi C, Bosco G, Leonetti D, Dessý S, Forte P, Amendola L. Results in treatment of distal femur fractures using polyaxial locking plate. Strategies Trauma Limb Reconstr. 2014; 9:13-18.
14. Claes LE, Heigele CA, Neidlinger-Wilke C, Kaspar D, Seidl W, Margevicius KJ, Augat P. Effects of mechanical factors on the fracture healing process. Clin Orthop Relat Res. 1998; 355:S132-S147.
15. Lujan TJ, Henderson CE, Madey SM, Fitzpatrick DC, Marsh JL, Bottlang M. Locked plating of distal femur fractures leads to inconsistent and asymmetric callus formation. J Orthop Trauma. 2010; 24:156-162.
16. Hak DJ, Toker S, Yi C, Toreson J. The influence of fracture fixation biomechanics on fracture healing. Orthopedics. 2010; 33:752-755.