



International Journal of Orthopaedics Sciences

E-ISSN: 2395-1958
P-ISSN: 2706-6630
IJOS 2020; 6(3): 707-709
© 2020 IJOS
www.orthopaper.com
Received: 02-05-2020
Accepted: 16-06-2020

Dr. Alok C Patil
Assistant Professor, Department
of Orthopaedics, Mahadevappa
Rampure Medical College,
Kalaburagi, Karnataka, India

Dr. Santhosh Kumar Raju K
Junior Resident, Department of
Orthopaedics, Mahadevappa
Rampure Medical College,
Kalaburagi, Karnataka, India

Dr. Mohit Kolhapure
Sr. Resident, Department of
Orthopaedics, Sanjay Gandhi
Institute of Trauma &
Orthopaedics, Bengaluru,
Karnataka, India

Corresponding Author:
Dr. Alok C Patil
Assistant Professor, Department
of Orthopaedics, Mahadevappa
Rampure Medical College,
Kalaburagi, Karnataka, India

Two level osteotomies in bilateral genu valgum: A case report

Dr. Alok C Patil, Dr. Santhosh Kumar Raju K and Dr. Mohit Kolhapure

DOI: <https://doi.org/10.22271/ortho.2020.v6.i3k.2274>

Abstract

Genu valgum is Latin derived term, commonly known as knock-knees, in which there is outward deviation of legs so that there is medial angulation at the knee. They are spontaneously corrected by 7 years of age. It is deemed that valgus (femorotibial alignment) of more than 15° (taking into consideration the measuring error) above 8 years of age is pathological. There are wide array of treatment options for deformity prevention & correction. We report an 18-year-old male who noticed progressive deformity in his bilateral knees for 7 years with bilateral knee pain & problems while walking. After necessary investigations and pre-operative planning, patient underwent two level osteotomies – distal lateral femur open wedge osteotomy with bone grafting and proximal medial tibial closed wedge osteotomy augmented with fibula osteotomy. At final follow-up, the patient has a good functional result.

Keywords: Genu valgum, osteotomy, knock-knees

Introduction

Genu valgum is Latin derived term, commonly known as knock-knees, in which there is outward deviation of legs so that there is medial angulation at the knee. They are spontaneously corrected by 7 years of age. It is deemed that valgus (femorotibial alignment) of more than 15° (taking into consideration the measuring error) above 8 years of age is pathological. In most cases this represents a variation in the normal growth pattern and is an entirely benign condition. Excessive valgus deformity (say >20°) in a child older than 4 years may be associated with numerous conditions, including idiopathic genu valgus, skeletal dysplasia, metabolic bone disease and renal abnormalities.

Genu valgum not only presents as cosmetic deformity but also affects the gait by rubbing the knees while running. It effects Q angle and predispose patella for dislocation. The weight bearing shifts to the medial aspect of foot giving the flat foot appearance and needs frequent foot wear change.

To manage the problem properly, first we should determine the cause of abnormal genu valgum by careful history taking, physical examination, and appropriate imaging studies. For persistent genu valgum, treatment recommendations have included a wide array of options, ranging from lifestyle modifications, NSAID's, bracing, physiotherapy. In recalcitrant cases, surgical procedures include hemiepiphyodesis & osteotomies around knee.

Case Report

We report an 18-year-old male who noticed progressive deformity in his bilateral knees for 7 years with bilateral knee pain & problems while walking.

On clinical examination, there was bilateral valgus deformity, the deformity was obliterated when flexed suggesting femur component. The inter-malleolar distance was 30cms.

We measured the deformities with both knees having 26 degrees of genu valgum. His blood investigations (including endocrinological parameters) were within normal limits.

The lengths of the wedge size for osteotomies were calculated using trigonometry over the scanogram. A 20 degree total correction was planned. A 15 degree roughly equal to 15mm wedge was planned on distal femur & 5 degree roughly equal to 5mm wedge was planned on proximal tibia.

After counseling the patient regarding corrective osteotomy & its associated complications and written & informed consent for surgery obtained, patient was posted for surgery.

Surgical Procedure

- After giving Spinal Anesthesia & Epidural Anesthesia, patient placed in supine position with high thigh tourniquet.
- Under aseptic precautions, parts were painted & draped.
- Initial, direct lateral approach was taken for distal femur. After adequate exposure, oscillating saw was used to cut the distal femur under C-arm guidance. Open wedge osteotomy was performed using lamina spreader to gain length of 15mm, iliac bone graft was placed & the osteotomy held with distal femur LCP.
- Incision was taken over proximal 1/3rd shaft of fibula & proximal fibular osteotomy was performed.
- Incision was taken over the medial tibia. After adequate exposure, tibia closed wedge osteotomy of 5 mm was performed & maintained by medial T-butress plate.
- Intra-operative mechanical axis of the lower limb was evaluated.
- Wound was closed in layers & pressure dressing applied.
- The same procedure was done on the contralateral limb after 3 months.

Post-operative protocol

Patient was taught Quadriceps strengthening exercises & Knee ROM exercises from post-operative day 2 and was allowed weight bearing from 4th week.

Complications

Patient developed superficial wound infection over Right fibular osteotomy which was addressed by debridement & re-suturing and appropriate antibiotic.

Follow-Up

Patient regularly followed up till 6months. At 6th month, Patients valgus on Right side was 6 degree and on Left side was 5 degree with inter-malleolar distance of 12mm.

Discussion

Angular deformities around knee joint are commonly presented in pediatric population. Most of these patients comes to hospital because of cosmetic problem. Majority of

these patients passes through the normal stages of development with Physiological Genu Varum and Physiological Genu Valgum. For these patients no intervention is needed. Only counselling and reassurance to the parents and follow-up at appropriate intervals is sufficient. It is necessary to differentiate between physiological causes of angular knee deformity and others in order to prevent unnecessary and avoidable subjection of child to a surgical procedure which was not required at all. In the past techniques like corrective osteotomies with external or internal fixation were used for correction of angular knee deformities. As these techniques were more invasive nowadays less invasive techniques used for correcting deformity in immature children. Distal femoral Metaphyseal osteotomy corrects deformity at level of CORA with no need of any translation at osteotomy site. With intact medial cortical hinge and stable fixation, bone graft can be avoided without any risk of failure.

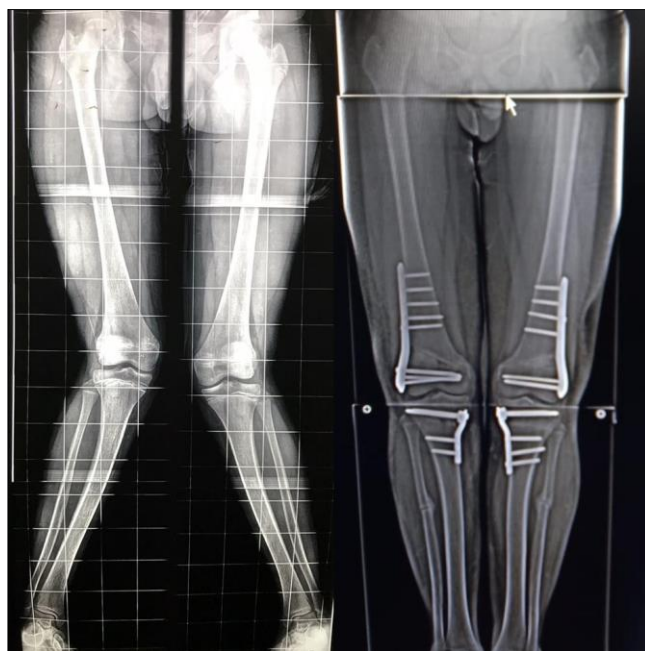

Fig 1: Pre-operative & Post-operative Scanogram

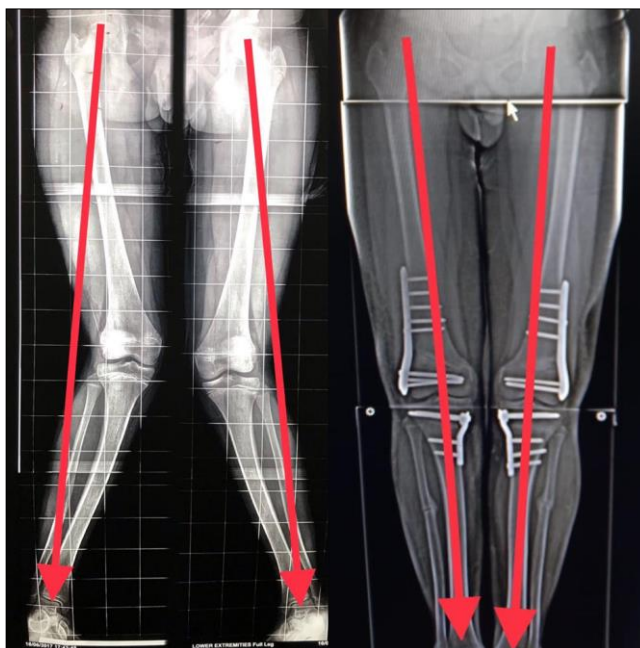


Fig 2: Pre-operative & Post-operative Mechanical Axis of the lower limb

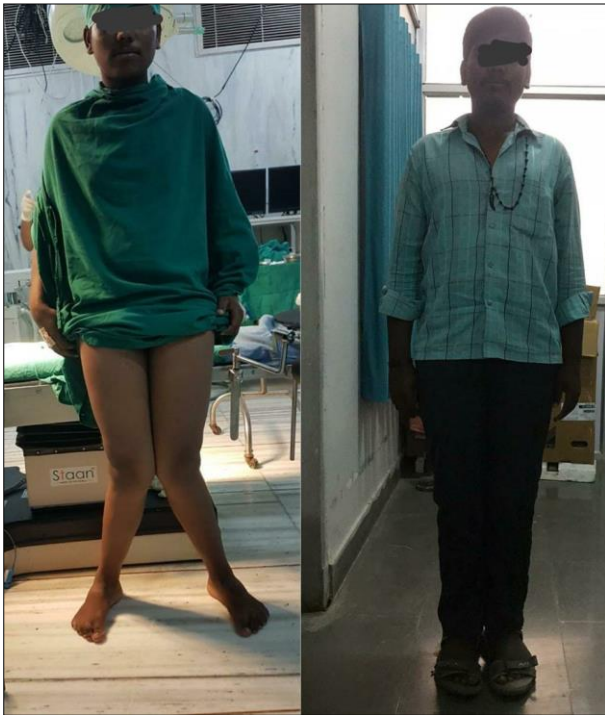

Fig 3: Pre-operative & Post-operative Clinical Photos

Conclusion

A two level osteotomy is a viable option for valgus osteotomy in patients who have attained skeletal maturity. In our study, we found significant relief of pain, function, range of motion and overall satisfaction of the patient. We also concluded that it is a technically demanding procedure and requires a long learning curve.

References

1. Paley D, Herzenberg JE, Tetsworth K, McKie J, Bhave A. Deformity planning for frontal and sagittal plane corrective osteotomies. *Orthop Clin North Am.* 1994; 25(3):425-65.
2. Puddu G, Cipolla M, Cerullo G, Franco V, Gianni E. Osteotomies: the surgical treatment of the valgus knee. *Sports Med Arthrosc.* 2007; 15(1):15-22.
3. O'Malley MP, Pareek A, Reardon PJ, Stuart MJ, Krych AJ. Distal Femoral Osteotomy: Lateral Opening Wedge Technique. *Arthrosc Tech.* 2016; 5(4):725-730.
4. Mycoskie PJ. Complications of osteotomies about the knee in children. *Orthopaedics.* 1981; 4:1005-15.
5. McDermott PA, Finkelstein JA, Farine I *et al.* Distal femoral varus osteotomy for valgus deformity of the knee. *J Bone Jt Surg Am.* 1988; 70:110-116.
6. Arazi M, Oğün TC, Memik R. Normal development of the tibiofemoral angle in children: a clinical study of 590 normal subjects from 3 to 17 years of age. *J Pediatr Orthop.* 2001; 21:264-7.
7. Herring JA, Kling TF. Genu valgus. *J Pediatr Orthop.* 1985; 5:236.
8. Westhoff B, Wild A, Krauspe R. Development of the leg axis in childhood and treatment options for deformities near the knee joint. *Orthopade.* 2002; 31:1198-1208.
9. Ramin Espandar, Seyed Mohammad-Javad Mortazavi, Taghi Baghdadi. Angular Deformities of the Lower Limb in Children. *Asian Journal of Sports Medicine.* 2010; 1(1):46-53.