



# International Journal of Orthopaedics Sciences

E-ISSN: 2395-1958  
P-ISSN: 2706-6630  
IJOS 2020; 6(3): 610-616  
© 2020 IJOS  
[www.orthopaper.com](http://www.orthopaper.com)  
Received: 04-05-2020  
Accepted: 06-06-2020

**Dr. Tapan Jain**  
Resident, GMC Bhopal,  
Department of Orthopaedics,  
Bhopal, Madhya Pradesh, India

**Dr. Pankaj Mishra**  
Assistant Professor, GMC  
Bhopal, Department of  
Orthopaedics, Bhopal, Madhya  
Pradesh, India

**Dr. Harendra Singh**  
Resident, GMC Bhopal,  
Department of Orthopaedics,  
Bhopal, Madhya Pradesh, India

**Dr. Vipin Singh**  
Resident, GMC Bhopal,  
Department of Orthopaedics,  
Bhopal, Madhya Pradesh, India

**Dr. Anil Chouksey**  
Resident, GMC Bhopal,  
Department of Orthopaedics,  
Bhopal, Madhya Pradesh, India

**Dr. Lakshya Bhardwaj**  
Resident, Dr R N Cooper  
Municipal Medical College  
Mumbai, Department of  
Orthopaedics, Bhopal, Madhya  
Pradesh, India

**Corresponding Author:**  
**Dr. Pankaj Mishra**  
Assistant Professor, GMC  
Bhopal, Department of  
Orthopaedics, Bhopal, Madhya  
Pradesh, India

## Fracture neck of femur in elderly patients- fixation with hemiarthroplasty by posterior approach and complications

**Dr. Tapan Jain, Dr. Pankaj Mishra, Dr. Harendra Singh, Dr. Vipin Singh, Dr. Anil Chouksey and Dr. Lakshya Bhardwaj**

DOI: <https://doi.org/10.22271/ortho.2020.v6.i3j.2258>

### Abstract

The optimal approach for hemiarthroplasty is hotly debated. We analysed 60 consecutive elderly patients who underwent hemiarthroplasty. Patients were analysed for all complications, during and after surgery with special emphasis on incidence of dislocation. The results were gratifying and were comparable with major series of hemiarthroplasty via the posterior approach. 3 patients had a dislocation. 57 patients (95%) had no or minimal pain after the surgery. There were no major intra-operative complications and mean harris hip score was 86.5 at one year follow-up. We conclude that the posterior approach, already known to cause less blood loss is safe due to less intra operative and post operative complication.

**Keywords:** Hemiarthroplasty, posterior approach, harris hip score

### 1. Introduction

Hip fractures are common injuries in the elderly. There are many risk factors for femoral neck fractures, including female gender, low bone density, and reduced mobility [1, 2] Hip fractures in the elderly usually result from trivial trauma and often are associated with osteoporosis [3] and other associated medical conditions that may increase the prevalence of falls. In young adults hip fractures are rare and are due to high velocity trauma [4].

Two factors which must be considered while dealing with displaced femoral neck fractures are early mobilization and minimization of complications. These factors may be affected by selection of surgical approach. Posterior approach has been used since 1957 introduced by Moore famously known as Southern approach [5] but it has been associated with complications like posterior dislocation of prosthesis, blood loss, soft tissue injury, increase hospital stay.

The aim of this paper is to determine the intra operative and postoperative complication associated with posterior (southern) approach for hemiarthroplasty.

#### 1.1 Anatomy and Classification

The hip is a synovial joint of the ball-and-socket variety formed by the globular femoral head cupped into the acetabular or cotyloid cavity of the hip bone. It plays a major role in the static and dynamic physiology of the locomotor system and, although it is the most stable ball-and-socket joint in the body, it still maintains an extraordinary range of motion [6].

Femoral neck fractures initially were classified by Sir Astley Cooper in 1823 as either intracapsular or extracapsular, which he felt had prognostic implications [7]

Pauwels (1935) [8-10] introduced first biomechanical classification for femoral neck fractures. This classification calculates the angle between the fracture line of the distal fragment and the horizontal line to determine shearing stress and compressive force (Fig 1). The classification is described as follows

- Type I: up to 30°. Compressive forces are dominant.
- Type II: 30°–50°. Shearing force occurs and may have a negative effect on bone healing.
- Type III: 50° and more. Under these circumstances, shearing force is predominant and is associated with a significant amount of varus force which will more likely result in fracture displacement and varus collapse.

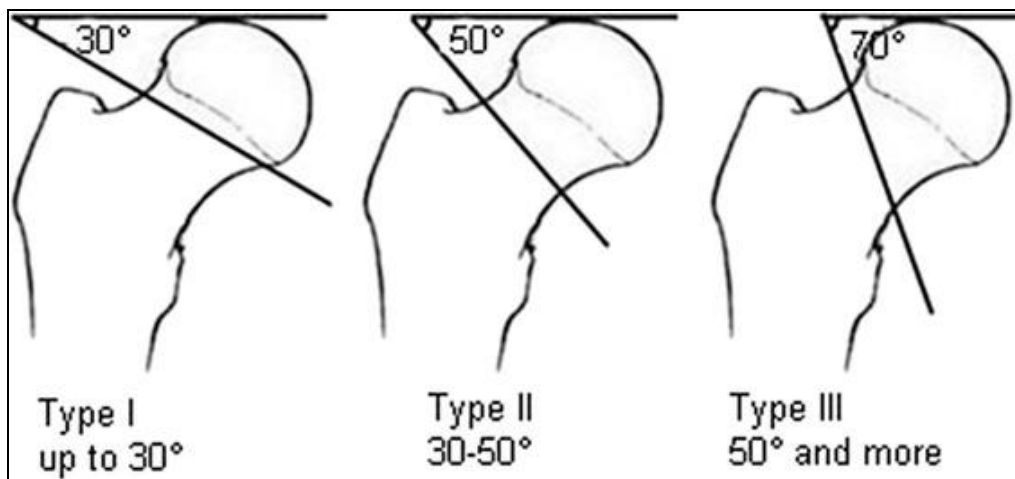


Fig 1: Pauwels Classification

Garden Robert Symon (1961) [11, 12] described a comprehensive classification. The Garden classification incorporates displacement, fracture completeness, and relationship of bony trabeculae in the femoral head and neck (Table 1) (Fig 2).

Table 1: Garden classification

Type	Description	Nondisplaced or displaced
I	Valgus impacted incomplete fracture, disruption of the lateral cortex while the medial cortex is preserved	Nondisplaced
II	Complete fracture	Nondisplaced
III	Complete fracture, partial displacement indicated by change in angle of the trabeculae	Displaced
IV	Complete fracture, complete displacement leading to parallel orientation of the trabeculae	Displaced

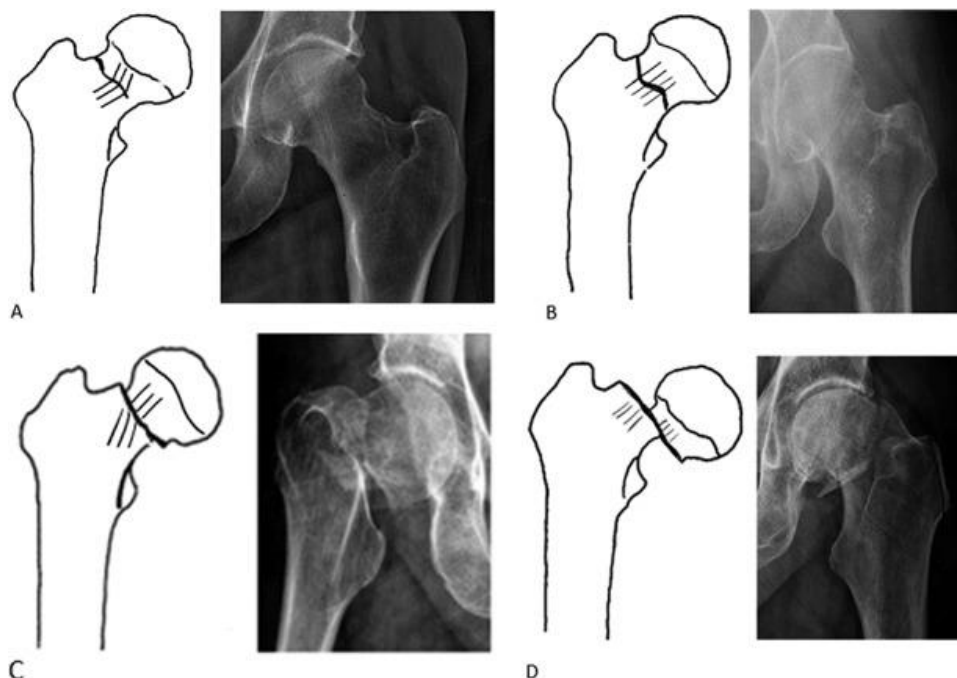


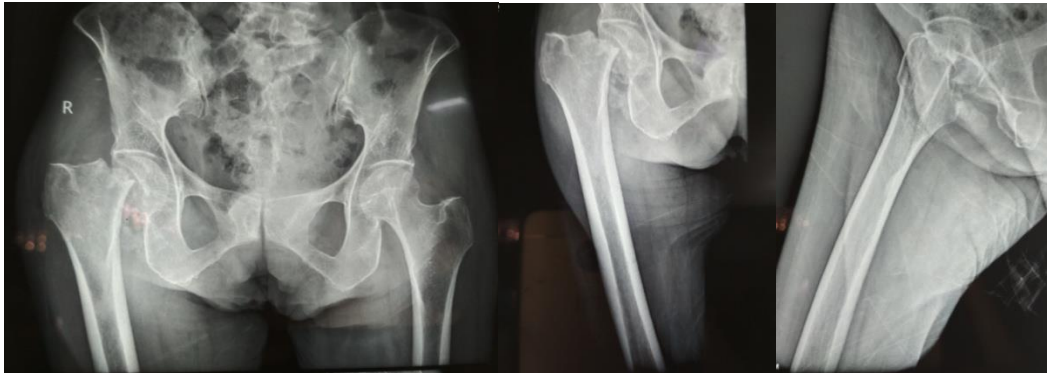Fig 2: The Garden classification is shown in the drawings and corresponding radiographs for Garden Types (A) I, (B) II, (C) III, and (D) IV femoral neck fractures.

## 2. Materials and Methods

60 patients of age >60 yrs. and both sex with fracture neck of femur operated via hemiarthroplasty using Southern approach with Austin Moore prosthesis between October 2017 to August 2019 were included in this prospective interventional study. Patients without any major hip pathology prior to the

fracture were included.

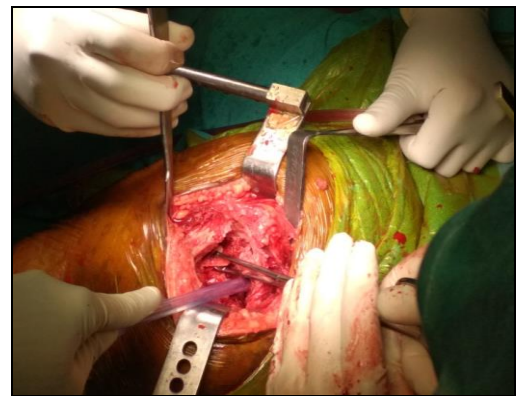
**2.1 Investigations:** Routine examination of blood, radiographic examination and necessary investigation for anaesthetic fitness were done.



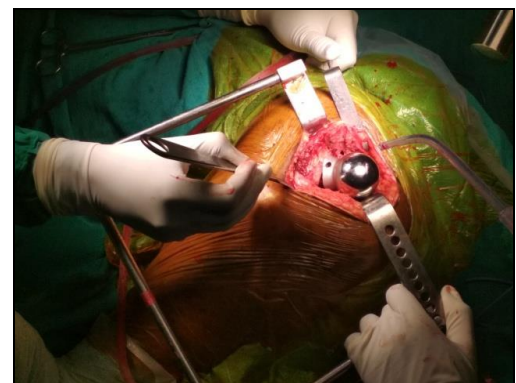
**Fig 3:** Standard X-ray in AP and lateral views.

### 2.2. Surgical Procedure for Hemiarthroplasty with Posterior Approach (Southern approach):<sup>[13-16]</sup>

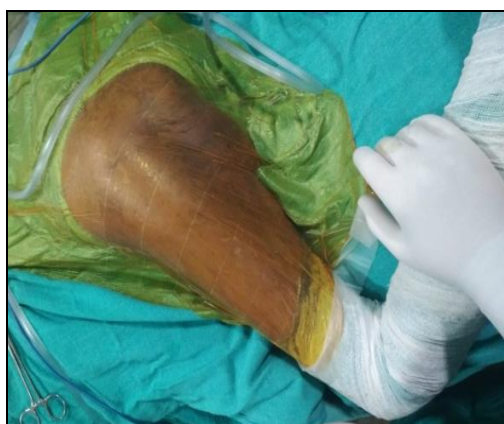Spinal anaesthesia was given. Patient was placed in lateral decubitus position. Site of the surgery was thoroughly painted with iodine and spirit and draped. The incision was given approximately 10 cm distal to the posterior superior iliac spine and extend distally and laterally parallel with the fibres of the gluteus maximus to the posterior margin of the greater trochanter. Then incision was directed distally 10 to 13 cm parallel with the femoral shaft. The deep fascia was exposed and divided in line with the skin incision. By blunt dissection, the fibres of the gluteus maximus were separated. The proximal fibres of the gluteus maximus were retracted proximally and the greater trochanter was exposed. The distal fibres were retracted distally and their insertion was partially divided into the linea aspera in line with the distal part of the incision. Next, gemelli and obturator internus and the tendon of the piriformis was exposed and divided at their insertion on the femur and these muscles were retracted medially. The posterior part of the joint capsule was well exposed. T shaped capsulotomy of the anterior capsule is made to obtain a direct approach to the femoral neck and fracture site. The posterior capsule was closed after joint replacement. Incision was closed in layers after thorough wash. Sterile dressing was done. Blood loss was calculated by counting the number of mops used and volume of suction done. Total time of surgery was counted from time of incision to dressing.



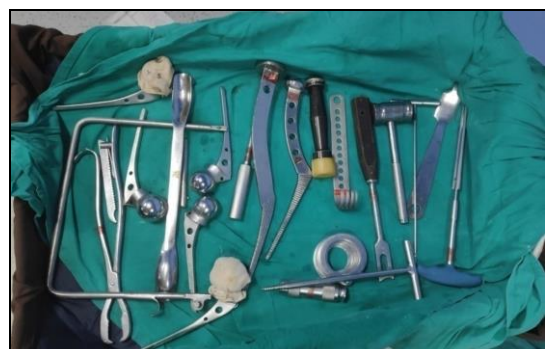**Fig 5:** Showing the head of femur



**Fig 6:** After insertion of prosthesis



**Fig 4:** Position of patient



**Fig 7:** Implant and instruments used in hemiarthroplasty

5.3) Follow Up: All patients were allowed partial weight bearing as soon as pain subsided. Clinical follow-up was carried out at 1, 6 and 12 months post surgery. At follow up, after a subjective assessment of quality of life and functional status, patients were evaluated according to Harris hip scoring system [17-19]. All the details were recorded in the follow up chart. A follow up radiograph of the pelvis was obtained at each follow up. Grading of functional outcome was done as follows.

**Table 2:** Harris Hip Score Grading

Category	Harris Hip Score
Excellent	90-100
Good	80-89
Fair	70-79
Poor	69 or less

**Pain**

- None or ignores it (44)
- Slight, occasional, no compromise in activities (40)
- Mild pain, no effect on average activities, rarely moderate pain with unusual activity; may take aspirin (30)
- Moderate pain, tolerable but makes concessions to pain; some limitation of ordinary activity or work; may require occasional pain medicine stronger than aspirin (20)
- Marked pain, serious limitation of activities (10)
- Totally disabled, crippled, pain in bed, bedridden (0)

**Limp**

- None (11)                       Moderate (5)
- Slight (8)                       Severe (0)

**Support**

- None (11)                       Two canes (2)
- Cane for long walks (7)       Two crutches (0)
- Cane most of the time (5)     Not able to walk (0)
- One crutch (3)

**Distance Walked**

- Unlimited (11)                 Indoors only (2)
- Six blocks (8)                 Bed and chair (0)
- Two or three blocks (5)

**Stairs**

- Normally without using a railing (4)
- Normally using a railing (2)
- In any manner (1)
- Unable to do stairs (0)

**Put on Shoes and Socks**

- With ease (4)       With difficulty (2)       Unable (0)

**Sitting**

- Comfortably in ordinary chair 1 hour (5)
- On a high chair for 1/2 hour (3)
- Unable to sit comfortably in any chair (0)

**Enter public transportation:**  Yes (1)  No

**Flexion contracture:** \_\_\_\_\_ (degrees)

**Leg-length discrepancy:** \_\_\_\_\_ (cm)

**Absence of Deformity (all Yes = 4; <4 = 0)**

- <30 degrees fixed flexion contracture:  Yes  No
- <10 degrees fixed adduction:  Yes  No
- <10 degrees fixed internal rotation  Yes  No
- in extension:  Yes  No
- Limb-length discrepancy <3.2 cm:  Yes  No

**Range of Motion (\*Normal)**

Total degree measurements, then check range to obtain score

- Flexion (\*140 degrees): \_\_\_\_\_ External rotation (\*40 degrees): \_\_\_\_\_
- Abduction (\*40 degrees): \_\_\_\_\_ Internal rotation (\*40 degrees): \_\_\_\_\_
- Adduction (\*40 degrees): \_\_\_\_\_

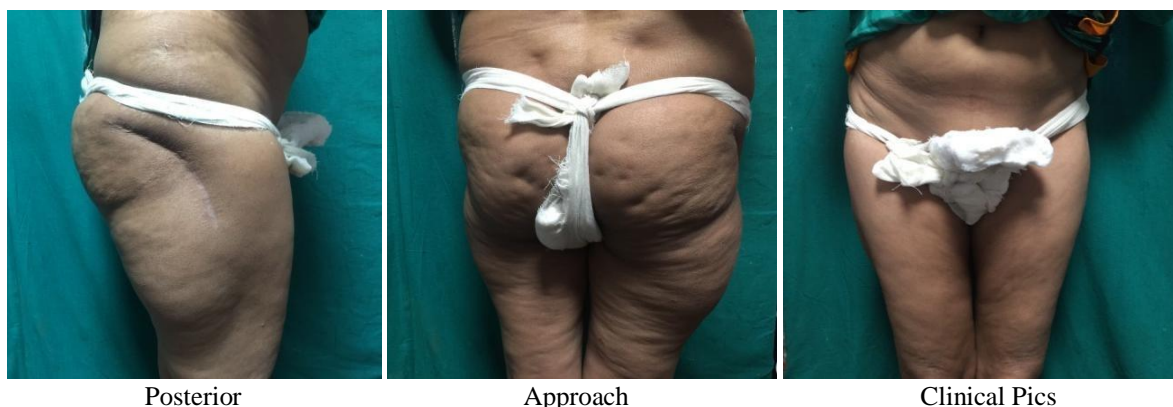**Range-of-Motion Scale**

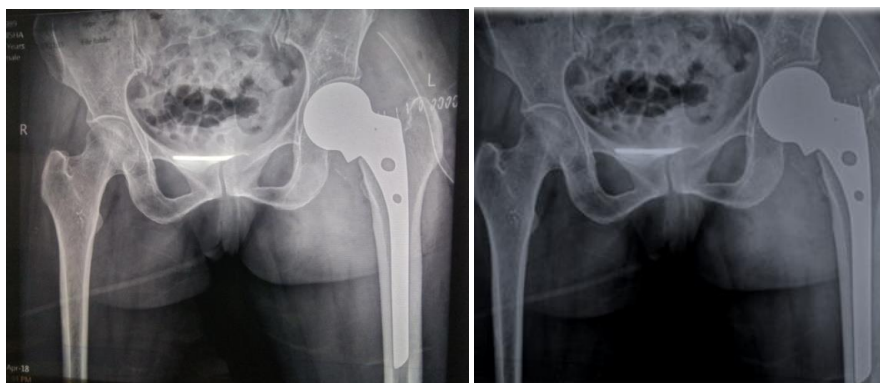
- 211-300 degrees (5)                      61-100 degrees (2)
- 161-210 degrees (4)                      31-60 degrees (1)
- 101-160 degrees (3)                      0-30 degrees (0)

**Range-of-Motion Score:** \_\_\_\_\_

**Total Harris Hip Score:** \_\_\_\_\_

**Fig 8:** Harris Hip Score

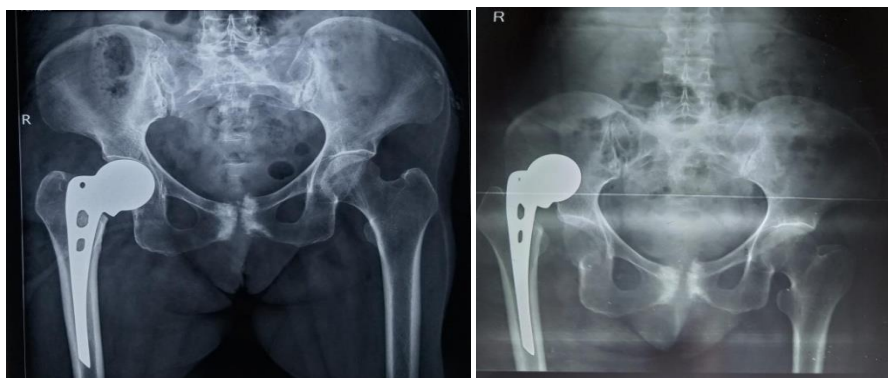




Post Op

Follow Up 1 Month

Posterior Approach Complications



Post Op

Hip Dislocation

3. Results

Table 3: Demographic Distribution

Age of patients	Total
61-70	21 (35%)
71-80	39 (65%)

In present study, out of 60 cases of posterior approach group 21 cases (35%) were in the age group of 61-70 years and 39 cases (65%) were in the age group of 71-80 years.

Table 4: Gender Distribution

Sex	Total
Male	12(20%)
Female	48(80%)

Out of 20 cases of posterior approach group 12 cases (20%) were males and 48 cases (80%) were females.

3.1 Blood loss

Table 5: Comparing Baseline Parameters

Surgical approach	Mean blood loss (in ml)
Posterior	161.00

In Present study mean blood loss in posterior approach was around 161.00 ml.

3.2. Duration of surgery

Surgical approach	Mean surgery duration (in min)
Posterior	61

In present in study mean duration of surgery in posterior approach was around 61 minutes.

3.3 Duration of post op hospital stay

Surgical approach	Mean duration (in days)
Posterior	5.45

In present in study mean duration of hospital stay in posterior approach was around 5.45 days.

Table 6: Complications

Complications	Total
Nil	54 (90%)
Posterior hip dislocation	3 (5%)
Surgical site infection	3 (5%)

Posterior approach had three patients of posterior hip dislocation and three patients of surgical site infection.

Table 7: Comparing Pain

Month	Pain	Total
1	None	18 (30%)
	Mild	9 (15%)
	Slight	30 (50%)
	Severe	3 (5%)
6	None	60 (100%)
12	None	60 (100%)

In present study, at first month, 15% patients in posterior approach had mild pain while at 6 months no pain was observed.

Table 8: Comparing Hip Range of Motion Score

Hip range of motion	Mean ROM Score
1 month	4.00
6 month	5.00
12 month	5.00

In present study it was found that the end of 1 month, 6<sup>th</sup> month and 12th month, hip range of motion score was 4, 5 and 5 respectively.

**Table 9:** Harris Hip Score

Harris hip score	Mean
1 month	74.30
6 month	86.55
12 month	86.55

In present study on comparing the Harris hip score it was found that at the end of 1 month, 6<sup>th</sup> month and 12<sup>th</sup> month Harris hip score was 74.3, 86.55,86.55 respectively.

#### 4. Discussion

This study of 60 cases of fracture neck of femur treated with hemiarthroplasty with Austin Moore Prosthesis in elderly patients of both the sexes using posterior approaches to hip. The observations were made and results were analyzed. The study was also compared with relevant studies of other authors.

The present study shows that mean blood loss in posterior approach is 161 ml. Similarly, studies of Keene G.S. *et al.* (1993) [20] and Trinh TQ *et al.* (2015) [21] reported that blood loss during surgery 197 ml and 216 ml respectively. Our results are similar to previous studies. Duration of surgery in posterior approach group was 61.8 minute in our study. Similar results were concluded by Keene G.S. *et al.* (1993) [20] and Trinh TQ *et al.* (2015) [21]. Post op hospital stay is significantly more in posterior approach. Similar results were found in studies of Trinh TQ *et al.* (2015) [21]. Lesser post operative hospital stay can be attributed to less post op pain in anterior approach group. The present study shows that post op dislocation of hip is not common but significant complication of posterior approach. Similar results were found in studies of Keene G.S. *et al.* (1993) [20], Unwin A J *et al.* (1994) [22] and Jean Langlo *et al.* (2015) [23]. More hip dislocation in posterior approach group can be attributed to disruption of posterior capsule which remains intact in the anterior approach group. Also surgical site infection is 5% in our study consistent with results of Keene G.S. *et al.* (1993) [20]. The present study shows that HHS at 1 month was 74.3, at 6 month 86.5 and at 6 month also 86.5 was observed.

#### 5. Conclusion

This single centre prospective study concludes that the intra operative complications includes blood loss which is about 160 ml (mean) in posterior approach and postoperative complications includes posterior dislocation of prosthesis which is 5%, surgical site infection which is 5%, mean length of hospital stay is around 5 days and 90% of those do not develop any complication. We believe posterior approach is safe due to less intra operative and post operative complication

#### 6. Reference

- Cummings SR, Browner W, Black DM, Nevitt MC, Genant HK, Cauley J *et al.* Bone density at various sites for prediction of hip fractures. *The Lancet.* 1993; 341(8837):72-5.
- Kannus P, Parkkari J, Sievänen H, Heinonen A, Vuori I, Järvinen M. Epidemiology of hip fractures. *Bone.* 1996; 18(1):S57-63.
- Koval KJ, Zuckerman JD. Hip fractures: I. Overview and evaluation and treatment of femoral-neck fractures.

- JAAOS-Journal of the American Academy of Orthopaedic Surgeons. 1994; 2(3):141-9.
- Protzman RR, Burkhalter WE. Femoral-neck fractures in young adults. *JBJS.* 1976; 58(5):689-95.
- Keene GS, Parker MJ. Hemiarthroplasty of the hip—the anterior or posterior approach? A comparison of surgical approaches. *Injury.* 1993; 24(9):611-3.
- Harty M. The anatomy of the hip joint. In *Surgery of the hip joint* Springer, New York, NY. 1984, 45-74.
- Cooper A. A treatise on dislocations and on fractures of the joints: fractures of the neck of the thigh-bone. *Clinical Orthopaedics and Related Research*. 1973; 92:3-5.
- Nowakowski AM, Ochsner PE, Majewski M. Classification of femoral neck fractures according to pauwels: interpretation and confusion. *J. Biomedical Science and Engineering.* 2010; 3:638-43.
- Bartoníček J. Pauwels' classification of femoral neck fractures: correct interpretation of the original. *Journal of orthopaedic trauma.* 2001; 15(5):358-60.
- Kazley JM, Banerjee S, Abousayed MM, Rosenbaum AJ. Classifications in brief: garden classification of femoral neck fractures. *Clinical orthopaedics and related research.* 2018; 476(2):441.
- Garden RS. Low-angle fixation in fractures of the femoral neck. *The Journal of Bone and Joint Surgery. British volume.* 1961; 43(4):647-63.
- Linton P. Types of displacement in fractures of the femoral neck. *The Journal of bone and joint surgery. British volume.* 1949; 31(2):184-9.
- Mullins MM, Norbury W, Dowell JK, Heywood-Waddington M. Thirty-year results of a prospective study of Charnley total hip arthroplasty by the posterior approach. *The Journal of arthroplasty.* 2007; 22(6):833-9.
- Hoppenfeld S, de Boer P, Buckley R. The humerus. *Surgical exposures in orthopaedics. The anatomic approach.* Philadelphia: Lippincott. 1984, 47-75.
- Daum WJ. Modified posterior approach to hip joint to enhance stability. *Orthop Rev* 1985; 2:103.
- Gibson A. Posterior exposure of the hip joint. *The Journal of bone and joint surgery. British.* 1950; 32(2):183-6.
- Nilsdotter A, Bremander A. Measures of hip function and symptoms: Harris hip score (HHS), hip disability and osteoarthritis outcome score (HOOS), Oxford hip score (OHS), Lequesne index of severity for osteoarthritis of the hip (LISOH), and American Academy of orthopedic surgeons (AAOS) hip and knee questionnaire. *Arthritis care & research.* 2011; 63(S11):S200-7.
- Mahomed NN, Arndt DC, McGrory BJ, Harris WH. The Harris hip score: comparison of patient self-report with surgeon assessment. *The Journal of arthroplasty.* 2001; 16(5):575-80.
- Harris WH. Traumatic arthritis of the hip after dislocation and acetabular fractures: treatment by mold arthroplasty: an end-result study using a new method of result evaluation. *JBJS.* 1969; 51(4):737-55.
- Keene GS, Parker MJ. Hemiarthroplasty of the hip—the anterior or posterior approach? A comparison of surgical approaches. *Injury.* 1993; 24(9):611-3.
- Trinh TQ, Ferrel JR, Pulley BR, Fowler TT. Short-term outcomes of femoral neck fractures treated with hemiarthroplasty using the anterior approach. *Orthopedics.* 2015; 38(12):e1091-7.
- Unwin AJ, Thomas M. Dislocation after hemiarthroplasty

- of the hip: a comparison of the dislocation rate after posterior and lateral approaches to the hip. *Annals of The Royal College of Surgeons of England*. 1994; 76(5):327.
23. Langlois J, Delambre J, Klouche S, Faivre B, Hardy P. Direct anterior Hueter approach is a safe and effective approach to perform a bipolar hemiarthroplasty for femoral neck fracture: outcome in 82 patients. *Acta orthopaedica*. 2015; 86(3):358-62.