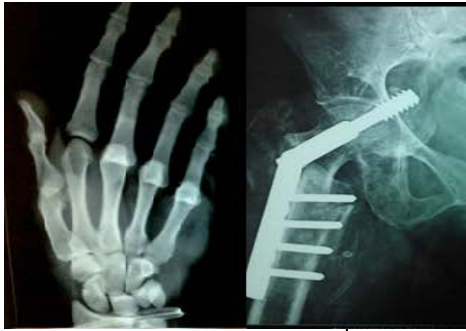



# International Journal of Orthopaedics Sciences

E-ISSN: 2395-1958  
P-ISSN: 2706-6630  
IJOS 2020; 6(3): 553-558  
© 2020 IJOS

[www.orthopaper.com](http://www.orthopaper.com)

Received: 15-05-2020

Accepted: 17-06-2020

**Dr. Mohammed Ashraf**  
Head of Orthopaedic,  
Department of orthopaedics, TD  
Medical College, Alappuzha,  
Kerala, India

**Dr. Shinas B Salam**  
Senior Resident, Department of  
orthopaedics, TD Medical  
College, Alappuzha, Kerala,  
India

**Dr. Siyad Ahammad**  
Senior Resident, Department of  
orthopaedics, TD Medical  
College, Alappuzha, Kerala,  
India

## Role of containment in late onset and early healed perthes-functional outcome

**Dr. Mohammed Ashraf, Dr. Shinas B Salam and Dr. Siyad Ahammad**

**DOI:** <https://doi.org/10.22271/ortho.2020.v6.i3i.2252>

### Abstract

Role of surgical containment in late onset and healed Perthes is still controversial and ill defined. Untreated and partially treated Perthes disease can progress to osteoarthritis by the fourth decade. The main complication is femoral head deformation. Two important factors contributing to complication:

1. Extruded femoral head
2. Deformed head leads to early onset of osteoarthritis

This study evaluates the clinical and radiological outcome of varus derotation osteotomy (VDRO) in late onset and early healed Perthes with extruded femoral head with remaining growth potential.

**Materials and Methods:** 30 children (19 males and 11 females) falling in the group of 10-16 years, belonging to modified Elizabethtown classification Stage 4-healed stage / Waldenstrom's stage 4-residual stage, radiologically – reossified, extruded, deformed femoral head are treated with open wedge VDRO, between 2009 and 2017 were included in this study. 21(70%) are between 10-14yrs, rest are 14 – 16yrs, mean age of osteotomy is 12.37yrs. All patients had limitation of abduction and internal rotation. 14 patients (46.67%) had pain at the hip and 26 patients (86.7%) had limp. Mean time between diagnosis and corrective surgery was 3 weeks.

**Results:** The evaluation was done using caput index (CI) and epiphyseal quotient (EQ) radiologically, range of motion and Harris Hip Score for clinical outcome. Our minimum follow up was 3yrs and maximum follow up of 10years. We studied Radiological and clinical parameters on 3<sup>rd</sup> year follow up. All measurement was done on pre-op, post op x-rays at 3<sup>rd</sup> year follow up and also compared with the contralateral hip. We noted improvement in the clinical outcome and radiologically femoral head attained more spherical contour after containment.

In our studies 21 children (70%) had good result with Spherical head and fully contained by acetabulum, 6 children (21%) had fair result with congruent head and acetabulum covering >4/5<sup>th</sup> of femoral head. Rest 3 children had poor result with clinically symptomatic and extruded deformed head. There was a significant change ( $P = 0.000$ ) in CI among all the patients after surgery. The final EQ after 3 years of VDRO was 0.685 and was significant ( $P = 0.0000$ ).

**Conclusion:** In Healed perthes with extruded and deformed femoral head, containing with VDRO helps to achieve a spherical femoral head, thereby delaying the onset of osteoarthritis. Mould for a spherical femoral head is the acetabulum. Containing the head resumes its growth until achieving skeletal maturity. The remaining growth potential is utilized to mould the head into sphericity.

**Keywords:** Healed perthes, Late onset perthes, varus derotation osteotomy, Caput index, containment, epiphyseal quotient

### 1. Introduction

Perthes disease is a self-limiting disease of children characterized by interruption of the blood supply to the capital femoral epiphysis resulting in necrosis of the epiphysis. The vascular occlusion is temporary. Complete re-vascularization of the epiphysis occurs over a period of 2-4 years if the child is under 12 years of age at onset of the disease<sup>[1, 2]</sup>. During the process of re-vascularization the necrotic bone is completely replaced by healthy new bone<sup>[3, 4]</sup>.

Extrusion of the femoral head is the main reason for deformity of the femoral head in perthes. Impaired blood supply to the head leads to bone necrosis which brings about soft tissue changes in the hip joint. The soft tissue changes include synovitis<sup>[5-7]</sup> and hypertrophy of both ligamentum teres<sup>[8]</sup> and articular cartilage<sup>9</sup>. Stress of weight bearing, muscle contraction and soft tissue changes are important factors contributing to the extrusion of the femoral head

**Corresponding Author:**  
**Dr. Mohammed Ashraf**  
Head of Orthopaedic,  
Department of orthopaedics, TD  
Medical College, Alappuzha,  
Kerala, India

laterally. Extrusion appears to be a prime factor that predisposes to femoral head deformation<sup>[10, 11]</sup>. The greater the extrusion, the greater the propensity for femoral head deformation. If more than 20% of the width of the epiphysis extrudes outside the acetabulum irreversible femoral head deformation is almost inevitable<sup>[12]</sup>.

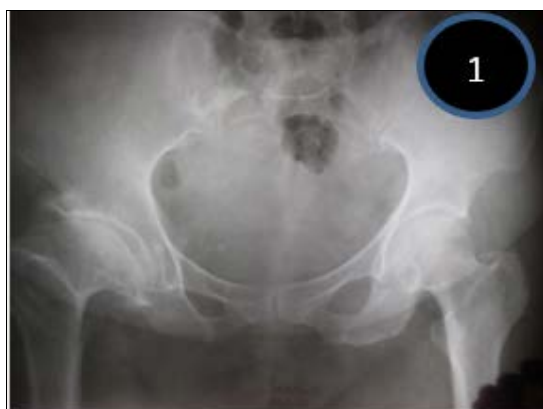Deformation of the femoral head subsequently leads to early osteoarthritis by the fourth decade. Prognostic factors in perthes disease depends on<sup>[13]</sup>.

- Age at time of healing
- persistent lateral uncovering of femoral head
- Irregular femoral head
- Premature closure of growth plate

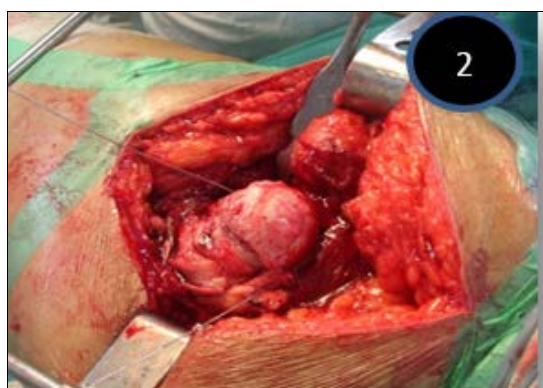Currently, disease in the younger age group of <6 years of age and can be managed conservatively using traction, no weight bearing, and analgesics<sup>[5]</sup>. Children between 6 and 9 years need surgical containment of the femoral head. Literatures regarding protocol of treatment for children of more than 9 years of age remain controversial. The containment of femoral head within the acetabular cavity decreases the mechanical load and allows normal development of the head and the acetabular cavity and maintains the joint congruency<sup>[14]</sup>.

Even though all modes of treatment aims to prevent the head from deformity by containment of the femoral head before the revascularization stage (Waldenstrom staging) sets in, from our study we can conclude that containment with varus derotation osteotomy even in early healed phase before epiphyseal closure helps to regain femoral head congruity.

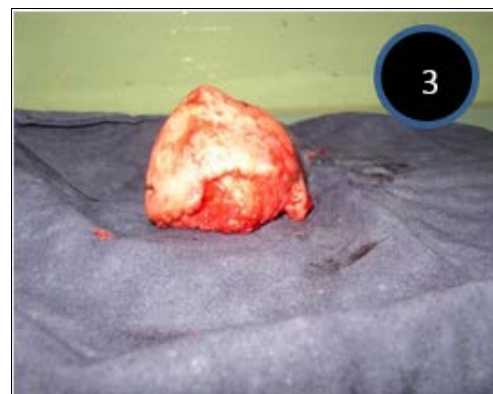Aim of this study is to assess the clinical and radiological outcome of containment by varus derotation osteotomy in late onset (more than 10 years) and early healed perthes with deformed and extruded femoral head.



**Fig 1:** Xray pelvis with both hip- showing Right hip post perthes sequelae -OA



**Fig 2:** Intraop image of post perthes Femur Head in THR



**Fig 3:** Post Perthes Deformed femoral head

### Materials and Method

30 children (19 males and 11 females) of 10- 16 years of age group at stages modified Elizabethtown Stage 4 –**healed stage** (Waldenstrom's stage 4- residual stage) before epiphyseal closure. They are treated by VDRO between 2009 to 2017 were included in this prospective study. Patients who had restriction of movements at presentation in the affected hip were treated with traction for 1–2 weeks to decrease the muscular spasm and allow synovitis to subside and any improvement in range of motion was noticed. The mean time between diagnosis and corrective surgery was 3 weeks. Radiograph of pelvis with abducted hip is taken in all children to check whether the head is containable or not. Those patient in whom the head can be contained are selected. The children who satisfy inclusion criteria were undergone VDRO of proximal femur. Excluded criteria included hinged abduction and fused epiphysis.

### Inclusion criteria

- Clinical: modified Elizabethtown Stage 4 –healed stage (Waldenstrom's stage 4- residual stage)
- Radiological: Reossified, deformed, extruded femoral head before epiphyseal fusion.

### Exclusion criteria

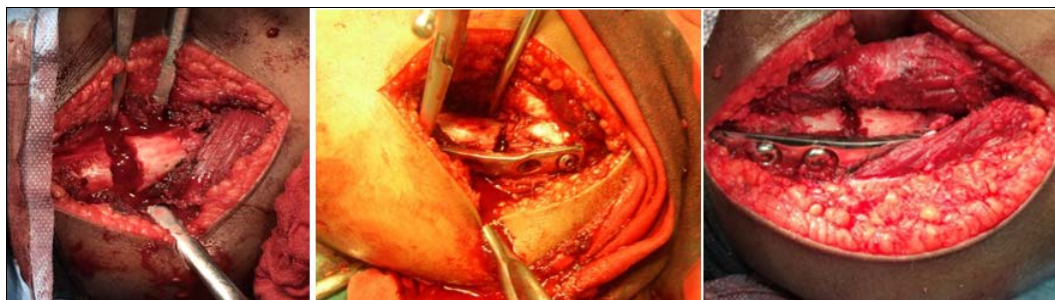
- Fused epiphysis-growth potential stops.
- Hinged abduction

### Operative Procedure-proximal femoral open wedge VDRO

Late onset and early healed perthes cases are taken for the studies. Open wedge varus derotational osteotomy is done to contain the deformed and extruded femoral head within the acetabulum. Mean age of osteotomy is 12.37yrs.

Operated by the same senior orthopedic surgeon using a lateral approach in supine position under an image intensifier.

- Varus correction of 15°–20°
- Target neck shaft angle was 110°–120° intra-operatively.
- 15°–20° of external rotation correction was done at the osteotomy site
- The osteotomy site was fixed with a contoured 3.5/4.5mm dynamic compression plate (depending on the size) and screws.
- The proximal most screw in the plate was placed through the greater trochanter after drilling the lateral aspect of the trochanteric growth plate.
- Uncooperative subjects were immobilized with a hip spica till union of the osteotomy site.
- Gradual weight bearing was started after the consolidation at the osteotomy site.

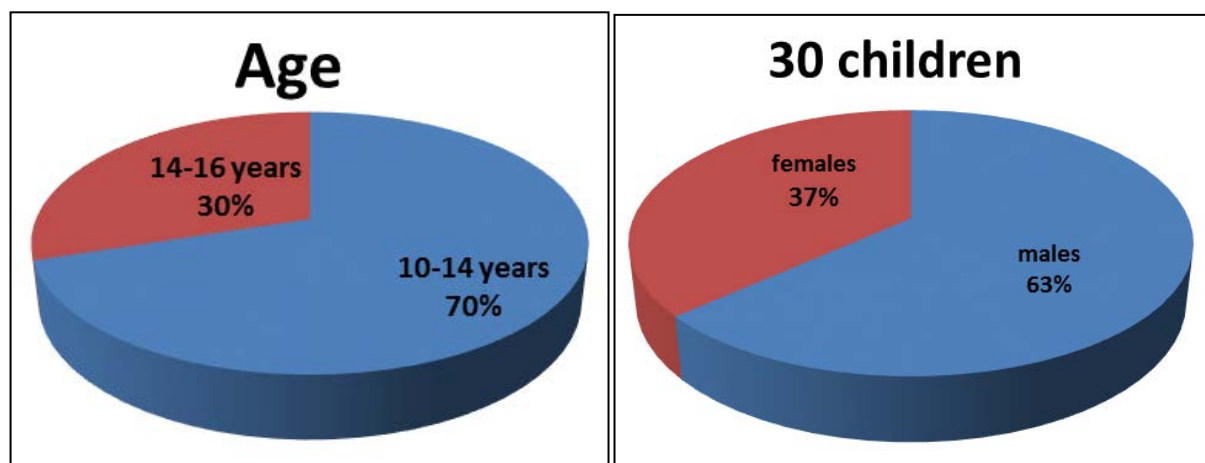


**Fig 4:** Intra-op images of Varus Derotation Osteotomy

#### Clinical parameters

- Out of 30 children 14 patient had complained of pain at hip, 26 children had limping. 9 patient had trendlenburg test positive, all patient had restrictions in internal rotation and abduction of which 9 patient had deformity. Mean time period of admission to surgery was 3 week.
- Postop patients were followed up at 2 weeks for suture removal, then every 2 months for a year. Thereafter, they were followed up 6 monthly for the next 2 years. At each

follow up patients were assessed clinically for range of motion, deformity, gait, limb length discrepancy, Harris Hips Score. Our minimum follow up was 3yrs and maximum follow up of 10years. The mean period of the union of osteotomy site was 3 months (range 2-4 months). During every follow up the patient were assessed clinically for range of motion, deformity, gait, and Harris Hips Score.



**Fig 5:** Age and sex distribution in the study

**Table 1:** Average age of osteotomy

Total number of children (n)	Mean age of osteotomy	Standard Deviation (SD)
30	12.37 yrs	1.790

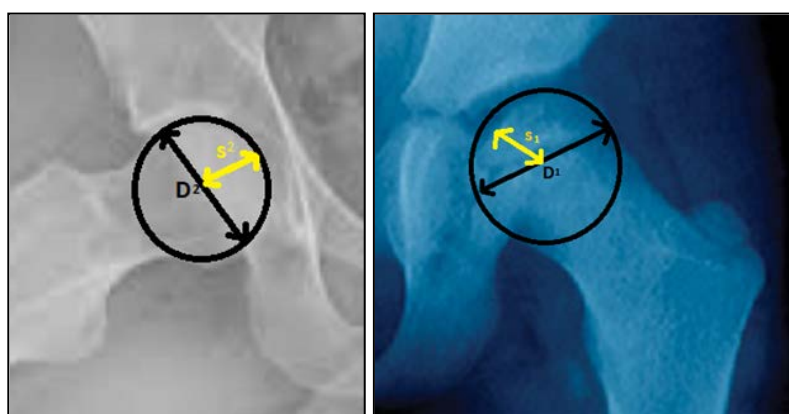
#### Radiological parameters

Radiological assessment was done after 3 years of follow up on both post and pre-operative x-rays. Antero-posterior and lateral views of both hips were taken [15].

Ideally femoral head is considered as round, anatomical

centre of femoral head was found by accommodating the head within an optimal sphere. The maximum diameter of the femoral head is  $D$ . The minimum radius ( $s$ ) is measured from middle of  $D$  to the surface of the femoral head. The  $D$  and  $s$  are an average of respective values in both the view.

Caput index (CI) is calculated  $= ([s \times 2]/D)^{[24]}$ . Caput index is used to measure the sphericity of femoral head Caput index  $> 70\%$  is considered as good,  $CI = 50-70\%$  is fair and  $CI < 50$  is poor.



**Fig 6:** Caput Index  $= (2*s)/D * 100$ ;  $[s = (s_1 + s_2), D = (D_1 + D_2)]$



The epiphyseal quotients (EQ) are calculated from the X-rays (the EQ is the ratio of the epiphyseal index of the involved head with that of the uninvolved head. The epiphyseal index is calculated by the greatest height of the epiphysis divided by its width [24].

The EQ was graded as good (>60%), fair (40%–60%) and poor (≤40%) [16]. All the radiological parameters were calculated using the AGFA computed radiography operating system on a true size (100%) radiograph. The clinical and radiological parameters of the affected hip were compared with the contralateral normal hip 3 yr of follow up.

We classified the results of treatment of hips along the following criteria [17, 24].

Good - radiologically: Spherical head fully contained by the acetabulum: (EQ over 60%, Clinically No symptoms, full range of hip movements), Fair - radio logically: Caput congruent, more than 4/5 of the head covered (EQ within 40%–60%, Clinically: No symptoms, slight restriction of hip movements);

Poor - radiologically: Caput irregular, more than 1/5 of the head uncovered (EQ <40%, Clinically Symptoms present, marked restriction of hip movements).

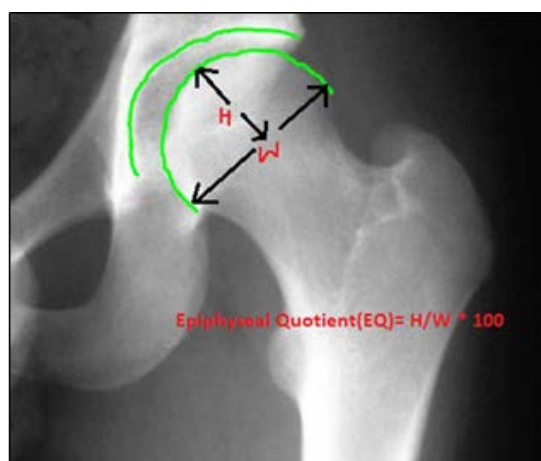


Fig 7: Epiphyseal Quotient (EQ)

### Statistics

We used IBM SPSS (Version 20.0, Armonk, NY:IBM Corp, USA) Statistics software for analysis of our results. Fischer's exact test for subject distribution, Student unpaired *t*-test for change in CI, Fischer's exact test for results in terms of EQ was used. The statistical significance value (*P*) was set to 0.05.

### Results

#### Radiological parameters:

Radiological assessment was done at 3 years of followup. Caput index of normal side and affected side after surgery was evaluated. Change in the CI of operated hip and normal hip was compared We found that there was a significant

change (*P* = 0.000) in Caput index.

T-test

Table 2: Mean Caput Index in normal and operated hip

One-Sample Statistics				
	N	Mean	Std. Deviation	Std. Error Mean
CI_normal	30	96.13	3.319	.606
CI_Operated	30	74.67	11.140	2.034

Table 3: One sample t test for Caput Index

One-Sample Test						
	Test Value = 0					
	t	DF	Sig. (2-tailed)	Mean Difference	95% Confidence Interval of the Difference	
					Lower	Upper
CI_norml	158.643	29	.000	96.133	94.89	97.37
CI_Operated	36.713	29	.000	74.667	70.51	78.83

The mean value of EQ at diagnosis was 0.4130 and the final EQ at 3 years followup after VDRO was 0.6853. The change in the EQ in the affected hip after VDRO was significant (*P* = 0.0000). According to EQ

70% of operated children (21) showed good result with EQ > 60%, 20% (10) showed fair result EQ=40-60% and rest 10% (3 children) with poor result.

Table 4: mean epiphyseal quotient in normal and operated hip

Paired Samples Statistics					
		Mean	N	Std. Deviation	Std. Error Mean
Pair 1	EQ_postop	0.6853	30	.17725	.03236
	EQ_preop	0.4130	30	.11018	.02012

Table 5: Paired t test for pre and post operated epiphyseal quotient

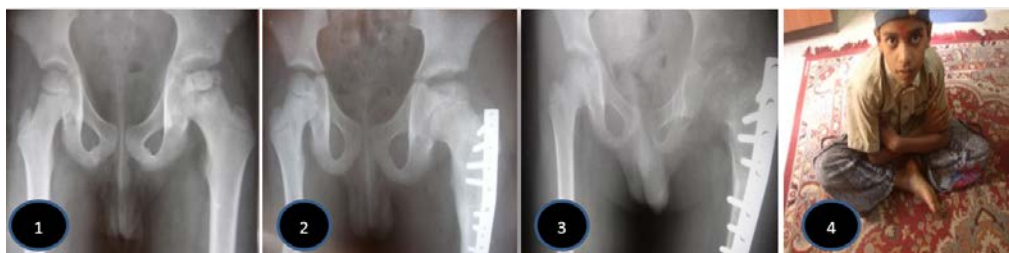Paired Samples Tes									
		Paired Differences					t	DF	Sig.(2tailed)
		Mean	Std. Deviation	Std. Error Mean	95% Confidence Interval of the Difference				
					Lower	Upper			
Pair 1	EQ_postop - EO_preop	.27233	.10365	.01892	.23363	.31104	14.391	29	.000

#### Clinical parameters:

Clinically 3 children complained of limping of which 2 had complains of hip pain and trendlenburg gait. They had marked restriction of hip movement. They also showed difficulty to squat or sit cross legged.6 children had no clinical symptoms but slight restriction of movement they were able to sit squat and sit cross legged. Rest 21 children showed satisfactory improvement with full ROM and clinically asymptomatic.2 patients had superficial infection during immediate postop period for which treated with iv antibiotics.

Mean harris hip score was 91.2 (Range 82-100)

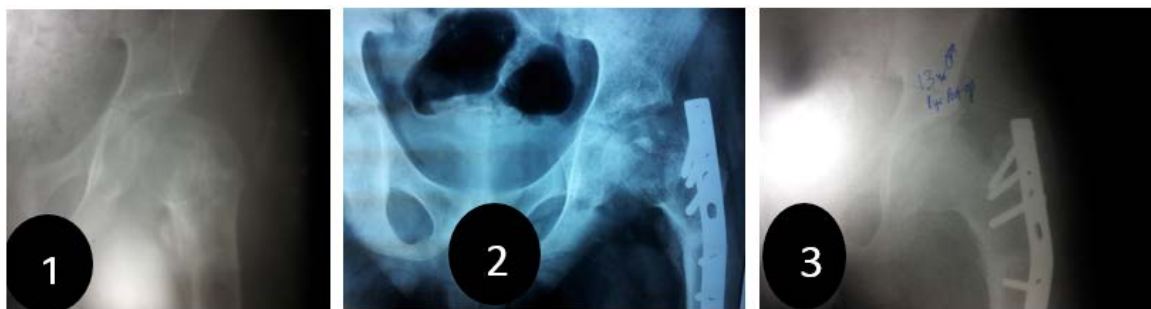### CASE 1



1. Preoperative Xray pelvis AP view of a 12 year old child

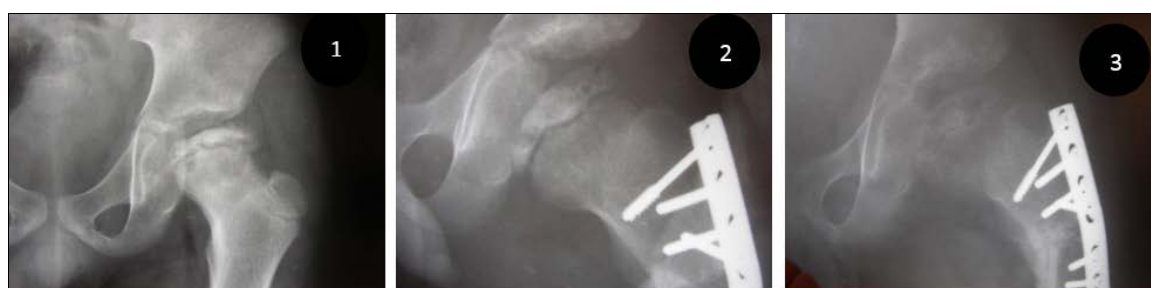2. Postoperative X-ray taken after 1 year
3. Postoperative X-ray taken after 3 years with fully reformed head.
4. 3<sup>rd</sup> year Follow up image

## CASE 2



1. Preoperative X-ray pelvis AP view of a 13 year old child.
2. Postoperative X-ray taken after 1 year.
3. Postoperative X-ray taken after 3 years with fully reformed head

## CASE 3



1. Preoperative X-ray pelvis AP view of a 15 year old child.
2. Postoperative X-ray taken after 1 year.
3. Postoperative X-ray taken after 3 years with reformed head.

## Discussion

Perthes is one of the disease where numerous study has been conducted and still to be idiopathic disease. Our aim of treatment is to contain the extruded and delayed femoral head inside the acetabulum.

Our study included 30 children between ages of 10 to 16 years. Mean age of VDRO is 12.37 yrs. All the case included in our study was early healed perthes and late onset perthes (>10yrs) with reossified extended and deformed femoral head before epiphyseal closure.

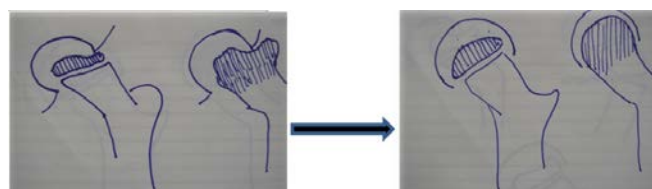
To assess the femoral head sphericity anteroposterior and lateral radiograph are taken. Various authors have used Moses index<sup>18</sup> in their studies. However, it is not possible to measure some femoral heads using Moses index which are not circular enough to fit the outline of the Moses Ring as quoted by Dickens *et al.* Shigeno and Evans<sup>[20]</sup> stated that femoral head deformation was more significant in AP radiograph than lateral in fragmentation stage. However, Cho *et al.*<sup>[21]</sup> put forward that in children the femoral head is deformed both in the sagittal and coronal plane. Herring *et al.*,<sup>[22]</sup> Fredensborg,<sup>[23]</sup> Heyman and Herndon.

We used Caput Index (CI) and Epiphyseal Quotient (EQ) as the measure of femoral head sphericity using AP and Lateral x-rays. EQ was calculated on pre-op and post-op radiograph of the operated side at 3yrs of followup. CI was calculated by comparing normal and index side on a 3<sup>rd</sup> year follow up radiograph.

From our study we concluded that Varus Derotational Osteotomy (VDRO) in early healed perthes with extruded

deformed femoral head before epiphyseal fusion regained the sphericity of head. 70 percent of children had satisfactory result with full range of motion, whereas 20 % of children even though clinically asymptomatic had slight restriction of ROM.

The limitation of our study is short follow up period and small size of study group. It is necessary to follow up the patient up to 4<sup>th</sup> decades of life to rule out early onset of secondary Osteoarthritis, which we were unable to do due to time limitation



1. Image showing deformed femoral head in neglected Perthes
2. Image showing femoral head reformation following containment

## Conclusion

Thus in early Healed perthes with extruded and deformed femoral head, containing with VDRO helps to achieve a spherical femoral head, thus delays the onset of early osteoarthritis<sup>25</sup>. Mould for a spherical femoral head is the acetabulum. Containing the head resumes its growth until achieving skeletal maturity. The remaining growth potential is

utilized to mould the head into sphericity.

### Conflict of interest

The author confirms that there is no conflict of interests of any sort with this article content.

### Reference

1. Catterall A. Legg-Calvé-Perthes' syndrome. Clin Orthop Relat Res. 1981; 158:41–52. [PubMed] [Google Scholar]
2. Conway JJ. A scintigraphic classification of Legg-Calvé-Perthes disease. Semin Nucl Med. 1993; 23:274–95. [PubMed], [Google Scholar].
3. Jensen OM, Lauritzen J. Legg-Calvé-Perthes' disease. Morphological studies in two cases examined at necropsy, J Bone Joint Surg Br. 1976; 58:332-8. [PubMed], [Google Scholar].
4. Salter RB. Legg-Perthes disease: The scientific basis for the methods of treatment and their indications. Clin Orthop Relat Res. 1980; 150:8-11. [PubMed] [Google Scholar].
5. Howorth MB. Coxa plana. J Bone Joint Surg Am. 1948; 30A:601–20. [PubMed] [Google Scholar]
6. Matsoukas JA. Viral antibody titers to rubella in coxa plana or Perthes' disease. Perthes diseases: Is it the late osseous residua of a minor prenatal rubella? Acta Orthop Scand. 1975; 46:957-62. [PubMed] [Google Scholar]
7. Joseph B, Pydisetty RK. Chondrolysis and the stiff hip in Perthes' disease: An immunological study. J Pediatr Orthop. 1996; 16:15-9. [PubMed], [Google Scholar].
8. Joseph B. Morphological changes in the acetabulum in Perthes' disease. J Bone Joint Surg Br. 1989; 71:756-63. [PubMed], [Google Scholar].
9. Kamegaya M, Moriya H, Tsuchiya K, Akita T, Ogata S, Someya M *et al.* Arthrography of early Perthes' disease. Swelling of the ligamentum teres as a cause of subluxation, J Bone Joint Surg Br. 1989; 71:413. [PubMed], [Google Scholar].
10. Rab GT, DeNatale JS, Herrmann LR. Three-dimensional finite element analysis of Legg-Calve-Perthes disease. J Pediatr Orthop. 1982; 2:39-44. [PubMed], [Google Scholar].
11. Ueo T, Tsutsumi S, Yamamuro T, Okumura H. Biomechanical analysis of Perthes' disease using the finite element method: The role of swelling of articular cartilage, Arch Orthop Trauma Surg. 1987; 106:202-8. [PubMed], [Google Scholar].
12. Griffin PP, Green NE, Beauchamp RD. Legg-Calvé-Perthes disease: Treatment and prognosis. Orthop Clin North Am. 1980; 11:127–39. [PubMed], [Google Scholar].
13. Kim HK. "Legg-Calvé-Perthes disease". J Am Acad Orthop Surg. 2010; 18(11):676–86. DOI: 10.5435/00124635-201011000-00005. PMID 21041802
14. Joseph B. Management of Perthes' disease. Indian J Orthop. 2015; 49:10-6. [PMC free article], [PubMed], [Google Scholar]
15. Eijer H, Berg RP, Haverkamp D, Pécasse GA. Hip deformity in symptomatic adult Perthes' disease, Acta Orthop Belg. 2006; 72:683-92. [PubMed], [Google Scholar].
16. Moberg A, Hansson G, Kaniklides C. Results after femoral and innominate osteotomy in Legg-Calvé-Perthes disease, Clin Orthop Relat Res. 1997; 334:257–64. [PubMed], [Google Scholar].
17. Dickens DR, Menelaus MB. The assessment of prognosis in Perthes' disease, J Bone Joint Surg Br. 1978; 60-B:189-94. [PubMed], [Google Scholar].
18. Mose K. Methods of measuring in Legg-Calvé-Perthes disease with special regard to the prognosis. Clin Orthop Relat Res. 1980; 150:103-9. [PubMed], [Google Scholar].
19. Shigeno Y, Evans GA. Revised arthrographic index of deformity for Perthes' disease, J Pediatr Orthop B. 1996; 5:44-7. [PubMed], [Google Scholar].
20. Cho TJ, Lee SH, Choi IH, Chung CY, Yoo WJ, Kim SJ *et al.* Femoral head deformity in Catterall groups III and IV Legg-Calvé-Perthes disease: Magnetic resonance image analysis in coronal and sagittal planes, J Pediatr Orthop. 2002; 22:601-6. [PubMed], [Google Scholar].
21. Herring JA, Neustadt JB, Williams JJ, Early JS, Browne RH. The lateral pillar classification of Legg-Calvé-Perthes disease. J Pediatr Orthop. 1992; 12:143-50. [PubMed], [Google Scholar].
22. Fredensborg N. The spherical index. A measure of the roundness of the femoral head. Acta Radiol Diagn (Stockh). 1977; 18:685-8. [PubMed], [Google Scholar].
23. Narendra Joshi, Soumya Shrikanta Mohapatra, Short Term Outcome of Varus Derotation Osteotomy in Late Presenting Perthes disease Indian J Orthop. 2018; 52(2):133-139.
24. Shohat N, Copeliovitch L, Smorgick Y, Atzmon R, Mirovsky Y, Shabshin N *et al.* The Long-Term Outcome After Varus Derotational Osteotomy for Legg-Calvé-Perthes Disease: A Mean Follow-up of 42 Years Bone Joint Surg Am. 2016; 98(15):1277-85.