



E-ISSN: 2395-1958
P-ISSN: 2706-6630
IJOS 2020; 6(3): 433-436
© 2020 IJOS
www.orthopaper.com
Received: 22-05-2020
Accepted: 24-06-2020

Shekhar Malve
Associate Professor,
Department of Orthopaedics
P.G.I. Swasthiyog Pratishthan
Miraj, Maharashtra, India

Shrinivas Jadhav
Department of Orthopaedics
P.G.I. Swasthiyog Pratishthan
Miraj, Maharashtra, India

Tejas Patil
Department of Orthopaedics
P.G.I. Swasthiyog Pratishthan
Miraj, Maharashtra, India

Nikhil Lambat
Department of Orthopaedics
P.G.I. Swasthiyog Pratishthan
Miraj, Maharashtra, India

Vijay Dattu
Department of Orthopaedics
P.G.I. Swasthiyog Pratishthan
Miraj, Maharashtra, India

Shubhdeep Chug
Department of Orthopaedics
P.G.I. Swasthiyog Pratishthan
Miraj, Maharashtra, India

Corresponding Author:
Shrinivas Jadhav
Department of Orthopaedics
P.G.I. Swasthiyog Pratishthan
Miraj, Maharashtra, India

Clinical and radiological outcome of posterior column acetabular fracture treated with open reduction and internal fixation using reconstruction plate

Shekhar Malve, Shrinivas Jadhav, Tejas Patil, Nikhil Lambat, Vijay Dattu and Shubhdeep Chug

DOI: <https://doi.org/10.22271/ortho.2020.v6.i3g.2235>

Abstract

Introduction: With increasing road traffic accidents, acetabular fractures are becoming more common. The present study was aimed to assess the functional and radiological outcomes of patients with posterior column acetabular fracture treated with open reduction internal fixation.

Methodology: The present observational study was conducted in the Department of Orthopaedics, Post Graduate Institute of Swasthiyog Pratishthan, Miraj of patients with displaced fractures of the posterior column acetabulum. Clinical grading at one year post-operatively was based on Merle d' Aubigne and Postel scoring which has been modified by Matta and radiological grading system was based on the anatomical displacement criteria.

Results: During the study period we included a total of 32 patients. Mean age of these patients was 42.6 years, and males comprised 66% of the patients. Clinical outcome as assessed by Merle d' Aubigné and Postel method revealed that 63% achieved excellent outcome, 28% had good outcome, 6% had fair and one patient had a poor outcome. Radiological evaluation at the end of one year post-operatively revealed excellent outcome in 59%, good in 28%, fair in 9% and poor outcome in 3%. Immediately post-operatively one patient developed superficial wound infection, and during the follow-up period, one patient developed paraesthesia along the lateral aspect of the thigh because of lateral femoral cutaneous nerve injury, who then recovered completely within 6 months.

Conclusions: Open reduction and internal fixation resulted in excellent and good clinical outcome in 91% of the patients and excellent and good radiological outcome in 87% of the patients.

Keywords: Fracture posterior column-wall acetabulum, open reduction, internal fixation

Introduction

Acetabular fractures commonly occur in young people who are involved in road traffic accidents. Though exact number is not available, the incidence of acetabular fracture is estimated to be 3 per 100000 [1]. In addition, due to increase in the prevalence of osteoporosis, there has been an increase in the number of acetabulum fractures resulting from a fall from height [2]. Recent advances in the management of acetabular fracture is the use of percutaneous fixation for certain fracture types. The majority of acetabular fractures require open reduction and internal fixation. Indications for conservative treatment include [3]: stable fractures which are, concentrically reduced and does not involve the superior acetabular dome, when the intact part of the acetabulum can maintain stability and congruency, and those with secondary congruency and those fractures having roof arc measurement of greater than 45 degrees on AP, iliac oblique, and obturator oblique. Indications for open reduction and internal fixation include all fractures which have hip joint instability, fractures which have soft tissue injuries, and in cases in which conservative treatment was not satisfactory. The present study was aimed to assess the clinical and radiological outcomes of patients with posterior column acetabular fracture treated with open reduction internal fixation using reconstruction plate.

Methodology

Study Design and Sampling

The prospective study was conducted in the Department of Orthopaedics, Post Graduate

Institute of Swasthiyog Pratishthan, Miraj. We included patients, aged 18 to 70 years with displaced fractures of the posterior column acetabulum, with or without joint incongruence with fracture posterior acetabulum caused mainly by intra-articular osteochondral fracture fragments. We excluded patients with fracture of posterior acetabulum with fracture anterior column or anterior wall of acetabulum; patients not suitable for internal fixation (i.e. severe local infection, severe osteoarthritis); associated comorbid conditions making patient unfit for surgery, moderate or severe cognitively impaired patients; pregnancy. All fractures were classified according to Judet and Letournel system of classification [4].

Surgical procedure

On arrival in the Emergency Department, all patients received first aid and were stabilized with fluids, oxygen and blood transfusion if required. The injured limb was inspected so as to know the extent of soft tissue injury and deformity. Musculature was assessed to rule out associated fractures. Other major injuries were ruled out as well. Imaging studies were done, fractures were maintained in traction and reduced and patients were admitted to indoor wards. We included only those patients who underwent open reduction and internal fixation. In our series the criterion used for surgical management was a fracture displacement of more than 5 mm. The goal of operative management was anatomic reduction of the fracture and subsequent stable internal fixation, with combination of inter-fragmentary screws and a reconstruction plate

Patients were operated under spinal/general anaesthesia and Kocher Langenbeck approach was used. It provides direct visualisation of the entire lateral aspect of the posterior column. Visualisation was extended antero-superiorly by dividing a portion of gluteus medius or performing a transtrochanteric osteotomy if required. After debriding the edges of the fracture, distracting the hip joint, and the wall fragments were reduced. Provisional fixation was done with Kirschner wires and definitive fixation was done with cancellous screws along with precontoured plate placed from ischium over the retro-acetabular surface. C-arm image intensifier confirmed reduction and screw positions. Immediate post-operatively, fluids, antibiotic coverage was started. Indomethacin was given to all patients as prophylaxis against heterotopic ossification in a dose of 50 mg 3 times per day. Active toe movement and check x-rays were done. Physiotherapy exercises were started from day one post-operative and the patients were mobilized to high sitting position with quadriceps training. Following the surgical drain removal, patients were mobilized with non-weight bearing using walking frame for 1 month, partial weight bearing for the following 3 weeks and started full weight bearing from 2 months onwards. Hip abductor and quadriceps strength training was continued throughout these 2 months. All patients received low molecular weight heparin thromboprophylaxis for 2 months. The patients were followed up by 2 weeks interval for first 2 months thereafter monthly basis till 6 months then at 1 year. All the patients were assessed clinically and radiographically.

Data Collection and Data Analysis

Using a pre-designed semi-structured questionnaire, patient related information was noted. Clinical grading at one year post-operatively was based on Merle d' Aubigne and Postel scoring which has been modified by Matta [5]. Merle

d'Aubigné and Postel Method of scoring system which included pain, gait and mobility on a scale of 1 to 6 for each item, where 1 indicates the worst and 6, the best state of the patient. The total minimum score is 3 and the maximum is 18 and the results were expressed in the form of poor, fair, good and excellent. Radiological grading system was based on the anatomical displacement criteria; excellent grade: 0 mm displacement, good: 0-1 mm, fair: 2-3 mm and poor: > 3 mm displacement. These data were analysed and presented descriptively.

Results

Table 1: Characteristics of the patients included in the study

Patient variables	Frequency	Percent
Age group (years)		
Up to 30	4	13%
31 to 60	18	56%
More than 60	10	31%
Gender		
Males	21	66%
Females	11	34%
Mode of injury		
Road traffic accident	30	94%
Fall	2	6%
Time between trauma and surgery		
Less than 7 days	11	34%
7 to 14 days	15	47%
More than 14 days	6	19%
Full weight bearing		
Up to 14 weeks	14	44%
15 to 18 weeks	15	47%
More than 18 days	3	9%

During the study period we included a total of 32 patients. Mean age of these patients was 42.6 years, 56% were from the age group 31 to 60 years. Males comprised 66% of the patients. Half of all patients were operated between 7 to 14 days of trauma, 34% were operated in less than 7 days after trauma and 19% after 14 days of trauma.

Table 2: Clinical and radiological outcomes of the patients included in the study

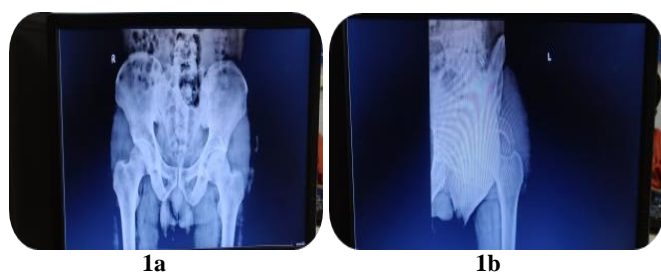
Clinical outcome based on Merle d' Aubigne and Postel scoring	Frequency	Percent
Excellent	20	63%
Good	9	28%
Fair	2	6%
Poor	1	3%
Radiological outcome based on the anatomical displacement		
Excellent	19	59%
Good	9	28%
Fair	3	9%
Poor	1	3%

All cases were from road traffic accident, except for 2 cases, who had a history of fall. Clinical outcome as assessed by Merle d'Aubigné and Postel method revealed that 63% achieved excellent outcome, 28% had good outcome, 6% had fair and one patient had a poor outcome. Radiological evaluation at the end of one year post-operatively revealed excellent outcome in 59%, good in 28%, fair in 9% and poor outcome in 3%.

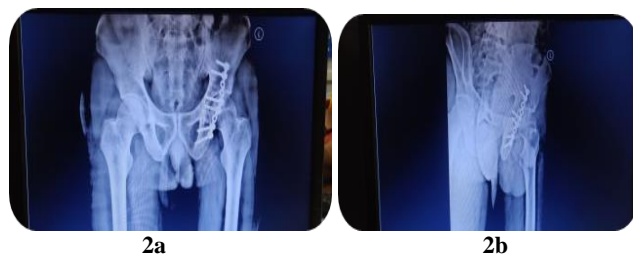Table 3: Complication in the study group

Complication	Frequency	Percent
Superficial infection	01	3%
Deep infection	00	00
Sciatic Nerve injury	00	00
Lateral cutaneous nerve injury	01	3%
Deep vein thrombosis	00	00
Heterotopic ossification	00	00

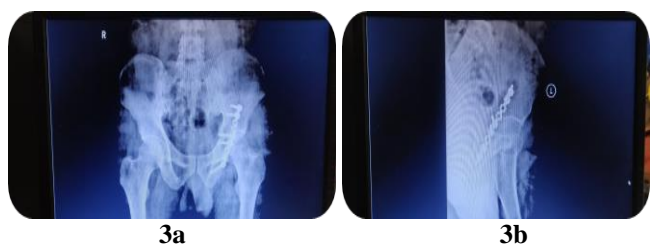
Immediately post-operatively one patient developed superficial wound infection, which resolved with daily dressing, antibiotics and delayed mobilization. During the follow-up period, one patient developed paraesthesia along the lateral aspect of the thigh because of lateral femoral cutaneous nerve injury, who then recovered completely within 6 months. No patient had deep vein thrombosis as ankle dorsiflexion, static quadriceps exercises and knee mobilization were started early.



Preoperative x-ray

Fig 1: Preoperative x-rays 1a (AP view), 1b (Oblique view)

Postoperative x-ray

Fig 2: Postoperative x-rays 2a (AP view), 2b (Oblique view)

Follow up x-ray at 6 month

Fig 3: Follow-up x-rays at 6 month 3a (AP view), 3b (Oblique view)

Discussion

In our study, 32 patients were operated for posterior column acetabular fracture with open reduction and internal fixation. Mean age of these patients was 42.6 years, 31 to 60 years being the most common age group and 66% were males. Kachnerkar and Markade studied the clinical outcome of surgical management of fracture posterior column and posterior wall of acetabulum [6]. In their study, mean age of the patients was 34 years, and 90% were males. Similar to our

study, mean age of the patients was less than 40 in other studies as well [7]. This is possible due to the fact that road traffic accident is a very common mode of injury in these patients. All except two cases were involved in a road traffic accident. Kulkarni *et al* assessed the clinical and radiological outcome, success rate and proportion of the post-operative complications of surgical management of comminuted quadrilateral plate acetabulum fractures after open reduction and internal fixation [8]. In their study, mean age was 36 years and 63% were males.

Clinical outcome as assessed in our patients by Merle d'Aubigné and Postel method revealed that 63% achieved excellent outcome, 28% had good outcome, 6% had fair and one patient had a poor outcome. Kim *et al* assessed the clinical outcomes of reconstruction of acetabular posterior wall using the D'Aubigne and Postel scores at the final follow-up which were excellent and very good in 45.5%, good in 15.2%, fair in 9.1%, and poor in 30.3% [9]. Similarly, Bassi *et al* reported functional outcomes of open reduction and internal fixation of posterior wall acetabular fractures as excellent in 29%, good in 38%, fair in seven 16% and poor in 18% [10]. Some investigators assessed functional outcomes using Harris Hip score. Kulkarni *et al* reported Harris Hip scores to be excellent in 48.5%, good in 30.3%, fair in 12.1% of patients at 1 year follow up. Laflamme and colleagues studied 21 patients who were operated by plates for quadrilateral plate fracture of acetabulum, 11 cases achieved anatomical reduction (<1mm) and 70.6% had satisfactory Harris hip scores [11]. In our patients radiological evaluation at the end of one year post-operatively revealed excellent outcome in 59%, good in 28%, fair in 9% and poor outcome in 3%. Using Matta criteria for radiological outcomes, Kim *et al* reported excellent and good outcomes in 72.7% of their patients. Kachnerkar also used radiological grading system by Matta and reported good outcomes in 79%.

In our study, half of all patients were operated between 7 to 14 days of trauma, 31% were operated in less than 7 days after trauma and 19% after 14 days of trauma. Previous literature has shown that timing of surgery affects the clinical outcome, as delay to surgery has been shown to be associated with worse radiographic and functional outcomes. Madhu *et al* analysed 237 patients and demonstrated this effect [12]. Matta *et al* studied 262 patients and reported 74% anatomic reduction in patients who underwent surgery within first 7 days, which reduced significantly to 57% for patients treated after 15 to 21 days [13].

We observed that only one patient developed paraesthesia along the lateral aspect of the thigh because of lateral femoral cutaneous nerve injury. Kulkarni *et al* reported one case of iatrogenic sciatic/femoral nerve palsy. This patient improved with physiotherapy and rehabilitation. In addition, Petsatodis *et al*, reported 2 peroneal nerve palsies and 3 wound infections and late complications including 1 patient with avascular necrosis of the femoral head, 5 patients with heterotopic ossification [14]. Heterotopic ossification was not a seen in our study patients. Some investigators have reported more than 50% incidence of heterotopic ossification after surgical treatment of acetabular fractures [15]. Matta *et al* reported a rate of heterotopic ossification as high as 82%. In our study, all patients were administered indomethacin which could have lower the incidence of heterotopic ossification.

Conclusion

Road traffic accident are increasing every year and is a major killer globally. As a result, acetabular fractures are become

more common and a definitive learning curve is involved in treating these patients surgically. These fractures represent a major weight bearing joints and thus must be restored satisfactorily. Open reduction and internal fixation resulted in excellent and good clinical outcome in 91% of the patients and excellent and good radiological outcome in 87% of the patients. This study was able to show that posterior column and wall of acetabular fractures were best treated with open reduction and internal fixation using reconstruction plate and we recommend the same as a treatment of choice.

References

1. Magnussen RA, Tressler MA, Obremsky WT, Kregor PJ. Predicting blood loss in isolated pelvic and acetabular high-energy trauma. *J Orthop Trauma*. 2007; 21(9):603-7
2. Laird A, Keating JF. Acetabular fractures: a 16-year prospective epidemiological study. *J Bone Joint Surg Br*. 2005; 87(7):969-73
3. Olson SA, Matta JM. The computerized tomography subchondral arc: A new method of assessing acetabular articular continuity after fracture (a preliminary report). *J Orthop Trauma*. 1993; 7(5):402-13
4. Letournel E. Acetabulum fractures: classification and management. *Clin. Orthop. Relat. Res*. 1980; 151:81-106.
5. D'Aubigne RM, Postel M. Functional results of hip arthroplasty with acrylic prosthesis. *J Bone Joint Surg Am*. 1954; 36(3):451-75
6. Kachnerkar NI, Markade P. Study and results of reconstruction plating in fracture posterior column and posterior wall of acetabulum. *Int J Res Orthop*. 2017; 3:1104-12.
7. Patel GM, Meghnathi U, Chaudhary J. Study and results of reconstruction plating in fracture posterior column and posterior wall of acetabulum. *International Journal of Orthopaedics Sciences*. 2019; 5(4):985-989
8. Kulkarni CU, Sen A, Jose J. Outcome analysis of surgical management of comminuted quadrilateral plate acetabulum fractures. *Int J Res Orthop*. 2019; 5:883-7
9. Kim HT, Ahn JM, Hur JO, Lee JS, Cheon SJ. Reconstruction of Acetabular Posterior Wall Fractures. *Clin Orthop Surg*. 2011; 3(2):114–20.
10. Bassi JL, Dattal C, Mahindra P, Singh N. Open Reduction And Internal Fixation Of Posterior Wall Acetabular Fractures: A Study of 45 Cases. *J Orthop*. 2007; 4(1):17.
11. Laflamme GY, Hebert-Davies J, Rouleau D, Benoit B, Leduc S. Internal fixation of osteopenic acetabular fractures involving the quadrilateral plate. *Injury*. 2011; 42:1130-4.
12. Madhu R, Kotnis R, Al-Mousawi A *et al*. Outcome of surgery for reconstruction of fractures of the acetabulum. The time dependent effect of delay. *J Bone Joint Surg Br*. 2006; 88(9):1197-203.
13. Matta JM. Fractures of the acetabulum: accuracy of reduction and clinical results in patients managed operatively within three weeks after the injury. *J Bone Joint Surg Am*. 1993; 78:1632-45.
14. Petsatodis G, Antonarakos P, Chalidis B, Padadopoulos P, Christoforidis J, Pournaras J. Surgically treated acetabular fractures via a single posterior approach with a follow-up of 2–10 years. *Injury*. 2007; 38(3):334-43.
15. Bray JT, Esser M, Fulkerson L. Osteotomy of the Trochader in Open Reduction and Internal Fixation of Acetabular Fractures. *J Bone Joint Surg*. 1987; 69(5):711-7.