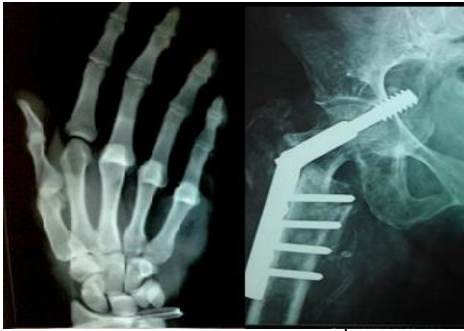

# International Journal of Orthopaedics Sciences

E-ISSN: 2395-1958  
P-ISSN: 2706-6630  
IJOS 2020; 6(3): 145-148  
© 2020 IJOS  
[www.orthopaper.com](http://www.orthopaper.com)  
Received: 08-05-2020  
Accepted: 13-06-2020

**Dr. Diwakar Pratap**  
Department of Orthopedics,  
Himalayan Institute of Medical  
Sciences, Swami Rama  
Himalayan University,  
Dehradun, Uttarakhand, India

**Dr. Digvijay Agarwal**  
Assistant Professor, Department  
of Orthopedics, Himalayan  
Institute of Medical Sciences,  
Swami Rama Himalayan  
University, Dehradun,  
Uttarakhand, India

**Dr. R Maheshwari**  
Professor, Head of Department,  
Department of Orthopedics,  
Himalayan Institute of Medical  
Sciences, Swami Rama  
Himalayan University,  
Dehradun, Uttarakhand, India

**Dr. Prakhar Maheshwari**  
Junior Resident, Department of  
Orthopedics, Himalayan  
Institute of Medical Sciences,  
Swami Rama Himalayan  
University, Dehradun,  
Uttarakhand, India

**Corresponding Author:**  
**Dr. R Maheshwari**  
Professor, Head of Department,  
Department of Orthopedics,  
Himalayan Institute of Medical  
Sciences, Swami Rama  
Himalayan University,  
Dehradun, Uttarakhand, India

## Correlation between PCR and histopathology in TB spine

**Dr. Diwakar Pratap, Dr. Digvijay Agarwal, Dr. R Maheshwari and Dr. Prakhar Maheshwari**

**DOI:** <https://doi.org/10.22271/ortho.2020.v6.i3c.2193>

### Abstract

**Introduction:** Tuberculosis (Tb) is an infectious disease with enormous mortality and morbidity. In India alone about 33million people are suffering from Mycobacterium tuberculosis and around 3 million are suffering from extra-pulmonary tuberculosis. It is a major burden on health care agency, hence the importance for rapid and accurate diagnosis cannot be ignored. Earlier diagnosis was based on detection of AFB on ZN stains which offers low sensitivity (requires  $10^4$  bacilli/ml for positive result), Mycobacterium culture is the standard method but due to its long incubation time affects treatment and long term outcome. Histopathological examination provides good information regarding the tissue and sample material but with limited capacity of its specificity the diagnosis and treatment is doubtful, i.e. epithelioid granuloma and caseating necrosis can occur in disease other than Tb. The acknowledgment of ATT therapy was widely used previously to confirm the diagnosis. With the advent of nucleic acid amplification tests there was a major advance in the diagnosis of tuberculosis, by using amplification systems, nucleic acid sequences unique to Mycobacterium tuberculosis can be detected directly in clinical specimen with better accuracy than AFB staining and at greater speed than culture and more specific than histopathology.

**Method:** The Samples were collected under strict aseptic precautions in the operation theatre under the fluoroscopic guidance from the affected vertebrae using Jamshidi needle. The collected sample were sent for PCR for Tb, ZN staining and Histopathological examination.

**Results:** Histopathology was found positive in 18 patients and PCR was found positive in 25 patients. Both were found positive in 15 patients

**Keywords:** Tb spine, PCR for Tb, Histopathology for Tb disease.

### Introduction

Tuberculosis is not so uncommon disease of developing world. Extrapulmonary Tb can involve different organ systems with varied signs and symptoms. Skeletal tuberculosis accounts for 8-10% of patients with extra-pulmonary tuberculosis. The skeletal site most commonly involved is spine followed by hip and knee. Spinal tuberculosis accounts for almost 50% cases of skeletal tuberculosis [1]. Spinal involvement occurs through hematogenous spread of M.Tuberculosis into the dense vasculature of cancellous bone of the vertebral bodies, the primary infection site is either a pulmonary lesion or an infection of the genitourinary system [2].

A high clinical suspicion and highly sensitive tools are needed to clinch the diagnosis [3]. Spine TB is commonly diagnosed on clinical and radiological findings substantiated by staining and culture to detect the mycobacterium tuberculosis. Radiological methods such as CT and MRI are helpful for the diagnosis of tubercular lesions but definite diagnosis is made by tissue/pus examination. Diagnosis of spinal TB is challenging due to many reasons, such as scanty amount of clinical specimen with pauci-bacillary nature, non-uniform distribution of bacilli in specimen, sites difficult to reach and above all its resemblance with other clinical entities including malignancy and inflammatory disorders [4].

The most commonly applied bacteriological examination includes ZN (Ziehl-Neelson) microscopy and culture for AFB (Acid fast Bacilli). Due to simplicity in procedure, cost effectiveness and rapidity ZN microscopy is a favoured technique used in laboratories

worldwide, but it has low sensitivity and requires  $10^4$ - $10^5$  bacilli/ml to be positive in a clinical sample (5). Histopathological examination is one of most important test required in the diagnosis of Tb spine, provides additional information, but occasionally results are indecisive and requires high expertise with reporting time of around a week or so [6].

With the advent of molecular biology technique, PCR (Polymerase chain reaction) is a major boost in the early diagnosis of Tb spine. In PCR the nucleic acid sequence specific to Mycobacterium tuberculosis can be identified in a tissue sample. There by providing superior accuracy to ZN staining with quicker results than culture and histopathology [7].

It is actually difficult to detect tubercle bacilli with routine methods such as smear microscopy and culture due to very small amount of bacilli in extra-pulmonary sample and moreover repeated sampling from spine is not possible. This study was undertaken to evaluate the efficiency and effectiveness of Histopathology and PCR in the diagnosis of Tb spine [8].

The accuracy of percutaneous spine biopsy is reported to range between 16% and 92%, and the complication rates are reported to range between 0% and 10%. [9] The accuracy of percutaneous spine biopsy performed under fluoroscopy guidance was reported as 93.8% by Kamei *et al.*, [10] in a series of 128 cases.

### Material and methods

This was a observational study carried out from January 2015 to August 2018 in Department of Orthopedics, Himalayan Institute of Medical science, Swami Ram Nagar, Dehradun, after getting ethical clearance.

### Study design

Type of study: observational study

Sample size and sampling method: The study included 61 patients. Patients were selected on clinical and radiological suspected case of Tb spine with or without neurological deficit.

### Selection of subject

**Inclusion criteria:** All patients with clinical and radiological suspicion of Tubercular spine with or without neurological deficit.

**Exclusion Criteria:** All those patients who were already

diagnosed Tuberculosis spine and/or on ATT treatment were excluded.

**Study tools:** The following tools were used to conduct the study

- A structured patient case recording form
- Operation theatre
- Jamshidi needle for biopsy

**Study protocol:** All patients coming to orthopedics OPD and emergency with clinical and radiological suspicion of Tubercular spine with or without neurological deficit were included in the study.

A structured patient case recording form was developed and used to generate data.

The Samples were collected under strict aseptic precautions in the operation theatre under the fluoroscopic guidance from the affected vertebrae using Jamshidi needle. The collected samples were sent for PCR for Tb, ZN staining and Histopathological examination. Sample for PCR was sent in sterile container with normal saline and histopathological examination was send in sterile container with 10% formalin.

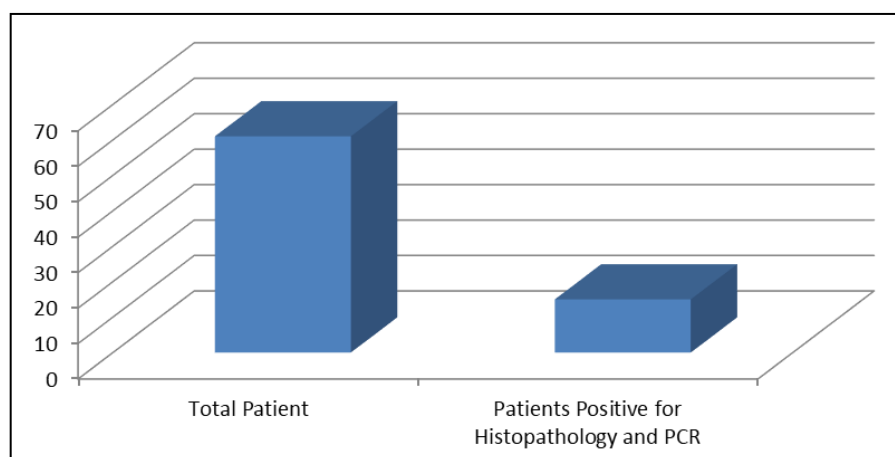
For the sensing of DNA all members of the M. tuberculosis Real time PCR kit is used. Real time PCR was performed by using QIAGEN Q1 Amp DNA mini kit.

### Data management and statistical analysis

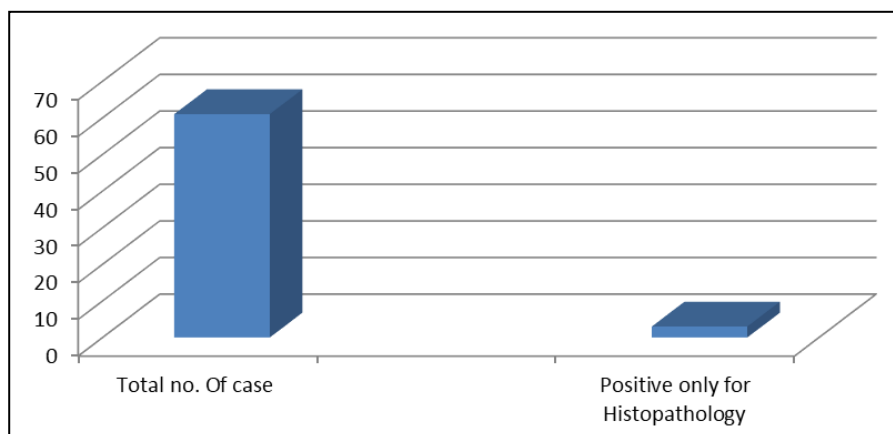
The collected data was entered in Microsoft excel and statistical analysis was performed using SPSS software version 22.

### Results

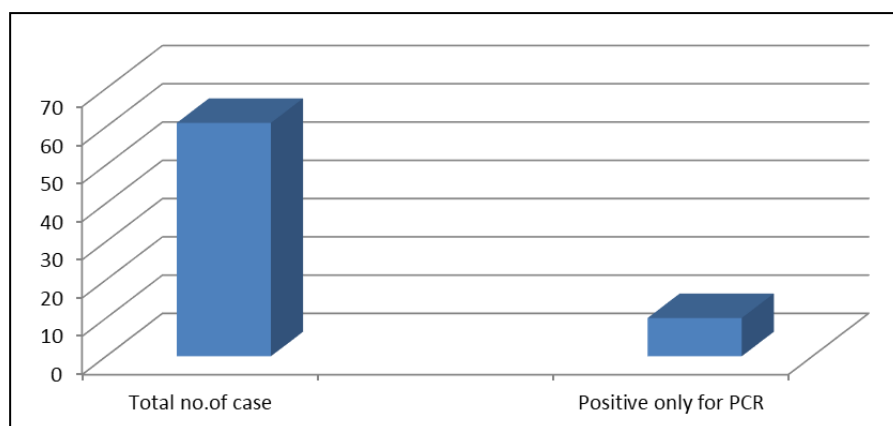
Our study included 61 patients, out of which 26 were male and 35 were female, with age group ranging between 26-68 years. On histo-pathological (figure-1) examination 18 patients (29.5%) were found to be positive and 43 patients (70.5%) negative for tuberculosis. PCR was found to be positive in 25 patients (40.98%) with 36 patients (59%) reporting negative. Out of 61 patients, 15(24.59%) were found to be positive for tuberculosis in both PCR and histopathological examination. Out of 25 patients who were PCR positive, 10(16.39%) patients were having only PCR positive (figure-2) and all other test reporting negative for TB. Out of 18(29.5%) patients who had histopathological test positive, 3 (4.91%) patients had only histopathology positive (figure-3) with all other test reported to be negative.



**Fig 1:** showing cases positive for histopathology and PCR both



**Fig 2:** showing cases positive for only histopathology



**Fig 3:** showing positive patients for only PCR

**Fig 1:** showing results of histopathology and PCR

N=61	Histopathology positive	Histopathology negative
PCR positive	15	10
PCR Negative	3	33

## Discussion

Spinal tuberculosis, accounts for 2% of all TB infections. Diagnosis of spinal Tuberculosis is based on proper history, clinical presentation, thorough examination supported by modern imaging techniques like X-Rays, CT and MRI. CT and MRI in particular can detect the subtle changes in the spine. Even if the x-rays of the spine appears normal, MRI can pick up the early changes and can detect intensity of involvement of vertebrae, soft tissue, pus, granulation tissue and deformity. However, MRI can never form a definitive diagnosis of tuberculosis and exclude various other pathologies like malignancy, inflammatory conditions and pyogenic infection which simulate with Tb diseases on imaging [11]. In our study we found 5 of 61 cases diagnosed to be neoplastic by the histopathological examination. This signifies that even strong suspicion of infection based on classical or nonclassical radiological and clinical findings can go wrong.

The histopathological and ZN staining findings are much more reliable in the diagnosis of EPTB. The study quoted the detection rate of EPTB including Tb spine varying from 53% to 81% [4]. The histopathological diagnosis could be reached in 32% (18 out of 56) of the cases. Among the negative case for histopathology, 10 case were identified as tubercular positive on PCR method.

Nucleic acid amplification method, such as PCR has been shown to have better accuracy in the diagnosis of

Tuberculosis which is similar to the study of Singh UB et al in 2006 [12].

In our study, we found that no single diagnostic test has a good positivity rate, hence a combination of diagnostic test is required for accurate diagnosis.

## Conclusion

So here by we conclude in all the suspected patients anti-tubercular treatment should not be started on clinico-radiological basis. All suspected patients should undergo tissue histopathology to form a correct diagnosis and rule out other diseases, otherwise patients with different diagnosis can be wrongly treated for tuberculosis. PCR should be used in addition to histopathology, as it increases the diagnostic efficacy.

## Reference

- Garg RK, Somvanshi DS. Spinal tuberculosis: a review. The journal of spinal cord medicine. 2011; 34(5):440-454. <https://doi.org/10.1179/2045772311Y.0000000023>
- Ansari S, Amanullah MF, Ahmad K, Rauniyar RK. Pott's Spine: Diagnostic Imaging Modalities and Technology Advancements. North American journal of medical sciences. 2013; 5(7):404-411. <https://doi.org/10.4103/1947-2714.115775>
- Singh R, Kumar N, Sundriyal D, Trisal D. Mixed pyogenic and tuberculous liver abscess: clinical suspicion is what matters. BMJ case reports, 2013, bcr2013008768. <https://doi.org/10.1136/bcr-2013-008768>
- Kumar M, Kumar R, Srivastva AK, Nag VL, Krishnani N, Maurya AK, Dhole TN, Babu SG. The efficacy of diagnostic battery in Pott's disease: A prospective study. Indian journal of orthopaedics. 2014; 48(1):60-66.

- <https://doi.org/10.4103/0019-5413.125503>
5. Agrawal M, Bajaj A, Bhatia V, Dutt S. Comparative Study of GeneXpert with ZN Stain and Culture in Samples of Suspected Pulmonary Tuberculosis. *Journal of clinical and diagnostic research*. 2016; 10(5):DC09-DC12. <https://doi.org/10.7860/JCDR/2016/18837.7755>
  6. Bennani K, Khattabi A, Akrim M, Mahtar M, Benmansour N, Essakalli Hossyni L, *et al*. Evaluation of the Yield of Histopathology in the Diagnosis of Lymph Node Tuberculosis in Morocco, 2017: Cross-Sectional Study. *JMIR public health and surveillance*. 2019; 5(4):e14252. <https://doi.org/10.2196/14252>
  7. Alli OA, Ogbolu OD, Alaka OO. Direct molecular detection of Mycobacterium tuberculosis complex from clinical samples - An adjunct to cultural method of laboratory diagnosis of tuberculosis. *North American journal of medical sciences*. 2011; 3(6):281-288. <https://doi.org/10.4297/najms.2011.3281>
  8. Afsar I, Gunes M, Er H, Gamze Sener A. Comparison of culture, microscopic smear and molecular methods in diagnosis of tuberculosis. *Revista espanola de quimioterapia: publicacion oficial de la Sociedad Espanola de Quimioterapia*. 2018; 31(5):435-438.
  9. Metzger CS, Johnson DW, Donaldson WF. 3rd Percutaneous biopsy in the anterior thoracic spine. *Spine (Phila Pa 1976)*. 1993; 18:374-8.
  10. Kamei Y, Nishida J, Mimata Y, Shiraishi H, Ehara S, Satoh T, *et al*. Core needle percutaneous transpedicular vertebral body biopsy: A study of 128 cases. *J Spinal Disord Tech*, 2013.
  11. Rasouli MR, Mirkoohi M, Vaccaro AR, Yarandi KK, Rahimi-Movaghar V. Spinal tuberculosis: diagnosis and management. *Asian spine journal*. 2012; 6(4):294-308. <https://doi.org/10.4184/asj.2012.6.4.294>
  12. Singh UB, Bhanu NV, Suresh VN, Arora J, Rana T, Seth P. Utility of polymerase chain reaction in diagnosis of tuberculosis from samples of bone marrow aspirate. *Am J Trop Med Hyg*. 2006; 75:960-3.