



E-ISSN: 2395-1958
P-ISSN: 2706-6630
IJOS 2020; 6(2): 919-923
© 2020 IJOS
www.orthopaper.com
Received: 17-01-2020
Accepted: 18-02-2020

Dr. Sandip R Patil
Associate Professor, Department of Orthopaedics, Krishna Institute of Medical Sciences, Karad, Maharashtra, India

Dr. Sapan Vora
Junior Resident, Department of Orthopaedics, Krishna Institute of Medical Sciences, Karad, Maharashtra, India

Dr. Dhaval Tailor
Junior Resident, Department of Orthopaedics, Krishna Institute of Medical Sciences, Karad, Maharashtra, India

Dr. Chitresh Mehta
Junior Resident, Department of Orthopaedics, Krishna Institute of Medical Sciences, Karad, Maharashtra, India

Dr. Swapnil Chitnavis
Junior Resident, Department of Orthopaedics, Krishna Institute of Medical Sciences, Karad, Maharashtra, India

Corresponding Author:
Dr. Sandip R Patil
Associate Professor, Department of Orthopaedics, Krishna Institute of Medical Sciences, Karad, Maharashtra, India

Functional outcome of Type 3 and Type 4 proximal humerus fractures treated with PHILOS plating

Dr. Sandip R Patil, Dr. Sapan Vora, Dr. Dhaval Tailor, Dr. Chitresh Mehta and Dr. Swapnil Chitnavis

DOI: <https://doi.org/10.22271/ortho.2020.v6.i2o.2161>

Abstract

Introduction: Proximal humerus fractures are commonly encountered fractures in general orthopaedic practices around 6% of fractures of humerus fractures.

Material and Method: The present study had 40 cases of proximal humerus fracture treated by PHILLOS plate. This prospective study was conducted in the department of orthopedics at a tertiary care centre, Krishna hospital and research centre karad from May 2017 to November 2019

Observation: The most common complications included varus malunion the occurrence of which was 12.5%, AVN 5%, screw perforation of the humeral head into the joint 10% and infection 2.5%

Results: The study shows 20% excellent, 60% good, 15% satisfactory and 5% poor results on Constant Murley Score.

Conclusion: PHILOS plate holds the key to stabilization of proximal humerus fracture.

Keywords: PHILOS, proximal humerus, orthopaedic practices

Introduction

Proximal humerus fractures are regularly encountered fractures in general orthopaedic practices around 6% of fractures of humerus fractures. In osteoporotic humerus, fractures of proximal humerus are listed third in incidence wise behind distal end radius fractures and compression fractures of the vertebrae. A 2006 Finnish study estimated the incidence of fall-related proximal humerus fractures has tripled since 1970. Around 85% occur in people older than 50, and the incidence peaks in the 60- to 90-year-old age-group with a female to male ratio of 70:30.

Treatment of the fracture of proximal humerus is aimed at maximizing patient's post operative functional outcome and managing the pain to its least possible level. The various modalities of treatment range from non-operative modalities such as strapping, immobilization to arthroplasty. The algorithm of management of the proximal humerus fracture still holds too much confusion in itself.

Aims of Study

- To functionally evaluate the PROXIMAL HUMERUS Type 3 and type 4 Fracture treated with PHILOS plate with early joint mobilization
- To achieve maximum functional activity at shoulder joint

Material and Method

The present study had 40 cases of proximal humerus fracture treated by PHILLOS plate. This prospective study was conducted in the department of orthopedics at a tertiary care centre, Krishna hospital and research centre, karad from May 2017 to November 2019.

Inclusion Criteria

- Adult patients
- Either sex
- Displaced proximal humerus fractures of type 3 and type 4 variety

For operative treatment outlined by Neer i.e. an angulation of articular surface of more than 45 degrees, a displacement between the major fractures fragments more than 1 cm or a fracture with valgus impaction

Exclusion criteria

- Non displaced proximal humerus fractures – type 1 and type 2 fractures
- Fracture dislocations
- Head splitting fractures
- Infection at the site of fracture
- Patients below age 18 years
- Pathologic fractures

Work up

1. History Taking

Important historical elements include the patient’s level of independence, functional demands, and any preexisting rotator cuff condition, hand dominance, and are these factors contribute to clinical management decisions.

Neer divides the proximal humerus into 4 conceptual and functional “parts”: the greater tuberosity, the lesser tuberosity, the articular segment (head), and the humeral shaft. In order to qualify as a part, the fragment must have greater than 1 cm of displacement or 45 degrees of angulations. The greater tuberosity is an exception to this rule, requiring only 0.5 cm of displacement to be considered a part. The Neer classification has shown moderate rater reliability. Outcomes and rates of rotator cuff injury correlate with the classification.

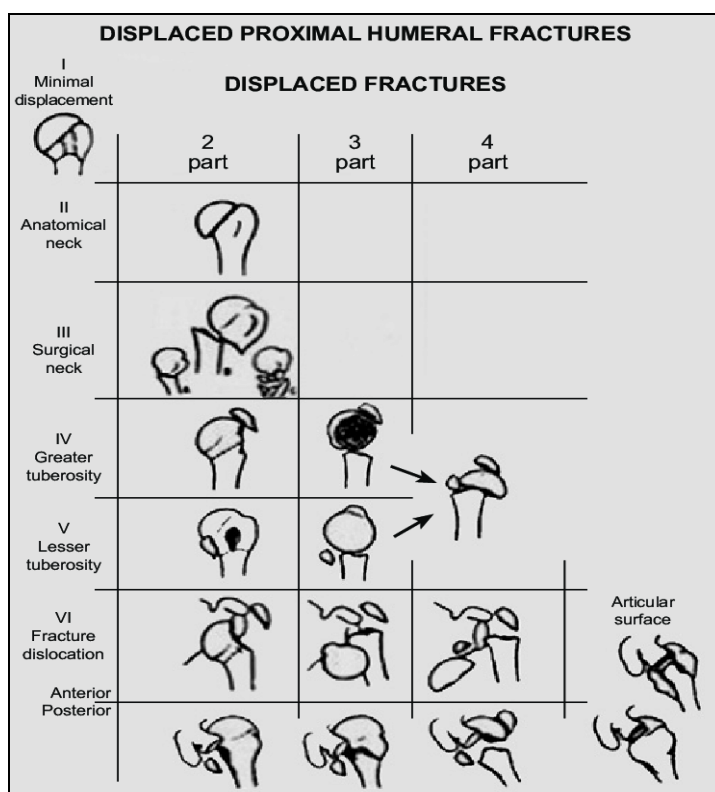


Fig 1.

2. Pre-Operative Work Up

The trauma series of the shoulder consists of three views: true AP, the lateral or scapular-Y, maxillary views and a Valpak view for evaluation of fracture anatomy, comminution, and fragment displacement.

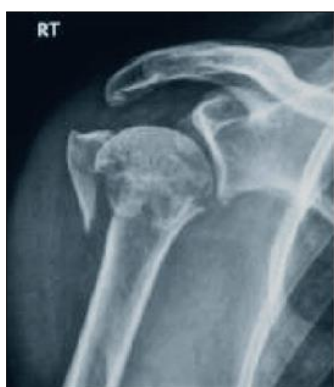

Fig 2.

3. Operative procedure

Surgery was performed in beach chair position on a radiolucent table under general anesthesia using the anterior deltopectoral approach. The greater and lesser tuberosity fragments were tagged with non-absorbable sutures. The tuberosity fragments were reduced to the lateral cortex of the shaft. Reduction of the tuberosities may indirectly reduce the head fragment; alternatively, to restore the medial calcar of the proximal humerus, an elevator was inserted to disimpact the head fragment. If required, the fracture was reduced and provisionally fixed into position using 1.5 mm Kirschner wires, sutures was passed through the rotator cuff and attached to the plate through the suture eyelets before permanent fixation with the contoured proximal humerus locking plate will be performed. On the anteroposterior view, the plate was ideally placed 8-10 mm distal to the superior tip of the greater tuberosity; from the lateral view, the plate was centered against the lateral aspect of the greater tuberosity. An adequate gap was left between the plate and the biceps tendon to prevent disruption of the anterior humeral circumflex artery

or entrapment of the tendon. The initial screw was then placed in the elongated hole in the humeral shaft (in classic 3 or 4 part fractures), so that the height of the plate could be adjusted. After achieving the appropriate fracture reduction and plate position, the locked screws were inserted into the humeral head using the insertion guide and sleeve assembly.

At least three distal shaft screws were inserted. A final fluoroscopic image was taken to ensure adequate reduction and proper medical support. Rotator cuff, capsule and subscapularis muscle tears/avulsions were repaired meticulously. The wound was closed in layers and a suction drain will be inserted.

Table 1.

Minimally Invasive design	Constant-Murley scores
Plate Fixation	63
1-year follow-up study of 54 patients treated with the S3 angular stable plate	75
2-year follow-up study using the radiolucent carbon fiber-reinforced polyetheretherketone plate	71.3

Three and Four part fractures

Open reduction with PHILOS plating was used in patients with good bone quality and complex fracture patterns. When plating complex fractures, suture fixation of the tuberosities and medial augmentation with cement, bone graft, and calcar screws were inserted for medial support.

4. Rehabilitation

Active assisted and passive exercises were used during the first two weeks, and 3 weeks later active motion was started. On the 8th postoperative week, daily activities were allowed. Patients were followed up on OPD basis at 2 weeks at first postoperatively then after every month till 6 months then every 3 monthly till 2 years. At every follow up, patients were assessed clinically for shoulder stability and range of motion and radio graphically checked for the progress of fracture healing. Radiographic union was defined as bridging trabeculation across the fracture site in the absence of hardware breakage or cut-out. The complications were also documented.

Observations

For our study, age incidence for the study reveals most cases in between 51-60 years in all types of fractures.

Table 2.

Age group	No. of cases	%
41-50	02	5
51-60	20	50
61-70	10	25
71-80	06	15
81-90	02	5

	No. of cases	Percentage
Male	28	76
Female	12	24
	40	100

The sex distribution of the patients in the study have a male predominance.

The side of fracture affected in the study was more on the left side.

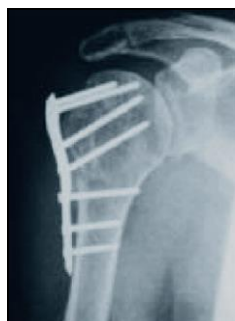

Fig 3

Table 3.

	No. of cases	%
Left	28	70
Right	12	30
	40	100

Profession	No. of cases	%
Labourer	20	50
Housewife	10	25
Bussinessmen	04	10
Factory worker	04	10
Driver	02	5

5. Evaluation

Evaluation of results were done on basis of scoring system given by Constant and Murley score, the scoring system of which comprises four parts: pain, power, activities of daily living and range of movement.

The patient profile on screening the patients for the occupation labourer were more common amongst housewives, businessmen, factory worker and drivers who took part in the study.

The mode of injury for the fractures was high energy polytrauma; road traffic accident most common among industries and fall.

Parameter	Score
Pain	15
Activities of daily living	20
Range of motion	40
Power	25
Total	100
Valuation	Score
Excellent	91-100
Good	81-90
Satisfactory	71-80
Adequate	61-70
Poor	<60

Fig 4.

Table 4.

Mode of injury	No. of cases	%
Road traffic accident	25	62.5
Industrial accidents	10	25
fall	05	12.5

Complications	No. of cases	%
Varus Malunion	5	12.5
Avascular Necrosis	2	5
Screw perforation of humeral	4	10
infections	1	2.5

The complications associated with the fractures and treatment complications included Varus malunion 12.5%, AVN 5%, screw perforation of the humeral head into the joint 10%, and infection 2.5%.

The study was assessed with Constant Murray score with excellent in 8 patients; good in 24 patients; satisfactory in 6 patients and poor in 2 patients.

Table 5.

Outcome	No. of cases	%
Excellent	8	20
Good	24	60
Satisfactory	6	15
Poor	2	5

Thyagarian <i>et al.</i>	57.5
Kettler <i>et al.</i>	52 to 72
Hentle <i>et al.</i>	55
Thanasias <i>et al.</i>	74.3

Discussion

In our study, men are exposed to more high energy trauma compared to female counterparts in our tertiary care hospital in isolated fractures of the proximal humerus {1.27:1}

Operative treatment of comminuted and displaced proximal humeral fractures, especially in osteoporotic bone, the PHILOS plate is used with minimally invasive technique. The mean Constant Murley score of 57.4 due to various complications encountered with plates. Various studies on Neer's 3-part, and 4-part fractures, mean age in this series was 58 years (range 19-92 years).

The study results align with our results with respect to the use of locking plates for proximal humerus fractures. The locking plate for proximal humerus fractures has a steep learning curve and appropriate surgical technique is very important for achieve good functional outcome. In our study also the mean Constant score for 4-part fractures was 48.6 which were inferior as compared to 3-part fractures (57 respectively).

Post operatively, various complications were observed. A varus malunion was observed in 5 patients (12.5%) and was found to be the commonest complication in our study.

Yang <i>et al.</i>	7.6 %
Helwig <i>et al.</i>	12.6 %
Thanasi's <i>et al.</i>	11.6%

In our patient population, screw perforation occurred in 4 patients (10%). An early implant removal was done in two of these patients who had poor outcome. The locking mechanism was found to give inadequate evaluation of the bone quality and screw fixation.

Vascular necrosis (AVN) is one of the most dramatic complications requiring re-operation. 2 patients (5%) in our study were reported to have developed osteonecrosis of the humeral head and poor results. The risk of osteonecrosis increases if the anterolateral branch of the anterior humeral circumflex artery is damaged. Deep wound infection was seen in 1 patient (2.5%).

Postoperatively, 6 patients (15%) in our study got their plate removed. One patient got his plate removed because of deep infection with distal screw and plate pullout, two patients (8%) got his plate removed because of AVN and implant loosening, two patients got his plate removed due to screw perforation, malreduction and implant loosening. These 5

patients had poor outcome.

A high rate of complications was found in our study in early cases but later on with surgeon's experience, further less complications were encountered.

Various studies have stressed out the association of high rate of complications and need for reoperation. The limitation of this study is lack of a control group and less follow up period and we do not evaluate any patient characteristics which can be risk factors for failure of this now common fixation technique.

Conclusion

Fixation of proximal humerus fractures with proximal humerus locking plates is associated with satisfactory functional outcomes in 3-part fracture. The incidence of complications and subsequent re-operation is relatively high. Based on our observations, inadequate positioning of the implant resulted in reduced functional outcome. Hence, to improve functional results, we consider plate positioning to be of utmost importance when using PHILOS plate fixation. Adequate surgical skills and surgeon's experiences with the surgical technique are necessary to achieve correct implant exaction and avoid these intraoperative errors.

References

1. Trumble T, Cornwall R, Budoff, Core G. Knowledge in Orthopedics—Hand, Elbow, and Shoulder. Philadelphia, Pa, USA: Mosby Elsevier, 2005.
2. Rockwood C, Matsen FA, III, Wirth M, Lippitt S. The Shoulder. 4th edition. Philadelphia, Pa, USA: Saunders Elsevier, 2008.
3. Terry GC, Chopp TM. Functional anatomy of the shoulder. Journal of Athletic Training. 2000; 35(3):248-255.
4. Gruson KI, Ruchelsman DE, Tejwani NC. Isolated tuberosity fractures of the proximal humerus: current concepts. Injury. 2008; 39(3):284-298.
5. Murachovsky J, Ikemoto RY, Nascimento LGP, Fujiki EN, Milani C, Warner JJP. Pectoralis major tendon reference (PMT): a new method for accurate restoration of humeral length with hemiarthroplasty for fracture. Journal of Shoulder and Elbow Surgery. 2006; 15(6):675-678.
6. Torrens C, Corrales M, Melendo E, Solano A, Rodríguez-Baeza A, Cáceres E. The pectoralis major tendon as a reference for restoring humeral length and retroversion with hemiarthroplasty for fracture. Journal of Shoulder and Elbow Surgery. 2008; 17(6):947-950.
7. Brooks CH, Revell WJ, Heatley FW. Vascularity of the humeral head after proximal humeral fractures: an anatomical cadaver study. Journal of Bone and Joint Surgery B. 1993; 75(1):132-136.
8. Duparc F, Muller JM, Fréger P. Arterial blood supply of the proximal humeral epiphysis. Surgical and Radiologic Anatomy. 2001; 23(3):185-190.
9. Visser CPJ, Coene LNJEM, Brand R, Tavy DLJ. Nerve lesions in proximal humeral fractures. Journal of Shoulder and Elbow Surgery. 2001; 10(5):421-427.
10. Hettrich CM, Boraiah S, Dyke JP, Neviasser A, Helfet DL, Lorich DG. Quantitative assessment of the vascularity of the proximal part of the humerus. Journal of Bone and Joint Surgery A. 2010; 92(4):943-948
11. Perlmutter GS. Axillary nerve injury. Clinical Orthopaedics and Related Research. 1999; (368):28-36.
12. Gardner MJ, Griffith MH, Dines JS, Briggs SM, Weiland

- AJ, Lorich DG. The extended anterolateral acromial approach allows minimally invasive access to the proximal humerus. *Clinical Orthopaedics and Related Research*. 2005; (434):123-129.
13. Kim SH, Szabo RM, Marder RA. Epidemiology of humerus fractures in the United States: nationwide emergency department sample, 2008. *Arthritis Care & Research*. 2012; 64(3):407-414.
 14. Robinson CM, Seah M, Akhtar MA. The epidemiology, risk of recurrence, and functional outcome after an acute traumatic posterior dislocation of the shoulder. *Journal of Bone & Joint Surgery*. 2011; 93(17):1605-1613.
 15. Hofman M, Grommes J, Krombach GA, Schmidt-Rohlfing B. Vascular injury accompanying displaced proximal humeral fractures: two cases and a review of the literature. *Emergency Medicine International*. 2011; 5:742-870.
 16. Naranja RJ Jr., Iannotti JP. Displaced three- and four-part proximal humerus fractures: evaluation and management. *The Journal of the American Academy of Orthopaedic Surgeons*. 2000; 8(6):373-382.
 17. Muller M, Perren S, Allgower M. Appendix A: the comprehensive classification of fracture of long bones. In: Allgower M, editor. *Manual of Internal Fixation: Techniques Recommended by the AO-ASIF Group*. Berlin, Germany: Springer, 1991, 118-125.
 18. Neer CS. II Displaced proximal humeral fractures: part I. Classification and evaluation. 1970. *Clinical Orthopaedics and Related Research*. 2006; 442:77-82.
 19. Kristiansen B, Christensen SW. Plate fixation of proximal humeral fractures. *Acta Orthopaedica Scandinavica*. 1986; 57(4):320-323.
 20. Lefevre-Colau MM, Babinet A, Fayad F *et al*. Immediate mobilization compared with conventional immobilization for the impacted nonoperatively treated proximal humeral fracture: a randomized controlled trial. *Journal of Bone and Joint Surgery A*. 2007; 89(12):2582-2590.
 21. Court-Brown CM, Garg A, McQueen MM. The translated two-part fracture of the proximal humerus. Epidemiology and outcome in the older patient. *Journal of Bone and Joint Surgery B*. 2001; 83(6):799-804.
 22. Court-Brown CM, Cattermole H, McQueen MM. Impacted valgus fractures (B1.1) of the proximal humerus. *Journal of Bone and Joint Surgery B*. 2002; 84(4):504-508.
 23. Yuksel HY, Yimaz S, Aksahin E, Celebi L, Muratli HH, Bicimoglu A. The results of nonoperative treatment for three- and four-part fractures of the proximal humerus in low-demand patients. *Journal of Orthopaedic Trauma*. 2011; 25(10):588-595.
 24. Calvo E, de Miguel I, de la Cruz JJ, López-Martín N. Percutaneous fixation of displaced proximal humeral fractures: indications based on the correlation between clinical and radiographic results. *Journal of Shoulder and Elbow Surgery*. 2007; 16(6):774-781.
 25. Jaberg H, Warner JJP, Jakob RP. Percutaneous stabilization of unstable fractures of the humerus. *Journal of Bone and Joint Surgery A*. 1992; 74(4):508-515.
 26. Alexa O, Puha B, Veliceasa B, Popia I. Percutaneous pinning for proximal humerus fractures. *Revista Medico-Chirurgicala a Societatii de Medici si Naturalisti din Iasi's*. 2007; 111(1):184-189.
 27. Keener JD, Parsons BO, Flatow EL, Rogers K, Williams GR, Galatz LM. Outcomes after percutaneous reduction and fixation of proximal humeral fractures. *Journal of Shoulder and Elbow Surgery*. 2007; 16(3):330-338.
 28. Harrison AK, Gruson KI, Zmistowski B, Keener J, Galatz L, Williams G *et al*. Intermediate outcomes following percutaneous fixation of proximal humeral fractures. *Journal of Bone & Joint surgery*. 2012; 94(13):1223-1228.
 29. Agel J, Jones CB, Sanzone AG, Camuso M, Henley MB. Treatment of proximal humeral fractures with Polarus nail fixation. *Journal of Shoulder and Elbow Surgery*. 2004; 13(2):191-195.
 30. Bernard J, Charalambides C, Aderinto J, Mok D. Early failure of intramedullary nailing for proximal humeral fractures. *Injury*. 2000; 31(10):789-792.
 31. Lobenhoffer P, Mathews J. The targon PH nail as an internal fixator for unstable fractures of the proximal humerus. *Operative Orthopädie und Traumatologie*. 2007; 19(3):255-275.
 32. Konrad G, Audige L, Lambert S, Hertel R, Sudkamp NP. Similar outcomes for nail versus plate fixation of three-part proximal humeral fractures. *Clinical Orthopaedics & Related Research*. 2012; 470(2):602-609.
 33. Zhu Y, Lu Y, Shen J, Zhang J, Jiang C. Locking intramedullary nails and locking plates in the treatment of two-part proximal humeral surgical neck fractures: a prospective randomized trial with a minimum of three years of follow-up. *Journal of Bone and Joint Surgery A*. 2011; 93(2):159-168.
 34. Olerud P, Ahrengart L, Ponzer S, Saving J, Tidermark J. Internal fixation versus nonoperative treatment of displaced 3-part proximal humeral fractures in elderly patients: a randomized controlled trial. *Journal of Shoulder and Elbow Surgery*. 2011; 20(5):747-755.