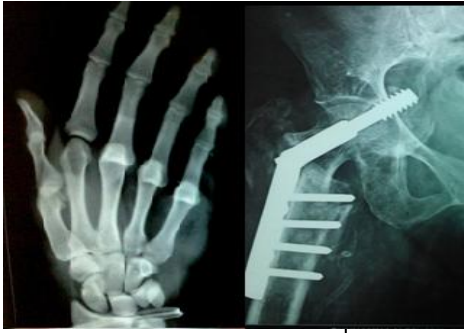

International Journal of Orthopaedics Sciences

E-ISSN: 2395-1958
P-ISSN: 2706-6630
IJOS 2020; 6(2): 860-863
© 2020 IJOS
www.orthopaper.com
Received: 22-02-2020
Accepted: 24-03-2020

Dr. Addagalla Srimannarayana
Assistant professor,
dept of orthopaedics,
Konaseema institute of medical
science, Amalapuram,
Andhra Pradesh, India

Dr. Dune Apparao
Assistant professor, dept of
orthopaedics, Konaseema
institute of medical science
Amalapuram, Andhra Pradesh,
India

Evaluation of functional outcome of subtrochantric fracture of femur managed by proximal femoral nail: A prospective study

Dr. Addagalla Srimannarayana and Dr. Dune Apparao

DOI: <https://doi.org/10.22271/ortho.2020.v6.i2n.2153>

Abstract

Background: Subtrochantric region is cortical in nature and vascularity is slow so healing is not as fast as highly vascular area of bone. This area of femur is subjected to stress due to its muscular insertions. So there is greater chance of fixation failure, non-union, and failure of procedure. Keeping all these in view present study has been designed to study the anatomical and functional outcome of subtrochantric fracture treated with proximal femoral nail, to access the stability of fixation and mobility of the patients and compare the result with standard treatment.

Method: Patients with sub trochanteric fracture admitted in the department of orthopaedics and trauma are enrolled for this study based on inclusion and inclusion criteria. Standard operative procedure was followed management of subtrochantric fracture by proximal femoral nail. Demographic, intra-operative, post-operative variables are recorded.

Result: The duration of surgery was $95.636 + 16799$ minutes in present study. The mean volume of blood lost during surgery was $114.387 + 17.90$ ml and regarding complication of in intra operative period 12% patient required open reduction. Regarding post operative complication no patient were presented with implant failure, malunion and delayed union was present in 10% patients. Joint stiffness and shortening of limb was present in 8% patients.

Discussion and Conclusion: We can conclude that subtrochantric fracture is common in elderly and trivial fall is common cause. Intra-operative variables during proximal femoral nailing were good with less blood loss and minimum deformities. Post-operative variables like non union and joint stiffness was less. Most of the patients have good functional outcome.

Keywords: Subtrochantric fracture, proximal femoral nail, functional outcome

Introduction

J William fielding from his observation published in 1949 has explained that subtrochantric region is between the lesser trochanter and around 5–7.5 cm below it, toward the femoral isthmus. The fractures can extend to the proximal region towards trochanteric area or distal region towards diaphyseal region. He has further quoted that is least common type of proximal femur ranges from 7% to 24% of total hip fracture^[1, 2] As longevity of individual has increased so various type of fracture associated with old age also increased fracture of hip is one of them. It has been observed in various studies that hip fracture incidence rates rise exponentially with age. Subtrochantric fracture is common in young age also but aetiology of fracture is different from old age. In old age cause of fracture is trivial trauma but in young people it is because of high-energy traumas^[3, 4].

Subtrochantric region is cortical in nature and vascularity is slow so healing is not as fast as highly vascular area of bone. This area of femur is subjected to stress due to its muscular insertions. So there is greater chance of fixation failure, non-union, and failure of procedure^[5, 6]. Because of these anatomical difficulties management of subtrochantric fracture of femur is challenge. There are both surgical and non surgical management of subtrochantric fracture but non surgical management is exception. It is associated with shortening, rotational deviation morbidity and mortality increase caused by extended periods of immobilization and decubitus for evaluation modified Harris hip score was used^[7]. The primary goal of surgical management is to restore anatomical alignment, early immobilisation and weight bearing.

Corresponding Author:
Dr. Dune Apparao
Assistant professor, dept of
orthopaedics, Konaseema
institute of medical science
Amalapuram, Andhra Pradesh,
India

Early mobilization and weight bearing are possible with advances in implants and fixation technology [6, 7] Recently because of better understanding of anatomy, reduction techniques and biomechanically more advanced implants are used. Mainly two types of implants are used extramedullary and intramedullary. Out of these two intramedullary implants have several biomechanical advantages. In spite of development of new implants, the treatment of subtrochanteric fractures of the femur still presents with complications and remains challenging [8].

Keeping all these in view present study has been designed to study the anatomical and functional outcome of subtrochanteric fracture treated with proximal femoral nail, to access the stability of fixation and mobility of the patients and compare the result with standard treatment.

Material and Method

This is a prospective observational study conducted in the department of orthopaedics Konaseema institute of medical science from July 2017 to October 2019.

Selection of patients: - Patients with sub trochanteric fracture admitted in the department of orthopaedics and trauma are enrolled for this study based on inclusion and inclusion criteria.

Inclusion criteria:-	Exclusion criteria
Age above 18 years	pathological fracture
Both sexes	open fracture
Subtrochanteric fracture	old neglected fractures

Sample size: Based on exclusion and inclusion criteria 50 patients were enrolled during twenty eight months of this study.

Ethics: Present study is approved by institutional ethics committee. A written informed consent was obtained from all patients before enrolling them for study.

Collection of data: All detail of the patient was recorded in predesigned Performa. After discharge from hospital patient was followed regularly both clinically and radiologically till full recovery.

Method: After admission in pre operative planning, all basic investigation was done associated injuries were evaluated and treated. Diameter of the nail was measured by x-ray of the patients neck shaft angle was measure of unaffected side using goniometer. We have used standard length proximal femoral nail 250mm in size. Distal diameter of nail was 11, 12, 13mm and the proximal diameter was 14mm. The length of

proximal derotation screw was 6.5mm and distal lag screw of 8mm. Distal locking is done with self tapping 4.9mm cortical screws in dynamic and static mode to allow 5mm movement. In the operation theatre patient was positional and dropped as per standard hip fracture fixation. Prophylactic antibiotic was given to all patients. After localisation of greater trochanter and 5cms incision was made proximal to it, fascia lata and gluteus maximums was incised in the line of fibre tip of greater trochanter was exposed and entry was made in the centre of medullary cavity in lateral view or slightly lateral to the tip of greater trochanter in AP view in C-arm. In this direction guide wire is inserted to a depth of 30 cm with a T handle. Manual reaming was done till the stop on the protection sleeve after a cannulated rigid reamer through protection over the guide wire.

The length of hip pin was measured, to be 5mm and was inserted to prevent the rotation of medical fragment with the help of guide wire. The length and position was confirmed with C-Arm, Guide wire then removed. Neck screw was inserted using cannulated screw driver. For distal locking two cortical screw was used it was inserted through protection sleeve and position was confirmed with image intensifier. After procedure is over wound was cleaned by normal saline and wound was closed in layers. All vitals were measured in post operative period, antibiotic was continued and analgesic was given as per requirement, suture was removed on 10th operative day.

All patients were followed every month for first 3 month and after that once in three month for one year. At every visit patient were accessed clinically regarding hip and knee fixation, fracture union, shortening, deformity and ability to walk. For evaluation modified Harris hip score was used [9].

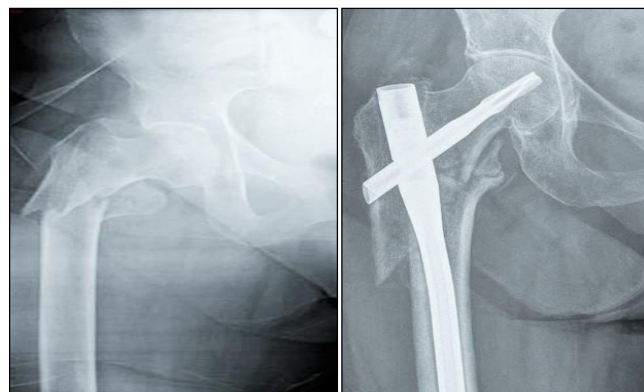

Fig 1: Subtrochanteric fracture of femur treated with proximal femoral nail

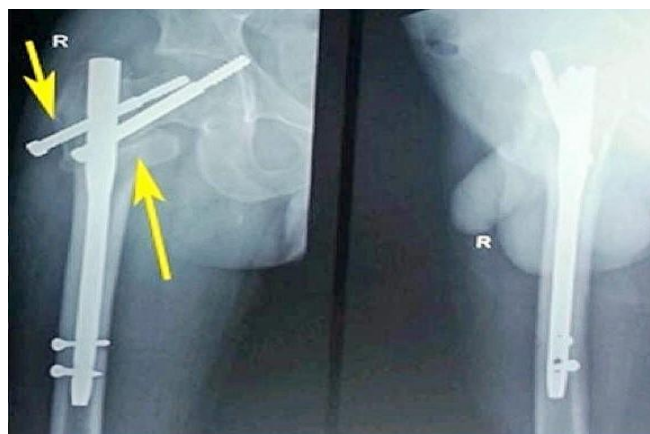


Fig 2: Proximal femoral nail lateral view

Result

As per exclusion and inclusion criteria 50 patients with

subtrochantric fracture are enrolled for this study.

Table 1: demography of patient with subtrochantric fracture

variables	number	percentage
Age (years)	0 to 30 years	7 14%
	31 to 60 years	20 40%
	More than 60 years	23 46%
sex	male	38 76%
	female	12 24%
Mode of injury	RTA	24 48%
	Fall from height	4 8%
	Trivial injury	22 44%
Side of fracture	Right	32 64%
	left	18 36%
Type of fracture (Seinsheimer classification)	Type I	0 0%
	Type II(a,b,c)	22 44%
	Type III(a,b)	18 36%
	Type IV	9 18%
	Type V	1 2%

As per table 1, seven patients (14%) were below 30 years of age, 20 patients (40%) were between 31 to 60 years of age rest were above 60 year that was 46%. Out of 50 patients 38 were male and 12 were female. Regarding mode of injury RTA was mode of injury in 48% patients. Mode of injury in 4

(8%) was fall from height and trivial injury in 22(44%) patients. Right side fracture was more common (64%) then left side that is (36%). Type II fracture are more common followed by type III and type IV.

Table 2: Intra-operative variables of subtrochantric fracture

variables	number	percentages
Duration of surgery (minutes) (Mean \pm SD)	95.636 \pm 16.799	-
Amount of blood loss (mean \pm sd)	114.387 \pm 17.90	-
complications	Required open reduction	6 12%
	Anatomical reduction failure	2 4%
	Varus angulations	1 2%

The duration of surgery was 95.636 \pm 16799 minutes in present study. The mean volume of blood lost during surgery was 114.387 \pm 17.90 ml. Now regarding complication of in

intra operative period 12% patient required open reduction, anatomical reduction failure was present in 4% and one patient were presented with varus angulations.

Table 3: post-operative variables of subtrochantric fracture

variables	number	percentage
Implant failure	0	0%
Malunion(varus $<10^\circ$)	5	10%
Non union	0	0%
Delayed union	5	10%
Joint stiffness	4	8%
shortening	4	8%
Duration of hospital stay(Mean \pm SD)	19.84 \pm 2.4113	
Time required for full weight bearing (Mean \pm SD)	16.04 \pm 4.431	
Mobility of patient	mobile	38 76%
	aided	12 24%
	Non-ambulatory	0 0%
Mobility of joint	Hip up to 110	48 96%
	Knee up to 120	44 88%

Regarding post operative complication no patient were presented with implant failure, malunion and delayed union was present in 10% patients. Joint stiffness and shortening of limb was present in 8% patients. The mean duration of hospital stay was 19.84 \pm 2.4113 days and mean of time required for full weight bearing was 16.04 \pm 4.431 days. In present study 76% patient were mobile, 24% patient required aids for mobilisation. Mobility of hip joint was 110 degree in 96% patients and mobility of knee joint was 120 degree in 88% patients.

Table 4: Functional outcome of treatment of subtrochantric fracture by proximal femoral nail

variables	Number	percentage
Excellent	18	36%
Good	26	52%
Fair	6	12%
Poor	0	0%

The functional outcome was good in 52% and excellent in 36%. In our study 12% patient have fair outcome.

Discussion

In present study 50 patients were evaluated for the anatomical and functional outcome of subtrochanteric fracture treated with proximal femoral nail and stability of fixation and mobility of the patients were assessed. It has been found that there male predominance and more cases were more than 60 year of age followed by between 31 to 60 years. This finding is supported by work of EL- Mowfi and Eid TA *et al.* [10] In present study trivial fall is the common mode of injury, right side is effected commonly and type 11 fracture is common then other type which is similar to the finding of LS Jiang, Sheng L *et al.* [11] Duration of surgery and amount of blood loss was 95.636 ± 16.799 min and 114.387 ± 17.90 ml, which is supported by the finding of Kumar M, Akshat V, *et al* and EL- Mowfi and Eid TA *et al.* [12, 10] Regarding intra operative complication required open reduction was little common that is 12% then anatomical reduction failure and varus angulations which is supported by the work of Chopra BL, Kumar K *et al.* [13] There was no incidence of non union and implant failure but delayed union malunion joint stiffness was present in less than 10% patients which corroborates with the finding of Abraham VT, Chandrasekaran M *et al.* [14] Duration of hospital stay and Time required for full weight bearing was 19.84 ± 2.4113 days and 16.04 ± 4.431 days respectively which corroborates with the finding of Ekström W, Karlsson-Thur C, *et al.* [15] Regarding mobility of patients 76% were mobile and 24% were able to move with aid, which corroborates with the finding of Ekström W, Karlsson-Thur C, *et al* and Ramakrishnan M, Prasad SS *et al.* [15, 16] Functional outcome of treatment of subtrochanteric fracture by proximal femoral nail was good in 52% patients and excellent in 36% which corroborates with the finding of Klinger HM, Baums MH, Eckert M, Neugebauer R. *et al.* [17]

Conclusion

Based on our study we can conclude that subtrochanteric fracture is common in elderly and trivial fall is common cause. Intra-operative variables during proximal femoral nailing were good with less blood loss and minimum deformities. Post-operative variables like non union and joint stiffness was less. Most of the patients have good functional out come.

Reference

- Fielding JW. Subtrochanteric fractures. Clin Orthop Relat Res. 1973; (92):86-99
- Boyd Hb, Griffin LL. Classification and treatment of trochanteric fracture. Arch Surg. 1949; 58(6):853-866. doi:10.1001/archsurg.1949.01240030864012
- Brauer CA, Coca-Perraillon M, Cutler DM, Rosen AB. Incidence and Mortality of Hip Fractures in the United States. JAMA. 2009; 302:1573-1579.
- Michelson JD, Myers A, Jinnah R, Cox Q, Van Natta M. Epidemiology of hip fractures among the elderly. Risk factors for fracture type. Clin Orthop Relat Res. 1995; (311):129-135.
- Joglekar SB, Lindvall EM, Martirosian A. Contemporary management of sub trochanteric fractures. Orthop Clin North Am. 2015; 46(1):21-35
- Barbosa de Toledo Lourenço PR, Pires RE. Subtrochanteric fractures of the femur: update. Rev Bras Ortop. 2016; 51(3):246-253. Published 2016 Mar 21. doi:10.1016/j.rboe.2016.03.001.
- Gadegone W, Lokhande V, Salphale Y, Ramteke A. Long proximal femoral nail in ipsilateral fractures proximal femur and shaft of femur. Indian J Orthop. 2013; 47(3):272-277. doi:10.4103/0019-5413.109441.
- Streubel PN, Wong AH, Ricci WM, Gardner MJ. Is there a standard trochanteric entry site for nailing of subtrochanteric femur fractures? J Orthop Trauma. 2011; 25(4):202-7.
- Harris WH. Traumatic arthritis of the hip after dislocation and acetabular fractures: treatment by mold arthroplasty. J Bone Joint Surg Am. 1969; 51:737-755.
- El-Mowafi HM, Eid TA, El-Sayed AS, Zalalo SH. Fixation of subtrochanteric fracture femur using a proximal femoral nail. Menoufia Med J [serial online] 2014 [cited 2020; 27:208-14. Available from: <http://www.mmj.eg.net/text.asp?2014/27/1/208/132811>.
- Jiang LS, Sheng L, Dai LY. Intramedullary fixation of subtrochanteric fractures with long proximal femoral nail or long gamma nail: technical notes and preliminary results. Ann Acad Med Singapore 2007; 36:821-826.
- Kumar M, Akshat V, Kanwariya A, Gandhi M. A Prospective Study to Evaluate the Management of Subtrochanteric Femur Fractures with Long Proximal Femoral Nail. Malays Orthop J. 2017; 11(3):36- 41. doi:10.5704/MOJ.1711.014.
- Chopra BL, Kumar K, Khajotia BL, Bhambu R, Bhatiwal S, Shekhawat V Proximal femoral nail outcome and complications: a prospective study of 125 cases of proximal femoral fractures Int J Res Orthop. 2017; 3:973-8
- Abraham VT, Chandrasekaran M, Mahapatra S. Outcome of subtrochanteric fracture of the femur managed with proximal femoral nail. Int Surg J. 2016; 3:1296-300.
- Ekström W, Karlsson-Thur C, Larsson S, Ragnarsson B, Alberts KA. Functional outcome in treatment of unstable trochanteric and subtrochanteric fractures with the proximal femoral nail and the Medoff sliding plate. J Orthop Trauma. 2007; 21(1):18- 25. doi:10.1097/BOT.0b013e31802b41cf.
- Ramakrishnan M, Prasad SS, Parkinson RW, Kaye JC. Management of subtrochanteric femoral fractures and metastases using long proximal femoral nail. Injury. 2004; 35(2):184- 190. doi:10.1016/s0020-1383(03)00101-3.
- Klinger HM, Baums MH, Eckert M, Neugebauer R. Eine vergleichende Untersuchung der Versorgung instabiler per- und intertrochantärer Femurfrakturen mittels DHS-Osteosynthese unter Verwendung der Trochanterabstützplatte und dem Proximalen Femurnagel (PFN) [A comparative study of unstable per- and intertrochanteric femoral fractures treated with dynamic hip screw (DHS) and trochanteric butt-press plate vs. proximal femoral nail (PFN)]. Zentralbl Chir. 2005; 130(4):301- 306. doi:10.1055/s-2005-836784.