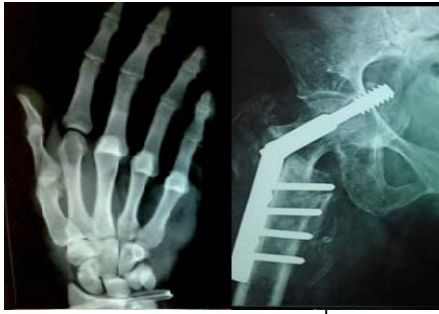



International Journal of Orthopaedics Sciences

E-ISSN: 2395-1958
P-ISSN: 2706-6630
IJOS 2020; 6(2): 677-680
© 2020 IJOS
www.orthopaper.com
Received: 15-02-2020
Accepted: 20-03-2020

Dr. Jaspal Singh
Professor, Department of
Orthopaedics, Government
medical College & Hospital,
Amritsar, Punjab, India

Dr. Partap Singh
Professor and head Department
of Orthopaedics, Government
medical College & Hospital,
Amritsar, Punjab, India

Dr. Saurabh Jain
Junior Resident Department of
Orthopaedics, Government
Medical College & Hospital,
Amritsar, Punjab, India

Dr. Gurinder Pal Singh
Junior Resident Department of
Orthopaedics, Government
Medical College & Hospital,
Amritsar, Punjab, India

Corresponding Author:
Dr. Partap Singh
Professor and head Department
of Orthopaedics, Government
medical College & Hospital,
Amritsar, Punjab, India

Operative treatment of inter-condylar and supra-condylar fracture of femur by swashbuckler approach

Dr. Jaspal Singh, Dr. Partap Singh, Dr. Saurabh Jain and Dr. Gurinder Pal Singh

DOI: <https://doi.org/10.22271/ortho.2020.v6.i2k.2118>

Abstract

Background: Fractures in the distal femur have posed considerable therapeutic challenges throughout the history of fracture treatment. Most of these surgical failures were due to inadequate fixation of the fracture fragments. Hence; the present study to report the results in a prospective study of patients with distal femur fractures, operated using Swashbuckler approach.

Materials & methods: 20 patients with inter-condylar and supracondylar fracture were enrolled. Twenty adult patients with open reduction and internal fixation of distal femur fractures with multifragmentary articular involvement were included in this prospective study. At 1 year follow-up, the Knee society score 17 was recorded, including the knee and functional subsets. A Knee Society Knee Score between 80 and 100 was regarded as excellent, between 70 and 79 was regarded as good, between 60 and 69 was regarded as fair, and <60 was regarded as poor. All the results were analysed by SPSS software.

Results: In 70 percent of the patients, mean duration of bony union was 17.35 weeks. KSS consist of two components: Knee society knee score (KSKS) and Knee society function score (KSFS). Mean KSKS score was 83.70 and KSFS was 80.25 respectively. At one year follow-up, excellent results were obtained in 60 percent of the patients (12 patients), while good and fair results were obtained in 25 percent (5 patients) and 15 percent of the patients (3 patients). Complications were found to be present in 2 patients.

Conclusion: Reconstruction of distal femur fractures especially in supracondylar and intercondylar fractures is a challenging task. For better functional outcome; proper anatomical alignment is required which can be achieved by swashbuckler approach.

Keywords: Swashbuckler, femur

Introduction

The femur is the longest, heaviest, and strongest bone in the human body. At the proximal end, the pyramid-shaped neck attaches the spherical head at the apex and the cylindrical shaft at the base. Hip fracture contributes to both morbidity and mortality in the elderly. The demographics of world populations are set to change with more elderly living in developing countries and it has been estimated that by 2050 half of hip fractures will occur in Asia^[1-4].

Fractures in the distal femur have posed considerable therapeutic challenges throughout the history of fracture treatment. Most of these surgical failures were due to inadequate fixation of the fracture fragments. Intraarticular supracondylar fracture of the femur is a complex injury that poses various challenges for the orthopedic surgeon starting from management of fracture to a protracted recovery of the patient with a very high potential of long-term disability like joint stiffness and mal union being the major culprits^[5].

Several treatment options are available for fractures of the distal femur which require internal fixation using various places such as 95 degree angled blade plate, condylar buttress plate, dynamic condylar screw with 95 degree side plate, distal femur locking compression plate (open or by LISS method i.e. less invasive stabilization system) and intramedullary nails (ante grade/retrograde)^[5]. It is not clear whether one implant is more reliable than other in achieving consistently good results. Various surgical approaches in the past literature have suggested achieving an adequate exposure of the distal femoral articular surface, including medial/lateral parapatellar approaches, Swashbuckler approach, tibial tubercle osteotomy, and combined

medial and lateral approaches. External ring fixators have been used with mixed results by several previous authors to address the comminution in these complex injuries. Some have used dual medial and lateral plates in these. Most previous authors have employed primary bone grafting to enhance union in these complex fractures. The use of Swashbuckler approach for femur fractures has been reported minimally in the literature [6-8]. Hence; under the light of above data, we have planned the present study to report the results in a prospective study of patients with distal femur fractures, operated using Swashbuckler approach.

Materials & Methods

The present study was conducted in the department of Orthopaedics of the Govt. Medical College, Amritsar and it included assessment of patients inter-condylar and supracondylar fracture of femur by Swashbuckler approach clinically. 20 patients with inter-condylar and supracondylar fracture were enrolled. Twenty adult patients with open reduction and internal fixation of distal femur fractures with multifragmentary articular involvement were included in this prospective study. Patients were taken up for surgery after routine preoperative workup. All the patients were operated within 10 days of the initial trauma. The patient was placed in

supine on a radiolucent table. A sterile tourniquet was used only if necessary to avoid medial retraction of the quadriceps. Placement of a retractor under the vastus lateralis and medialis was done, exposing the distal femur and displacing the patella medially. Ligation of the perforating vessels and elevation of vastus lateralis was done, exposing the entire distal femur. The wound was sutured by placing the fascia back in place. All the patients were operated in the supine position on a radiolucent table. The Swashbuckler approach described by Starr *et al.* was used in all cases [8]. Osteochondral fragments were fixed with headless or countersunk screws (for large fragments >1cm) or K-wires (for intermediate fragments 5-10mm). K-wires were put in a divergent fashion, preferably purchasing the far cortex (bicortical) and was cut flush with the articular surface (lost K-wire technique). Small osteochondral fragments (<5mm) were excised. Chondral fragments were similarly fixed with K-wires or excised. At 1 year follow-up, the Knee society score 17 was recorded, including the knee and functional subsets. A Knee Society Knee Score between 80 and 100 was regarded as excellent, between 70 and 79 was regarded as good, between 60 and 69 was regarded as fair, and <60 was regarded as poor [8]. All the results were analysed by SPSS software.

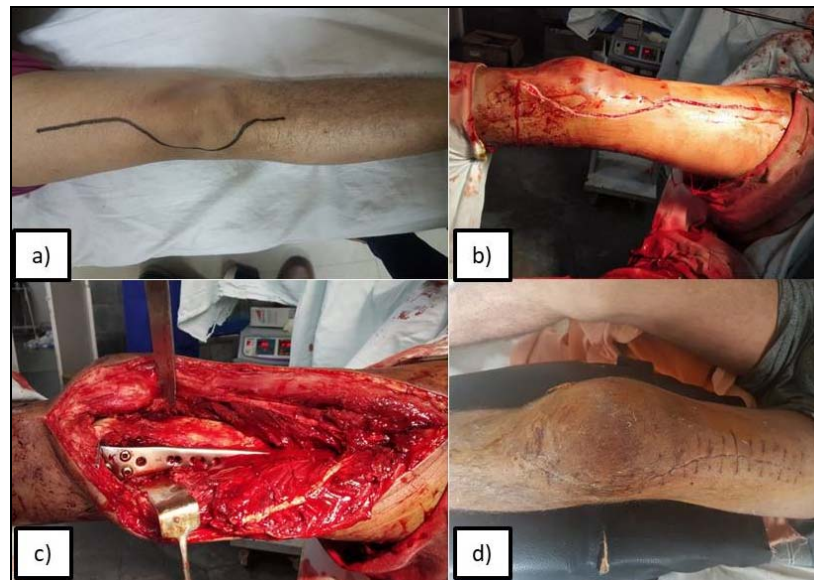


Fig 1: a) Line of Incision, b) Incision, c) Intraoperative, d) Closure

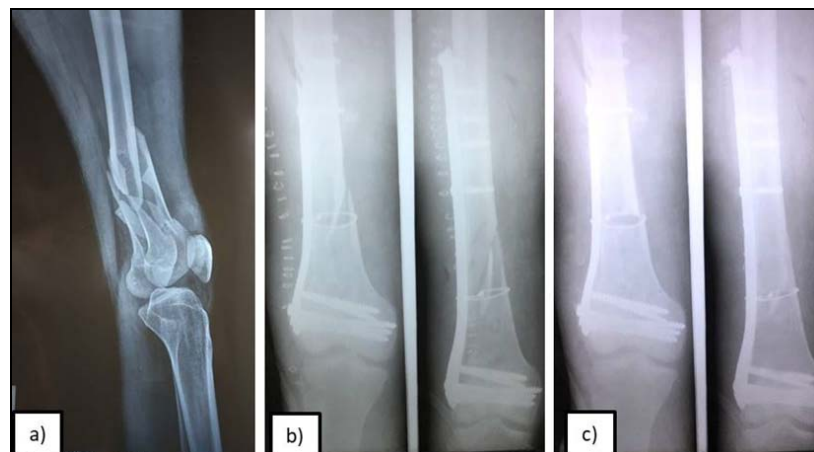

Fig 2: Radiograph a) Preoperative, b) Immediate Postoperative, c) Postoperative 6 months

Results

Table 1 shows the age-wise distribution of patients. A total of 20 patients were analyzed. 65 percent of the patients (13 patients) belonged to the age group of less than 40 years. Mean age of the patients of the present study was 35.15 years. In 70 percent of the patients, mean duration of bony union was 17.35 weeks. KSS consist of two components: Knee society knee score (KSKS) and Knee society function score (KSFS). Mean KSKS score was 83.70 and KSFS was 80.25 respectively. At one year follow-up, excellent results were obtained in 60 percent of the patients (12 patients), while good and fair results were obtained in 25 percent (5 patients) and 15 percent of the patients (3 patients). Complications were found to be present in 2 patients. Superficial infection and restriction of movement was seen in 1 patient each. The overall incidence of complications was 10 percent.

Table 1: Age-wise distribution

Age group (years)	Number of patients	Percentage of patients
18 to 30	10	50
31 to 40	3	15
41 to 50	4	20
51 to 60	3	15
Total	20	100
Mean \pm SD	35.15 \pm 11.49	

Table 2: Mean time of bony union

Time to bony union	Number of patients	Percentage of patients
3 weeks	0	0
6 weeks	0	0
9 weeks	2	10
12 weeks	4	20
24 weeks	14	70
Total	20	100
Mean \pm SD (weeks)	17.35 \pm 5.26	

Table 3: Knee society score (KSS) at 6 months follow-up

Knee society score (KSS) components	Mean	SD
Knee society knee score (KSKS)	83.70	11.09
Knee society function score (KSFS)	80.25	9.38

Table 4: Outcome at 6 months follow-up according to KSS

Outcome	Number of patients	Percentage of patients
Excellent	12	60
Good	5	25
Fair	3	15
Poor	0	0

Table 5: Complications

Complications	Number of patients	Percentage of patients
Superficial infection	1	5
Restriction of movement	1	5
None	18	90
Total	20	100

Discussion

In the present study, a total of 20 patients were analyzed. 65 percent of the patients belonged to the age group of less than 40 years. Mean age of the patients of the present study was 35.15 years. 90 percent of the patients of the present study were males while the remaining were females. Our results were in concordance with the results obtained by previous authors who also reported similar findings. In a study conducted by Ahire R *et al*, authors reported that 91.67 percent of the patients were males and 63.33 percent of

the patients belonged to the age group of less than 40 year.⁹ In the present study, in 70 percent of the patients, the duration of surgery was 60 to 90 minutes. Mean duration of surgery in the present study was 87.35 minutes. Our results were in concordance with the results obtained by previous authors who also reported similar time duration of surgery in their respective studies.

The mean duration of surgery for Swashbuckler group in a study conducted by Ahire R *et al* was 85 minutes^[9]. However; longer average duration of surgery of 112 minutes was reported in the study conducted by Solanki R *et al*^[10].

Successful fracture union was defined as complete bridging callus in three cortices, together with painless full weight bearing. Radiological union of the fracture i.e. characterized by cortex to cortex healing and bridging callus of the fracture in both AP and lateral views of follow up x-rays, was considered as satisfactory union^[9]. In the present study, in 70 percent of the patients, mean duration of bony union was between 12 to 24 weeks. Mean time duration of bony union was found to be 17.35 weeks. Our results were in concordance with the results obtained by previous authors who also reported similar time of bony union in their respective studies. The average time of union was reported to be 18.4 weeks in the study conducted by Solanki R *et al*^[10].

In the present study, KSS was calculated at 1 year follow-up. KSS consist of two components: Knee society knee score (KSKS) and Knee society function score (KSFS). Mean KSKS score was 83.7 and KSFS was 80.25 respectively. At one year follow-up, excellent results were obtained in 60 percent of the patients (12 patients), while good and fair results were obtained in 25 percent (5 patients) and 15 percent of the patients (3 patients).

Our results were in concordance with the results obtained by Agrawal A *et al*, who also reported similar findings. In their study, mean KSKS was 82.33 and mean KSFS was 82.5. They reported that excellent results were obtained in 58.33 percent of the patients, while good and fair results were observed in 25 percent of the patient's and 16.67 percent of the patients^[11].

In another study conducted by Solanki R *et al*, the functional and radiological outcome was studied using NEER knee score. They reported that excellent and satisfactory results were found to be present in 69.23 percent of the patients^[10].

In the present study, complications were found to be present in 2 patients. Superficial infection and restriction of movement was seen in 1 patient each. The overall incidence of complications was 10 percent. In a study conducted by Ahire R *et al*, restriction of movement and terminal extension lag was seen in 6.67 percent of the patients each. The overall incidence of complications in their study was 13.33 percent^[9]. The outcome of distal femur fractures has improved in recent times, with the use of biological and indirect reduction techniques and percutaneous osteosynthesis with bridge plates, usually locked ones. Zlowodzki *et al*. in a systematic review of different fixation techniques in the operative management of acute non periprosthetic distal femur fractures found that the use of locked plates is associated with a decreased relative risk of nonunions and infections as compared to compression plates. However, they found an increased relative risk of fixation failures and secondary surgical procedure with the use of locked plates. Several other studies have expressed concerns that locking plates may cause callus inhibition, with reported nonunion rates up to 20% in distal femur fractures. Furthermore, the precontoured locked plates may not conform to the bony contours in all patients

and may lead to malalignment ^[12-14].

femur fractures. Clin Orthop Relat Res, 2010, 2011; 469:1757-65.

Conclusion

Reconstruction of distal femur fractures especially in supracondylar and intercondylar fractures is a challenging task. For better functional outcome; proper anatomical alignment is required which can be achieved by swashbuckler approach. Excellent results are shown by Swashbuckler approach in terms of anatomical reduction and functional outcome.

References

1. Gwathmey FW Jr, Jones-Quaidoo SM, Kahler D. Distal femoral fractures: current concepts. Review. J Am Acad Orthop Surg. 2010; 18(10):597-607.
2. Henderson CE, Kuhl LL, Fitzpatrick DC. Locking plates for distal femur fractures: is there a problem with fracture healing?. Review. J Orthop Trauma. 2011; 25(1):S8-14.
3. Areneson TJ, Melton LJ, Lewallen DG. Epidemiology of diaphyseal and distal femoral fractures in Rochester, Minnesota, 1965-1984. Clin Orthop Relat Res. 1988; 234:188-94.
4. Martinet O, Cordey J, Harder Y. The epidemiology of fractures of the distal femur. Injury 2000; 31(3):C62-3.
5. M-Hosam N, Emad EI M, Khaled I. Buttress Condylar Plating in Treatment of Intercondylar Supracondylar Fractures of Distal Femur. Pan Arab J Orth Trauma. 2007; 11(1):26-34.
6. Khan MA, Shafique M, Sahibzada AS, Sultan S. Management of type-A supracondylar fractures of femur with dynamic condylar screw (DCS). Journal of Medical Sciences January. 2006; 14(1):44-7.
7. Hofbauer M, Muller B, Murawski CD, Baraga M, Van Eck CF, Fu FH. Strategies for revision surgery after primary double-bundle anterior cruciate ligament (ACL) reconstruction. Knee Surg Sports Traumatol Arthrosc. 2013; 21(9):2072-80.
8. Zeebregts CJ, Zimmerman KW, Ten Duis HJ. Operative treatment of a unilateral bicondylar fracture of the femur. Acta Chir Belg. 2000; 100(3):104-6.
9. Ahire R, Jindal S, Phuljhele S, Dev Sahu N, Kashyap G. A comparative study between swashbuckler approach (Modified Anterior Approach) and lateral approach for the distal femur fractures. International Journal of Orthopaedics Sciences 2018; 4(3):184-188.
10. Solanki R, Tolani A, Asati S, Kansara H, Pathria V. AO type C distal femur fracture: results of operative management in 52 patients. International Journal of Orthopaedics Sciences. 2018; 4(4):73-77.
11. Agrawal A, Kiyawat V. Complex AO type C3 distal femur fractures: Results after fixation with a lateral locked plate using modified swashbuckler approach. Indian J Orthop. 2017; 51:18-27.
12. Rademakers MV1, Kerkhoffs GM, Sierevelt IN, Raaymakers EL, Marti RK. Intraarticular fractures of distal femur-A long term follow up study of surgically treated patients. J Orthop Trauma. 2004; 18(4):213-9.
13. Zlowodzki M, Bhandari M, Marek DJ, Cole PA, Kregor PJ. Operative treatment of acute distal femur fractures: Systematic review of 2 comparative studies and 45 case series (1989 to 2005). J Orthop Trauma 2006; 20:366-71.
14. Henderson CE, Lujan TJ, Kuhl LL, Bottlang M, Fitzpatrick DC, Marsh JL. Mid-America Orthopaedic Association Physician in Training Award: Healing complications are common after locked plating for distal