



E-ISSN: 2395-1958

P-ISSN: 2706-6630

IJOS 2020; 6(2): 371-374

© 2020 IJOS

[www.orthopaper.com](http://www.orthopaper.com)

Received: 19-01-2020

Accepted: 23-02-2020

**R Dinesh Iyer**

Senior Resident, Dept of Trauma Surgery, AIIMS, Rishikesh, Uttarakhand, India

**Bhaskar Sarkar**

Assistant Professor, Dept of Trauma Surgery, AIIMS, Rishikesh, Uttarakhand, India

**Samarth Mittal**

Senior Resident, Dept of Orthopaedics, AIIMS, Rishikesh, Uttarakhand, India

## Asymmetric incomplete cord syndrome: A delayed and unusual presentation of traumatic sub-axial cervical disc prolapse

**R Dinesh Iyer, Bhaskar Sarkar and Samarth Mittal**

**DOI:** <https://doi.org/10.22271/ortho.2020.v6.i2f.2070>

### Abstract

Isolated non-osseous cervical spine injuries are rare entities and most of the algorithms (NEXUS criteria and Canadian C- spine rules) focus on ruling out osseous injuries. Discoligamentous injuries require high index of suspicion and thorough clinical examination which may not be possible in emergency department due to other distracting injuries or lack of trained personnel in the centre. We present a case of 27 years old male with an unusual presentation of a combination of upper motor neuron and lower motor neuron lesions due to traumatic disc prolapse.

**Keywords:** Traumatic disc prolapse, discoligamentous injuries, nexus criteria, canadian c - spine rules, anterior cervical discectomy and fusion

### Introduction

Isolated non-osseous cervical spine injuries are rare entities <sup>[4]</sup> (3.8% of all cervical spine injuries) and most of the existing algorithms (NEXUS criteria and Canadian C- spine rules) focus on ruling out osseous injuries <sup>[5, 6]</sup>. Disco-ligamentous injuries require high index of suspicion and thorough clinical examination which may not be always possible in emergency department due to other distracting injuries or lack of trained personnel in the centre. We present a case of traumatic C4-C5 disc prolapse in a 27 years old male who presented late with an unusual neurologic picture.

### Presentation

A 27 year old male presented to our Spine Injury Clinic twelve days after injury, that he sustained allegedly when his bike was struck by a four-wheeler from side and he fell from bike without helmet. His initial complaints was weakness in all four limbs, subjectively more involvement of right upper limb, and pain over right shoulder, both increasing progressively for last ten days. He had to seek our advice for urinary urgency and involuntary dribbling of for last five days. He was able to ambulate within his house though with a bit of unsteadiness while walking.

### Clinical Assessment

On clinical examination right sided clavicle fracture and mandible fracture was detected and managed accordingly.

On local examination of cervical spine there was midline tenderness in neck posteriorly without any clinical deformity.

Neurological examination of the patient gave an unusual picture. Bulk of both upper limbs were symmetrical as were in lower limbs. Both lower limbs and left upper limb showed hypertonia with clasp-knife spasticity, while right upper limb was flaccid. On examination of muscle power (according to Medical Research Council grading system), which may be inaccurate due to hypertonia, the patient had grade 4+ power in both lower limb muscle groups. In left upper limb the patient had grade 4+ power in all groups with maintained grip strength.

**Corresponding Author:**

**R Dinesh Iyer**

Senior Resident, Dept of Trauma Surgery, AIIMS, Rishikesh, Uttarakhand, India

Motor assessment of right upper limb showed grade 3 power at shoulder abduction and elbow flexion. Elbow extension was not possible against gravity and neither was wrist extension and palmar flexion (grade 2). His hand grip was weak on right side (~30%) and so were the interossei and thumb abductors.

**Table 1:** Power-charting of his bilateral upper extremities is given below:

Nerve root	Right	Left
C5	3/5	4+/5
C6	2/5	4+/5
C7	2/5	4+/5
C8	2/5	4+/5
T1	2/5	4+/5

Sensory examination was done for each dermatomes for touch, pressure, pain, temperature, proprioception and vibration, and were unremarkable.

Deep tendon reflexes of both lower limbs (knee jerk and ankle jerk were examined) and left upper limb (Biceps, triceps and supinator reflexes were examined) were exaggerated. Left side reflexes were 3+. Right lower limb reflexes were grade 4 + with sustained ankle and patellar clonus, and bilateral positive Babinski's sign. Reflexes were absent in right upper limb.

**Table 1.**

Reflex	Right	Left
Biceps jerk	-3	+2
Triceps jerk	-4	+2
Supinator jerk	-4	+2
Knee jerk	+4	+4
Ankle jerk	+4	+4
Plantar response	Upgoing	Upgoing

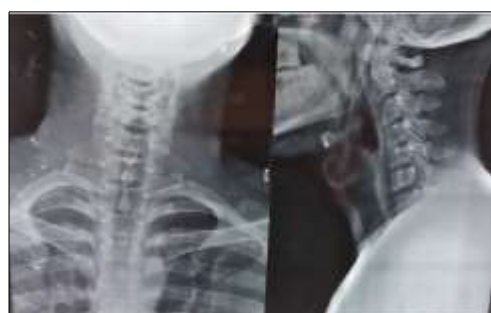Perianal sensations, voluntary anal contractions and bulbocavernous reflex were present.

Gait examination revealed scissoring gait, aligning with hypertonia in bilateral lower limbs.

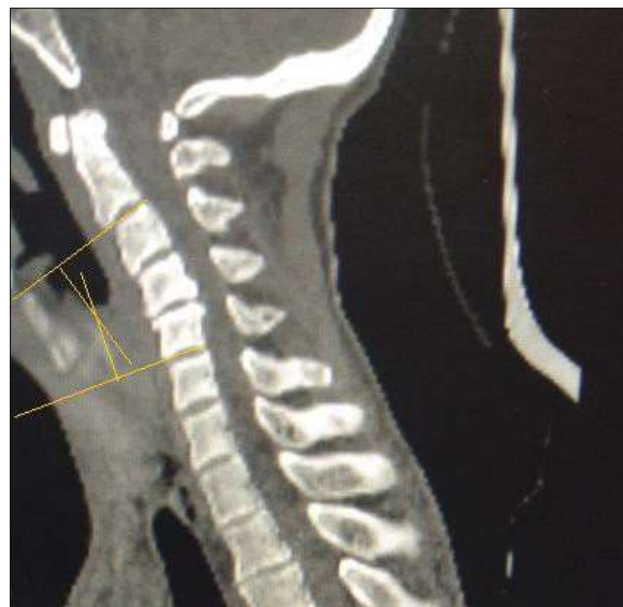**Radiological Assessment**

As per pre-operative protocol of the institute for patients with these injuries, orthogonal X-rays cervical spine, Multi-detector Computed Tomography (MDCT) of cervical spine with screening of whole spine and MRI of cervical spine were performed.

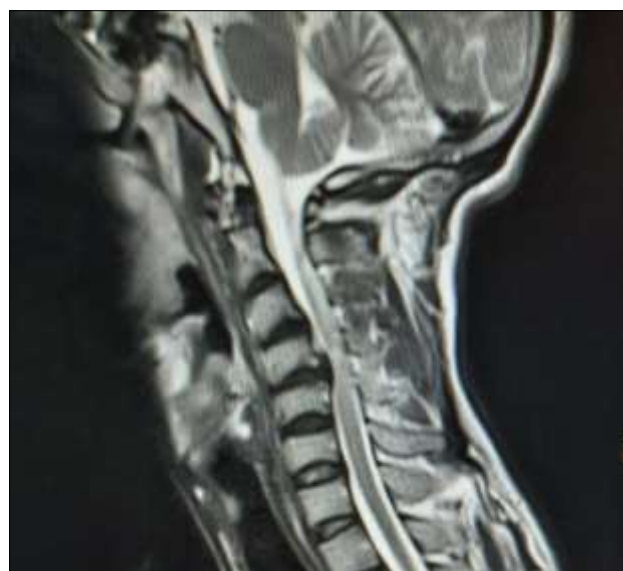Plain X-rays and MDCT of C-spine showed decreased disc height at C4-C5 level with focal kyphosis 15 degrees in the cervical region. MRI showed right paracentral C4-C5 disc protrusion with obliteration of functional reserve of CSF, and T1- and T2- hyper-intensity in cord at that level with no evidence of haematomyelia.



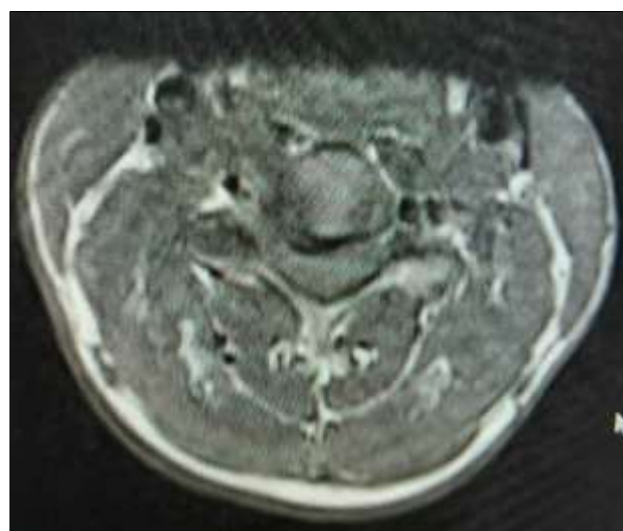
**Fig 1:** Pre operative radiographs of cervical spine



**Fig 2:** CT scan (Mid sagittal) showing no bony involvement and Pre-operative focal kyphosis of 15 degrees

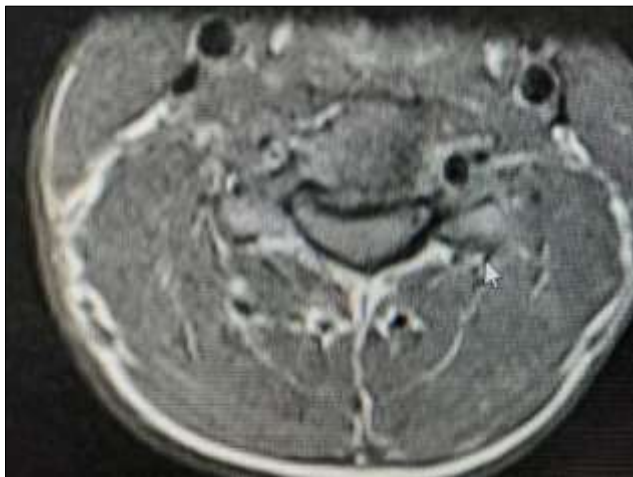


**Fig 3**

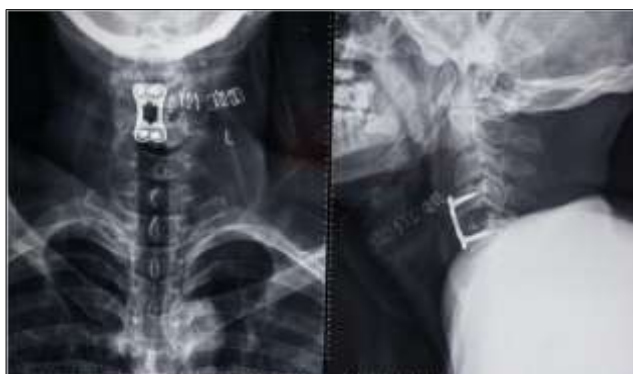

**Fig 4**

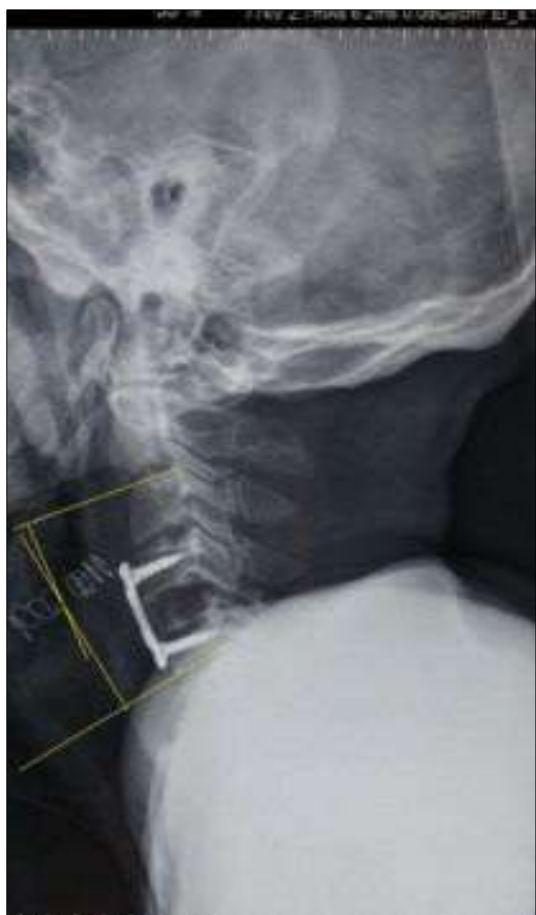**Fig 3 and 4:** Sagittal and axial section of MRI cervical spine showing posterolateral disc extrusion showing right sided root compression



**Fig 5:** Axial section showing central cord compression at C4-C5 level causing the UMN features



**Fig 6:** Post operative radiograph after ACDF at C4-C5



**Fig 7:** Restoration of cervical lordosis after surgery

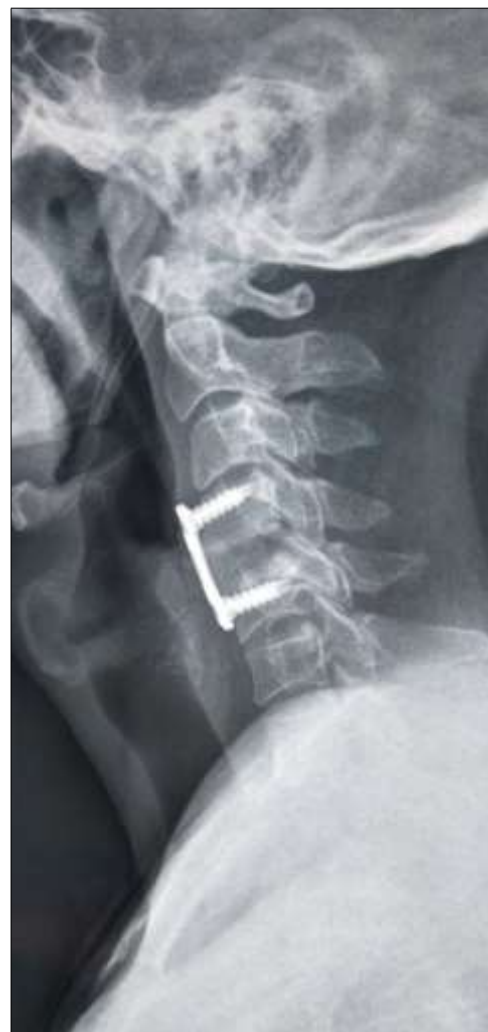Patient and his kin were explained about the need for surgical intervention and Pre-anaesthetic work-up started.

**Management**

Patient underwent anterior cervical discectomy and fusion at C4-C5 level 14 days after injury. Rehabilitation in the form of range of motion of all joints, chest and back care, stretching and strengthening exercises of upper and lower limb muscles were started from post-operative recovery room. Post-op neurology improved as right upper limb power at shoulder and elbow increased to 4/5 on Day-1 and plantar response became mute. Hospital stay was uneventful. Patient was discharged on post op day 2 with advice to continue immobilization with hard cervical brace and follow-up at 2 weeks for suture removal.

At 3 months follow up patient reported improvement in form of improved gait, increased power in right upper limb at elbow and wrist, and most importantly restored bladder control. However, weakness of hand grip and interossei muscles persisted and patient was advised to continue physical therapy.

Nerve root	Right	Left
C5	4-/5	5/5
C6	4-/5	5/5
C7	4-/5	5/5
C8	3/5	5/5
T1	3/5	5/5



**Fig 8:** 3 month follow up radiograph showing maintained cervical lordosis and evidence of bony fusion between C4-C5 bodies



## Discussion

There are numerous case reports regarding traumatic disc prolapse without osseous injuries but none with such an injury pattern. Timo M Ecker <sup>[4]</sup> and colleagues reported a case of cervical disc extrusion without neurological deficit, with only paraesthesia as the only symptom, while the two cases reported by Roberto Alexandre Dezena <sup>[2]</sup> and colleagues one presented with central cord syndrome and the other with anterior cord syndrome.

This case also highlights the fact that discoligamentous injuries of the cervical spine, though a rare clinical entity, can have varied presentations and devastating results if not diagnosed on time.

These injuries cannot be diagnosed by radiographs or CT done in the emergency room <sup>[5, 6]</sup>. Rather it requires thorough clinical examination and a high index of suspicion with special emphasis in patients with dangerous mechanism of injury (like in this case fall from bike and without helmet) and subtle radiologic signs (like decreased disc space and focal kyphosis in young adult). Our case had a delay of 12 days after injury when he presented with progressive neuro-deficit. The diagnosis was probably missed due to lack of proper clinical examination at the index centre and misinterpretation of initial radiographs as normal.

Probable explanation for the neurological deficit may be that the postero-laterally prolapsed disc causing compression of C5 nerve root on right side, leading to lower motor neuron-type picture in right upper limb, as well as compression of the cord at the same level, as evident in MRI findings, leading to clinical signs of Upper Motor Neuron-like picture in other three limbs. Still weakness of muscle groups in right upper limb innervated by roots below C5 could not be explained by the pathologic lesion.

## Conclusion

Radiologically innocuous-looking cervical spine injuries, though rare, may lead to potentially devastating consequences. Diligent clinical examination and scrutinization of initial radiographs are of paramount importance in high risk populations like in patients with high-velocity trauma. Also, clinical presentations of these injuries, though can be varied, should be explainable and synchronous with radiologic findings. If they do not, then our existing understanding of patho-anatomy of these injuries should be re-instigated. After all, science is all about questioning the existing one and discovering the newer one.

**Funding:** The authors received no funding/grant from any external agencies

**Conflict of Interest:** The authors declare that they have no conflict of interest.

**Ethical Approval:** All procedures performed in studies involving human participants were in accordance with the ethical standards of the institutional research committee (Institute ethics committee vide letter no. AIIMS (R) - ethics/1995) and with the 1964 Helsinki declaration and its later amendments or comparable ethical standards.

**Consent to Participate:** Written and informed consent were taken from the patient and his family members for using his individual and clinical data for publication and research purposes.

**Availability of Data and Materials:** Data sharing not applicable to this article as no datasets were generated or analysed during the current study

## References

1. Hayes KC, Askes HK, Kakulas BA. Retropulsion of intervertebral discs associated with traumatic hyperextension of the cervical spine and absence of vertebral fracture: an uncommon mechanism of spinal cord injury *Spinal Cord*. 2002; 40:544-547. Doi: 10.1038/sj.sc.3101344
2. Roberto Alexandre Dezena, Carlos Umberto Pereira, Leopoldo Prézia de Araújo, José Luiz Romeo Boulosa, Manoel Nunes da Silva. Traumatic extrusion of C5-C6 intervertebral disc associated to mielopathy without bone lesion: Report of 2 cases and review; *Rev. Chil. Neurocirugía*. 2014; 40:49-52.
3. Esa Kotilainen M, Tauno Kärki, Outi Satomaa K. Traumatic cervical disc herniation—tetraparesis in a patient kicked by a horse, *Acta Orthopaedica Scandinavica*. 1997; 68(2):176-177. DOI: 10.3109/17453679709004003
4. Timo Ecker M, Mark Kleinschmidt, Luca Martinolli, Heinz Zimmermann, Aristomenis Exadaktylos K. Clinical presentation of a traumatic cervical spine disc rupture in alpine sports: a case report; *Scandinavian Journal of Trauma, Resuscitation and Emergency Medicine*. 2008; 16:14. Doi:10.1186/1757-7241-16-14
5. Stiell IG, Clement CM, McKnight RD, Brison R, Schull MJ, Rowe BH *et al*. The Canadian C-spine rule versus the NEXUS low-risk criteria in patients with trauma. *N Engl J Med*. 2003; 349(26):2510-8.
6. Stiell IG, Wells GA, Vandemheen KL, Clement CM, Lesiuk H, DeMaio VJ *et al*. The Canadian C-spine rule for radiography in alert and stable trauma patients. *Jama*. 2001; 286(15):1841-8.