



# International Journal of Orthopaedics Sciences

E-ISSN: 2395-1958  
P-ISSN: 2706-6630  
IJOS 2020; 6(2): 171-180  
© 2020 IJOS  
[www.orthopaper.com](http://www.orthopaper.com)  
Received: 10-01-2020  
Accepted: 14-02-2020

**Venkatesh V**  
Senior Resident, Department of  
Orthopaedics, ChamaraJanagar  
Institute of Medical Sciences,  
ChamaraJanagar, Karnataka,  
India

**Abdul Ravoof**  
Professor & Unit Chief,  
Department of Orthopaedics,  
Adichunchanagiri Institute of  
Medical Sciences, Bellur,  
Karnataka, India

## Surgical management of malleolar fractures of ankle in adults

**Venkatesh V and Abdul Ravoof**

**DOI:** <https://doi.org/10.22271/ortho.2020.v6.i2c.2033>

### Abstract

**Background and Objectives:** Ankle fractures represents 10% of all fractures making it a second most common fractures of lower limb after hip. Peak incidence of ankle fractures in younger men & older women have a bimodal distribution. Typically low energy injuries with majority occurring due to simple falls or Sports. Ankle joint is very congruous and any disturbance of the normal articular relationship may result in some progressive arthrosis of biomechanical dysfunction. Determining ankle stability for planning fracture management is very critical. Stable fractures can be managed conservatively but outcomes of unstable fractures are always better with surgical management. ORIF has shown clearly the superiority in literatures. Lateral malleoli without any deltoid ligament involvement can be treated conservatively with good results whereas lateral malleoli with deltoid ligament involvement leads to talar subluxation and arthritis hence needs to be fixed stably. The objectives is to study the functional outcomes and results of surgical management of malleolar fractures, and to know the complications of open reduction internal fixation of malleolar fractures.

**Methods:** 30 patients with fresh malleolar fractures were taken into study. As soon as the patients were brought to emergency room a complete survey was done to rule out any significant injuries. Then radiographs were taken, both antero-posterior and lateral views of ankle joints. On admission history was elicited in relation to age, sex, occupation, address, mode of injury, past illnesses, associated medical ailments and was subjected to thorough clinical examination. Analgesics and below knee slabs were applied to alleviate the pain. Eventually fractures were classified according to Lauge Hansen's classification system. Patients were operated as early as possible once they were fit for Surgery.

**Results:** Out of 30 patients treated 23(76.6%) had good to excellent results, 4(13.3%) had fair & 3(10.0%) had poor results, our study showed that mean age of presentation was 37.87 years with male preponderance & involvement of dominant limb(right side), most common mode of injury was road traffic accident, analysis according to lauge Hansen classification were found to have supination external rotation injury in common, there were no intraoperative complications, But had poor outcomes due to the superficial skin infection which was treated appropriately.

**Interpretation and Conclusion:** Mechanism of injury is necessary for accurate reduction & further management. Fibular length has to be maintained, Anatomical reduction is essential in all intra articular fractures like ankle joint, where weight bearing is essential.

Open reduction and internal fixation Guarantees high standard of reduction besides eliminating the chances of loss of reduction. Chances of non- union of medial malleolus was reduced by preventing interposition of periosteum or any other soft tissue. Even after cast immobilization for 3-4 weeks the results are satisfactory due to the vigorous physiotherapy which was followed immediately after cast removal. Tension band principles was followed for osteoporotic & small fragment fractures.

**Keywords:** Malleolar fracture; ankle injury, Uni malleolar, bi malleolar, Trimalleolar, Lauge Hansen classification, Biard & Jackson Scoring

### Introduction

Sir Robert Jones said "ankle is the most harmed joint of the body however the least well treated <sup>[1]</sup>. Ankle injuries put on significant morbidity since body weight is transmitted through it and relies on the steadiness of this joint. They are normally blended injuries, ligamentous and bony and every injury is a final product of the arrangement of ligamentous and bony failure because of miss happening forces. ankle injuries is the most widely recognized weight bearing orthopedic musculoskeletal injury experienced in emergency medicine and practice <sup>[2]</sup>.

**Corresponding Author:**  
**Venkatesh V**  
Senior Resident, Department of  
Orthopaedics, ChamaraJanagar  
Institute of Medical Sciences,  
ChamaraJanagar, Karnataka,  
India

Ankle joint is highly congruous and any disturbance of the normal articular relationship may result in some progressive arthrosis of biomechanical dysfunction [2]. Stable fractures can be treated conservatively with good results although outcomes in the management of unstable ankle fractures are often better with surgical treatment.

The superiority of ORIF over closed treatment have been thoroughly demonstrated in literature [3]. When malleolar fractures are not reduced accurately they may lead to post traumatic painful restriction of motion or osteoarthritis or both [2]. Lateral malleolar fractures in the setting of a competent deep deltoid ligament can usually be treated non-operative with good results. In contrast, a lateral malleolar fracture with an incompetent deep deltoid ligament is clinically equivalent to a bimalleolar ankle fracture and may result in talar subluxation and degenerative arthritis when treated non-operative [4].

The reason for this study is to survey the useful result and after effects of Careful surgical management of malleolar fractures. The treatment alternatives with ORIF procedure accessible for malleolar fractures, to achieve a reasonable anatomical arrangement and strength of lower leg joint, can prompt remunerating result for the patient and specialist.

### Aims & Objectives

- To study the functional outcomes and results of surgical management of malleolar fractures in adults.
- To know the complications in surgical management of malleolar fractures.

### Methodology

30 patients with fresh unimalleolar, Bimalleolar and trimalleolar fractures who attended Adichunchanagiri Institute of Medical Sciences, attached to Sri Adichunchanagiri Hospital and Research Centre, B.G. Nagara, between September 2016 – September 2018 were studied.

As soon as the patients were brought to the casualty a complete survey was done to rule out significant injuries. Then the patient's were subjected for radiographs, Both anteroposterior and lateral views of the ankle joints. On admission, Detailed history was taken relating to the age, sex, occupation, address, mode of injury Past and associated medical illness, patients general condition was assessed and then were put through a thorough clinical examination. In all these patients the following clinical signs were looked for.

### Inclusion criteria's

1. Age group: 18 - 60 years with lauge Hansen type
  - Supination Adduction
  - Supination external rotation
  - Pronation abduction
  - Pronation external rotation
2. Type III A gustilo Anderson & lower degrees of fractures

### Exclusion Criteria's

1. Open type IIIB & IIIC gustilo Anderson fractures
2. Pathological fractures
3. Malleolar fractures associated with Talus, Calcaneum & Pilon fractures.

Analgesics were administered and fractures were stabilized by below knee posterior pop slab to alleviate pain. Also antibiotics and tetanus toxoid were given as needed.

The fractures were classified based on Lauge-Hansens classification in adults.

Routine investigations like CBC, HIV, HBsAg, Urine routine, X rays –(Chest AP, ankle AP, lateral view). Follow up x rays done at regular intervals.

Patients were operated using various methods of fixation like: For medial malleolus – Malleolar screw, tension band wiring For lateral malleolus – 1/3<sup>rd</sup> tubular plate, rush pin, reconstruction plate.

Curvilinear approach taken over medial malleolus to avoid skin related complications & direct lateral approach taken over the lateral malleolus.

After open reduction fractures were reduced using various modalities of fixation as mentioned above & fracture fixed.

### Post-Operative management

Analgesics and Serratiopeptidase were given. Elevation of the affected limb was done.

x- rays antero posterior and lateral views were taken. Wounds were inspected on 2<sup>nd</sup>, 5<sup>th</sup> & 10<sup>th</sup> post op days, by approximately 12<sup>th</sup> day sutures were removed and send them on below knee POP cast.

Patients were asked to have non weight bearing walking with crutches for 6 weeks & to review once in 3 weeks.

### Follow up

Weight bearing was restricted for 4-6 weeks. If any condition and other factors prevented secure fixation, the fracture was protected for longer duration.

At 3 weeks the POP was removed. Clinical examination was done regarding tenderness and movement of ankle.

At 6 weeks x- ray of the ankle was taken both AP and lateral views and looked for signs of fracture union and then were advised partial weight bearing for further period of 6weeks with elastic crepe bandage application and elevation of the limb at night times and active movements of ankle joints.

Patients were allowed full weight bearing on the affected limb. Patients were followed up for 1, 2 and 6 months after discharge till the fracture united. All the patients were advised removal of implants after complete union after 1 year.

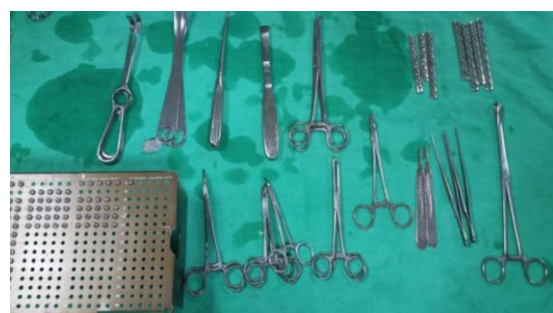### Functional and radiological evaluation

Functional and radiological results were analysed using the ankle scoring system of Biard and Jackson [5].

The seven categories in the scoring system were given alphabetical grades each being assigned a point score.

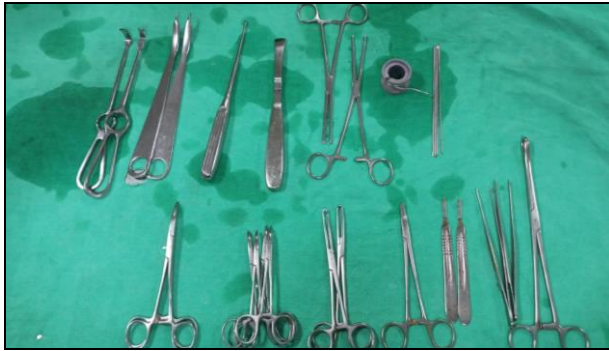Final scores were based on the combined point scores from seven categories of subjective objective and radiographic evaluation. Results were designated as excellent good fair and poor. A score of 96- 100 points was considered excellent; 91 to 95 good; 81- 90 points fair and zero to 80 points poor.

### Instruments



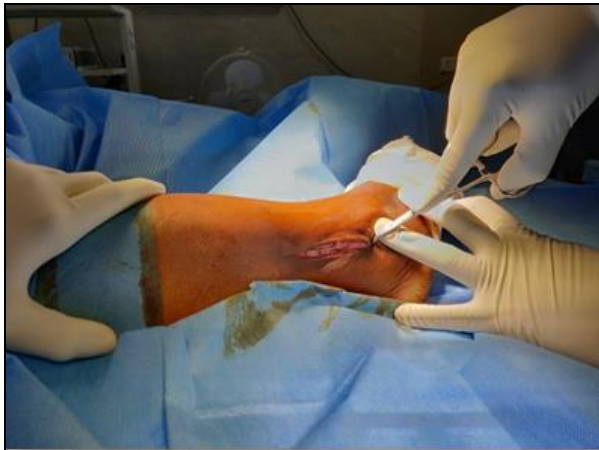**Fig 1:** Instruments for lateral malleoli fixation



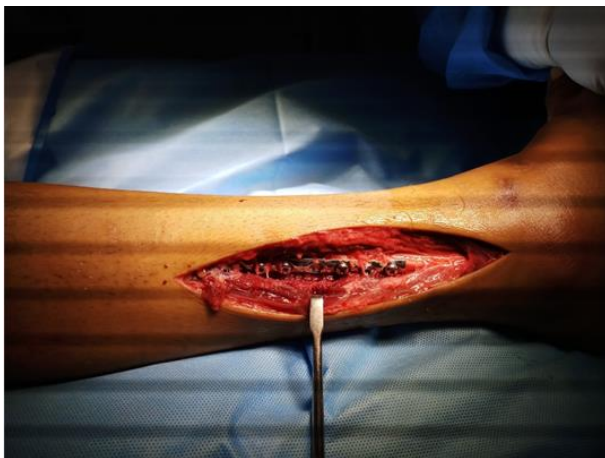

**Fig 2:** Instruments for fixation of medial malleoli

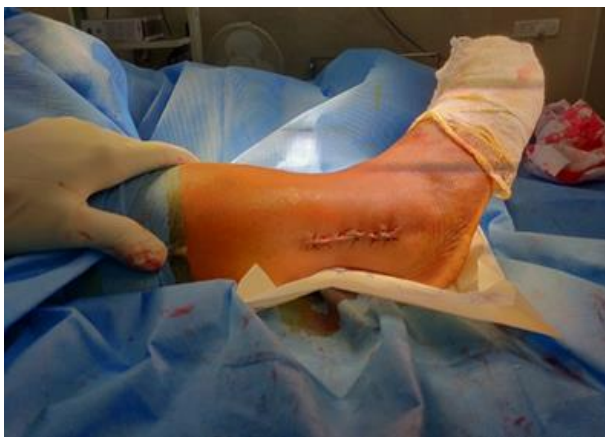#### Fixation of lateral malleoli



**Fig 3:** Incision for lateral malleoli

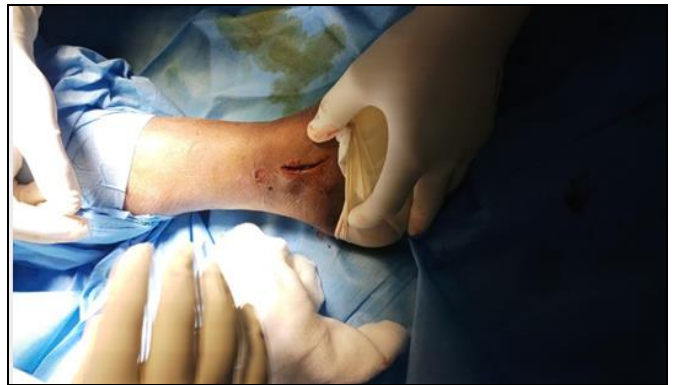

**Fig 4:** After fixation of fracture

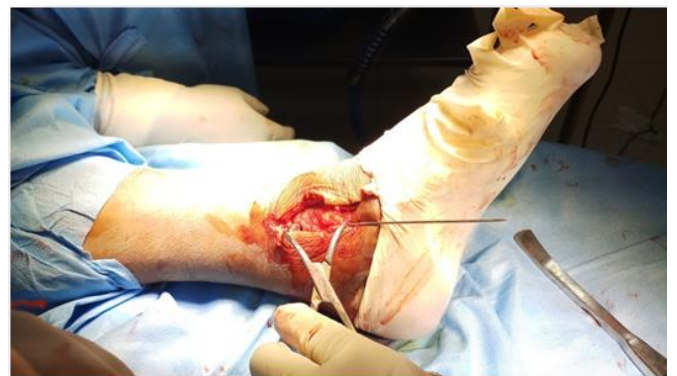

**Fig 5:** Closure of Skin

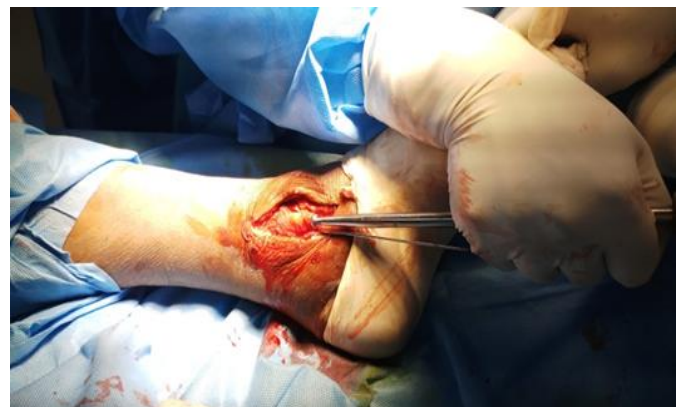#### Fixation of medial malleoli with malleolar screw



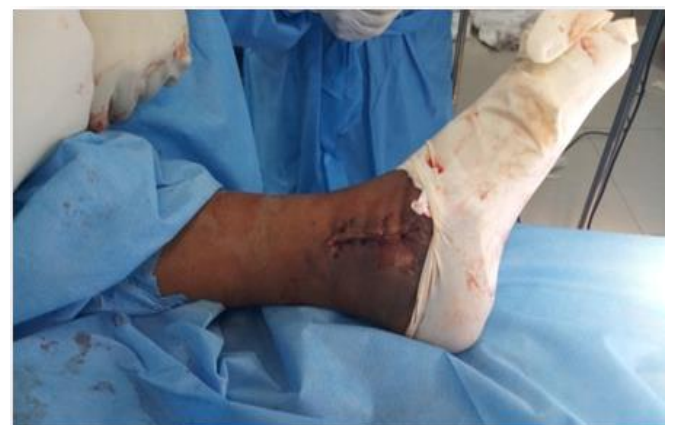**Fig 6:** Drapping & incision for medial malleolar fixation



**Fig 7:** Open reduction showing fracture site



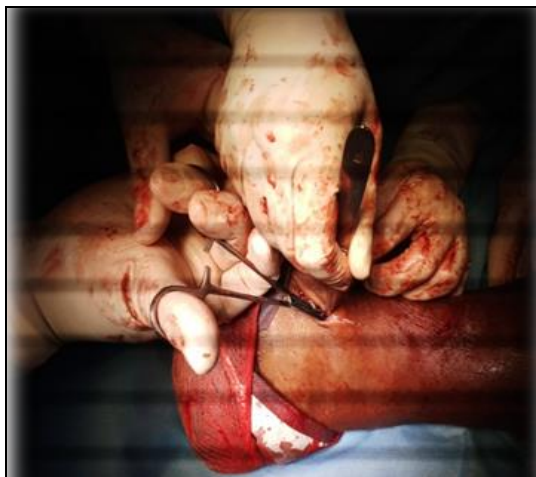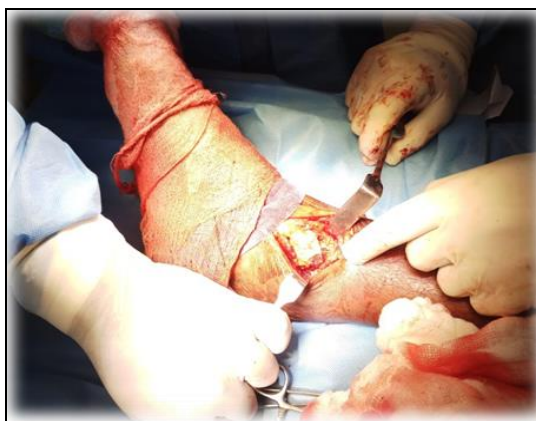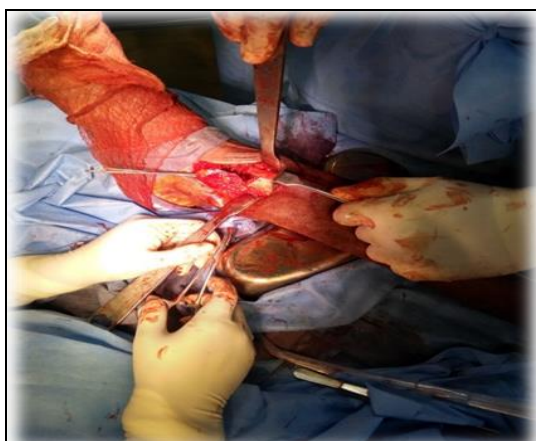
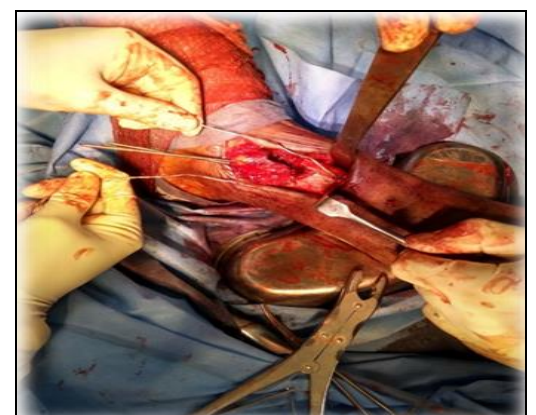
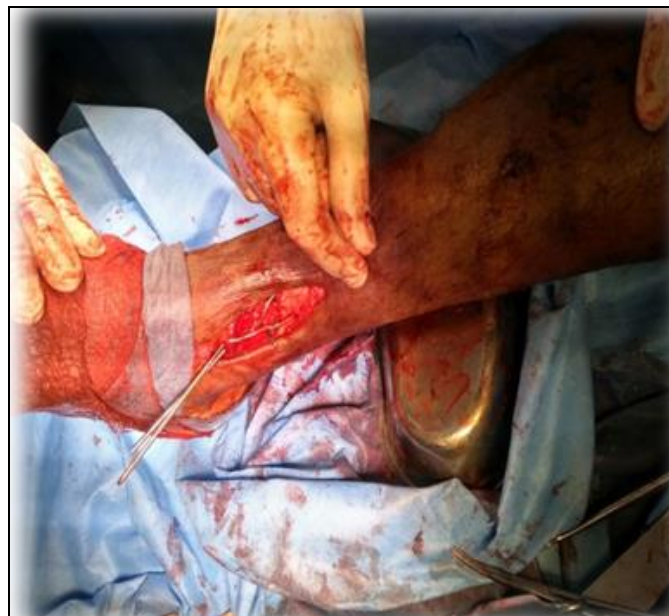**Fig 8:** Insertion of malleolar screw



**Fig 9:** Closure of the skin

#### Figure H: Fixation of medial malleoli with tension band wiring



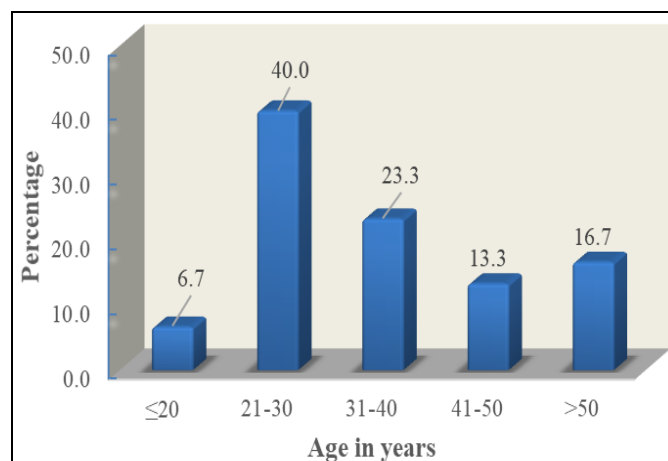
**Fig 10:** Deepening of incision**Fig 11:** Exposure of the fracture site**Fig 12:** Passing K- wires anterior & posteriorly**Fig 13:** Winding of ss wire**Fig 14:** SS wire in figure of eight

### Results

All the fractures were followed until fracture union was seen. Results were analyzed both clinically and radio graphically. Most of all fractures united at the end of 10 - 12 weeks.

**Table 1:** Age distribution

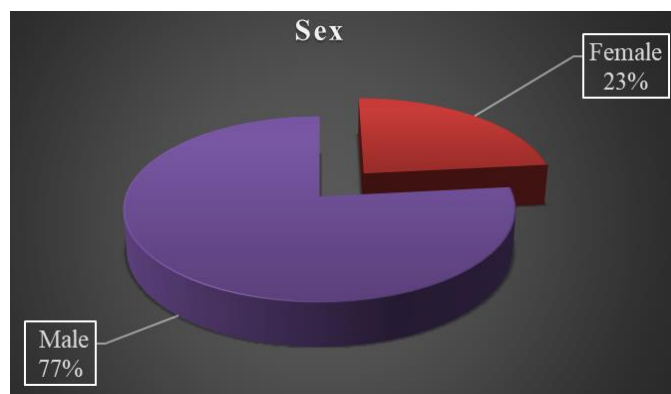
Age in Years	Frequency	Percent
≤20	2	6.7
21-30	12	40.0
31-40	7	23.3
41-50	4	13.3
>50	5	16.7
Total	30	100.0

**Graph 1:** Age distribution

Majority of the patients around 12 (40%) were between 21-30 years of age followed by 31-40 years age group. Mean age of presentation was 37.87 years. With a standard deviation of 13.970.

**Table 2:** Sex distribution

Sex	Frequency	Percent
Female	7	23.3
Male	23	76.7
Total	30	100.0

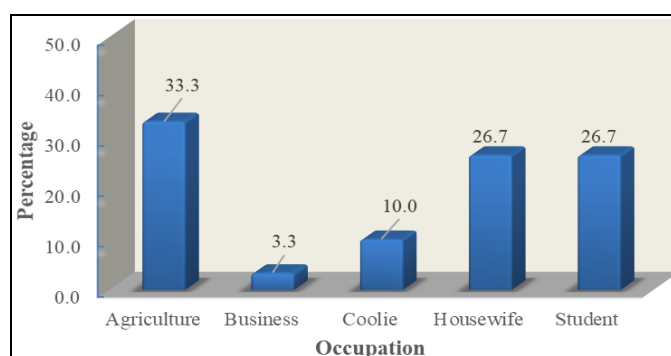


Graph 2: Sex Distribution

Majority of the patients were male 23(77%) & female were 7 (26.7%).

Table 3: Occupation

Occupation	Frequency	Percent
Agriculture	10	33.3
Business	1	3.3
Coolie	3	10.0
Housewife	8	26.7
Student	8	26.7
Total	30	100.0

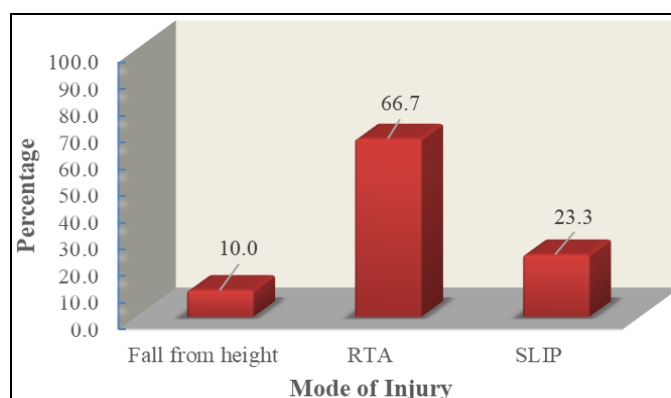


Graph 3: Occupation

Agriculture was the major occupation seen through this study approximately 10 (33.3%) followed by other occupations.

Table 4: Mode of injury

Mode of Injury	Frequency	Percent
Fall from height	3	10.0
RTA	20	66.7
SLIP	7	23.3
Total	30	100.0

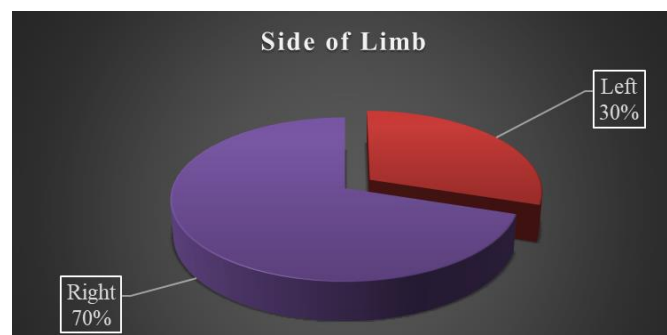

Graph 4: Mode of injury

The major cause of fracture in our study was road traffic accident in 20 (66.7%) and in 7(23.3%) due to slip and fall followed by 3(10.0%) due to fall from height.

Table 5: Side of fracture

Side of Limb	Frequency	Percent
Left	9	30.0
Right	21	70.0
Total	30	100.0

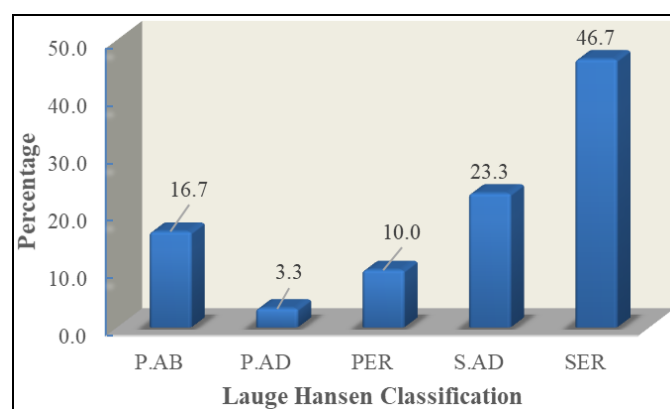


Graph 5: Side of fracture

Right ankle was involved in 21(70%) cases & remaining 9(30%) had involvement of left ankle.

Table 6: Type of fractures depending on Lauge Hansen classification

Lauge Hansen Classification	Frequency	Percent
P.AB	5	16.7
P.AD	1	3.3
PER	3	10.0
S.AD	7	23.3
SER	14	46.7
Total	30	100.0

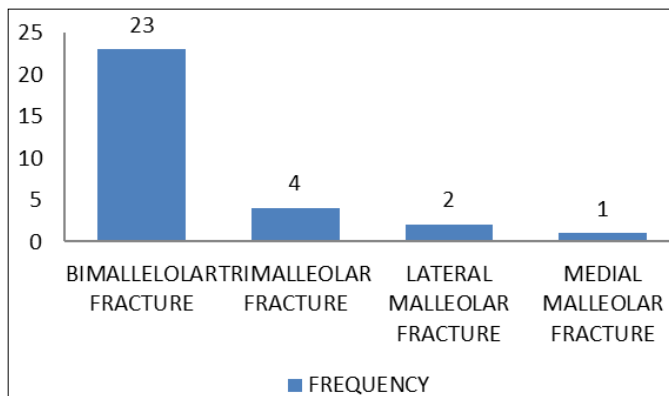


Graph 6: Type of fracture depending on Lauge Hansen classification

In the present study 14(46.7%) patients had supination external rotation injuries, followed by supination adduction injury of 7 (23.3%). 5(16.7%) had pronation abduction injury, 3 (10.0%) had pronation external rotation injury followed by least of pronation adduction 1 (3.3%) injury.

Table 7: Number of Malleoli involved

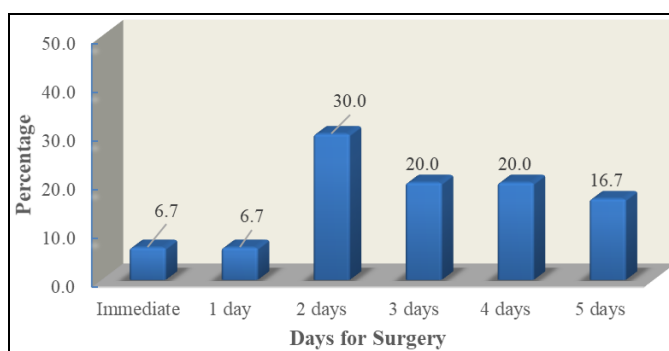
Diagnosis	Frequency	Percent
Bimalleolar fracture	23	76.7
Trimalleolar fracture	4	13.3
lateral malleolar fracture	2	6.7
medial malleolar fracture	1	3.3
Total	30	100.0

**Graph 7:** Number of malleoli involved

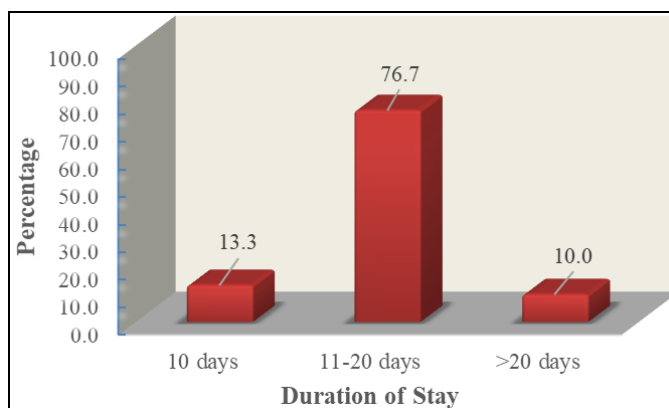
In the present majority of the patients had Bi-malleolar fractures followed by tri-malleolar & uni-malleolar (including isolated medial & lateral malleolar) fractures.

**Table 8:** Number of days for surgery

Days for Surgery	Frequency	Percent
Immediate	2	6.7
1 day	2	6.7
2 days	9	30.0
3 days	6	20.0
4 days	6	20.0
5 days	5	16.7
Total	30	100.0

**Graph 8:** Number of days for surgery**Table 9:** Duration of stay post surgery

Duration of Stay	Frequency	Percent
10 days	4	13.3
11-20 days	23	76.7
>20 days	3	10.0
Total	30	100.0

**Graph 9:** Duration of stay

### Statistics of surgery

Most patients were operated between 2 and 5 days. Average duration between trauma and surgery was 3 days in our series. All the patients were given spinal anaesthesia.

**Tourniquet:** Pneumatic tourniquet was used in all the cases.

**Duration of surgery:** Average duration of surgery was about 1 hour.

### Lateral malleolar fracture

There were total of 30 lateral malleolar fracture majority 23 (69%) were fixed with 1/3rd semitubular plate, 4 (12%) were fixed with Rush nail and remaining 3 (9%) were fixed with LCP/ Reconstruction plate.

### Medial malleoli fracture

In our series, there were 30 cases with medial malleolus fracture, tension band wiring was done in 12 (36%) and remaining 18 (6%) cases malleolar/ Lagscrews were used.

### Complications

Out of 30 patients 3 patients had complications like superficial skin infection with wound gapping which resolved by 10 -14 days of extended duration of stay, during the stay they were treated with appropriate antibiotics & regular dressings.

**Ankle Pain:** In this series 18 (60%) had no pain, 9(30%) had mild pain with strenuous activity, 2(6.6%) had mild pain with activities of daily living, and 1 (3.3%) had pain with weight bearing.

**Ankle stability:** In this series 24(80%) had no clinical instability of ankle, 6(20%) had clinical instability.

**Ability to walk:** Majority of the patients i.e; 17(8.6%) could walk desired distance without a limp, 11(36.6%) could walk desired distance with mild limp, 2 (6.6%) had moderately restricted in ability to walk

**Ability to run:** 15(50%) patients were able to run desired distance without pain, 12 (40%) were able to desired distance with slight pain and 3(10%) had Moderate restriction in ability to run with mild pain.

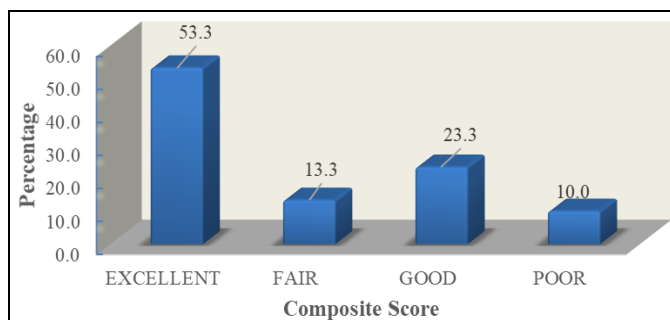
**Ability to work:** Nineteen (63.3%) were Able to perform usual occupation without restrictions, 10(33.3%) Able to perform usual occupation with restrictions in some strenuous activities, 1(3.3%) were Able to perform usual occupation with restrictions in some strenuous activities.

**Motion of ankle:** 25 (83.3%) had mobility Within 10° of uninjured ankle, 5(16.6%) had mobility Within 15° of uninjured ankle.

**Table 10:** Composite score

Composite Score	Frequency	Percent
Excellent	16	5.3
Good	7	23.3
Fair	4	13.3
Poor	3	10.0
Total	30	100.0





Graph 11: Composite score

In the present study out of 30 patients treated for Uni, Bi & Tri- malleolar fractures by open reduction & internal fixation. We found that 16(53.3%) had excellent results, 7(23.3%) had good results, 4 (13.3%) had fair results & 3 (10.0%) had poor results because of the superficial skin infection, Patients with fair results had pain with activity of daily living, had decreased ability to run/work, decreased ankle movements & on X rays had reduced joint space.

### Discussion

Increased knowledge about the normal and post traumatic anatomy and function of the ankle joint has led to demands for exact reduction and rigid fixation of the ankle fractures. Prompt operative treatment of displaced ankle fractures decreases morbidity and improves functional outcome [6].

The treatment of malleolar fractures with accurate open reduction and stable internal fixation using AO method and principles was found to give a high percentage of excellent and good results [6].

In fractures of the ankle only the minute variations from normalcy are Compatible with good function of the joint.

Treatment of malleolar fractures with accurate open reduction and internal fixation using AO principles was found to give good results. This study supports these conclusions.

The scoring of Baird and Jackson has proven to be strict allowing only very small fluctuation from normal about 5.3% patients in this series achieved excellent results by this scoring system and 23.3% patients achieved good results and had anatomical reduction of the lateral malleolus, medial malleolus as well as anatomical reduction of talus radiologically.

### Age distribution

Mean age of this study was 37.87 years. These finding was similar to observation of Baird and Jackson [5], Roberts RS [7] & Gregory Joy *et al.* [8].

Table 11: Age distribution

Studies	No of patients	Mean age [years]
Baird & Jackson [5]	24	30
Roberts RS [7]	25	40.0
Gregory joy <i>et al.</i> [8]	117	44.4
Zakir ali <i>et al.</i> [9]	40	37.4
Present study	30	37.87

Table 12: Sex Distribution

Studies	No of patients	Male to female	Percentage of males
Gregory joy <i>et al.</i> [8]	117	6: 63	46
Baird & Jackson [5]	24	17:7	70
Nabeel sham <i>et al.</i> [10]	21	13:8	62
Our study	30	23:7	76.7

Table 13: Comparison of mode of injury with other studies

Studies	Number of patients	Mode of injury
Baird & Jackson [5]	24	Fall From Height
Zakir ali <i>et al.</i> [9]	40	RTA
Lee <i>et al.</i> [11]	168	RTA
Our study	30	RTA

Table 14: Side affected in various studies

Studies	No of patients	Right	Left
Roberts RS [7]	25	14	11
Baird & Jackson [5]	24	11	13
Beris, <i>et al.</i> [3]	144	73	71
Zakir ali <i>et al.</i> [9]	40	25	15
Our Study	30	21	9

### Type of injury depending on Lauge Hansen classification

In the present study Lauge Hansens classification system was used for operative evaluation. The most common type of injury was pronation external rotation (35%) and supination external rotation (35%) and least common was pronation dorsiflexion. This finding was in contrast to observation of Roberts RS [7], Baird and Jackson [5], Beris *et al.* [3].

Table 15: Type of Injury in Various Studies as Determined by Lauge Hansens Classification

Studies	No of patients	Most common injury	Percentage
Baird and Jackson [5]	24	Supination external rotation	44.0%
Beris, <i>et al.</i> [3]	144	Supination external rotation	
Burwell and Chornney [12]	135	Supination external rotation	46.0%
Zakir ali <i>et al.</i> [9]	40	Supination external rotation	37.5%
Our study	30	Supination external rotation	46.7%

### In the present study the fractures that influence the results are

1. Anatomical reduction is the most important factor for a good outcome.
2. Type of fracture, severity of injury is inversely proportional to the final results obtained.
3. The importance to the injury to the posterior malleolus was attended when it showed more than 25% involvement of the distal tibial articular surface, and hence was also taken as an indication for the fixation of the posterior malleoli.
4. Cast immobilization for 4 weeks did not diminish the ankle motion after removal, although reduced initially but after the cast removal the ankle movements rapidly improved. The rapid gaining of motion from 4 to 10 weeks may be due to the intensive physiotherapy for range of movement and resumption of weight bearing at 6-8 weeks.

Malleolar fractures has a wide variety of presentation. Bimalleolar fractures in general have a less favorable outcome compared to isolated malleoli fracture. They have a varied presentation from isolated unimalleolar to trimalleolar fracture with dislocations & vascular complications. Thorough understanding of the mechanism of injury patho anatomy and treatment options with accurate reduction and early mobilization can give excellent results.

**Table 16:** Final results of this study compared with other studies

Studies	Good to excellent	Fair	Poor
Burwell &Charnley <sup>[12]</sup>	102(77.3%)	22(16.7%)	8(6%)
Beris <i>et al.</i> <sup>[3]</sup>	105(74.3%)	21(14.6%)	16(11.1%)
Desouza <i>et al.</i> <sup>[13]</sup>	135(90%)	9(6%)	6(4%)
Frank Wilson <i>et al.</i> <sup>[14]</sup>	42(77%)	12(21%)	1(2%)
Zakir ali <i>et al.</i> <sup>[9]</sup>	33(82.5%)	5(12.5%)	2(5%)
Our study	23(76.6%)	4(13.3%)	3(10.0%)

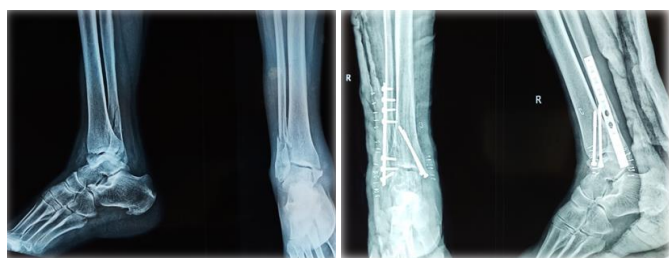### Conclusion

In this review of 30 patients with ankle fractures that were unstable, displaced or both, which were treated surgically by Open reduction and internal fixation in accordance with AO principles.

1. The most common pattern of fracture in our study is supination external rotation
2. The most common mode of injury is Road traffic accident
3. Male are more predisposed
4. Mechanism of injury is necessary for accurate reduction & further management
5. Fibular length has to be maintained
6. Anatomical reduction is essential in all intra articular fractures like ankle joint, where weight bearing is essential. Open reduction and internal fixation Guarantees high standard of reduction besides eliminating the chances of loss of reduction.
7. Chances of non- union of medial malleolus was reduced by preventing interposition of periosteum or any other soft tissue
8. 85-90% of the results are satisfactory
9. Even after cast immobilization for 3-4 weeks the results are satisfactory due to the vigorous physiotherapy which was followed immediately after cast removal.
10. Tension band principles were followed for osteoporotic & small fragment fractures.

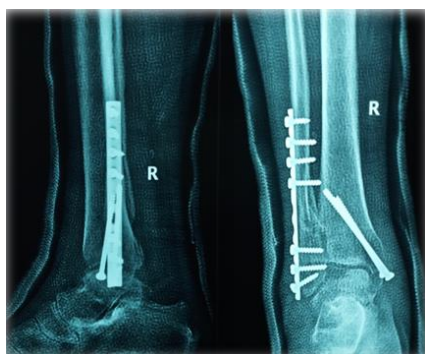### Radiographs & clinical pictures

#### CASE 1: Excellent

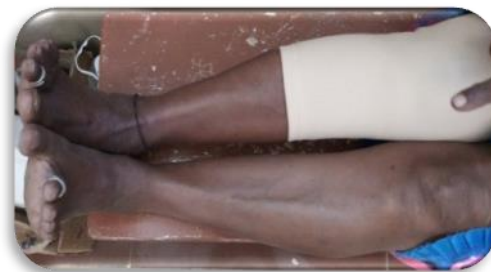

PRE OP

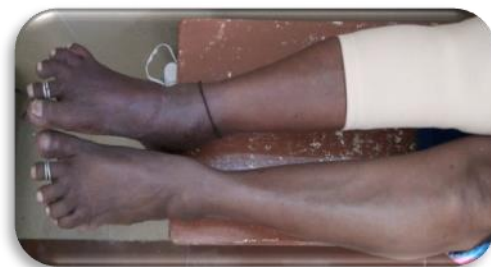POST OP



6 weeks follow up

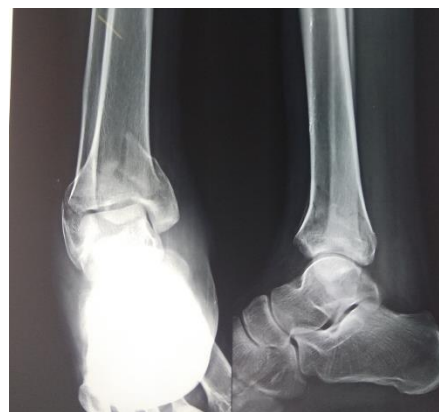

Dorsiflexion

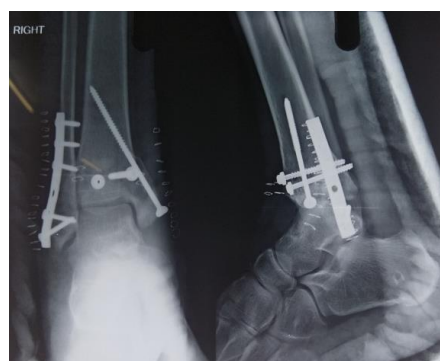

Plantar Flexion

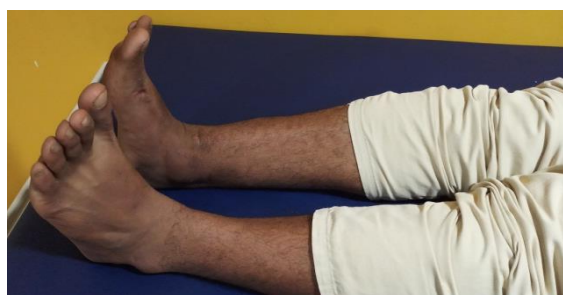#### Case No 2: Excellent



PRE OP

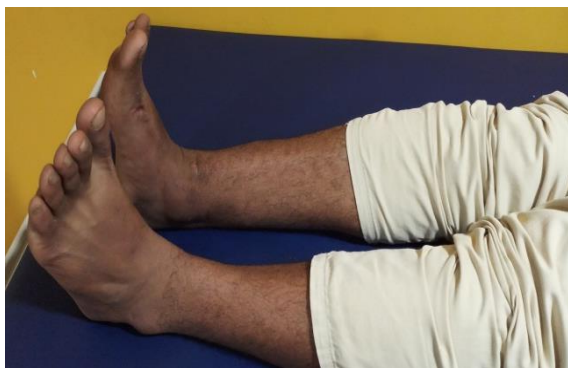

POST OP

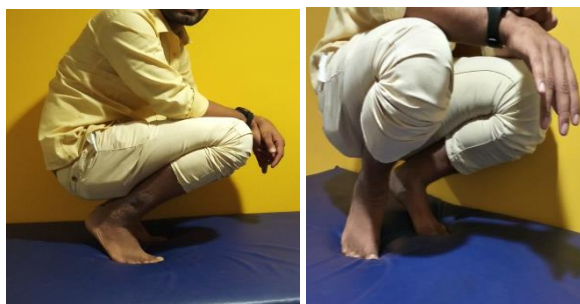

Dorsiflexion



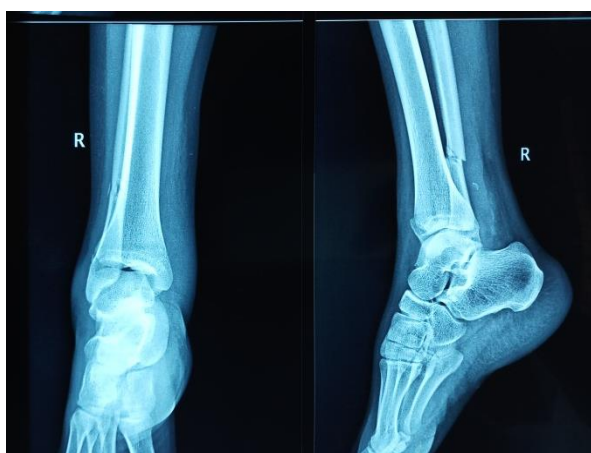

Plantar flexion

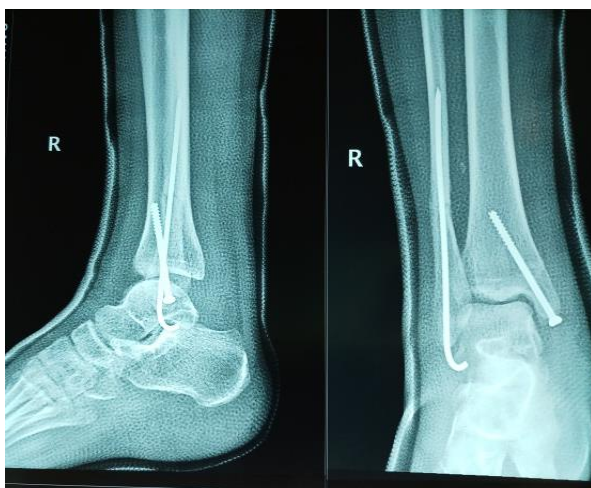


Squatting

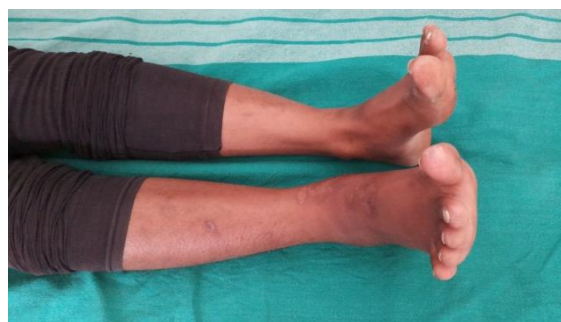### CASE 3: Excellent



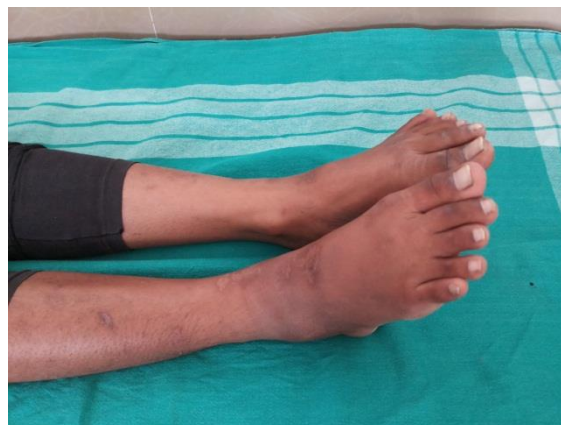PRE OP



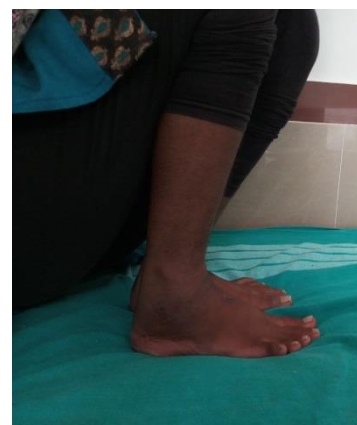POST OP



Dorsi flexion



Plantar Flexion



Squatting

**Conflict of interest: NIL**

### References

1. Shelton Mar vin L. Complication of fractures and dislocation of the ankle. In: Complications in Orthopaedic surgery, Chapter 23, 3rd Edn, edt. EPPS, Charles H, Philadelphia: J.B. Lippincott Company, 1994, 595-648.
2. Harold W Voguer, Wary B Bauer. McGlamny's comprehensive textbook of footand ankle surgery. 3rd ed. Chapter, 1897, 59.
3. Beris AE, Kabbani KT, Xenakis TA, Mitsionis G, Soucacos PK, Soucacos PN. Surgical treatment of malleolar fractures – a review of 144 patients. Clin Orthop Related Research. 1997; 341:90-98.
4. Michelson J. Fractures about the ankle. The Journal of Bone & Joint Surgery. 1995; 77(1):142-152.
5. Baird RA, Jackson ST. Fracture of the distal part of fibula with associated disruption of the deltoid ligament. J Bone Joint Surg. 1987; 69A:1346-52.

6. Shekhar D. Outcome of Surgical Management of Bimalleolar Fractures - our Experience. IOSR Journal of Dental and Medical Sciences. 2017; 16(03):34-37.
7. Roberts RS. Surgical treatment of displaced ankle fractures. Clin Ortop, 1983; 172:164-170.
8. Joy G, Patzakis M, Harvey J. Precise Evaluation of the Reduction of Severe Ankle Fractures. The Journal of Bone & Joint Surgery. 1974; 8(5):979-993.
9. Zakir Ali Shah, Uzmaarif. 'Surgical management of bimalleolar fractures of ankle' P J M H S. 2013; 7(2):471-3.
10. Nabeel Shams, ImthiazAhmed, Athmananda Hegde. 'A study on surgical treatment of ankle fractures- A clinical study of 21 cases' IJBAR, 2014, 05(04).
11. Lee Y, Huang C, Chen C, Lin C. Operative Treatment of Displaced Lateral Malleolar Fractures. Journal of Orthopaedic Trauma. 2005; 19(3):192-197.
12. Burwell S, Charnley AD. Treatment of displaced fractures at the ankle by rigid internal fixation and early joint movement. JBJS. 1965; 47B:634-60.
13. Desouza LJ. Fractures and dislocations about the ankle. In: Fractures and dislocations, Chapter- 30, edt. Gustilo RB, Kyle RF, Templeman D, St, Louis: Mosby Year book Inc. 1993 2:997-1043.
14. Frank C Wilson, Arne Skilbred. Long term results in the treatment of displaced bimalleolar fractures. JBJS. 1966; 48:1065-78.