



International Journal of Orthopaedics Sciences

E-ISSN: 2395-1958
P-ISSN: 2706-6630
IJOS 2020; 6(2): 24-26
© 2020 IJOS
www.orthopaper.com
Received: 13-02-2020
Accepted: 15-03-2020

Dr. Uma Anand KP
Assistant Professor of
Orthopaedics, Department of
Orthopaedic Surgery, Sri
Manakkula Vinayagar Medical
College and Hospital,
Puducherry, India

Dr. Justin Moses
Associate Professor, Department
of Orthopaedic Surgery, Sri
Manakkula Vinayagar Medical
College and Hospital,
Puducherry, India

Mathematical analysis of femoral version controversies in MRI and axial oblique CT measurement

Dr. Uma Anand KP and Dr. Justin Moses

DOI: <https://doi.org/10.22271/ortho.2020.v6.i2a.2012>

Abstract

Background: Femoral version is the amount of twist the proximal femur has undergone in relation to the distal femur. Recently axial oblique CT and MRI measurement of version have been described. Oblique sections are taken along the axis of femoral neck and anteversion is calculated from a single slice. Does this obliquely measured angle “oblique version” represent the true version? The aim of this study is to analyze the geometry of femoral version and to establish the relationship between “oblique version” and “true version”.

Methods: Mathematical analysis of the geometry of femoral version was done and the relation between oblique version and true version was established. Formulae have been devised to correct for errors due to rotation. Oblique version and true version of 50 dry femora was measured and analysed.

Results: Significant difference was found between oblique version and true version ($p=0.02$). Using the formulae we were able to calculate the true version from oblique version and vice-versa with an error of $\pm 1^\circ$. Graphs have been made to illustrate how oblique version is related to true version at different neck-shaft angles.

Conclusion: “Oblique version” measured in MRI and axial oblique CT doesnot correspond to the “true version”. It is a function of neck shaft angle and true version. Even though accurate and simple they may give spuriously wrong results. Four formulae have been elucidated for conversion of oblique version to true version and to correct for rotation.

Clinical Relevance: Abnormalities in the amount of version have been linked to various orthopaedic disorders. Earlier methods have estimated true anteversion only and pre-operative planning and intra-operative decisions in derotational osteotomy and arthroplasties are based on true version only. Therefore it is recommended that only true version is used and the formulae can be used for conversion.

Keywords: Mathematical analysis, controversies, MRI, CT

Introduction

Femoral version or torsion is the amount of twist the proximal femur has undergone in relation to the distal femur. This is one of the areas in orthopaedics that has been extensively studied and published. A clear idea about the anatomy of femoral version is essential for orthopaedic surgeons for diagnosis as well as treatment of many musculoskeletal conditions. Abnormalities in the amount of version have been linked to various orthopaedic disorders like in-toeing and out-toeing gait in children, perthe’s disease, slipped capital femoral epiphysis, developmental dysplasia of hip, hip impingement, osteoarthritis of hip etc... Also calculation of anteversion is of paramount importance in planning for derotational osteotomy of proximal femur and for hip arthroplasty.

Recently axial oblique CT ^[1] and oblique MRI ^[2] methods for measuring femoral version have been described. The accuracy, intra-observer and interobserver reliability has been reported to be comparable or better than conventional methods. Also it has been mentioned that anteversion measured by this method was consistently lower than that measured transversely. Though accurate and reliable, the angle measured doesnot represent the true version of the neck in the transverse plane, instead it is a measure of deviation of neck axis in a oblique plane, determined by the neck-shaft angle. Also Toogood *et al.*, have reported measuring femoral anteversion in femur specimens by taking photographs of the lateral profile of the neck by abducting the shaft ^[3].

Corresponding Author:
Dr. Justin Moses
Associate Professor, Department
of Orthopaedic Surgery, Sri
Manakkula Vinayagar Medical
College and Hospital,
Puducherry, India

Does this obliquely measured angle (herein called “oblique version or oblique anteversion” for the sake of simplicity) correspond to the true version?

Methods

Comparison of Oblique Version and True Version

A total of 50 adult femora obtained from the anatomy department were used in the study. Femurs with significant abnormalities in the proximal portion were excluded. The femur was placed on a flat rectangular table so that it rested on both the posterior condyles and the greater trochanter, with the long axis parallel to the lateral edge of the table. The following were measured,

1. Acute neck-shaft angle or 180° minus the neck-shaft angle (d) - measured with a goniometer
2. True anteversion (a) – measured by a method similar to that described by Toogood *et al.* [3]. The femur was placed in its anatomical position and a digital photograph was taken with the camera lens in line with the axis of the shaft and at the level of the surface of the table. The image was then processed using GIMP 2.6 open source software and the anteversion was measured (figure-1).
3. Oblique anteversion (b) – measured by the method of Toogood *et al.* The femur was abducted till the axis of neck was parallel to the front edge of the table and a digital photograph was taken and processed.

Results

A total of 50 femurs were used for the study. The mean true version was 11.235°, Range: -12° to 37°. 5(10%) femurs were retroverted. 3(6%) were in neutral version. 32(64%) were in the range 1° to 20° of anteversion. 10(20%) femurs showed anteversion more than 20°. The mean oblique version was 7.25°, range -9.2 to 26.57°, 39(78%) were in the range 1° to 20° and only 3(6%) had >20° anteversion.

Paired t-test was used for comparison. Results show that a statistically significant difference exists between oblique and true anteversion values (p<0.001).

Relation between “Oblique Version” and “True Version”/ Neck-Shaft Angle

Using trigonometric methods the following formulae were derived.

$$\sin b = \sin a \times \sin d \quad \text{----- (Formula-1)}$$

Where, a = true version
 b = oblique version
 d = acute neck shaft angle (180°–neck shaft angle)

In MRI/Axial oblique CT the true neck shaft angle is not used, instead the angle projected in the antero-posterior view is used for taking oblique slices of femoral neck. Therefore the relationship between true and oblique version is given by the formula,

$$\tan b = \tan a \times \sin c \quad \text{----- (Formula-2)}$$

(c = acute angle between neck and shaft as seen in antero-posterior projections of femur or the angle at which oblique cuts are made for MRI/CT measurement of anteversion.)

The above equation can be used to measure true anteversion from oblique version provided the femur is in neutral rotation. If the neck shaft angle is 90°, then oblique anteversion and true anteversion are equal and has a linear relationship to the amount of rotation. But in normal femora the neck-shaft angle

is more than 90°, therefore during internal or external rotation the head and neck inscribe a cone (figure-3) with the apex at the base of the neck and opening angle equal to the acute neck-shaft angle. Therefore, even if a femur is rotated by 90°, the oblique anteversion would never be more than the acute neck-shaft angle. Hence subtracting amount of rotation from the measured angle would give a spuriously wrong idea of the amount of true anteversion.

Relationship between Oblique Anteversion and Rotation

$$\sin b = (\sin a \times \sin e) / (\sin (a+x)) \quad \text{---- (Formula-3)}$$

where, a = true anteversion
 b = oblique anteversion
 e = measured oblique anteversion at x rotation or at bicondylar angle = x degrees the value of (a+x) can be calculated from formula (2) by substituting, “a+x” for “a” and “e” for “b”.

$$\tan e = \tan (a+x) \times \sin c \Rightarrow \tan (a+x) = \tan e / \sin c \quad \text{-- (Formula-4)}$$

where, c is the acute neck-shaft angle in the scout view at x degrees of rotation.

Discussion

Measurement of oblique anteversion has no relevance to clinical practice; it is the true anteversion that is important. Only true anteversion is measured intra-operatively as a guide for positioning the stem of a total hip prosthesis. Recently there have been reports of measuring this oblique angle [1-5]. Advantages quoted are the simplicity as the complete profile of the neck can be seen in a single slice, accuracy, intra and inter-observer reliability. But this measurement cannot be used for pre-operative planning because oblique anteversion, a combination of true anteversion and neck shaft angle, underestimates the amount of true anteversion. Also the oblique anteversion doesnot maintain a linear relationship with true anteversion. The relationship between true and oblique anteversion at various acute neck shaft angles is shown in the graph (figure-4). The ellipse represents the clinically important zone.

Finally compensating for rotation by subtracting the bicondylar angle from the measured oblique anteversion yields grossly erroneous results (sometimes a normal femur may be classified as retroverted if the leg is in full external rotation).

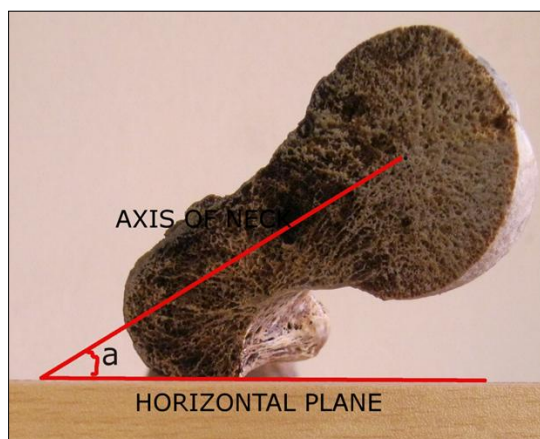


Fig 1: Axial photograph of femur for measurement of true anteversion (a=true anteversion).

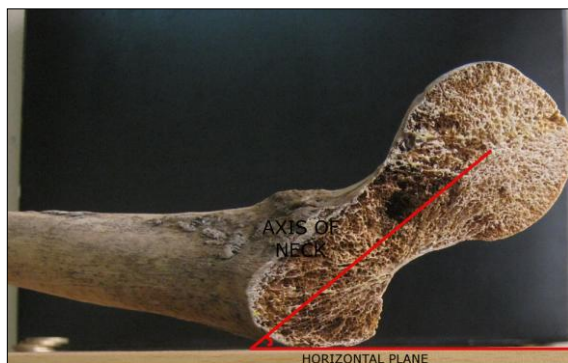


Fig 2: Photograph of lateral aspect of neck for measurement of oblique version (b=oblique version).

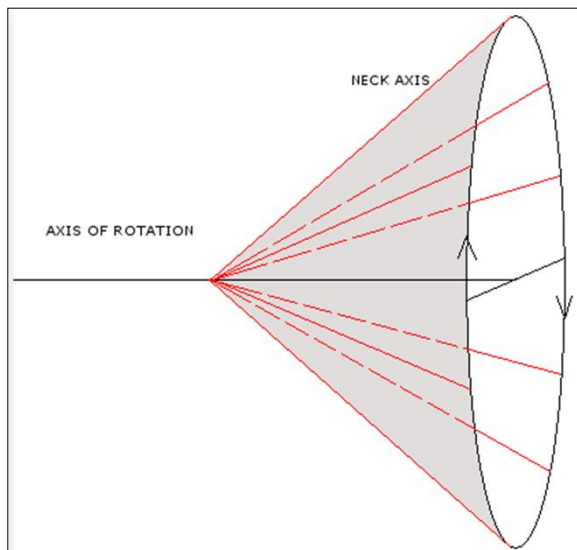


Fig 3: line diagram showing the conical path of neck axis (red lines) during rotation.

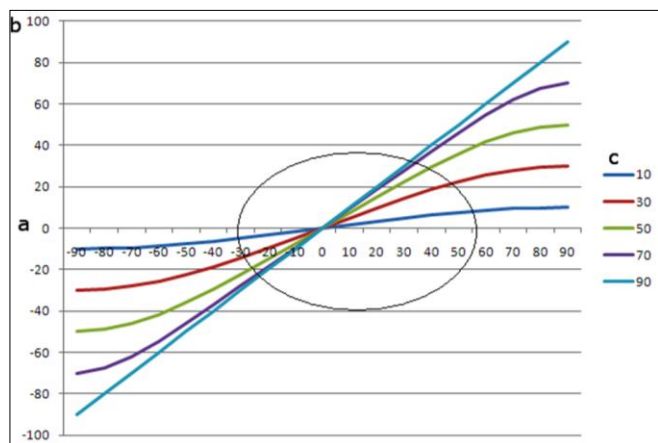


Fig 4: Graph showing relationship between true version and oblique version (colored lines) at different neck shaft angles (X-axis: true version; Y-axis: oblique version).

3. $\sin b = (\sin a \times \sin e) / (\sin (a+x))$
4. $\tan (a+x) = \tan e / \sin c$

(a = true anteversion; b = Oblique anteversion; c = projected acute neck-shaft angle in antero-posterior view / angle at which oblique slices are taken for MRI measurement; d = acute neck-shaft angle (or) 180°- neck shaft angle; e = measured oblique anteversion at x degrees of external rotation; x = amount of external rotation)

References

1. Delma Jarrett Y, Amy Oliveira M, Kelly Zou H, Brian Snyder D, Paul Kleinman K. Axial Oblique Ct To Assess Femoral Anteversion – Ajr, 2010, 194.
2. Reinhard Tomczak J *et al.* Mr Imaging Measurement of The Femoral Antetorsional Angle As A New Technique: Comparison With Ct In Children And Adults.
3. Paul A, Toogood BS, Anthony Skalak MD, Daniel R, Cooperman MD. Proximal Femoral Anatomy in the Normal Human Population - Clin Orthop Relat Res. 2009; 467:876-885.
4. Benjamin Domb G, Itamar Botser B, George Ozoude C. Comparison of CT and MRI Evaluation of Femoral Neck Version to Each Other and Hip Joint Motion <http://aana.omnibooksonline.com/2011/data/papers/e35.pdf>
5. Shital Parikh, Frank Noyes R. Patellofemoral Disorders Role of Computed Tomography and Magnetic Resonance Imaging in Defining Abnormal Rotational Lower Limb Alignment-Sports Health: A Multidisciplinary Approach. 2011; 3(2):158-169.

Conclusion

Only true anteversion is clinically relevant as it correctly represents the amount of twist or torsion of femur. Therefore it is recommended that true anteversion alone is used for diagnosis, management, for pre-operative planning and follow up. If oblique anteversion is preferred for some reason then the following simple trigonometric relations can be used for calculating true anteversion.

1. $\sin b = \sin a \times \sin d$
2. $\tan b = \tan a \times \sin c$