



E-ISSN: 2395-1958
P-ISSN: 2706-6630
IJOS 2020; 6(1): 1371-1376
© 2020 IJOS
www.orthopaper.com
Received: 17-10-2019
Accepted: 25-12-2019

Dr. Gopi HG
Senior Resident, Department of
Orthopaedics, Mysore Medical
College, Mysore, Karnataka,
India

Dr. Arjun A
Senior Resident, Department of
Orthopaedics, Mysore Medical
College, Karnataka, Mysore
India

Dr. Male Gowda P
IMO, ESI Hospital, Mysore,
Karnataka, India

Corresponding Author:
Dr. Arjun A
Senior Resident, Department of
Orthopaedics, Mysore Medical
College, Karnataka, Mysore
India

A randomised comparative study of platelet rich plasma versus corticosteroid in the management of plantar fasciitis

Dr. Gopi HG, Dr. Arjun A and Dr. Male Gowda P

DOI: <https://doi.org/10.22271/ortho.2020.v6.i1r.3187>

Abstract

Plantar fascia by repetitive overuse or over stretching gets inflamed resulting in plantar fasciitis. In plantar fasciitis, inflammation and degeneration go hand in hand. This is one of the commonest chronic tendinopathies affecting humans. It typically affects both men and women in the age group of 40-70 years, predominantly in women. 100 patients selected for the study with 50 patients in each group. The patients were selected according to our criteria and diagnosis made on clinical examination alone. The pain status was assessed with VAS, RM score and AOFAS scoring system. The patients were followed up at 2th, 4th, 12th and 24th weeks. Post-injection pain and activity level noted. The statistical result for PRP group in mean VAS significantly decreased from 7.53 to 3.12, at six months follow up, RMS 3.26 to 1.47, and AOFAS 29.79 to 72.49. For Steroid group the VAS decreased from 7.39 to 4.23; RMS 3.12 to 2.02; AOFAS 31.30 to 59.09. PRP group showed 46% excellent, 36% very good and 18% poor outcome, Steroid group 22% excellent, 26% very good and 52% poor result. We concluded that in plantar fasciitis, intralesional PRP injection gives better pain relief and faster return to daily activities compared to Corticosteroid injection.

Keywords: Plantar fasciitis, intralesional injection, platelet rich plasma, corticosteroid, heel spur, visual analogue scale, RM score and AOFA score

Introduction

Plantar fascia by repetitive overuse or overstretching gets inflamed resulting in a condition called as plantar fasciitis. In plantar fasciitis, inflammation and degeneration go hand in hand. This is one of the commonest chronic tendinopathies affecting humans. It typically affects both men and women in the age group of 40-70 years predominantly in women. It occurs in 10% of the general population and is bilateral in 33% of case^[1].

The clinical application of platelet-rich plasma (PRP) and other regenerative therapies in sports, spine, and musculoskeletal medicine has soared in the last decade. Over this period, many factors have converged to fuel this development. Advances in scientific understanding of tendinopathy as a degenerative cellular and connective tissue process; lack of long-term efficacy of steroid injection therapies, which has prompted the need for alternative therapies; limited studies of comparative significance between PRP and steroid, advances in musculoskeletal ultrasound to facilitate diagnosis and guide interventions; as well as translation of treatment paradigms from colleagues from orthopedics and surgery have all contributed to the advancement of this regenerative field^[2].

PRP therapy has gained popularity in regenerative medicine and other specialties since the earliest reports of its clinical use in the 1980s and 1990s, with applications traced to the fields of cardiac, dental, and maxillofacial surgery. In cardiac surgery, PRP was shown to be an effective autologous source for transfusion to address surgical blood loss and hematologic derangements from cardiopulmonary bypass. In dentistry, Anitua demonstrated application of PRP to tooth extraction sites facilitated bone regeneration in these sockets with compact mature bone that had normal morphology. In maxillofacial surgery, Marx and colleagues evaluated the effect of PRP on bone maturation rate and bone density in bone graft reconstructions of mandibular continuity defects, demonstrating that addition of PRP to grafts resulted in increased bone formation^[3].

Today in musculoskeletal and sports medicine PRP therapy has become highly attractive for its potential benefit and influence on repairing injured tissue, treating a wide range of degenerative disorders, and accelerating return to sport, finding its role as an injectable biologic used to augment healing of tendon, ligament, muscle, and cartilage^[4].

This article provides the latest clinically relevant information on the basic science of PRP and practical considerations for its use, evidence for PRP and steroid use in musculoskeletal medicine, recommendations for PRP preparation and steroid, the patient selection, as well as suggested post procedure rehabilitation and return to sport protocols. The authors will identify the limitations in current knowledge of this regenerative therapy and recommend critical areas for future research.

Methodology

Inclusion criteria

The patients included in our study are between 18-60 years old, have pain and tenderness centered on the medial tubercle of the calcaneum on weight bearing after rest which resolved either partly or fully after activity, Patient using orthoses, insoles, pads were also included in our study.

Exclusion criteria

1. Those who received local steroid Injection within last 6 months, non-steroidal anti-inflammatory therapy within one week prior to therapy.
2. Who are having significant cardiovascular disease, renal or hepatic disease, local malignancy and anemia
3. Those who have undergone previous surgery for plantar fasciitis.
4. Patients who are having diabetes, vascular insufficiency or neuropathy.

Patients Selection

This was a prospective study of 100 cases of clinically diagnosed plantar fasciitis treated with single dose intralesional injection of PRP and steroid (50 cases each) during the period.

Between the above-mentioned period, 100 cases of plantar fasciitis who met the above criteria entered the study. There were 37 males and 63 females with a mean age of 42.18/49.08 years. Range was age 18 to 60 years.

Methods

100 patients with chronic plantar fasciitis who had failed extensive traditional non - operative treatment were randomized into 2 groups for prospective treatment and evaluation group 1 was treated with freshly prepared

autologous PRP, group 2 was injected 40 mg 1 ml of Methylprednisolone (Depomedrol, Pfizer).

All patients gave informed consent for the study and the study was approved by the institutional ethical committee (KIMS).

All patients were screened with plain x ray of ankle joint lateral view and with basic investigation like Hemoglobin, Random blood sugar, Lipid profile and Renal Profile to the inclusion criteria.

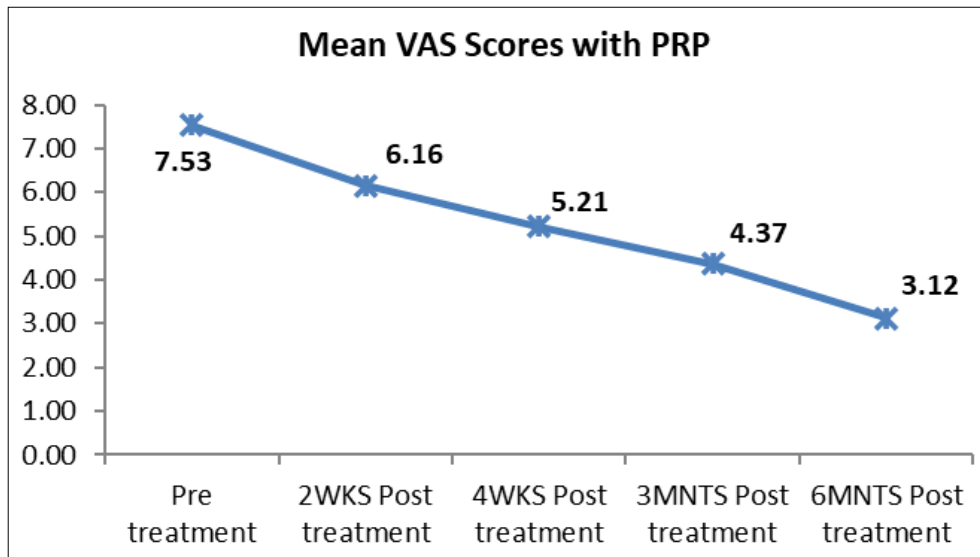
In this study, 18 cc venous blood sample was obtained from cubital vein of the patient and mixed with 2cc of anticoagulant Acid citrate dextrose solution (ACD), to prevent clotting of the sample and to prevent platelet activation prior to its use. Here used double spin method, soft and hard spin. This sample was then centrifuged at 1500 rpm for 12 minutes using a soft spin technique to minimize mechanical damage to the platelets. And the upper layer and intermediate layer with few RBCs are transferred to sterile container then the hard spin centrifuge done at 3000 rpm for 10 min. the platelet poor plasma was discarded the lower one third plasma and platelet pellets was taken and transferred to injection syringe with 18-gauge needle. it is about 2.5 to 3cc PRP ready for use. This PRP is unbuffered and unactivated. With the patient lying in a supine position, the injury zone was peppered in both groups using 2% chlorhexidine gluconate 70% isopropyl alcohol and then a local anaesthetic field block was performed by the same individual in all cases using a 23-gauge needle with a total of 6 cc of 0.5% w/v Bupivacaine. The block was placed medially with 2 cc of 0.5% Bupivacaine injected into the skin, 2 cc into the fascial tissue, and 2 cc into the periosteum of the medial calcaneal tubercle.

Following aseptic preparation of the skin, injection given either with PRP obtained from preparation with said procedure or with Depo Medrol obtained from pharmacy infiltrated into the lesion, later patients were placed into a Walker brace, CAM boot or MCR footwear for 2 weeks and allowed to return to activities as tolerated along with a daily home eccentric exercise and calf stretching regimen in both the groups.

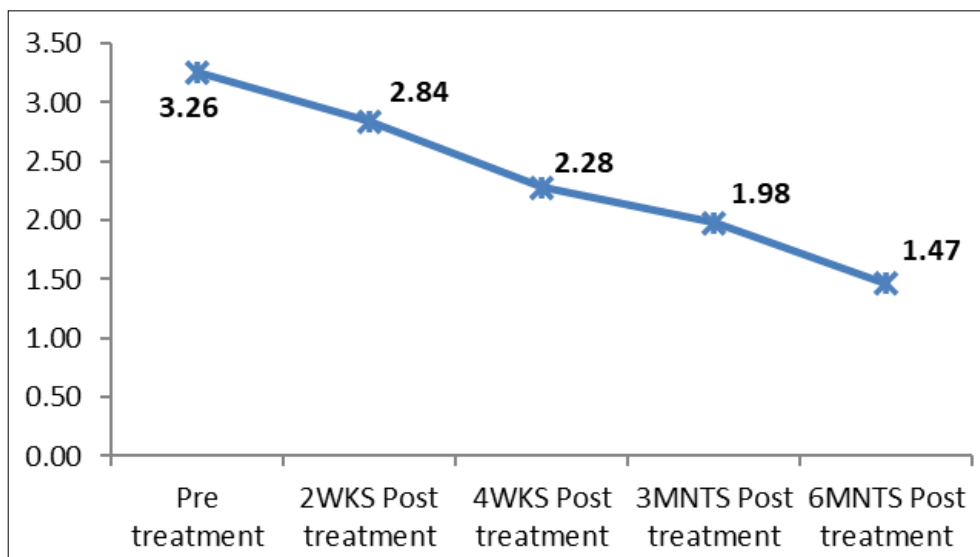
Nonsteroidal anti-inflammatory drugs use was not permitted during the first 2 weeks after treatment and was discouraged throughout the entire study period in particularly with PRP group. No other treatment modalities were used during the study except exercises and footwear.

Interval AOFAS hindfoot scoring data, VAS and RM scoring done and physical examinations were conducted with clinical symptoms and pain status assessed and compared with pre injection status. Pre and post injection status assessed. periodically at 2ndweek, 4thweek,12thweek, and 24thweek after treatment with said scores.

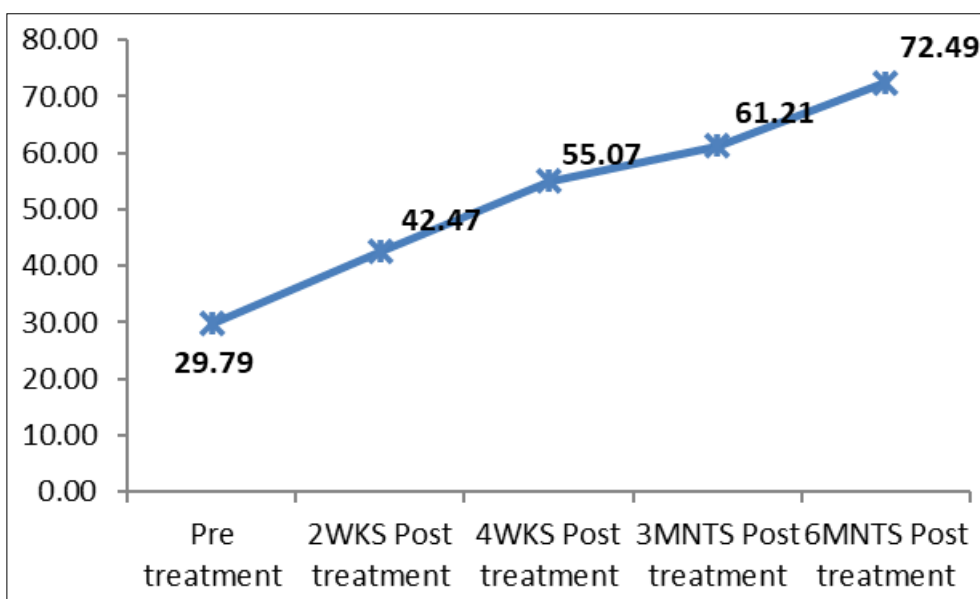
Results



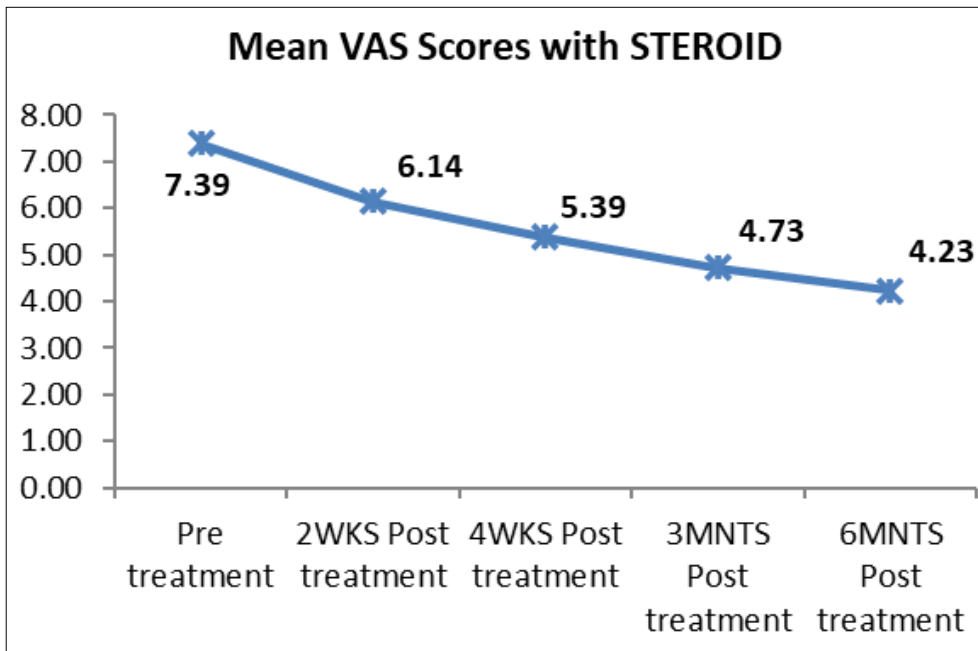
Graph 1: Clinical assessment done by visual analogy scale pre and post injection status with PRP. Score decreased from 7.53 before injection to 3.12 at the end of 6 months.



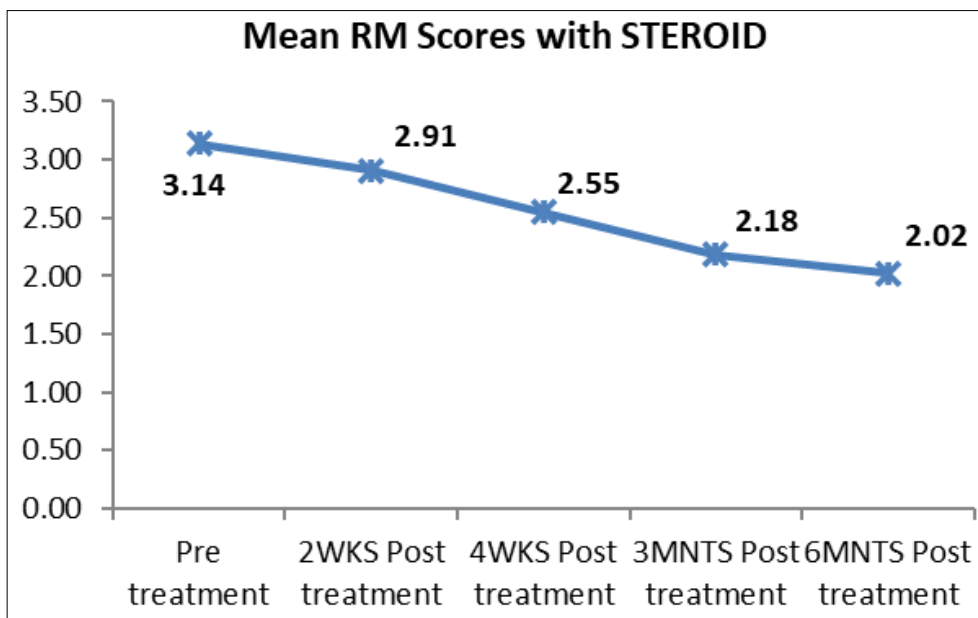
Graph 2: Descending graph with PRP the RMS score 3.26 to 1.47.



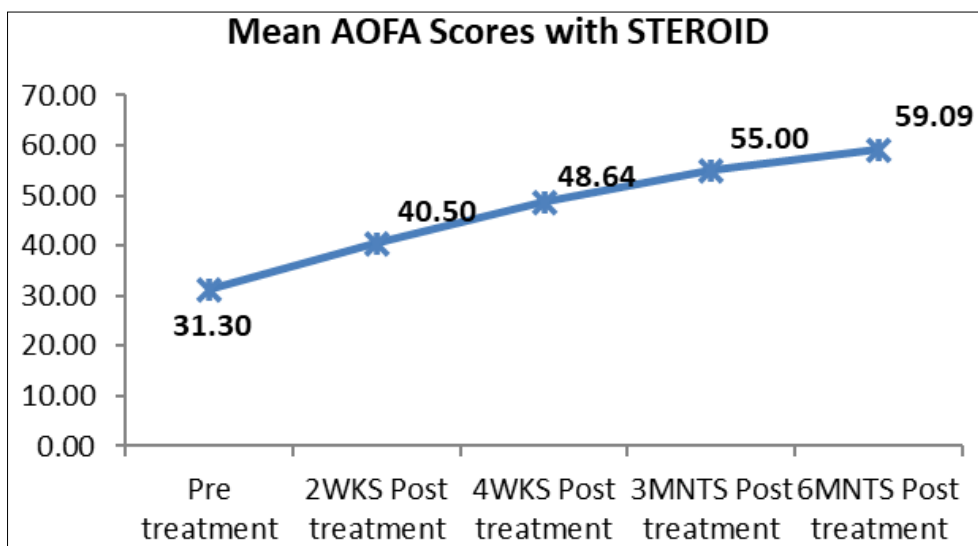
Graph 3: Mean AOFA score with PRP.



Graph 4: Mean VAS score decreased from 7.39 to 4, 23 with steroid.



Graph 5: Descending score of RMS with steroid from 3.14 to 2.02.



Graph 6: Ascending graph with steroid the AOFAS is 31.30 to 59.09.

Table 1: Comparison of Mean VAS Scores between PRP & STEROID groups at different follow up:

VAS	Intervention	N	Mean	Std. Deviation	Mean Difference	T	p value
Pre	PRP	50	7.53	1.85	0.16	0.465	0.643
	STEROID	50	7.37	1.63			
2 Wks	PRP	50	6.18	1.75	0.05	0.16	0.873
	STEROID	50	6.12	1.62			
4 Wks	PRP	50	5.20	1.58	-0.11	-0.343	0.733
	STEROID	50	5.31	1.64			
3 Mnts	PRP	50	4.35	1.45	-0.32	-0.994	0.323
	STEROID	50	4.67	1.67			
6 Mnts	PRP	50	3.12	1.71	-1.11	-2.785	0.007 (Sig.)
	Steroid	50	4.23	2.00			

Table 2: Comparison of Mean RM Scores between PRP & STEROID groups. Mean RM score PRP vs Steroid:

RM Score	Intervention	N	Mean	Std. Deviation	Mean Difference	student score	p value
PRE	PRP	50	3.25	0.80	0.09	0.565	0.573
	STEROID	50	3.16	0.83			
2WKS	PRP	50	2.84	0.70	-0.08	-0.559	0.578
	STEROID	50	2.92	0.64			
4WKS	PRP	50	2.27	0.60	-0.26	-2.3	0.024(Sig.)
	STEROID	50	2.53	0.50			
3MNTS	PRP	50	1.94	0.66	-0.24	-1.816	0.073
	STEROID	50	2.18	0.61			
6MNTS	PRP	50	1.47	0.67	-0.56	-3.402	0.001 (Sig.)
	STEROID	50	2.02	0.85			

Table 3: Comparison of Mean AOFAS Scores between PRP & STEROID groups at different follow up and shows significance 4 weeks onwards.

AOFAS	Intervention	N	Mean	Std. Deviation	Mean Difference	T	p value
PRE	PRP	50	29.76	12.67	-1.60	-0.714	0.477
	STEROID	50	31.37	9.47			
2WKS	PRP	50	42.59	12.98	1.91	0.835	0.406
	STEROID	50	40.67	9.64			
4WKS	PRP	50	55.88	11.17	7.03	3.269	0.001 (Sig.)
	STEROID	50	48.86	10.27			
3MNTS	PRP	50	62.14	12.41	7.14	2.829	0.006 (Sig.)
	STEROID	50	55.00	11.88			
6MNTS	PRP	50	72.49	16.68	13.40	3.712	<0.005 (Sig.)
	STEROID	50	59.09	16.98			

Discussion

Plantar fasciitis literally means inflammation of the plantar fascia at the site of its attachment to the calcaneum. But recent studies indicate that it is a condition of degeneration of the plantar fascia rather than true inflammation. Dr. Barrett in 2004 suggested that it is really a degeneration of the plantar fascia and called it better as plantar fasciosis. It was also supported by the findings of pathologists that only very few inflammatory cells were found in specimens received from cases of chronic plantar fasciitis. The pathology passes through a cascade of events including inflammation and degeneration.

True inflammation is found only in acute cases and in chronic stages inflammation and degeneration exists together with degeneration dominating the other. This is alike other chronic tendinopathies wherein the features of loss of collagen continuity, increase in ground substance, vascularity and fibroblasts predominate the lesion. Several treatment methods exist for chronic plantar fasciitis which are broadly classified into conservative and invasive.

Initially treatment is begun with a combination of conservative methods including rest, ice pack application, Non-steroidal anti-inflammatory drugs, and footwear modifications including arch supports. Usually, multiple sessions of the modalities like ultrasound waves, electrical stimulation, phonophoresis may be required before resolution of the condition can occur. When it is not responsive to the

above conservative treatment options, local intra-lesional injections or surgical plantar fascial release can be considered. Local intra-lesional injections of corticosteroids, Botulinum toxin, Autologous blood and Platelet rich plasma can be tried. Several studies indicate the advantage/disadvantage of one treatment option over the other.

The successful use of PRP formulations to treat chronic tendinopathies led to its application in treating severe cases of plantar fasciitis,

Lopez-Gavito *et al.* (2011) [5] surveyed a small group of patients with a minimum of 12 months of severe chronic plantar fasciitis and/or Achilles tendinosis and noted AOFAS hindfoot score improvement from 39 to 97 by a month and average Visual Analogue Scale (VAS) pain scores dropping from 9 to 2 after PRP treatment. No control group was provided in this investigation.

In another small, non-blinded preliminary study without a control group, Martinelli *et al.* (2013) [6] used 3 weekly injections for chronic plantar fasciitis and noted average VAS scores decreased from 7.1 to 2.1 after 12 months with excellent final results in 9 patients, good results in 4, and poor in 1.

Ragab and Othman (2012) [7] followed a group of 25 patients with chronic plantar fasciitis treated with PRP without a control group for an average of 10.3 months and documented VAS score improvement from 9.1 to 1.6 [7] Prior to treatment 72% of their patients noted severe activity limitations, while

28% were moderately limited, but after PRP treatment 92% had little or no noticeable limitations. Ultrasonography demonstrated decreased plantar fascial thickening after PRP treatment but no control group was provided in that study.

Barrett and Erredge^[8] reported in 2004 that complete resolution of symptoms at 1 year in approximately 78% of subjects with plantar fasciitis treated with PRP. However, the study was limited by a small sample size and lack of a control group. Larger-scale randomized controlled studies are needed to help elucidate PRP as a viable treatment of this common musculoskeletal injury.

In the only controlled study comparing PRP and cortisone treatment of chronic plantar fasciitis, Akashin *et al.* (2012)^[9] prospectively examined 60 patients who had failed 3 months of conservative care. The patients were treated in 2 nonrandomized consecutive groups of 30 with either 40 mg methylprednisolone or 3 cc of PRP and then followed for 6 months post treatment. Mean VAS scores improved from 6.2 to 3.2 in the steroid group and 7.33 to 3.93 in the PRP group after 6 months.

In Kawshik Jain *et al.*,^[10] studying 2015 that the crucial result for this series of analyses concerns the interaction between treatment group (PRP vs Steroid) and time point. Whilst this was not significant for the comparisons between pre-treatment and the 3 month or 6 month time points for any of the outcome measures, at 12 months, the interaction was significant on all three measures. For the RM F (1, 58) = 6.584, P = .013, partial eta squared = .102; for the VAS F (1, 58) = 5.105, P = .028, partial eta squared = .603; and for the AOFAS F (1, 58) = 4.776, P = .033, partial eta squared = .076. Thus, both PRP and Steroid are effective in the early treatment of plantar fasciitis, with no significant difference in early outcome at 3 and 6 months post injection, but at 12 months post injection, the PRP group had clearly advantageous scores compared to the Steroid group in all three outcome measures but our study time limited for six months, here consistent results with PRP obtained in six months compared to steroids.

Shetty *et al.* (2009)^[11] compared short term results (3 months) of Steroid vs. PRP in 60 patients (30 in each arm). They found that result of PRP were significantly better than that of steroid. The AOFAS, VAS and Foot and Ankle Disability Index were all significantly better in the PRP group at 3 months. However, their results were preliminary, and there was no data available on results beyond the 3 months stage^[12]. These results comparable with our study.

Conclusion

In conclusion, this is the study to demonstrate that platelet rich plasma can provide successful longer-term treatment of severe chronic plantar fasciitis in patients who have failed to respond to traditional non operative management techniques. The use of PRP in these difficult situations seems far more efficacious than the traditional treatment of cortisone injection and appears safer than surgical alternatives. PRP is significantly more effective than Steroid, making it better and more durable than cortisone injection as a treatment option. Unlike steroids its effect does not wear off with time.

References

1. Priscilla Tu. Do, Heel Pain: Diagnosis and Management, Virginia Tech Carilion School of Medicine and Research Institute, Roanoke, Virginia. Am Fam Physician. 2018 Jan 15;97(2):86-93.
2. Medline plus Medical Encyclopedia: Plantar fasciitis:

Anatomy of fascia, Fasciosis, causes, Biomechanism, pathology, Clinical features, Diagnosis, Differential diagnosis and Treatment options.

3. Wikipedia the free Encyclopedia: Plantar fascia: Anatomy of plantar fascia structure, muscles arteries and nerves.
4. Andrew McMillan M, Karl Landorf B, Mark Gilheany F, Adam Bird R, Adam D. Ultrasound guided injection of dexamethasone versus placebo for treatment of plantar fasciitis: protocol for a randomised controlled trial. Journal of Foot and Ankle Research. 2010;3:15.
5. Lopez-Gavito E, *et al.* Platelet-rich plasma for managing calcaneus tendon tendinopathy and plantar fasciitis. Acta Ortop Mex. 2011;25:380-385.
6. Martinelli N, Marinozzi A, Carni S, *et al.* Platelet-rich plasma injections for chronic plantar fasciitis. Int Orthop. 2013;37:839-842.
7. Ragab EM, Othman AM. Platelet rich plasma for treatment of chronic plantar fasciitis. Arch Orthop Trauma Surg. 2012;132:1065-1070.
8. Barrett SL, Erredge SE. Growth factors for chronic plantar fasciitis. Podiatry Today. 2004;17:37e42.
9. Akashin E, Dogruyol D, Yuksel HY, *et al.* The comparison of the effect of corticosteroids and platelet-rich plasma (PRP) for the treatment of plantar fasciitis. Arch Orthop Trauma Surg. 2012;132:781-785.
10. Kowshik Jaina, *et al.* Platelet rich plasma versus corticosteroid injection for plantar fasciitis: Cloughaa Wrightington Hospital, UK, <http://dx.doi.org/10.1016/j.foot.2015.08.006> 0958-2592/© 2015.
11. Shetty VD, Dhillo. A study to compare the efficacy of corticosteroid therapy with platelet-rich plasma therapy in recalcitrant plantar fasciitis: a preliminary report. Foot Ankle Surg. 2014;20(1):10-3.
12. Say F, Gürler D. Inkaya E, Bülbül M; Acta Orthop Traumatol Turc. 2014;48(6):667-72.