



E-ISSN: 2395-1958
P-ISSN: 2706-6630
IJOS 2020; 6(1): 1296-1299
© 2020 IJOS
www.orthopaper.com
Received: 07-11-2019
Accepted: 09-12-2019

Vikash Agarwala
Assistant Professor, Department
of Orthopaedics, Silchar Medical
College and Hospital, Silchar,
Assam, India

Arun Kumar Sipani
Professor & Head of the
Department, of Orthopaedics,
Silchar Medical College and
Hospital, Silchar, Assam, India

Lebu Sarkar
Postgraduate Trainee,
Department of Orthopaedics,
Silchar Medical College and
Hospital, Silchar, Assam, India

Lebu Sarkar
Postgraduate Trainee,
Department of Orthopaedics,
Silchar Medical College and
Hospital, Silchar, Assam, India

A clinical study on management of medial compartment knee osteoarthritis by proximal fibular osteotomy

Vikash Agarwala, Arun Kumar Sipani and Lebu Sarkar

DOI: <https://doi.org/10.22271/ortho.2020.v6.i1r.2000>

Abstract

Background: Knee osteoarthritis (OA) is a cause of considerable pain and disability in the affected individuals. Proximal Fibular Osteotomy is a straightforward and comparatively new surgery that results in pain relief and maintenance of joint space in osteoarthritis. It is a day care procedure that helps in realigning the knee joint and may result in delay of knee replacement by a decade or in some cases even longer.

Materials and Methods: 20 adult patients (25 knees) with medial compartment knee osteoarthritis admitted in Silchar Medical College and Hospital (SMCH) and treated with Proximal Fibular Osteotomy between June 2018 to May 2019 were included. Preoperative and postoperative weight bearing radiographs are taken to evaluate the medial joint space. Visual Analogue Score and American Knee Society Score were used to assess knee pain and knee ambulation activities, respectively.

Results: It was observed that all patients experienced pain relief following proximal fibular osteotomy. Weight bearing lower extremity radiographs showed an average increase in the postoperative medial joint space. Additionally, correction of lower limb alignment was observed in eight patients.

Conclusion: Proximal Fibular Osteotomy is a simple, cost effective procedure which significantly reduces knee pain and improves joint function in medial compartment knee osteoarthritis.

Keywords: Medial compartment osteoarthritis, proximal fibular osteotomy, medial joint space, visual analogue score, American knee society score

1. Introduction

Knee osteoarthritis (OA) is a persistent progressive degenerative disease with associated joint pain, stiffness, and deformity in the elderly population. In patients with idiopathic osteoarthritis, weight bearing antero-posterior radiograph of knee joint shows narrowed medial joint space and mechanical femoro-tibial axis of less than 180 degrees ^[1]. The medial compartment bears 60-80% of the load which is generally distributed along the mechanical axis ^[2]. A Proximal Fibular Osteotomy which decreases the loading force on the medial compartment osteoarthritis of the knee joint may help in such situations. It may also result in better alignment of lower limbs, improved range of motion [ROM] of knee, and lesser pain early on.

2. Materials and Methods

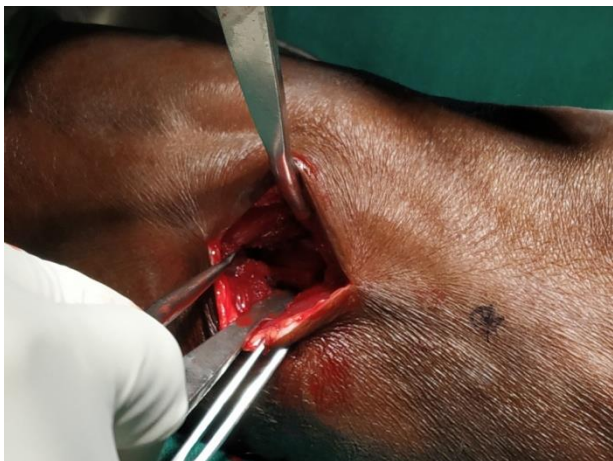This study was approved by the institutional ethical committee. All participants gave written informed consent to participate in this study.

2.1. Study Population

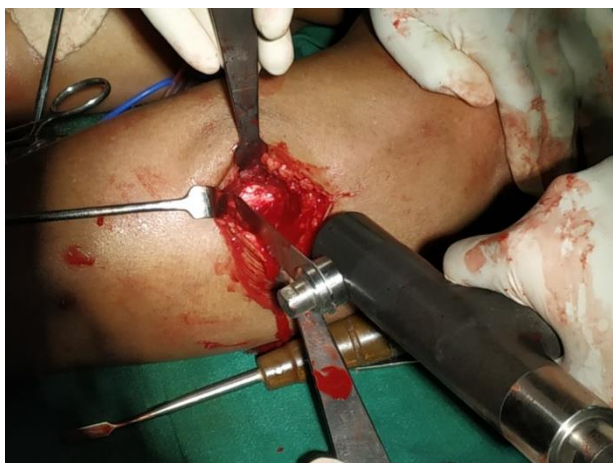This prospective study was carried out from June 2018 to May 2019 on patients with moderate to severe symptomatic medial compartment OA of the knee with difficulty in walking and genu varus deformity of the knee, attending OPD of Department of Orthopaedics, SMCH. The patients were diagnosed with knee osteoarthritis by American College of Rheumatology criteria³ and severity of disease was graded by Kellgren and Lawrence grading system ^[4]. Patients with post traumatic knee OA, inflammatory joint disease, patients with a history of previous operations or fractures of knee joint, local infection, septic and tubercular arthritis and genu valgus deformity of the knee were excluded from the study.

2.2. Surgical procedure

The patient was put in supine position after administration of spinal anaesthesia. At first, fibular head was marked and a point marked at 5 cm distance from the head of the fibula. A 4 cm longitudinal skin incision made over lateral aspect of the proximal fibula and the fibula was exposed between the peroneus muscle and soleus muscle. Proximal Fibular Osteotomy was performed by removing a 2-3 cm section of fibula. After resection, the wound was irrigated with large volume of normal saline and the muscle, fascia and skin were sutured one by one. Full weight bearing and free mobilization was allowed post operatively as soon as pain was tolerable.



A. Exposure of fibula between peroneus and soleus 5cm distal from the head of fibula



B. Osteotomy done with the help of Oscillating Saw

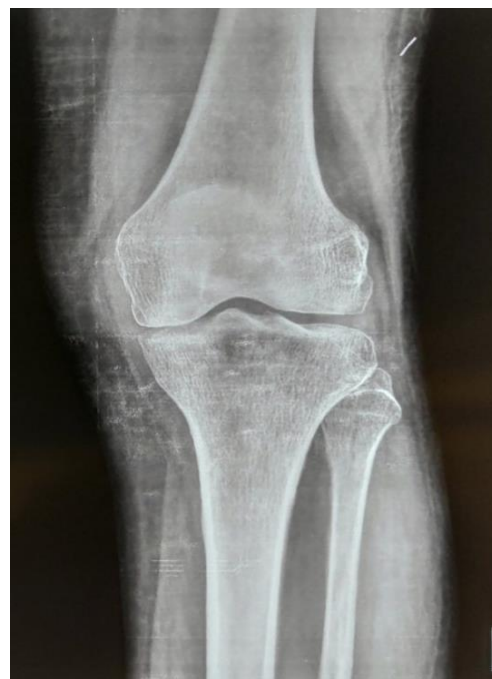Fig 1: Surgical approach of Proximal Fibular Osteotomy

Follow up was done after 1, 3 6 and 9 months postoperatively. The severity of knee pain was assessed using a visual analogue scale (VAS) [5]. The Knee Society Score (KSS) was used to assess knee ambulation activities [6]. Knee joint with full leg standing weight bearing X-ray in antero-posterior view was used to measure the medial and lateral joint space of knee joint and femoro-tibial angle for whole lower limb alignment measurement.

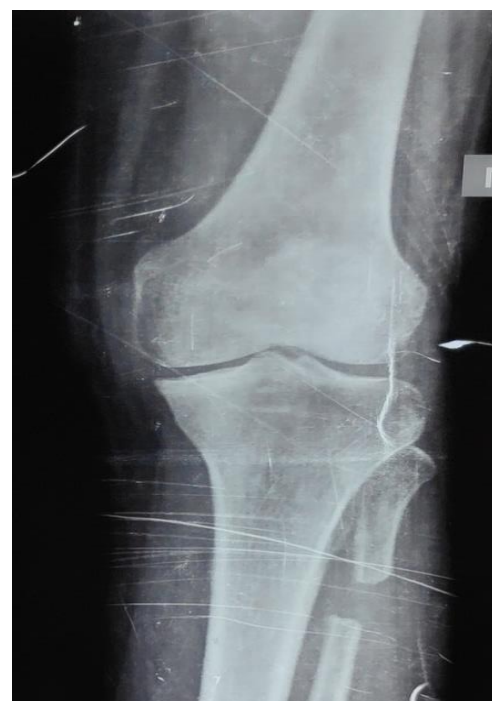3. Results

The study was conducted among 20 patients and 25 knees, as there were 5 bilateral cases. 18 were females and 7 were males with mean age of 57.15 years and mean duration of follow up of 8 months. The average duration of unilateral Proximal Fibular Osteotomy was 19.8 minutes per knee.

Among 20 patients, 4 patients developed ipsilateral lower leg numbness. Otherwise no postoperative complications were noted. Medial pain relief was observed in all patients after Proximal Fibular Osteotomy. The mean Visual Analogue Scale Score significantly decreased from 7.52 preoperatively to 2.92 postoperatively. The American Knee Society Score improved from 44.48 to 76.04 at last follow up at 12 months. Weight bearing lower extremity radiograph shows an average increase in medial knee joint space postoperatively. The medial joint space increased from an average of 1.784 mm to an average of 4.508 mm postoperatively. Additionally an obvious correction of alignment in the whole lower extremity radiographs was observed in eight patients.



A. Pre operative radiograph [A-P view]



B. Post-operative radiograph [A-P view]

Fig 2: Improvement of medial joint space of knee seen in radiographs.

4. Discussion

At the proximal tibia, the lateral support of the fibula to the lateral tibial plateau leads to non-uniform weight distribution, that is more severe in medial plateau than lateral plateau. The slope of the tibial plateau arising from non-uniform settlement of weight results in a transverse shearing force with the femoral condyle shifting medially during walking and sports.⁷ Proximal Fibular Osteotomy weakens the lateral fibular support, that corrects varus deformity, which subsequently shift the loading force from medial to laterally leading to decrease pain and functional recovery. Yang et.al conducted a study among 110 patients with a mean duration of follow up 49.1 months. They observed mean KSS at final follow up was 92.3+/-31.7 from 45.0+/-21.3, the mean VAS score from 7 to

2 at final follow up. The femorotibial angle from 182.7+/-2.0 to 179.4+/-degrees postoperatively¹⁸. Wang et al conducted a study among 47 patients with mean duration of follow up was 13.38 months. They observed the mean American KSS from 44.41+/-8.9 to 69.02+/-11.12 and mean VAS score decreased from 8.02+/-1.50 to 2.74+/-2.34 postoperatively¹⁹. Average increase in joint space is seen in all cases. In our study, mean VAS score decreased from 7.52 preoperatively to 2.92 postoperatively, and American KSS improved from 44.48 to 76.04 at last follow up at 12 months. The patient belonging to stage 2 and stage 3 are associated with good outcome. So, Proximal Fibular Osteotomy is a simple, safe and affordable surgery and hence, a suitable surgical option in most developing countries.

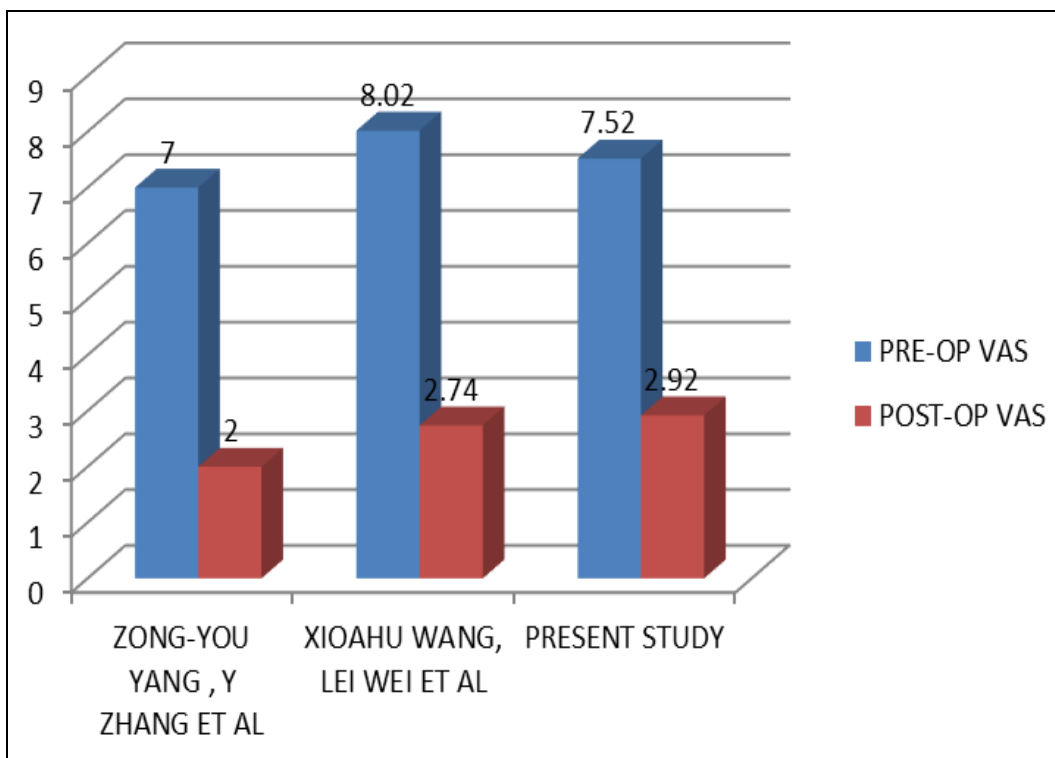


Fig 3: Pre-op and post-op VAS in various studies

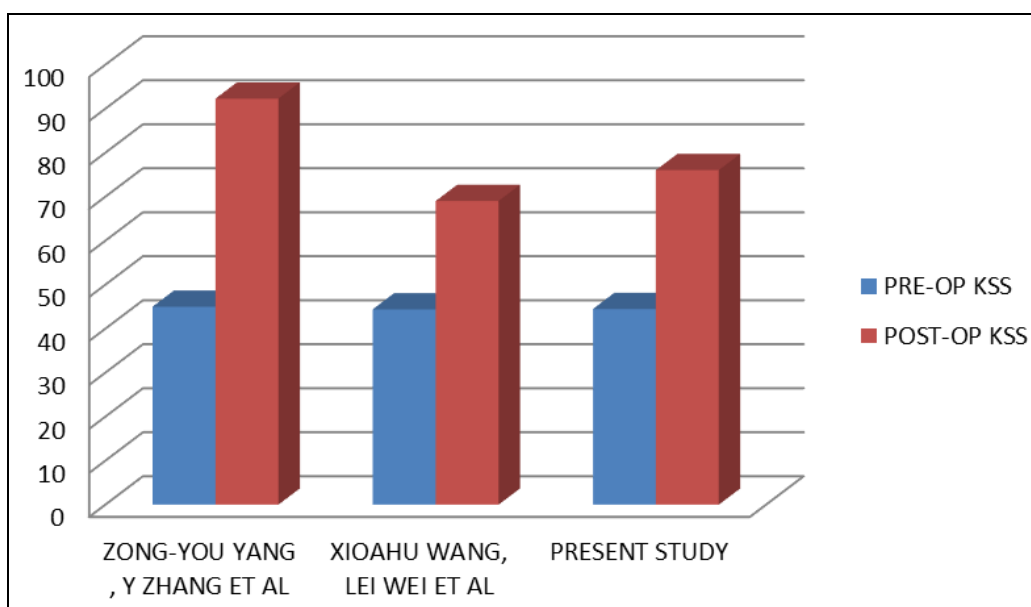


Fig 4: Pre-op and post-op KSS in various studies

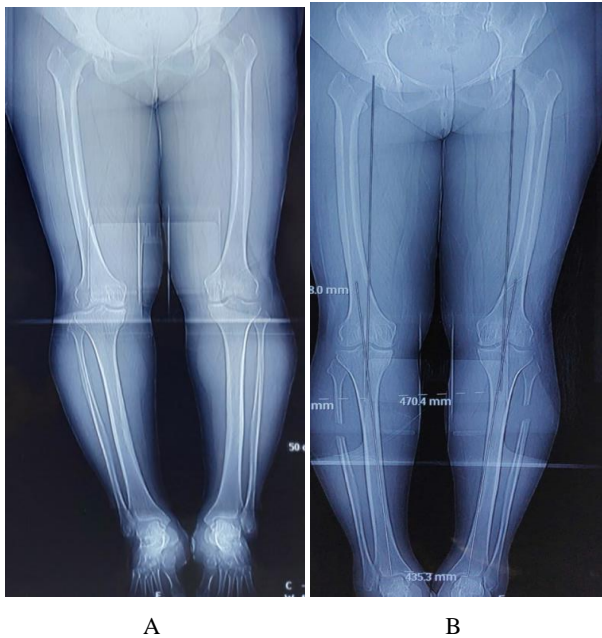


Fig 5: Improvement in the axial alignment of the lower extremity in a 54 year old woman with a 6 year history of bilateral knee joint pain **A.** Weight bearing radiograph of whole lower limb showing bilateral genu varus before proximal fibular osteotomy **B.** Correction of lower limb alignment after proximal fibular osteotomy

5. Conclusion and Limitations

Proximal Fibular Osteotomy reduces knee pain significantly in medial compartment osteoarthritic knee and improves functional recovery and radiographic appearance. It is a simple and cost effective procedure that delays or even negates the need for TKA. Hence, it is a viable alternative to TKA for the management of medial compartment knee osteoarthritis, especially in developing countries. Additionally, these patients can still undergo TKA in the future if it becomes necessary. The limitation of this study is small sample size and short duration of follow up. Whether this outcome will remain unchanged at a longer follow up is not clear, and has to be further investigated.

6. References

1. Shiozaki H, Koga Y, Omori G, Yamamoto G, Takahashi HE. Epidemiology of osteoarthritis of the knee in a rural Japanese population. *The Knee*. 1999; 6(3):183-8.
2. Ahlback S. Osteoarthrosis of the knee. A radiographic investigation. *Acta radiol*. 1968; 227:7-2.
3. Altman RD, Hochberg MC, Moskowitz RW, Schnitzer TJ. American College of Rheumatology Subcommittee on Osteoarthritis Guidelines. Recommendations for the medical management of osteoarthritis of the hip and knee: 2000 update. *Arthritis Rheum*. 2000; 43(9):1905-15.
4. Kellgren JH, Lawrence JS. Radiological assessment of osteo-arthrosis. *Annals of the rheumatic diseases*. 1957; 16(4):494.
5. Bodian CA, Freedman G, Hossain S, Eisenkraft JB, Beilin Y. The visual analog scale for pain Clinical significance in postoperative patients. *Anesthesiology: The Journal of the American Society of Anesthesiologists*. 2001; 95(6):1356-61.
6. Insall JN, Dorr LD, Scott RD, Scott WN. Rationale of the Knee Society clinical rating system. *Clin Orthop relat res*. 1989; 248(248):13-4.
7. Zhang Y, Li C, Li J. The pathogenesis research of non-

uniform settlement of the tibial plateau in knee degeneration and varus. *J Hebei Med Univ*. 2014; 35(2):218-9.

8. Yang ZY, Chen W, Li CX, Wang J, Hou ZY, Gao SJ *et al*. Medial compartment decompression by fibular osteotomy to treat medial compartment knee osteoarthritis: a pilot study. *Orthopedics*. 2015; 38(12):e1110-4.
9. Wang X, Wei L, Lv Z, Zhao B, Duan Z, Wu W *et al*. Proximal fibular osteotomy: A new surgery for pain relief and improvement of joint function in patients with knee osteoarthritis. *Journal of International Medical Research*. 2017; 45(1):282-9.