



International Journal of Orthopaedics Sciences

E-ISSN: 2395-1958

P-ISSN: 2706-6630

IJOS 2020; 6(1): 1333-1335

© 2020 IJOS

www.orthopaper.com

Received: 28-11-2019

Accepted: 30-12-2019

Dr. Suhruth Prasad TM

Department of Orthopedics, A.J

Institute of Medical Sciences,

Mangalore, Karnataka, India

Dr. Sudeep Shetty

Department of Orthopedics, A.J

Institute of Medical Sciences,

Mangalore, Karnataka, India

Dr. Abhishek MU

Department of Orthopedics, A.J

Institute of Medical Sciences,

Mangalore, Karnataka, India

Dr. Anushree Anil Kumar

Department of Orthopedics, A.J

Institute of Medical Sciences,

Mangalore, Karnataka, India

Subungual osteochondroma: A case report

Dr. Suhruth Prasad TM, Dr. Sudeep Shetty, Dr. Abhishek MU and Dr. Anushree Anil Kumar

DOI: <https://doi.org/10.22271/ortho.2020.v6.i1r.2007>

Abstract

Osteochondromas are among the most common benign bone tumors of the foot. However their occurrence is rare in subungual region. Clinically they present as slow growing mass causing deformity of the overlying nail. Here we present a case of subungual osteochondroma in an 11 year male kid with characteristic clinical, radiological & histopathological findings. The lesion was successfully treated by excision.

Keywords: Osteochondroma, exostosis, subungual

Introduction

Osteochondroma is a benign bone tumor. Subungually located osteochondromas are rare and are more common in toes than in fingers. Clinically these lesions may present as slow-growing masses, usually on the dorsum of the distal phalanx. This lesion will further cause deformity of the overlying nail. Main symptom includes pain further leads to ulceration due to pressure on the surrounding structures by the mass. Differential diagnosis includes subungual exostosis, verruca vulgaris, glomus tumor, enchondroma, pyogenic granuloma, osteosarcoma, or malignant melanoma. Early diagnosis and treatment of these lesions with their distinctive clinical, radiologic, and histopathologic features is critical in preventing overaggressive, sometimes mutilating therapy.

Case Report

An 11year old boy presented with pain in the right great toe since. Patient also complains of ulceration over dorsum of great toe medial to nail plate. There was no history trauma. On physical examination, a firm, reddish white nodule was noted medial to the distorted nail. Radiological examination revealed well circumscribed, pedunculated outgrowth over the dorsum of distal phalanx. Growth was radio opaque with sclerotic borders.

Under general anaesthesia, first the deformed nail was removed. Dissection was done till the tumor. Tumor measuring 1 x 0.8 cm was excised & sent to histopathological examination. Curretage of base was done till the medullary cavity. Dead space created by the lesion was sutured using monocrl 3-0. Mupirocin cream was applied. Nail bed dressing was done using Bactigras. A firm bandage was wrapped around the great toe, and the limb was elevated. Wound examination was done once in 2 days. Nail bed began to heal on 14th day. On histopathological examination of the lesion, a characteristic trabecular bone pattern covered with a hyaline cartilage cap was seen, confirming the diagnosis of osteochondroma.

Discussion

Osteochondroma is the most common benign skeletal neoplasm and accounts for 10% to 15% of all bone tumors and 20% to 50% of benign bone tumors and usually is solitary (90%). Subungually located osteochondromas are rare and are more common in toes than in fingers. Osteochondromas are more frequently observed in adolescents and young adults, with a male to female ratio of 2:1. Etiology is not fully understood. Although they are thought to be congenital in origin, they usually remain asymptomatic in childhood and begin enlarging after puberty. Clinically the lesions appear as firm, shiny, smooth-surfaced, white yellow nodules, which is characteristic for the entity.

Corresponding Author:

Dr. Suhruth Prasad TM

Department of Orthopedics, A.J

Institute of Medical Sciences,

Mangalore, Karnataka, India

Radiographic appearance is diagnostic, exhibiting a well-defined, circumscribed, pedunculated bone growth, projecting from the dorsum of the distal phalanx. Histopathology examination has typical findings of a well-defined trabecular bone topped with a hyaline cartilaginous cap.

Osteochondromas are easily misdiagnosed. Differential diagnosis included benign conditions like verruca vulgaris, subungual fibroma, glomus tumor, pyogenic granuloma, subungual digital mucous cyst, subungual exostosis and enchondroma, and malignant lesions such as osteosarcoma, squamous cell carcinoma, and malignant melanoma.

Verruca vulgaris, squamous cell carcinoma, and malignant melanoma can be easily diagnosed by histopathological examination. Subungual fibroma and glomus tumors have characteristic clinical findings.

Enchondromas are tumoral lesions composed of cartilage. They arise from the medullary cavity of the bones and they are frequently located on the dorsum of the distal phalanx. Typically they cause expansion of the underlying phalanx as they enlarge. Radiologically they may be seen as radiolucent areas surrounded by a calcified cartilage localized on the dorsum of the expanded phalanx.

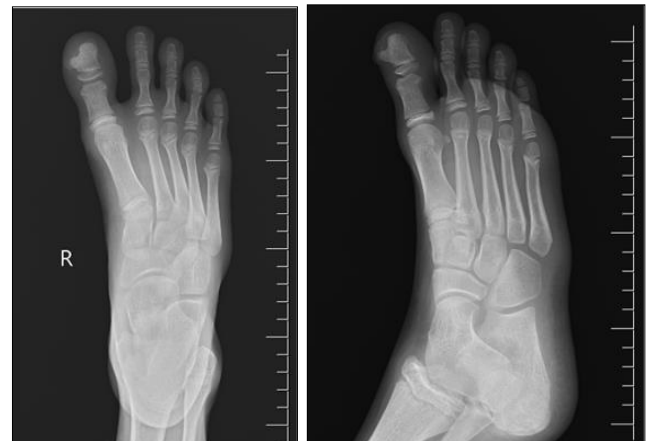Osteochondromas often are misdiagnosed as mature subungual exostosis because of their radiographic similarities. Subungual exostosis shows trabeculated bone arising from the dorsal or dorsomedial aspect of the tuft and extends distally and away from the epiphysis¹¹. This may be broad based, tapered, and upwardly extending or narrow-based with progressive widening. Ossification varies with lesion maturity, and trabeculae are commonly observed at the bases of mature lesions. Destructive changes of the phalanx and periosteal reaction are absent.

Subungual osteochondroma presents as an outpocketing of trabecular bone from the juxtaepiphyseal region of the distal phalanx. These growths usually slant away from the adjacent interphalangeal joint of the phalanx. The cortical and medullary bone of osteochondroma curves smoothly into the distal phalanx, and the lesion bases may be circumscribed, sessile, or pedunculated. Because subungual osteochondroma grows by enchondral ossification, the tumor may increase slowly until puberty and then show an accelerated growth rate throughout puberty and adolescence, until closure of the physal plates.

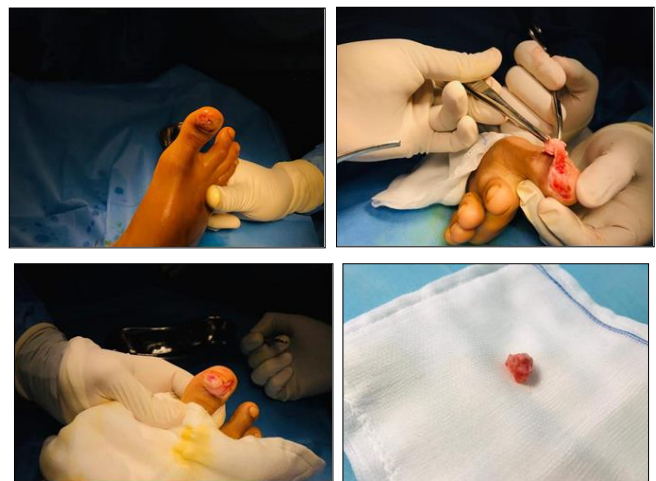
The major histologic difference between subungual exostosis and subungual osteochondroma is the composition of the cartilaginous cap. In subungual exostosis, this is composed of fibrocartilage, and the distal phalangeal tuft normally develops through enchondral ossification of fibrocartilaginous anlage. Exostosis begins as a fibrocartilaginous nest just below or adjacent to the nail bed. Microscopic examination of the cap exhibits hypercellularity with plump nuclei and chondrocyte multinucleation. Therefore, a limited biopsy may create the false impression of a malignant cartilage tumor. The thicknesses of fibrocartilage caps vary and largely depend on lesion maturity; moreover, as lesions mature the thickness of cartilage rims reduce as they are replaced by bone. The cartilaginous cap of an osteochondroma is composed of hyaline cartilage, with a cell configuration similar to that of a normal growing epiphysis. This hyaline cartilage cap may grow to become much larger than in an exostosis, which generally measures less than 1 cm and contains a large number of chondrocytes. Active enchondral ossification also was evident at interfaces between hyaline cartilage and underlying trabecular bone, and trabecular and cortical bone were found to be continuous with the distal phalanx.

Moreover, histologic examinations of subungual osteochondromas do not suggest the possibility of a traumatic etiology.

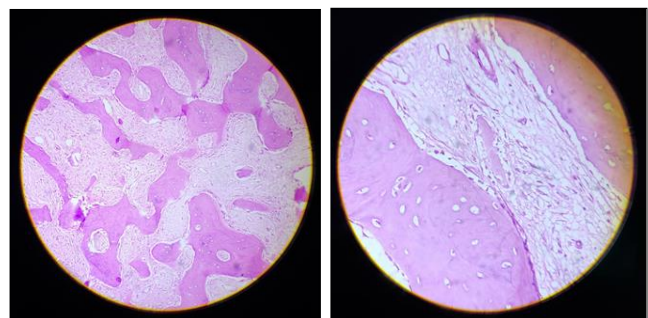
X-Rays



Intra-Operative Images



Microscopy Images



Conclusion

Subungual exostosis and subungual osteochondroma are benign but distinct osseous pathologies, which differ clinically, radiographically, histologically, and how they develop. When a diagnosis has been made and symptoms persist, complete bony lesion excision with curettage of its base and nail bed reconstruction is the treatment of choice in both conditions.

References

1. Hodgkinson DJ. Subungual osteochondroma. *Plast Reconstr Surg.* 1984; 74:833-4.

2. Eliezri YD, Taylor SC. Subungual osteochondroma. *J Dermatol Surg Oncol.* 1992; 18:753-8.
3. Apfelberg DB, Druker D, Maser MR, Lash H. Subungual osteochondroma: differential diagnosis and treatment. *Arch Dermatol.* 1979; 115:472-3.
4. Greger G, Catanzariti AR. Osteochondroma: review of the literature and case report. *J Foot Surg.* 1992; 31:298-300.
5. Haneke E, Baran R, Bureau H. Tumors of the nail apparatus and adjacent tissues. In: Baran R, Dawber RPR, eds. *Diseases of the nails and their management.* Oxford: Blackwell Scientific. 1984; 424-9.
6. Davis DA, Cohen PR. Subungual exostosis: case report and review of the literature. *Pediatr Dermatol.* 1996; 13:212-8.
7. Grisafi PJ, Lombardi CM, Sciarrino AL, Rainer GF, Buffone WF. Three select subungual pathologies: subungual exostosis, subungual osteochondroma and subungual hematoma. *Clin Podiatr Med Surg.* 1989; 6:355-64.
8. Berker DAR, Langtry J. Subungual exostosis and day surgery. *Br J Dermatol.* 1999; 140:915-8.
9. Apfelberg DB, Druker D, Maser MR *et al.* Subungual osteochondroma: differential diagnosis and treatment. *Arch. Dermatol.* 1979; 115:472.
10. Baek GH, Kim JS, Chung MS. Multiple subungual osteochondromas: A case report. *J Korean Orthop. Assoc.* 2004; 39:579-581.
11. Cates HE, Burgess RC. Incidence of brachydactyly and hand exostosis in hereditary multiple exostosis. *J. Hand Surg.* 1991; 16- A:127-132.
12. Cavolo DJ, D'Ameilo JP, Hirsch AL *et al.* Juvenile subungual osteochondroma: case presentation. *J Am. Podiatr. Med. Assoc.* 1981; 71:81.
13. De Palma L, Gigante A, Specchia N. Subungual exostosis of the foot. *Foot Ankle Int.* 1996; 17:758-763.
14. Dupuytren G. On the injuries and diseases of the bones. F. Legros Clark, Trans, ed. London, Publications of the Sydenham Society, 1847, 408-410.
15. Evison G, Price CH. Subungual exostosis. *Br. J Radiol.* 1966; 39:451-455.
16. Freedman DJ, Luzzi A, Picciotti J. Solitary osteochondroma of the distal phalanx: A case report. *J Am. Podiatr. Assoc.* 1987; 77:615.
17. Giudici MA, Moser RP, Kransdorf MJ. Cartilagenous bone tumors. *Radiol. Clin. North Am.* 1993; 31:237-259.
18. Hodgkinson DJ. Subungual osteochondroma. *Plast. Reconstr. Surg.* 1984; 74:833-834.
19. Ippolito E, Falez F, Tudisco C *et al.* Subungual exostosis: Histological and clinical consideration on 30 cases. *Ital. J Orthop. Traumatol.* 1987; 13:81-87.
20. Kim SW, Moon SE, Kim JA. A case of subungual osteochondroma. *J Dermatol.* 1998; 25:60-62.
21. Lichtenstein L, Golden RL. Cartilage tumors in soft tissues, particularly in the hand and foot. *Cancer.* 1964; 17:1203-1208.
22. Milgram JW. The origins of osteochondroma and enchondromas. A histopathologic study. *Clin. Orthop.* 1983; 174:264-284.
23. Miller-Breslow A. Dorfman, HD: Dupuytren's (subungual) exostosis. *Am. J Surg. Pathol.* 1988. 12:368-378.
24. Murphey MD, Choi JJ, Kransdorf MF, Flemming DJ, Gannon FH. Imaging of osteochondroma: variants and complication with radiologic-pathologic correlation. *Radiographics.* 2000; 20:1407-1434.
25. Scarborough MT, Moreau G. Benign cartilage tumors. *Orthop. Clin. North Am.* 1996; 27:583-589.