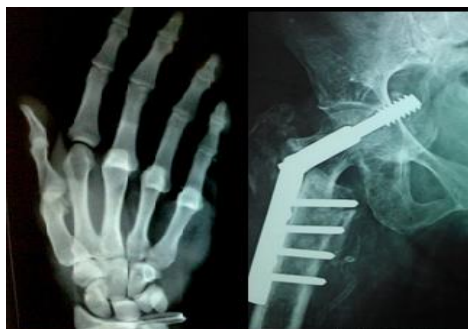



## International Journal of Orthopaedics Sciences

E-ISSN: 2395-1958  
P-ISSN: 2706-6630  
IJOS 2020; 6(1): 1021-1026  
© 2020 IJOS  
[www.orthopaper.com](http://www.orthopaper.com)  
Received: 14-11-2019  
Accepted: 18-12-2019

**Dr. HS Chandrashekar**  
Professor and Director, Dept. Of  
Orthopaedics, Sanjay Gandhi  
Institute of Trauma and  
Orthopaedics, Bangalore,  
Karnataka, India

**Dr. Akhil M**  
Post Graduate, Dept. Of  
Orthopaedics, Sanjay Gandhi  
Institute of Trauma and  
Orthopaedics, Bangalore,  
Karnataka, India

**Dr. Chidanand KJC**  
Assistant Professor, Dept. Of  
Orthopaedics, Sanjay Gandhi  
Institute of Trauma and  
Orthopaedics, Bangalore,  
Karnataka, India

**Corresponding Author:**  
**Dr. Chidanand KJC**  
Assistant Professor, Dept. Of  
Orthopaedics, Sanjay Gandhi  
Institute of Trauma and  
Orthopaedics, Bangalore,  
Karnataka, India

### A prospective study of functional outcome of intracapsular femur neck fractures treated with bipolar prosthesis

**Dr. HS Chandrashekar, Dr. Akhil M and Dr. Chidanand KJC**

**DOI:** <https://doi.org/10.22271/ortho.2020.v6.i1m.1952>

#### Abstract

**Aims:** In this clinical study forty cases of intracapsular fracture neck of femur in elderly patients above the age of 60 years treated by bipolar hemiarthroplasty and were followed up and functional results were analysed with the objectives, to study the age and sex incidence of fracture neck of femur, quality of life after hemiarthroplasty, morbidity and mortality associated with the procedure, recovery of physical, social and vocational independence, number of days of stay in hospital and associated complications.

**Methods:** Forty cases of fracture neck of femur in elderly patients above the age of 60 years treated by hemiarthroplasty using bipolar prosthesis between November 2017 to May 2019 were selected according to inclusion and exclusion criteria. Cases were followed up for 6 months and the short term functional results were analysed by using modified Harris hip score.

**Results:** Most of the patients were in the age group of 60 to 70 years with mean average age of 69.2 years. Females were predominant. In 62.5 percent cases mode of injury was trivial trauma. Associated comorbidities hypertension, diabetes mellitus and anaemia were common. The complications observed were superficial infection of the wound, bed sore, periprosthetic fracture and posterior prosthetic dislocation. There were 30% excellent results and 45% good results.

**Conclusion:** The success of hemiarthroplasty depends on preoperative planning and attention to surgical details to achieve the optimum biomechanical stability. Bipolar hemiarthroplasty for fractures neck femur provides better range of movement, freedom from pain and more rapid return to unassisted activity with an acceptable complication rate. The end functional results depend on the age of the patient, associated co-morbidity and optimum post-operative rehabilitation. Early functional results are satisfactory.

**Keywords:** Bipolar prosthesis, harris hip score, calcare femorale, hemiarthroplasty, southern moore approach

#### Introduction

Femoral neck fractures, one of the most common injuries in the elderly. The prevalence of these fractures has increased with improvement in life expectancy, increased incidence of osteoporosis, poor vision, neuro-muscular incoordination and changes in lifestyle leading to sedentary habits. The incidence of these fractures are expected to double in the next twenty years and triple by the year 2050 [1]. Despite of marked improvements in implant design, surgical technique and patients care, hip fractures consume a potential proportion of our health care resources [2]. In elderly population and approximately 90% of these injuries are the result of simple fall from standing position. It has been observed that age specific incidence of hip fracture doubles every 5 - 6 years after the age 30 in women reaching 18 fractures per 1000 per year in women over 85 [3]. Limited and unprotected blood supply to the femoral head, the intracapsular location and severe trabecular atrophy of femoral neck are the factors that inhibit fracture healing and leads to osteonecrosis and late segmental collapse of femoral head [4]. In Elderly patients, prolonged recumbency leads to many problems such as bed sores, cardiac and respiratory problem, thromboembolism, renal problems and dementia. This led many surgeons to abandon the native treatment of immobilization and osteosynthesis procedure for displaced femoral neck fracture in elderly patients, in favor of primary hemi replacement arthroplasty, which has certain advantages such as early ambulation, shortening the period of hospitalization and also avoids danger of non-union and avascular necrosis.

This forces one to totally abandon the complete immobilization to achieve a bony union, or to resort early ambulatory procedures by surgery<sup>[5]</sup>. Hemireplacement arthroplasty by using vitallium or stainless steel was popularly practiced by Austin Moore's produced fair results<sup>[6, 7]</sup>. But it had its limitations in loosening and reactions at acetabulum etc. Many of the shortcomings of this procedure were overcome by a new type of prosthesis, which had the advantage of second joint, below the acetabulum. It was named as bipolar prosthesis, since it had an outer head of metal which articulates with the acetabulum and a second inner small metallic head which articulates with the high density polyethylene (HDPE), lining the inner surface of the outer head. This results were found to be encouraging<sup>[8]</sup>.

Primary Total Hip Replacement (THR) is being offered at many centres as a treatment option for these fractures. Total hip arthroplasty is still not popular as a treatment modality for fracture neck of femur in our country because majority of the patients do well with hemiarthroplasty and also due to the high costs involved. It also has a higher incidence of dislocations and higher morbidity associated with the procedure<sup>[9]</sup>.

### Materials and Methods

This is a prospective study of 40 cases of fracture neck of femur in elderly patients above the age of 60 years treated by hemiarthroplasty using bipolar prosthesis which were admitted to SGITO, Bangalore, Karnataka between November 2017 to May 2019 were included after obtaining the permission from the Institutional Ethical Committee. Patients with age group >60yrs of either sex and ambulatory, patient with intracapsular femur neck fracture, neglected femur neck fracture more than 3-4 weeks old in elderly patients, ability to understand the content of the subject information / informed consent form and to be willing to participate in the clinical investigation were included and patients <60 yrs of age, compound femur neck fractures, pathological fractures, polytrauma patients, Not willing to give informed written consent. Cases were followed up for 6 months and the short term functional results were analysed by using modified Harris hip score.

### Surgical approach-southern moore's posterior approach to the hip

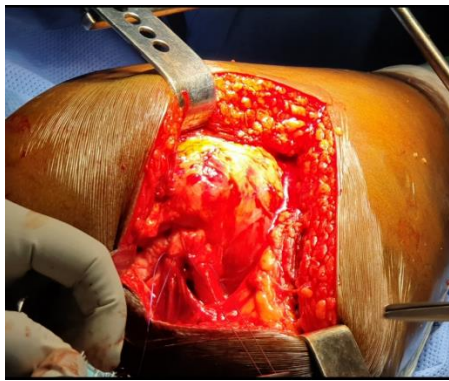
After induction of either spinal or epidural anaesthesia the patient was placed on the lateral position on the operative table with the affected side facing up. A curved incision is taken from 8 cm distal to the posterior superior iliac spine, extended distally and laterally, parallel with fibers of gluteus maximus muscle to the posterior margin of the greater trochanter. The incision is then directed distally 5-8 cms along the femoral shaft. The deep fascia is exposed and divided in line with the skin incision. By blunt dissection the fibers of the gluteus maximus are separated taking care not to disturb the superior gluteal vessels in the proximal part of the

exposure. The gluteus maximum muscle is split and short external rotators are exposed. Stay sutures are applied to the short external rotators, and a tenotomy of the short external rotators is done close to their insertion on the inner surface of the Greater trochanter. The short external rotators are retracted to protect the sciatic nerve and expose the posterior hip capsule. The capsule is incised by a T-shaped incision, and the hip flexed, adducted and internally rotated to dislocate the hip joint. Using a head extractor and bone levers, head is delivered out of the acetabulum and the acetabulum is cleared of debris. The size of the extracted head is measured by using measuring gauze, and the size of prosthesis is selected.

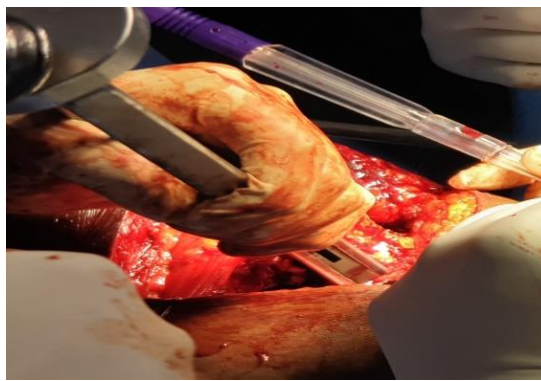Preparation of proximal femur, The neck is trimmed leaving 1cm medial calcar, on which the shoulder of the prosthesis would eventually sit. The proximal femur was reamed with rasp, the length of the rasp corresponding to the stem of the prosthesis. The direction of the insertion of the rasp for was ascertained by using the lesser trochanter as a guide to achieve correct seating of the prosthesis in 10-15° anteversion. Insertion of the bipolar prosthesis, The appropriate sized prosthesis is inserted into the reamed canal taking care to place it in 10-15° of anteversion. The final seating of the prosthesis is by gentle blows with the help of a mallet and the inserter. Adequate seating of the prosthesis on the calcar is visualized directly. The hip joint is reduced by gentle traction with external rotation of the hip and simultaneous manipulation of the head of the prosthesis into the acetabulum. The range of movement in all directions is checked by taking the joint through the whole range of movements. The stability of the prosthesis and its tendency to dislocate is checked by flexing and adducting the hip. The limb is kept in slight abduction and external rotation for suturing the wound. Great care is taken to achieve adequate closure of the posterior capsule and anatomical reattachment of the short external rotators. The rest of the wound is closed in layers over a suction drain placed beneath the gluteus maximus. Haemostasis is maintained throughout the procedure.

### Postoperative protocol

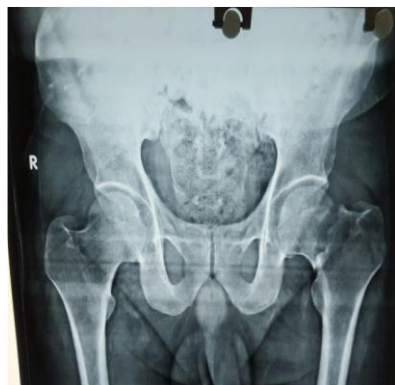All the patients who were operated were kept in supine position with the involved lower limb in 20-30° abduction. The drain was removed between 24-48 hours depending on the amount of collection. Peri-operative prophylaxis of Ceftriaxone-S given 1.5g 8th hourly intravenous was continued for the first 5-7 days. The wound was inspected at the time of drain removal and at the time of suture removal. If however, there was soakage of the dressing or if patient had high fever the wound was inspected accordingly. Patients were initially advised to touch weight bearing and later advised progress to full weight bearing as tolerated. The sutures were removed between 10-14 days. The patients were examined before discharge for the evidence of any infection at operated site.



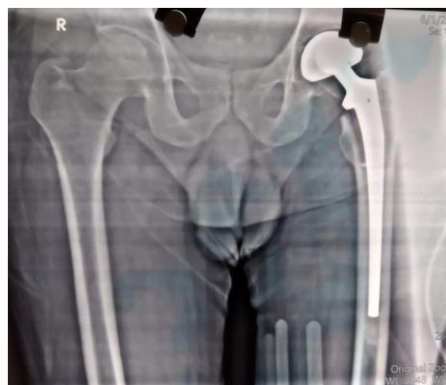**Fig 1:** Exposure of short external rotators



**Fig 2:** Prosthesis snug fit over calcar femorale



**Fig 3:** Pre-op Radiograph



**Fig 4:** Post-op Radiograph

**Results**

The average age was noted to be 69.2 years.

**Table 1:** Age distribution.

	No. of patients	Percentage
60-70	26	65
71-80	8	20
>80	6	15

**Table 2:** Sex distribution

Sex	No. of patients	Percentage
Males	13	32.5
Females	27	67.5

In 28 patients left side was involved and in 12 patients right side involved.

**Table 3:** Laterality pattern

Sex	No. of patients	Percentage
Males	13	32.5
Females	27	67.5

The mode of injury causing the fracture of the neck of femur. 62.5% of the patients sustained the injury by tripping or slipping, 20% due to and RTA and the remaining 17.5% by a fall from a height.

**Table 4:** Mode of Injury.

Mode of Injury	No. of patients	Percentage
Tripping/Slipping	25	62.5
RTA	8	20
Fall from a height	7	17.5

10 patients had heart disease, 20 had diabetes, 6 had COPD and 12 had hypertension.

**Table 5:** Systemic co-morbidities.

Systemic Co-morbidity	No. of patients	Percentage
Heart Disease	10	25
Diabetes	12	30
COPD	6	15
Hypertension	12	30

6 patients were operated with cemented hemiarthroplasty as these patients had osteoporotic bone and to make the prosthesis snug fit to prevent iatrogenic fracture during serial rasping.

**Table 6:** Type of Hemiarthroplasty

Type	No. of patients	Percentage
Uncemented	34	85
Cemented	06	15
	40	100

The most commonly encountered peri-operative problem was technical difficulty in insertion of the prosthesis. Postoperative blood transfusion reaction patients for which blood transfusion was stopped and injection CPM was administered.

**Table 7:** Perioperative complications.

Peri-operative complications	No. of patients	Percentage
Technical Difficulty	8	20
Post-ophypotension	6	15
Bloodtransfusionreaction	2	5
Communion of tip of GT	1	2.5
Greater trochanter blowout	2	5
Nil	21	52.5



Limb lengthening (<1cm) was observed in two patients (10%) post-operatively due to technical errors in the form of the prosthesis sitting proud of the calcar. Superficial infection in the form of a wound dehiscence was seen in three patient and was managed by debridement and secondary suturing along with appropriate antibiotics based on culture-sensitivity results. The infection resolved without any sequelae and there was no late reactivation of the same.

**Table 8:** Early post-operative complications

Early Complications	No. of patients	Percentage
Limb Lengthening	4	10
Superficial Infection	3	7.5

There were no late postoperative complications like loosening, dislocation, erosion, secondary osteoarthritis, protrusion acetabuli, periprosthetic fracture.

The minimum duration of hospital stay amongst the study patients was 11 days and maximum duration was 16 days with the average being 13 days.

**Assessment of functional results**

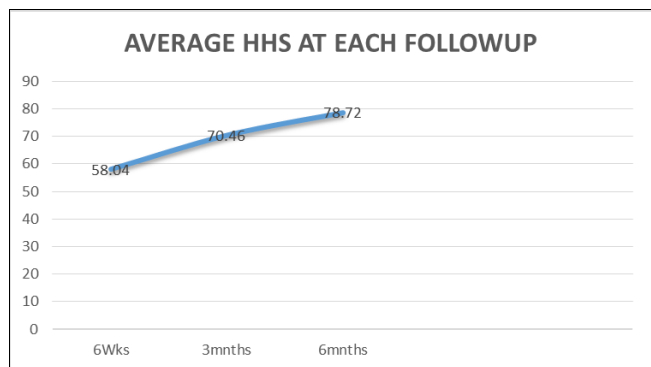
The patients were followed up at 6 weeks, 3 months and 6 months. Functional results of hemiarthroplasty were assessed by using modified Harris hip scoring system.

**Radiographic results**

There were three cases with radiolucent zone more than 2 mm around the stem of the prosthesis. Subsidence of the prosthesis was found in one case.

**The progression of harris hip score**

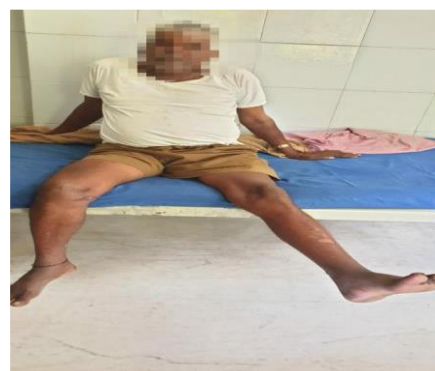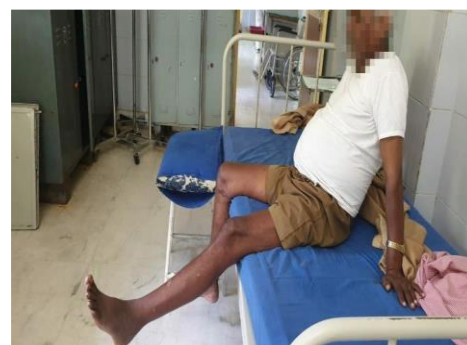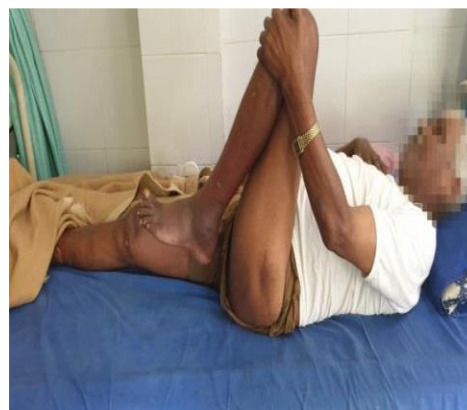The average Harris Hip Score at 6 weeks after surgery was 58.04 with the highest score being 66.65 and the lowest being 43.83. The average Harris Hip Score at the second follow-up of 3 months was 70.46 with the maximum score being 83.88 and the minimum 58.05. At the final follow-up at 6 months the average Harris Hip Score was 78.72 with the highest being 88.8 and the lowest being 57.45.



Overall, 12 patients (30%) achieved Excellent result, 18 patients (45%) achieved Good result, 7 patients (17.5%) achieved fair result and 3 patients (7.5%) achieved poor result. 75% of the patients achieved an excellent or good result.

**Table 9:** Final harris hip score and clinical result.

Grade	Harris Hip Score	No. of patients	Percentage
Excellent	90-100	12	30
Good	80-89	18	45
Fair	70-79	7	17.5
Poor	<70	3	7.5



**Fig 5, 6, 7:** Illustration at 6 month follow-up (Flexion, Extension, Abduction)

**Discussion**

The aim of replacement surgery in trans-cervical fracture neck femur is early return to daily activities. This is particularly applicable to the elderly age group where complications need to be prevented. The mean age of the patients in the present study was 69.2 years. The aim of assessing age is to estimate the patient’s mean survival time and their ability to comply with rehabilitation protocol. Patients with hip fractures have an increased mortality rate during the first year after fracture but after one year the mortality rate is comparable to that of the general population. The results of our study showed that age of the patient had minimal influence on the final clinical result. As in most standard studies, the present study also had a higher number of females with the left side more commonly affected than the right.

Majority of our study patients (62.5%) sustained the injury due to a trivial trauma like tripping or slipping. This is a very common occurrence in elderly population where poor vision and lack of neuro-muscular coordination is a problem. Most of such injuries can be classified as “indirect” trauma. Next common (20%) sustained the injury due to RTA and remaining (17.5%) due to a Fall from height.

The common scenario in our country where patients present to a doctor much late given the seriousness of the condition.

Difficulty in post-operative rehabilitation was particularly noticed in the group who presented after 1 week. All of our study patients had a displaced fracture of the neck of femur. Majority of the patients (87.5%) had a trans-cervical fracture while four patients had sub-capital and one patient with basicervical fracture. The anatomical type of fracture and the displacement did not have any effect on the final function.

Diabetes and Hypertension were found to be the most common co-morbidity seen in 30% of the study patients. All patients had Type II Diabetes and were on oral hypoglycaemic agents. They were shifted to insulin pre-operatively and blood sugar values optimized before taking up for surgery. The other co-morbid conditions seen in the order of frequency were Heart Disease (25%) and COPD (15%). It was observed that the post-operative rehabilitation of patients was significantly affected by the presence of the above co-morbidities. This also had an effect on the final functional result of the procedure. Similar observations have been made by Koval *et al.*<sup>[10]</sup> and Bath<sup>[11]</sup>.

All the study patients were taken up for the surgical procedure between the 4<sup>th</sup> and 12<sup>th</sup> day after the trauma, the average delay to surgery being 7 days. Delay in taking up for surgery was usually for optimizing the medical condition of the patient and some patients presented late. All cases were performed on an elective basis. All the surgeries were performed under spinal or epidural anaesthesia after a thorough preanaesthetic evaluation and preparation. The choice of the type of anesthesia was as per the anesthetist's discretion.

All patients were operated after being put into lateral decubitus position by the posterior approach of Moore. The posterior approach was preferred because of the familiarity of most of the surgeons at our institution with the approach. Though the dislocation rate is reported to be more with the posterior approach, none of our study patients had a post-operative dislocation of the prosthesis. This was because meticulous attention was given to suturing the posterior capsule and the short external rotators and keeping the limb in slight abduction after the procedure. Patients were also explained in the immediate post-operative period about the risk of dislocation with excessive flexion or adduction of the hip.

The size of the prostheses used, in 35% of the cases 45 mm prostheses were used. This was followed in frequency by 43 mm (27.5%), 47 mm (20%), 41 mm (10%) and 39mm (2.5%) prostheses in the order of frequency. All the prostheses were inserted by press fit technique and 6 required any additional augmentation with cement.

The main difficulty faced was calculating the angle of the neck osteotomy which resulted in poor seating of the prosthesis collar on the neck and calcar. The second difficulty encountered was miscalculation of the amount of neck to be resected. Inadequate resection of the neck resulted in the prosthesis sitting proud of the calcar and subsequent limb lengthening in some cases.

In upto half of the cases, the blood loss was < 500ml for the whole procedure and in most of the others it was between 500-750ml. Only 12.5% of cases had a blood loss of >750 ml requiring a blood transfusion. It has been reported in literature that the average blood loss with hip hemiarthroplasty is less in the anterior approach as compared to the posterior approach<sup>[11, 12]</sup>. Most of the surgeries were completed between 90-120 minutes of starting the procedure. Similar duration of the procedure has been reported by Haidukewych, *et al.*<sup>[13]</sup> and Drinker, *et al.*<sup>[14]</sup> Neither the intra- operative blood loss nor

the duration of the procedure had any effect on final function. Most of our study patients were mobilized in bed on day one of surgery and with weight bearing as tolerated within the 72 hours postoperative period. Delay if at all was due to medical reasons.

Limb lengthening (<1 cm) was observed in four patients (10%) post- operatively due to technical errors in the form of the prosthesis sitting proud of the calcar.

Superficial infection in the form of a wound dehiscence was seen in three patient (7.5%) who were diabetic. They were managed by debridement and secondary suturing with adequate control of the diabetic status and appropriate antibiotics based on culture-sensitivity results. The infection resolved without any sequelae and there was no late reactivation of the same. Infection rate of 3.9% after bipolar hemiarthroplasty is reported by Nottage, *et al.*<sup>[15]</sup> None of our study patients had bed sores. The minimum duration of hospital stay amongst the study patients was 11 days and maximum duration was 16 days with the average being 13 days. Average hospital stay of 21 days with bipolar hemiarthroplasty has been reported by Lestrangle.<sup>16</sup> Drinker and Murray have reported an average hospital stay of 23 days with the same procedure<sup>[14]</sup>. There were no late postoperative complications like loosening, dislocation, erosion, secondary osteoarthritis, protrusioacetabuli or periprosthetic fracture. We are unable to comment upon long term acetabular erosion due to relative short follow up.

All patients were followed up regularly at 6wks, 3 months and 6 months. The Harris Hip Scores were recorded at each follow-up visit.

In our study, the final Harris Hip Score as evaluated at 6 months follow-up averaged 78.72 with the maximum score being 88.8 and the minimum score being 57.45 Overall, 14 patients (35%) achieved Excellent result, 16 patients (40%) achieved.

Good result, 6 patients (15%) achieved fair result and 4 patients (10%) achieved poor result. Overall, 81.81% of the patients achieved an excellent or good result. Our results are comparable with standard studies of bipolar hemiarthroplasty performed for fracture neck femur.

All study patients were also evaluated with their level of satisfaction with the procedure and their ability to return to pre-fracture level of activity. 14 patients (35%) were 'very satisfied', 18(45%) were 'fairly satisfied' and 8 (20%) were 'not satisfied'. The level of satisfaction being a subjective assessment did not correlate well with the Harris Hip Score which was an objective assessment.

### Comparison of the present study with standard studies

**Table 10:** Comparison of the present study with standard studies.

Grade	Our study	Moshein study <sup>[17]</sup>	Lestrangle study <sup>[16]</sup>
Excellent	30	40	39.6
Good	45	25	31.2
Fair	17.5	23	15.3
Poor	7.5	12	13.9

Our study is not without its own shortcomings. Firstly, our duration of follow- up of is less in assessing the longevity and functional endurance of the prosthesis used and hence come to definitive conclusions. Secondly, we have not evaluated the degree of intra-prosthetic motion at the inner bearing at each follow-up. Such studies are complicated and beyond the facilities available at our institution. Such studies are indicated because there are claims that the motion at the inner

bearing reduces over time and most prostheses behave as unipolar prostheses over a period of time.

### Conclusion

Bipolar hemiarthroplasty for fractures of the femoral neck provides better range of movement, freedom from pain and more rapid return to unassisted activity with an acceptable complication rate. The end functional results depend on the age of the patient, associated co-morbidity and optimum post-operative rehabilitation. Though out of the purview of the present study our experience with bipolar prosthesis have been significantly better. The long term results using bipolar hemiarthroplasty needs further study for a longer period in a larger sample.

### References

1. Schmidt AH, Swiontkowski MF. Femoral neck fractures. *Orthop Clin North Am.* 2002; 33(1):97-111.
2. Mark Smiontkoski F *et al.* Current concepts review of intracapsular fracture of hip. *JBJS.* 1994; 76A:129-135.
3. Robert WB, James DH. *Rock wood Green's Fracture in Adults.* 5<sup>th</sup> Edition. Lippincot Williams & Wilkins, 2001.
4. Canate TS. *Campbell's operative orthopaedics.* 10th Edition. Mosby, 2003.
5. Elizabeth Johnson O *et al.* Vascular anatomy and microcirculation of skeletal zones vulnerable to osteonecrosis. *Clinical Orthop.* 2004; 35:285-291.
6. Austin Moore T. The self-locking metallic hip prosthesis. *JBJS.* 1957; 39A:811-27.
7. Austin Moore T, Bohlman HR. Metallic hip joint, a case report. *JBJS.* 1963; 25:688-92.
8. Bateman JE. Single assembly total hip arthroplasty, preliminary report. *Orthop Digest.* 1974; 15:35-43.
9. Maini PS, Talwar N, Nijhawan VK, Dhawan M. Results of cemented bipolar hemiarthroplasty for fracture of the femoral neck – 10 year study. *Indian Journal of Orthopaedics.* 2006; 40(3):154-156.
10. Koval KJ, Zuckerman JD. Current Concepts Review: Functional Recovery after Fracture of the Hip. *J Bone Joint Surg Am.* 1994; 76:751-766.
11. Bath R. Problems in the treatment of femoral neck fractures. *Proceedings of the Royal Society of Medicine.* 1975; 63:1120-1128.
12. Kenzora JE, Magaziner J, Hudson J. Outcome after hemiarthroplasty for the femoral neck fractures in the elderly. *Clin Orthop.* 1998; 348:51-58.
13. Haidukewych GJ, Israel TA, Berry DJ. Long term survivorship of cemented bipolar hemiarthroplasty for fracture of the femoral neck. *Clin Orthop.* 2002; 403:118-126.
14. Drinker H, Murray WR. The universal proximal femoral endoprosthesis—A short term comparison with conventional hemiarthroplasty. *J Bone Joint Surg.* 1979; 61A:1167-1174.
15. Nottage WM, McMaster WC. Comparison of bipolar implants with fixed neck prosthesis in femoral neck fractures. *Clin Orthop.* 1990; 251:38-44.
16. Lestrangle NR. Bipolar arthroplasty for 496 hip fractures. *Clin Orthop.* 1990; 251:7-18.
17. Moshein J, Alter AH, Elconin KB, Adams WW. Transcervical fractures of the hip treated with the bateman bipolar prosthesis. *Clin Orthop.* 1990; 251:48-53.