



International Journal of Orthopaedics Sciences

E-ISSN: 2395-1958
P-ISSN: 2706-6630
IJOS 2020; 6(1): 677-681
© 2020 IJOS
www.orthopaper.com
Received: 16-11-2019
Accepted: 20-12-2019

Sachin NS
Department of Orthopaedics, SS
Institute of Medical Sciences and
Research Centre, Davangere,
Karnataka, India

Manjunath J
Department of Orthopaedics, SS
Institute of Medical Sciences and
Research Centre, Davangere,
Karnataka, India

Kiran GU
Associate Professor, Department
of Orthopaedics, SS Institute of
Medical Sciences and Research
Centre, Davangere, Karnataka,
India

Druva V
Department of Orthopaedics, SS
Institute of Medical Sciences and
Research Centre, Davangere,
Karnataka, India

Kore Aditya B
Department of Orthopaedics, SS
Institute of Medical Sciences and
Research Centre, Davangere,
Karnataka, India

Corresponding Author:
Kiran GU
Associate Professor, Department
of Orthopaedics, SS Institute of
Medical Sciences and Research
Centre, Davangere, Karnataka,
India

Surgical management of subtrochanteric fractures treated with long proximal femoral nail antirotation 2 (PFN-A2)

Sachin NS, Manjunath J, Kiran GU, Druva V and Kore Aditya B

DOI: <https://doi.org/10.22271/ortho.2020.v6.i11.1943>

Abstract

Background: Subtrochanteric fractures of the femur remain some of the most challenging fractures facing orthopaedic surgeons. Most of the fractures in the elderly results from trivial fall from standing or walking, while in the younger age group it's mainly due to road traffic accidents. Closed management of these subtrochanteric fractures thus poses difficulties in obtaining and maintaining a reduction, making operative management the preferred treatment. Therefore, this has led to the development of intramedullary devices in the management of subtrochanteric fractures.

Objective: To analyze functional outcome of Subtrochanteric fractures by proximal femoral nail antirotation A2 (PFN-A2).

Materials and Methods: A prospective study with 20 adult patients with subtrochanteric fractures according to Seinsheimer's classification were treated with proximal femoral nail antirotation-2 (PFN-A2) in SSIMS, Davangere from October 2017 and March 2019. All the cases were followed at regular intervals as per our study protocol. The functional outcome were assessed with Modified Harris Hip Score.

Results: In the present study, 20 subtrochanteric fractures underwent surgical fixation with proximal femoral nail antirotation 2 (PFN-A2). According to Modified Harris Hip scores, out of 20 cases, the functional outcome were excellent in 5 cases (25.00%), good in 11 cases (55.00%), fair in 3 cases (15.00%) and poor in 1 case (5.00%).

Conclusion: We conclude that the proximal femoral nail antirotation 2 (PFN-A2) was an ideal and reliable implant for subtrochanteric fractures, leading to high rate of bone union, reducing the chances of implant failure and decreasing the post-operative morbidity by improving the functional quality of life.

Keywords: Subtrochanteric fractures, PFN-A2, seinsheimer's classification, cephalomedullary

Introduction

Subtrochanteric fractures are femoral fractures where the fractures occur below the lesser trochanter to 5 cm distally in the shaft of femur [1]. These fractures occur typically at the junction between trabecular bone and cortical bone where the mechanical stress across the junction is highest in the femur, which is responsible for their frequent comminution. These fractures account for 10% to 34% of all hip fractures [2].

These fractures occur typically in two age groups. In young and healthy individuals, the injury results from high-energy trauma, whereas in the elderly population, most of the fractures are osteoporotic, resulting from a fall. With the increase in the aging population, there is also considerable growth in the number of pathological fractures and fractures around hip prostheses (periprosthetic fractures) [1].

Subtrochanteric region is usually exposed to high stresses during activities of daily living. Axial loading forces through the hip joint create a large moment arm, with significant lateral tensile stresses and medial compressive loads. In addition to the bending forces, muscle forces at the hip also create torsional effects that lead to significant rotational shear forces. During normal activities of daily living, up to 6 times the body weight is transmitted across the subtrochanteric region of the femur.

As a result of these high forces, the bone in this region is a thick cortical bone with less vascularity and results in increased potential for healing disturbances.

Hence subtrochanteric fracture is difficult to manage and associated with many complications.

Closed management of these subtrochanteric fractures thus poses difficulties in obtaining and maintaining a reduction, making operative management the preferred treatment. The goal of operative treatment is restoration of normal length and angulation to restore adequate tension to the abductors^[3]. The obvious advantages of operative treatment are namely a) avoidance of complications of prolonged bed rest and hospitalization, b) accurate reduction and anatomical alignment and c) early mobilization and weight bearing, is possible with new implants and fixation technology^[1].

The two primary options for treatment of subtrochanteric fractures are intramedullary fixation and extramedullary fixation^[3]. Many internal fixation devices have been recommended, but because of high incidence of complications like non-union and implant failure, a series of evolution in designing a perfect implant has begun. Only recently better understanding of biology, reduction techniques and biomechanically improved implants like Gamma nail, Russell Taylor nail, Proximal femoral nail allowed for these fractures to be addressed with consistent success. This study was done to analyze the functional outcome of surgical management of subtrochanteric fractures by PFN-A2.

Materials and Methods

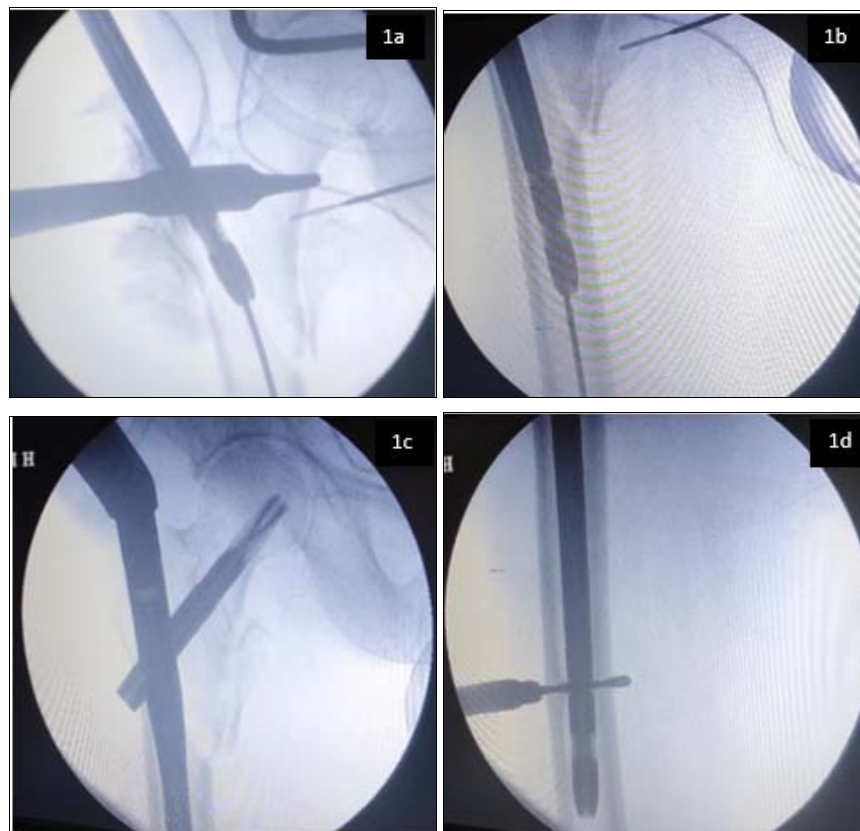

Fig 1: Surgical technique of PFN-A2 for subtrochanteric fracture

All the patients were advised to completely weight bearing after 10 – 12 weeks of post operative period. All patients were followed up at the end of 1, 2, 6 and 12 months. At each follow up, the radiographs of upper femur and hip were taken

With a level IV evidence, a prospective study was carried out from October 2017 and March 2019 in department of Orthopaedics, SS Institute of Medical Sciences & Research Centre, Davanagere, Karnataka. A total of 20 patients with subtrochanteric fractures were treated surgically by proximal femoral nail – A2 and were followed up at the immediate post op period and at the end of 1, 2, 6 and 12 months and evaluated for functional outcome using Modified Harris Hip score.

Patients who were in the age group from 30 – 70 years of age, patients with clinically and radiologically diagnosed subtrochanteric fractures as per Seinsheimer's classification were included in the study. Patients who were below 30 and above 70 years of age, patients with subtrochanteric fracture type 5 as per Seinsheimer's classification, patients with compound fractures, pathological fractures and fractures over ipsilateral lower limb and patients with neck of femur and shaft of femur fractures were excluded from the study.

After getting IEC and informed & written consent from the patients and attenders, the patients enrolled in the study were subjected for thorough clinical examination. The baseline investigations and radiographic analysis such as plain X ray of the affected hip with proximal femur were analysed. All the cases were posted for surgical management with closed or open reduction with PFN-A2 and followed up according to our study protocol.

to assess the fracture union and the complications. The functional results were calculated according to Modified Harris hip score.

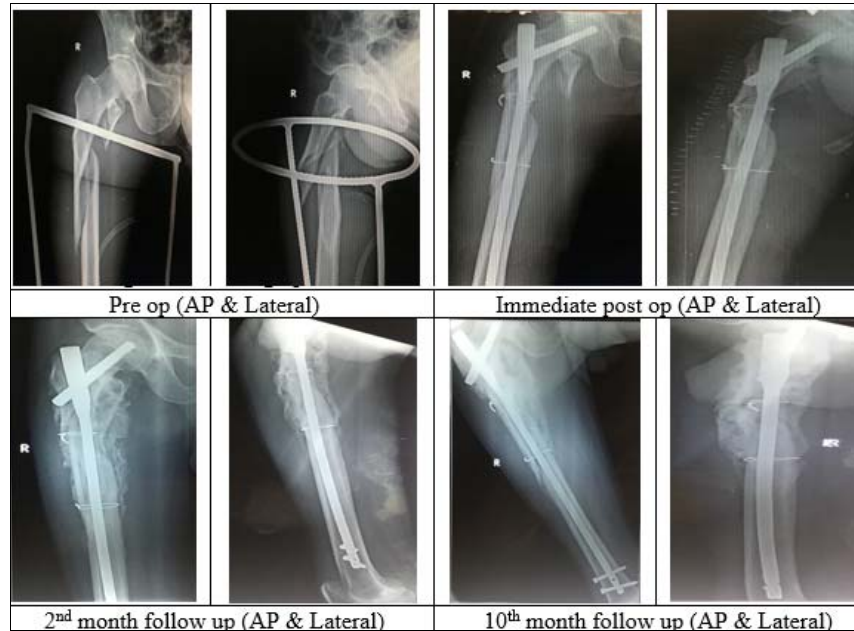

Fig 2: Radiographs of subtrochanteric fracture fixed with PFN-A2

Results

A total of 20 cases of subtrochanteric fractures underwent surgical management with proximal femoral nail antirotation 2 (PFN-A2) as per our study protocol. The descriptive statistics were reported as mean (SD) for continuous variables, frequencies (percentage) for categorical variables. Data were statistically evaluated with IBM SPSS Statistics for Windows, Version 24.0, IBM Corp, Chicago, IL. Among 20 cases, 13 cases (65.00%) were males and 7 cases (35.00%) were females. The maximum age limit in the study was 69 years and minimum age was 33 years. The mean (\pm SD) age of the patients were 47.81 ± 3.61 years. A total of 11 cases (55.00%) sustained injury due to road traffic accident and 9 cases (45.00%) due to fall from height.

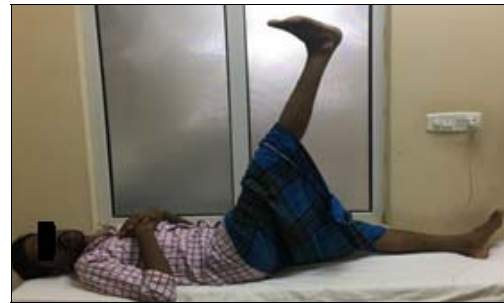

Fig 3c: Hip flexion with knee extension

Fig 3a, b, and c: Clinical outcome in patient with subtrochanteric fracture fixed with PFN-A2



Fig 3a: Hip flexion with knee flexion

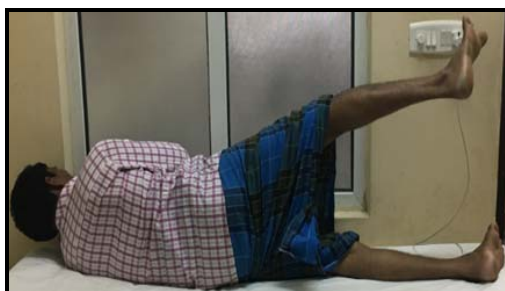

Fig 3b: Abduction

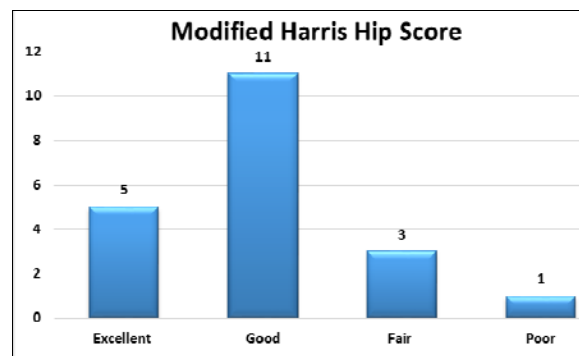


Fig 4: Functional outcome of Subtrochanteric fracture

According to Seinsheimer’s classification, the pattern of fractures were type 1 in 3 cases (15.00%), type 2 in 6 cases (30.00%), type 3 in 6 cases (30.00%) and type 4 in 5 cases (25.00%). A total of 12 cases (60.00%) were operated with CRIF with PFN-A2 and 8 cases (40.00%) underwent ORIF with PFN-A2. The mean radiological union of subtrochanteric fractures were 11.74 ± 2.93 weeks. Out of 20 cases, 1 case (5.00%) showed signs of established non-union after 9

months of post procedure with PFN-A2 which was counselled for bone grafting. The complications associated in our study were pain 4 cases (20.00%), non-union 1 case (5.00%) and varus angulation 1 case (5.00%). According to Modified Harris Hip scores, out of 20 cases, the functional outcome were excellent in 5 cases (25.00%), good in 11 cases (55.00%), fair in 3 cases (15.00%) and poor in 1 case (5.00%).

Discussion

Unlike osteoporotic trochanteric fractures, subtrochanteric fractures are usually the result of high-energy trauma and often subjected to significant displacement and great difficulty in close reduction through traction. The high incidence of delayed union, malunion and non-union of fractures has left conservative treatment, as advocated by DeLee *et al*, abolished in modern trauma care^[4].

Extra medullary fixation with plating has the potential disadvantages of extensive surgical exposure, severe soft tissue damage and blood loss, thus leading to problems of fracture union and implant failure. In addition, the eccentrically plating is prone to fatigue breakage due to their mechanical load-sharing effect. Allowing a minimally open approach, intramedullary nailing is closely linked to "biological internal fixation", in addition to its mechanical benefits over plate fixation. Intramedullary fixation allows the surgeon to minimize soft tissue dissection thereby reducing surgical trauma, blood loss, infection, and wound complications^[5, 6, 7].

Cephalo-medullary femoral reconstruction nails with a trochanteric entry point are biomechanically stronger than extramedullary implants^[8]. The recent implant for management of subtrochanteric fracture was proximal femoral nail antirotation-2. PFN-A2 has advantages over PFNA in following ways: a) the proximal nail diameter was reduced from 17mm to 16.5mm, b) the medio-lateral angle was reduced from 6 degree to 5 degree and c) a flat proximal lateral surface was adapted to avoid impingement of femoral lateral cortex^[9, 10].

Lei Sheng *et al*. concluded long PFN or long gamma nail are the implants of choice in the fixation of subtrochanteric fractures in 49 patients with good bony union at the fracture site with minimal complications^[11]. Werner *et al*. detected 5 cases of Z effect (7.1%) in 70 cases of per and subtrochanteric fractures managed by PFN. They referred Z-effect phenomenon as a characteristic sliding of the proximal antirotation and compression screws to opposite directions during the postoperative weight-bearing period^[12]. Boldin *et al* observed 3 cases of Z effect and 2 cases of reverse Z effect in 55 patients of unstable intertrochanteric or subtrochanteric fractures by PFN. They coined reverse Z-effect as an event occurred with movement of the hip pin towards the lateral side, which required early removal^[13].

In our study, a cephalo-medullary proximal femoral nail antirotation-2 (PFN-A2) for subtrochanteric fractures were used. These nails prevent the rotation and collapse of the head-neck fragment and smaller diameter of distal shaft of nail results in less stress concentration at the tip of the nail. The antirotation screw at the proximal aspect of nail increases the biomechanical stability of the fracture fixation. According to Modified Harris Hip scores, out of 20 subtrochanteric fracture cases, the functional outcome were excellent in 5 cases (25.00%), good in 11 cases (55.00%), fair in 3 cases (15.00%) and poor in 1 case (5.00%). PFN-A2 have the biological advantages in terms of restoration of abductor-

lever-arm mechanism, decreased tensile strain on the implant and maintenance of controlled fracture impaction. Limitations of the study were smaller sample size, limited duration of post operative follow up to comment on biomechanical stability of the implant and no control group for comparison.

Conclusion

Subtrochanteric fractures pose a great challenge for orthopaedic surgeons to manage surgically. We conclude that the proximal femoral nail antirotation 2 (PFN-A2) is an ideal implant for subtrochanteric fractures, leading to high rate of bone union restoring the lateral femoral wall, reducing the chances of implant failure and decreasing the post-operative morbidity by improving the functional quality of life. The key to the success of treatment of these complex fractures is near anatomical reduction of fracture by closed, mini open or open reduction of the fracture prior to nailing.

Acknowledgements: Nil

Conflicts of interest: Nil

Funding sources: Nil

References

1. Toni M, Mclaunn Ericka A. Lawler: Treatment Modalities for Subtrochanteric Fractures in Elderly. Techniques in Orthopaedics. 2004; 19(3):197-213.
2. Tyllianakis M, Panagopoulos A, Papadopoulos A, Pappasmos S, Mousafiris K. Treatment of extracapsular hip fractures with the proximal femoral nail (PFN): long term results in 45 patients. Acta Orthop Belg. 2004; 70:444-454.
3. Klinger HM, Baums HM, Eckert M, Neugebauer R. A comparative study of unstable per and intertrochanteric femoral fractures with DHS and PFN and TSP. Zentralbl Chir. 2005; 130(4):301-6.
4. Franco Lavini *et al*. The treatment of stable and unstable proximal femoral fractures with a new trochanteric nail: result of a multicentre study with the Veronail. Strat Traum recon.2008; 3:1522.
5. Macheras GA, Koutsostathis SD, Galanakos SP, Kateros K, Papadakis SA. Reply to letter to the editor: Does PFNA II avoid lateral cortex impingement for unstable pertrochanteric fractures? Clin Orthop Relat Res. 2013; 471:1395-6.
6. Loo WL, Loh SYJ, Lee HC. Review of Proximal Nail Antirotation (PFNA) and PFNA-2—Our Local Experience. Malaysian Orthopaedic Journal. 2001; 5:1-5.
7. Gotfried Y. The lateral trochanteric wall: a key element in the reconstruction of unstable pertrochanteric hip fractures. Clin Orthop Relat Res. 2004; 425:82-86.
8. Linga SS, Aithala JP, Savur A. Can proximal femoral nailing of unstable trochanteric fractures help to regain pre-injury functional status in Indian rural patients? A prospective study of functional outcome of unstable intertrochanteric fractures with proximal femoral nailing. Int J Res Orthop. 2017; 3:728-33.
9. Paul Tornetta, William Ricci, Charles M. Court-Brown, Margaret M, McQueen *et al*. Rockwood and Green Fractures in Adults 8th edition, chapter, 50, 2705.
10. Palm H, Jacobsen S, Sonne-Holm S. Hip fracture study group. Integrity of the lateral femoral wall in intertrochanteric hip fractures: an important predictor of a reoperation. J Bone Joint Surg Am. 2007; 89(3):470-475.

11. Wasudeo MG, Bhaskaran Shivashankar, Vijayanand Lokhande, Yogesh Salphale. Augmentation of proximal femoral nail in unstable trochanteric fractures. SICOT J. 2017; 3(12):1-9.
12. Werner-Tutschku W, Lajtai G, Schmiedhuber G, Lang T, Pirkl C, Orthner E. Intra- and perioperative complications in the stabilization of per- and subtrochanteric femoral fractures by means of PFN. Unfallchirurg. 2002; 105:881-5.
13. Boldin C, Seibert FJ, Fankhauser F, Peicha G, Grechenig W, Szyszkowitz R *et al.* The proximal femoral nail (PFN) - A minimal invasive treatment of unstable proximal femoral fractures: a prospective study of 55 patients with a follow-up of 15 months. Acta Orthop Scand. 2003; 74(1):53-8.