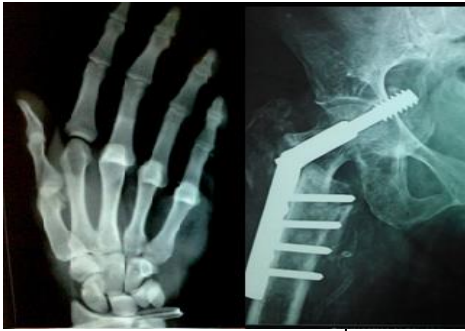

International Journal of Orthopaedics Sciences

E-ISSN: 2395-1958
P-ISSN: 2706-6630
IJOS 2020; 6(1): 647-652
© 2020 IJOS
www.orthopaper.com
Received: 01-11-2019
Accepted: 05-12-2019

Dr. Rajesh Kumar Sharma
Senior Resident, Department of
Orthopaedics, SMS Medical
College, Jaipur; 64, Nayawasi
Street- Sarundla, Achalpur,
Dausa, Rajasthan, India

Dr. Arun Kumar Sharma
Assistant Professor, Department
of Orthopaedics, SMS Medical
College, Jaipur; A-176,
Shivshakti Nagar, Model town,
Jagatpura, Jaipur, Rajasthan,
India

Dr. Avtar Singh Balawat
Assistant Professor, Department
of Orthopaedics, SMS Medical
College, Jaipur; 2/2,
Heerabagh Flats, Narayan Singh
Circle, Jaipur, Rajasthan, India

Dr. Vishal Sekhawat
Assistant Professor, Department
of Orthopaedics, SMS Medical
College, Jaipur; 27, Nand
Vihar Colony, Amrapali marg,
Vaishali Nagar, Jaipur,
Rajasthan, India

Corresponding Author:
Dr. Rajesh Kumar Sharma
Senior Resident, Department of
Orthopaedics, SMS Medical
College, Jaipur; 64, Nayawasi
Street- Sarundla, Achalpur,
Dausa, Rajasthan, India

Comparison between simultaneous versus staged bilateral total hip arthroplasty in patients with painful disabling bilateral hip diseases: A prospective, randomized, controlled study

**Dr. Rajesh Kumar Sharma, Dr. Arun Kumar Sharma, Dr. Avtar Singh
Balawat, and Dr. Vishal Sekhawat**

DOI: <https://doi.org/10.22271/ortho.2020.v6.i11.1937>

Abstract

Background: It's always a burning debate, whether a simultaneous or staged bilateral Total Hip Arthroplasty (THA) should be performed for patients with painful disabling bilateral hip diseases. Although, many studies now indicate that the treatment option should be patient specific to achieve the maximum efficiency without increasing risk of perioperative complications. The purpose of this study to compare simultaneous vs staged procedure in order to determine the functional outcomes, risks and benefits of each procedure.

Materials and Methods: Our study includes total 80 patients (160 hips) with advanced bilateral hip diseases, underwent simultaneous or staged bilateral THA during 2015 to 2019. Study population was randomly divided into two groups with 40 patients in each one. The post-op evaluations were done according to Harris Hip Score (HHS) at one, three, six and 12 months and yearly thereafter for 2 years. The second procedure in staged group was done at 6 weeks to 3 months interval. All possible outcomes and complications regarding each procedure were accessed.

Results: As compared to staged procedure, estimated blood loss was significantly less in simultaneous THA (group A). Although, requirement of blood transfusion was significantly higher in this group. The length of hospital stay was significantly shorter in group A. Although, overall complication rate was higher in group A but it was statistically not significant. Superficial surgical site infection was significantly lower in simultaneous THA group. There was no post-op dislocation, no in-patient mortality and no need of revise the surgery in any of our study group within 2 years of follow-up.

Conclusion: With proper patient selection, simultaneous bilateral THA is safe, effective and good alternative to staged procedure for painful disabling bilateral hip diseases.

Keywords: Total Hip Arthroplasty (THA), simultaneous bilateral THA, staged bilateral THA, harris hip score (HHS)

1. Introduction

Total Hip Arthroplasty (THA) is considered as one of the most effective and cost-beneficial surgical treatment for painful disabling hip diseases like osteoarthritis, avascular necrosis, rheumatoid arthritis, developmental dysplasia of hip, juvenile rheumatoid arthritis and others^[1,2]. Most of these diseases have bilateral association with estimated prevalence^[3] of 42% to 50%. A bilateral procedure is required in approximately 15% to 25% of patients, chosen between either doing the two surgeries simultaneously or staged surgeries by 6 to 12 weeks interval between two procedures, for rehabilitation and the functional recovery to return to baseline^[4]. The staging or optimum time of surgery in patients requiring bilateral THA is controversial and has been part of ongoing debate^[5]. The purpose of this study was to compare the results of peri-operative and post-operative findings and complications (within 2 years) in patients with simultaneous bilateral THA (during single admission and single anaesthetic) versus staged bilateral THA (during two different hospitalizations and two anaesthetics) in a prospective, randomized controlled trial.

2. Materials and Methods

This study was carried out in department of Orthopaedics, SMS Medical College, Jaipur (Rajasthan) during the years 2015 to 2019. A prospective, randomized, controlled study was designed after obtaining approval of our institutional ethics committee. A sample size of 80 patients (160 hips), met with inclusion criteria, was taken for study purpose. Written informed consent was taken from all patients about the nature of surgery, potential benefits and possible complications. Study population was further divided randomly using sealed envelopes on the day preceding the surgery to have simultaneous (Group A) or staged bilateral THA (Group B). Randomly, 40 patients (80 hips) were allotted in each group. An interval ranging from 6 to 12 weeks was taken between the two surgeries in group B (staged bilateral THA) in order to return physiological parameters to baseline and for rehabilitation.

Inclusion criteria: Patients with advanced bilateral osteoarthritis of hip with significant bilateral flexion contracture, patients with low risk of anaesthesia that was ASA score ^[6] (American Society of Anaesthesiologist) grade 1 & 2, and willingness to participate in the study.

Exclusion criteria: Patients with ASA score- grade 3 & 4, significant involvement of the knee and/or spine, revision THA, and patients who were unwilling to undergo simultaneous bilateral THA.

All demographic data (age, sex, etiological distribution) of patients were comparable in the both the groups (Table 1, and Figure 1).

2.1 Surgical technique

In order to eliminate potential bias related to the surgical technique, all patients underwent bilateral THA with same arthroplasty surgeon's team. Similar preoperative and postoperative protocols were followed in both groups. Same type of intraoperative antibiotics and postoperative venous thromboembolism prophylaxis was administered to all patients of both the groups. All patients were catheterised for urine output calculation, which was removed 48 hours after surgery.

All the surgeries were performed under combined epidural spinal anaesthesia in a laminar airflow operating room. Posterior (Southern) approach was used in all patients for performing the surgery. The patient was placed in a lateral position and the more painful hip was operated first. In simultaneous bilateral THA group, after completing the first hip, the position was changed and the contralateral side was then operated. In both the groups the decision of cemented or cementless fixation was made depending upon the quality of the bone stock and the age of the patient. All patients with good bone stock and less than 65 years of age (56 hips in the simultaneous group and 54 hips in the staged group) underwent cementless total hip arthroplasty (Harris Galante II and Versys Trilogy; Zimmer, DePuy, & Stryker). A cemented procedure using a CPT femoral stem and ZCA cup (Zimmer) was used in the rest of the patients (24 hips in the simultaneous group and 26 hips in the staged group). A third-

generation cementing technique was used in the cemented hips. The press-fit technique of insertion of the acetabular shell involved under-reaming of the acetabulum by 2 mm before impaction of the implant prior to supplementary fixation by one or two screws in most cases. At the time of standard closure, one suction drain was placed in each hip for post-operative drainage.

To reduce peri-operative blood loss, tranexamic acid was given intravenously after the incision (15 mg/kg) and then 6 hourly (10 mg/kg) for next 12 hours in both groups. Each patient of both groups received 1 g of Ceftriaxone intravenously 30 minutes prior to the surgical incision followed by 1 g twice daily postoperatively for one week. Subcutaneous LMW heparin (40 mg once daily) was given to all patients from the day of surgery to 5 days postoperatively for the prophylaxis of deep vein thrombosis (DVT). Oral aspirin (150 mg once daily) was given for three to four weeks after the discontinuation of Subcutaneous LMW heparin. D-dimer test and Doppler ultrasonography was carried out in postoperative patients, if DVT was suspected.

The surgical time, perioperative blood loss and length of hospital stay in both groups were recorded. Post-operatively, the hematocrit was measured at eight hours and the hemoglobin levels on the first, second and third post-operative days. Blood transfusion requirement was assessed according to intra-operative blood loss, clinical and hematological parameters in both the groups.

Early mobilisation was done both to prevent DVT and to improve functional recovery. Patients were made to stand on day 1 following surgery. Full-weight-bearing walk was started from post-op day 2 in all patients even in uncemented hips, except those with perioperative complications. All the patient were discharged once there was no pain at wound site with no sign of surgical site infection.

2.2 Post-operative follow-up

The patients had clinical and radiological evaluation at one, three, six and 12 months and yearly thereafter for 2 years following a simultaneous bilateral THA group (A) and the second procedure in the staged bilateral THA group (B). In each follow-up, any complications like anterior thigh pain, dislocation, fracture were recorded.

For clinical evaluation Harris hip scoring (HHS) system⁷ was used. They then carried out a timed 10-metre walking test to assess walking speed, examining the overall time to walk ten metres and the time to walk the middle six metres. The use of any walking aid was also noted. Time taken by the patients for walk without support and use of public transportation was also recorded. Fixation of components, loosening, osteolysis and heterotrophic ossification were ruled out in radiological evaluation of hips.

2.3 Statistical analysis

Statistical analysis was undertaken using SPSS v10.0 and MS Excel 2013. Continuous baseline variables were compared using the Student t-test, and categorical variables using chi-squared test. The measurements were expressed as mean (and standard deviation) for continuous variables and percentages for categorical variables. The level of significance applied was 95.0%, when p- value < 0.05.

Table 1: Showing randomized demographic distribution between simultaneous and staged bilateral THA groups.

	Simultaneous Group (A)	Staged Group (B)
Total Patients	40 (80 Hips)	40 (Hips)
Male: Female ratio	15:25	17:23

	Mean Age (years)	47.63 (range 16 to 64)	48.71 (range 17 to 66)
Etiological distribution	B/L Osteoarthritis (OA)	16 (40%)	18 (45%)
	B/L Avascular Necrosis (AVN)	13 (32.5%)	14 (35%)
	B/L Rheumatoid Arthritis (RA)	7 (17.5%)	5 (12.5%)
	B/L Developmental Dysplasia of hip (DDH)	2 (5%)	2 (5%)
	B/L Juvenile Rheumatoid Arthritis (JRA)	2 (5%)	1 (2.5%)

*B/L: Bilateral

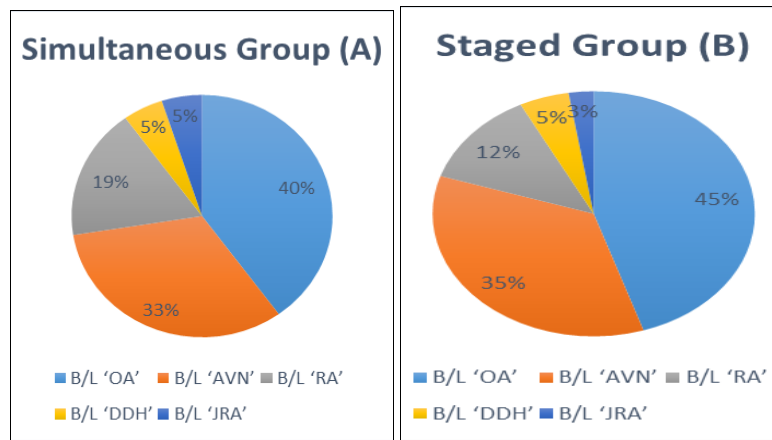


Fig 1: Pie chart showing randomized etiological distribution of patients in simultaneous and staged bilateral THA groups.

3. Results

In our study, the mean surgical time in group A (simultaneous bilateral THA) and group B (staged bilateral THA) were 191.55 and 205.13 minutes, respectively and this difference was not statistically significant (*p-value* 0.1748). The mean estimated blood loss in group A was 845.73 ml and in group B was 1230.45 ml, and the difference was statistically significant (*p-value* <0.0001). The mean blood transfusion for group A & group B were 2.29 and 1.72 units, respectively and the difference was statistically significant (*p-value* <0.0001). In this study, the mean length of hospital stay was 5.5 days for 'simultaneous bilateral THA' group and 8.9 days for 'staged bilateral THA' group. The differences in mean length of

hospital stay was statistically significant (*p-value* < 0.0001). [Table 2, and Figure 2]

Comparative clinical evaluation of pre-op & post-op mean values of 'Harris Hip Score (HHS)' at 1 year in both groups are shown in 'Table 3, and Figure 3'.

Although, overall complication rate was higher in group A, but it was statistically not significant. Overall complications within 2 years of surgery, their managements, and final outcomes in both groups are shown in 'Table 4'.

Radiological and clinical evaluations following the simultaneous bilateral THA at 6 months follow-up are also shown in 'Figure 4'.

Table 2: Showing various outcomes of patients in simultaneous and staged bilateral THA groups.

	Bilateral THA		<i>p-value</i>
	Simultaneous (Group A)	Staged (Group B)	
Mean Surgical Time (min)	191.55	205.13	0.1748
Mean Estimated Blood Loss (ml)	845.73	1230.45	<0.0001
Mean blood transfusion (units)	2.29	1.72	<0.0001
Mean Length of hospital stay (days)	5.5	8.9	<0.0001

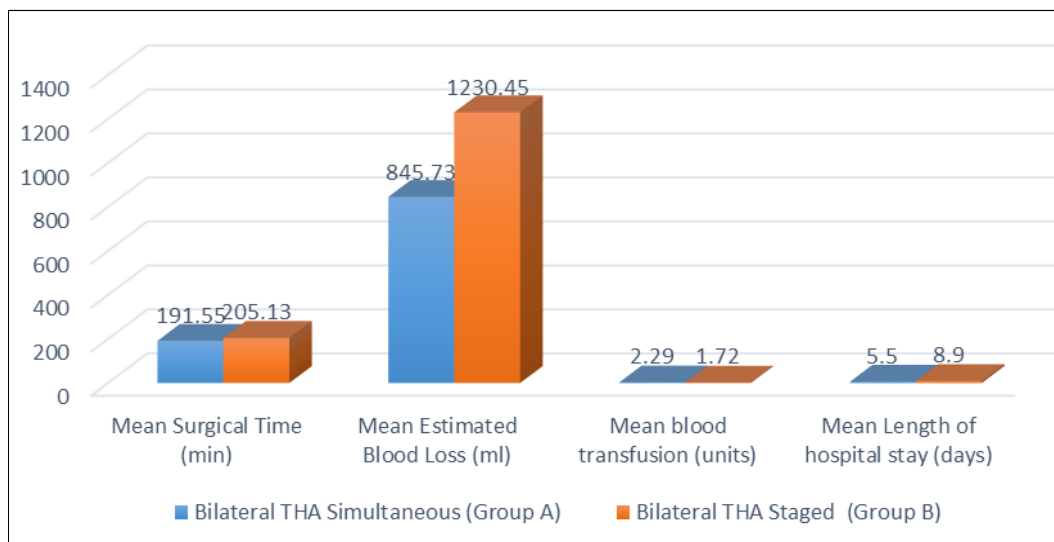


Fig 2: Graph showing various outcomes of patients in simultaneous and staged bilateral THA groups.

Table 3: Showing clinical evaluation by comparing pre-op and post-op (1 year) mean values of Harris Hip Score (HHS) in both groups.

	Bilateral THA		p-value
	Simultaneous (Group A)	Staged (Group B)	
Pre-op HHS*	44.1	42.8	0.3294
Post-op HHS (at 1 year)	91.3	89.5	0.2179

*HHS: Harris Hip Score

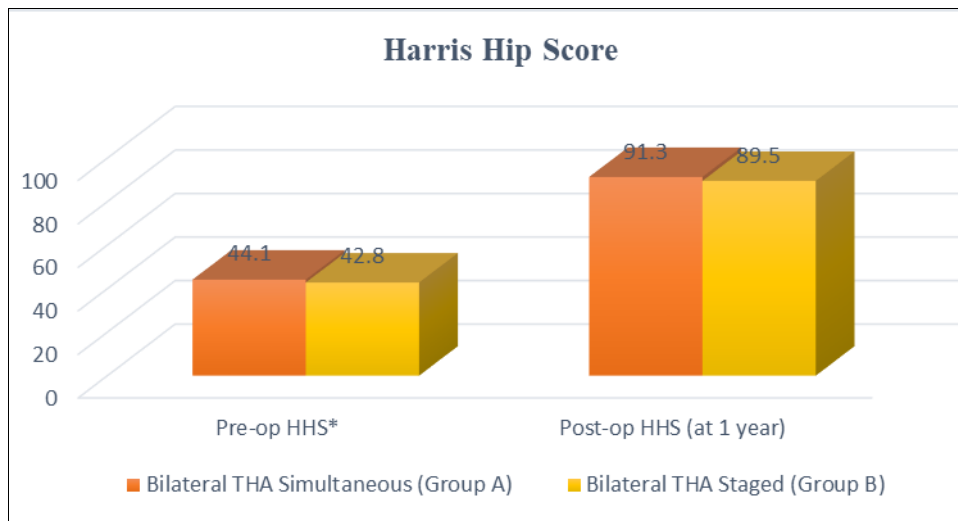


Fig 3: Graph showing clinical evaluation by comparing pre-op and post-op (1 year) mean values of Harris Hip Score (HHS) in simultaneous and staged bilateral THA group.

Table 4: Showing overall complications within 2 year of surgery, their management, and final outcome in simultaneous and staged bilateral THA groups.

Complications	Bilateral THA		Management	Final Outcome
	Simultaneous (Group A)	Staged (Group B)		
Periprosthetic fracture femur (Intraoperatively)	1	1	Strengthen with cerclage wires	No residual complications
Periprosthetic fracture acetabulum	None	None	-	-
Transient sciatic nerve palsy	2	1	Treated medically	Resolved completely
Superficial wound infection	1	2	Oral antibiotics	Resolved completely
Deep wound infection	None	None	-	-
Pulmonary embolism	2	None	Anticoagulation	Complete Recovery
Deep vein thrombosis	3	1	Anticoagulation	Successfully treated
Urinary Tract Infection	1	2	Antibiotics	No residual complications
In-patient mortality*	None	None	-	-
Dislocation	None	None	-	-
Heterotopic ossification (within 2 years)	None	None	-	-
Revision of surgery (within 2 years)	None	None	-	-

(*In-hospital mortality: mortality due to any reason during hospitalization for Bilateral THA)

3.1 Follow-up evaluation

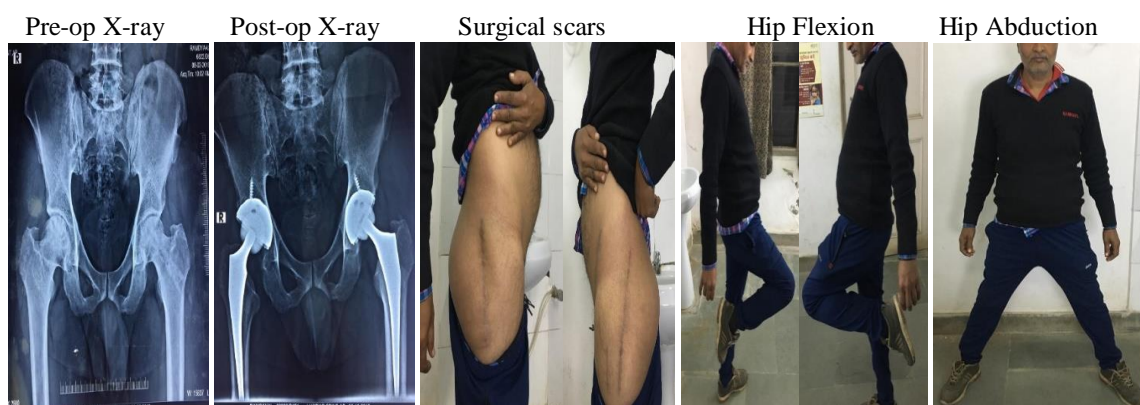

Fig 4: Radiological and clinical evaluation following a simultaneous bilateral THA at 6 months postoperatively.

4. Discussion

Although THA is considered a safe and effective procedure

with acceptable rate of complications, but in case of patient with bilateral hip disease, performing either simultaneous or

staged procedure is still controversial [8, 9]. Simultaneous bilateral THA was initially reported by Charnley in 1967, demonstrating good functional outcomes [10]. According to previous literature, indications of bilateral THA performing as simultaneous or staged procedure cannot be generalised and meticulous patient selection affects the outcomes of surgery [4, 11].

In our study, mean surgical time was less (191.55 min vs 205.13 min) in patients with simultaneous procedure (group A) as compare to staged procedure (group B), although this difference was statistically not significant between the two groups. Less surgical time was associated with lower risk of surgical site infection and anaesthesia related complications. The mean estimated blood loss was significantly lower (845.73 ml vs 1230.45 ml) in simultaneous group. We found that post-op clinical and hematological parameters (hematocrit & Hb levels) were noticeably lower in group A patients, so the mean blood transfusion requirements were significantly higher in this group (2.29 units vs 1.72 units). In the staged group, two procedures were carried out with a physiological recovery interval of 6 weeks to 3 months. It significantly reduces the requirement of blood transfusion in these patients. The mean length of hospital stay was significantly shorter in group A (5.5 days vs 8.9 days). Shorter hospital stay, one time hospitalization, single anaesthesia session, early rehabilitation, and early return to the work in a working patient would certainly have an impact in reducing combined surgical cost in simultaneous bilateral THA. These findings are comparable with the literature [4, 12, 13].

We faced one intra-op complication of periprosthetic fracture femur in each study group that was successfully managed with 2 cerclage wires intraoperatively. Transient sciatic nerve palsy seen in 2 patients of group A and in 1 patient of group B. It was treated medically and complete recovery seen within 6 months after surgery. There was no significant difference in limb length discrepancy and implant positioning in both the groups. In both groups, the Harris Hip Score was similar at 3 months and further follow-ups. Similarly, time to use public transport was same in both study groups. We noticed that risk of superficial wound infection and urinary tract infection were higher in staged procedure. We assumed that multiple hospitalizations and longer hospital stay were significant predictors for such complications. The incidence of DVT and pulmonary embolism (PE) were more in group A. Prolonged surgical time in single sitting of simultaneous bilateral procedure may increases the risk of DVT by causing endothelial damage and stasis of blood. Dislodged thrombus may further leads to PE. Similar rate of complications were reported in the previous studies [14, 15].

Heterotopic ossification was not observed radiologically in any study group. In-patient mortality rate and postoperative dislocation rate was zero in both study groups. Although, the number of patients were probably too small to detect any difference between the groups. Revision of surgery, due to malpositioning, loosening or osteolysis of prosthesis, was not required in any patient of our study group within 2 years of follow-up. However, 2 years follow-up is too early to comment on revision of THA.

In this study, overall systemic and local complications were less. Most of the cases in our study groups were ASA grade 1 or grade 2. This factor was favourable in order to reduce systemic complications. Proper postoperative care, shorter hospital stay and early rehabilitation helped to minimize the local complications.

5. Conclusion

Our study shows that simultaneous bilateral THA, in patients with lower risk group (ASA grade 1 and grade 2), has certain benefits as single hospitalization, single anaesthesia session, less blood loss, shorter hospital stay, early rehabilitation, and reduced combined surgical costs without increase in the overall complication rate within two years of surgery. Although the need for blood transfusion is greater in simultaneous procedure, as compared to staged procedure. So, with proper patient selection, simultaneous bilateral THA is safe, effective and good alternative to staged procedure for painful disabling bilateral hip diseases.

Acknowledgement: None

Declarations

Funding: None

Conflict of interest: Not declared.

Ethical approval: This study was approved by the local ethics committee.

6. References

1. Ibrahim MS, Twaij H, Giebaly DE, *et al.* Enhanced recovery in total hip replacement: a clinical review. *Bone Joint J.* 2013; 95:1587-94.
2. Laupacis A, Bourne R, Rorabeck C, *et al.* The effect of elective total hip replacement on health-related quality of life. *J Bone Joint Surg Am.* 1993; 75:1619-26.
3. Tepper S, Hochberg MC: Factors associated with hip osteoarthritis: Data from the First National Health and Nutrition Examination Survey (NHANES-I). *Am J Epidemiol.* 1993; 137:1081-1088.
4. Alfaro-Adrian J, Bayona F, Rech JA, Murray DW. One- or two-stage bilateraltotal hip replacement. *J Arthroplasty.* 1999; 14:439-45.
5. Agins HJ, Salvati EA, Ranawat CS *et al.* The nine to fifteen year follow-up of one stage bilateral total hip arthroplasty. *Orthop Clin North Am.* 1988; 19:517-530.
6. Dripps RD. New classification of physical status. *Anesthesiology.* 1963; 24:111-117.
7. Kim YH, Kim JS, Oh SH *et al.* Comparison of porouscoated titanium femoral stems with and without hydroxyapatite coating. *J Bone Joint Surg Am.* 2003; 85:1682-8.
8. Tsiridis E, Pavlou G, Charity J, Tsiridis E, Gie G, West R. The safety and efficacy of bilateral simultaneous total hip replacement: an analysis of 2063 cases. *J Bone Joint Surg Br.* 2008; 90:1005e12.
9. Babis GC, Sakellariou VI, Johnson EO, Soucacos PN. Incidence and prevention of thromboembolic events in one stage bilateral total hip arthroplasty: a systematic review. *Curr Vasc Pharmacol.* 2011; 9:24e32.
10. Lazansky M: A Study of Bilateral Low- Friction Arthroplasty. Internal Publication No. 3. Appley Bridge, UK: Centre for Hip Surgery, Wrightington Hospital, September, 1967.
11. Shao H, Chen CL, Maltenfort MG, Restrepo C, Rothman RH, Chen AF. Bilateral total hip arthroplasty: 1-stage or 2-stage? A meta-analysis. *J Arthroplasty.* 2017; 32:689e95.
12. Salvati EA, Hughes P, Lachiewicz P. Bilateral total hip-replacement arthroplasty in one stage. *J Bone Joint Surg [Am].* 1978; 60-A:640-4.
13. Bhan S, Pankaj A, Malhotra R. One or two-stage bilateral total hip arthroplasty: a prospective, randomised, controlled study in an Asian population. *J Bone Joint*

Surg Br. 2006; 88:298-303.

14. Ritter MA, Stringer EA. Bilateral total hip arthroplasty: a single procedure. Clin Orthop. 1980; 149:185-90.
15. Bracy D, Wroblewski BM. Bilateral Charnley arthroplasty as a single procedure: a report on 400 cases. J Bone Joint Surg [Br]. 1981; 63-B:354-6.