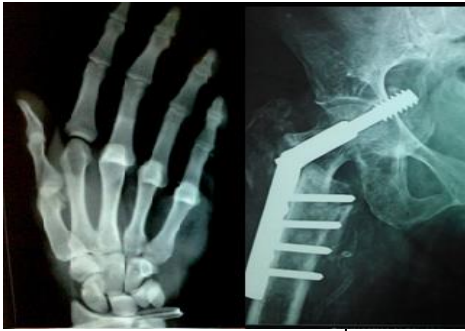

# International Journal of Orthopaedics Sciences

E-ISSN: 2395-1958  
P-ISSN: 2706-6630  
IJOS 2020; 6(1): 602-605  
© 2020 IJOS  
[www.orthopaper.com](http://www.orthopaper.com)  
Received: 16-11-2019  
Accepted: 20-12-2019

**Dr. Yogesh C Patel**  
Professor, Dept of Orthopaedic,  
Baroda Medical College, SSGH,  
Vadodara, Gujarat, India

**Dr. Ranajitshih Rathod**  
Resident Doctor Dept of  
Orthopaedic, Baroda Medical  
College, SSGH, Vadodara,  
Gujarat, India

## Study of result of postero medial soft tissue release (PMSTR) in congenital talipes equinus varus (CTEV) children with Pirani score

**Dr. Yogesh C Patel and Dr. Ranajitshih Rathod**

**DOI:** <https://doi.org/10.22271/ortho.2020.v6.i1k.1933>

### Abstract

**Specific Objectives:** Congenital talipes Equinovarus (clubfoot) is most common congenital deformity of foot. It can be treated by PONSETI technique with high rate of success but surgery is indicated for rigid deformities that cannot be corrected by serial casting.

In our study, our aim is to assess the outcome of Posteromedial Soft Tissue Release (PMSTR) in child with rigid CTEV by PIRANI score.

**Material and Methods:** Between November 2018 to November 2019, we treated twenty (20) feet with idiopathic CTEV with PMSTR. All children with idiopathic clubfoot will be screened. First trial of CTEV cast will be given upto 3 casts. Child with clubfoot deformity which was not corrected with CTEV cast will be selected. Deformity will be assessed with pre-operative PIRANI score. Blood investigations and clinical examination will be done. Surgically fit child will be posted for POSTEROMEDIAL SOFT TISSUE RELEASE. After operative procedure, correction achieved is measured with immediate post-operative PIRANI score. Then above knee slab is given to patient up to stitch removal (12 days). Then after stitch is removed and above knee POP is applied to maintain correction. Patient is called at hospital at every 15 days. Old cast is removed and correction is assessed with PIRANI score. Below knee POP is applied at every 15 days and PIRANI score is assessed at every 15 days. Parents are encouraged to walk their child with cast. This procedure is followed until satisfactory correction is achieved (Usually 6-8 casts).

**Results:** All 20 feet were treated between 7 months to 48 months age-group children with mean age of 19 months. Postoperatively the patients were followed up for every 15 days upto 6 month and everytime correction is noted with PIRANI score. According to these 20 feet evaluated. Among this, 12 children (60%) having excellent result with final PIRANI score  $\leq 1$ . 4 children (20%) having good result with final PIRANI score  $< 2$ . 4 children (20%) having fair result with final PIRANI score  $> 2$ .

**Conclusion:** From this study, we conclude that all children with Congenital Talipes Equino Varus (CTEV) deformity should be first treated with casting. All patients with a rigid idiopathic clubfoot should be given casts preoperatively, not with a view to achieve complete correction but only to stretch stretch the soft tissues and decrease the chances of post-operative skin breakdown. One stage Postero-medial soft tissue release is an excellent mode of treatment for those children with CTEV deformity which is not corrected by serial casting.

**Keywords:** postero medial, congenital talipes, equinus varus, Pirani score

### Introduction

Idiopathic congenital talipes equinovarus (clubfoot) is a common complex deformity that occurs in approximately one or two per 1000 newborns<sup>[1]</sup>. The long-term goal of treatment is a functional, pain-free, plantigrade foot with good mobility, without calluses and walking with comfortably with normal shoes<sup>[2, 3]</sup>. Treatment of congenital talipes equinovarus (clubfoot) begins as soon as possible with serial casting techniques<sup>[4]</sup> with 20-95% of success rate<sup>[5]</sup>. However in case of failure of serial casting or recurrence, or in whom parents seek medical intervention too late, surgical treatment can be performed. There are different types of surgical procedures according to the remaining deformities ranging from simple posterior release and tendon transfer to extensive procedures like postero-medial release and complete subtalar release<sup>[7]</sup>. Theoretically, as the child becomes older, soft tissues become more contracted and difficult to be a corrected because of long-standing deformity and secondary contractures.

**Corresponding Author:**  
**Dr. Ranajitshih Rathod**  
Resident Doctor Dept of  
Orthopaedic, Baroda Medical  
College, SSGH, Vadodara,  
Gujarat, India

Turco8 reported that the best results from the surgical treatment of congenital clubfoot were obtained in children operated on between ages of one and two year and the thereafter the number of the excellent result diminished as the age at operation increased.

**Materials and Methods**

This study was conducted in the department of orthopedic surgery, Baroda Medical College, Vadodara with twenty (20) feet with rigid idiopathic congenital talipes Equinovarus (CTEV) who were evaluated and operated below the age of 5 years between November 2018 to November 2019.

**Exclusion criteria:** The exclusion criteria were clubfoot secondary to some other disorders such as cerebral palsy, arthrogryposis multiplex congenital, myelodysplasia.

- Inclusion criteria:**
1. Idiopathic clubfoot
  2. Child with rigid deformity of foot which cannot be corrected by 3. corrective cast (Any one of deformity equines, cavus, forefoot adduction, inversion not corrected with consecutive 3 cast).
  3. Neglected clubfoot which is not corrected by casting.

**Operative technique**

The skin was incised horizontally from the base of the first metatarsal to the lateral side of tendo achilles which was lengthened, as were the tendons of tibialis posterior, flexor hallucis longus & flexor digitorum longus using a z-technique. The posterior tibial neurovascular bundle identified & isolated along the entire length of incision. The posterior talofibular & calcaneofibular ligaments, the posterior third of deep deltoid ligament, the superficial deltoid & the talocalcaneal interosseous ligament, the spring ligament & the Y ligament were all divided. Complete release by capsulotomies of ankle, subtalar, talonavicular & first tarsometatarsal joints until mobilization of the ankle, hind foot & mid foot was obtained. In all cases, irrespective of the presence of cavus deformity, a

planter fascia release was performed near its origin flexor digitorum brevis & halluc abductor muscle were also release from their proximal insertion to allow forefoot correction. The ankle joint & subtalar joint, posterior capsule release was necessary to correct hindfoot equinus. Z-plasty done over tendo achillis according to the severity of equines deformity Suture were removed after 12 days followed by manipulation & cast application. Patients were followed post operatively at 15 days regular interval. Post operatively above knee fibre cast is given and patient is encouraged to walk with POP.

Mobilisation with modified above knee fibre cast allows tarsal bone to be realigned at every 15 days old cast is removed and correction is recorded with PIRANI score and new cast is given and this sequence is followed upto 6 to 8 cast.

**Clinical assessment pirani scoring**

The Pirani score is a simple, easy to use tool for assessing the severity of each of the components of a clubfoot. It is extremely useful for assessing the severity of the clubfoot at presentation and for monitoring patients’ progress. The Pirani score should be recorded at each visit the patient makes. If the Pirani score increases from one visit to the next it may indicate that a relapse of deformity is occurring. Information on how to manage relapse can be found here.

The components are scored as follows:

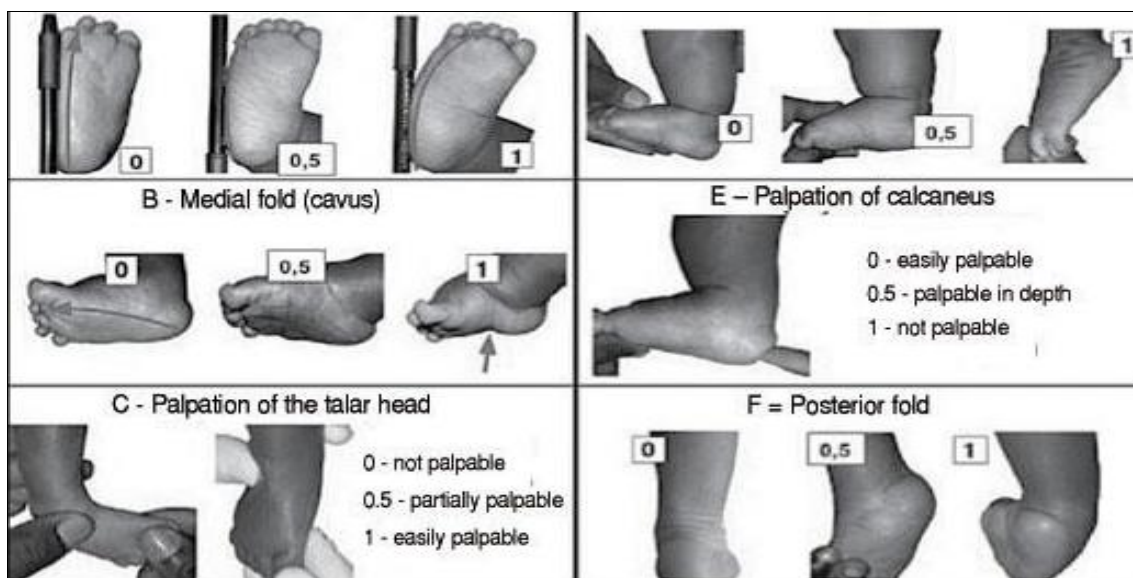
**Pirani scoring**

Each component may score 0, 0.5 or 1  
Hind foot contracture score (HCFS)

1. Posterior crease
2. Empty heel
3. Rigid equinus

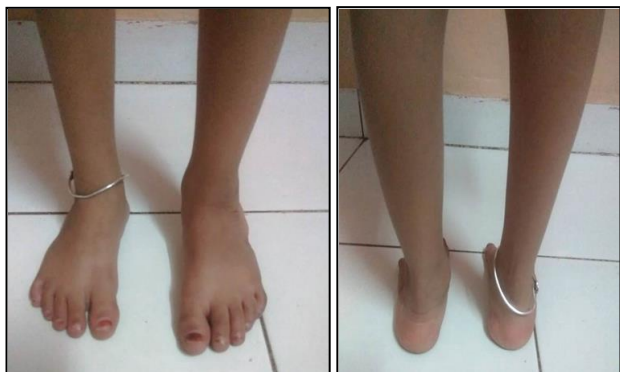**Mid foot contracture score (MFCS)**

1. Medial crease
2. Curvature of lateral border
3. Position of head of talus

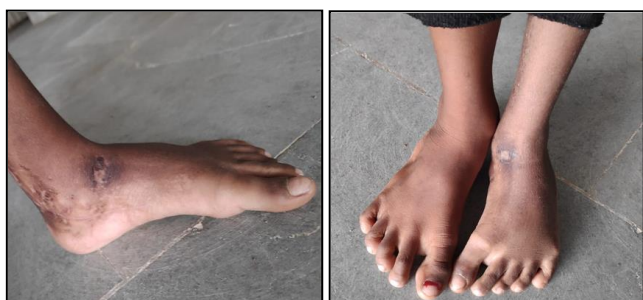

**Fig:** Pirani’s Classification for CC. Source: Pirani and Naddumba 110.

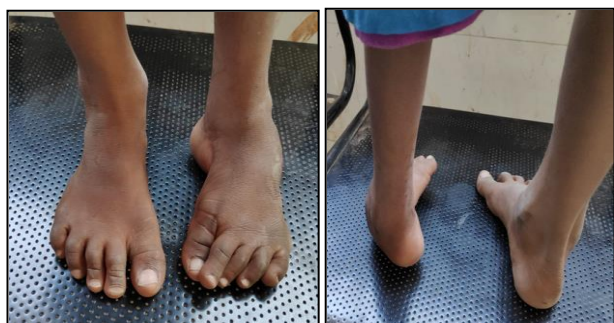**Clinical Image  
Excellent Result**



**Good Result**



**Fair Result**



**Result**

Functional results in 20 feet using Pirani scoring system:

Pre-Operative Pirani Score	No.	Percentage
5-6	11	55%
4 to <5	7	35%
3 to <4	2	10%
TOTAL	20	100%

Immediate Post-Operative Pirani Score	No.	Percentage
3 to <4	5	25%
2 to 3	11	55%
≤2	4	20%
Total	20	100%

Pirani score at final follow up	No.	Percentage
0 to ≤1(Excellent)	12	60%
1 to ≤2(Good)	4	20%
>2(Fair)	4	20%
TOTAL	20	100%

Residual deformity was appreciated clinically in 4 feet. Among the residual deformities, fore foot adduction was there. All feet were considered to have the normal range of

ankle movement and subtalar movement.

- A normal event or power was observed is every feet
- NO one child had gait abnormality and limping.
- Among 20 feet, 12 feet had excellent result, 4 feet had good result and 4 feet had good result.
- Among complication, 4 children having-residual deformity and 5 children were having plaster sore. No any infection found among these children.

**Discussion**

Clubfoot is one of the most common congenital abnormalities of foot. Most of the clubfeet could be very well managed with conservatively using PONSETI technique. It is not still unusual to find untreated or partially treated clubfoot in the scenario of developing countries.

Limitations of conservative treatment are seen in older children when the deformity become rigid and secondary changes start to occur in skeleton of foot. Postero medial soft tissue release is used to treat those children upto 4 years of age. After 4 years of age patient may require bony procedure. The usual problems faced by an orthopaedic surgeon treating the club foot are:

- Conservative treatment versus surgical treatment
- Early surgery versus delayed surgery
- One stage surgery versus two stage surgery

In our study, with the help of our clinical experience and study of literature, we tried to give brief opinion on them.

So from our study, we can conclude that all club feet should be first treated with conservative management (Casting by PONSETI method). But those who are not getting progressive correction with casting (rigid or severe variety) should be treated with surgical management.

So from our study we can conclude that for severe and resistant type of club foot, after initial casting by PONSETI method, surgical management (Posteromedial soft tissue release) should be done between 1-2 years of age for better result.

If surgery is delayed, an outcome may worsen with the age and it becomes difficult to correct and maintain correction of deformity.

We also conclude that for severe and resistant variety of clubfoot after initial casting by PONSETI method, one stage Posteromedial soft tissue release is good method of treatment for achieving better correction.

**Conclusion**

From this study, we conclude that all children with Congenital Talipes Equino Varus (CTEV) deformity should be first treated with casting. All patients with a rigid idiopathic clubfoot should be given casts preoperatively, not with a view to achieve complete correction but only to stretch stretch the soft tissues and decrease the chances of post-operative skin breakdown. One stage Postero-medial soft tissue release is an excellent mode of treatment for those children with CTEV deformity which is not corrected by serial casting. PMSTR should be done between age of 1 to 2 years for excellent result. After this result may worsen as age increases. Among complication, residual deformity is seen in those children who presented to hospital at late age. (3-4 years) without any prior casting.

At the end we can say that PMSTR is an excellent mode of treatment for rigid type of clubfoot which is not corrected by serial casting by PONSETI method.

## References

1. Wynne-Davies R. Family study and the causes of congenital clubfoot: Talipes equinovarus, talipes calcaneal valgus and metatarsus varus. *J Bone Joint Br.* 1964; 46:445-463.
2. Turco VJ. Surgical correction of resistant clubfoot one stage posteromedial soft tissue release. *J Bone Joint Surg.* 1971; 51:477-97.
3. Ponseti IV, Smoley EN. Congenital clubfoot, the results of treatment. *J Bone Joint Surg.* 1963; 45A:261.
4. Handelsman JE, Badalamente MA. Neuromuscular Studies in Clubfoot *J Pediatr Orthop.* 1981; 1(1):23-32.
5. Ritsila VA. Talipes equinovarus and Vertical Tails Produced Experimentally in Newborn Rabbits. *Acta Orthop Scan Suppl.* 1969; 121:1-98.
6. Stewart SF. Clubfoot: Its Incidence, Cause and Treatment. -Anatomical-Physiological Study. *J Bone Joint Surg.* 1951; 33A(3):557-590.
7. Wiley AM. Clubfoot an anatomical and experimental study of muscle growth. *J Bone Joint Surg.* 1959; 41B:821.
8. Irani RN, Sherman MS. The Pathological Anatomy of Clubfoot) *Bone joint Surg.* 1963; 45(1):45-52.
9. Bleck EE. Annotation of Clubfoot. *Develop Med Child Neurol.* 1993; 35:927-930.
10. Diaz VA, Diaz VJ. Pathogenesis of Idiopathic Clubfoot. *ClinOrthop.* 1984; 85:14-24.
11. Honein MA, Paulozzi LJ, Moore CA. Family history, and clubfoot: an indication of a gene-environment interaction. *Am J Epidemiol.* 2000; 152:658-665.
12. Wynne-Davies R. Family studies and aetiology of clubfoot. *J Med Genet.* 1965; 2:227-232.
13. Gibbons PJ *et al.* Updates on clubfoot. *J Paediatr Child Health.* 2013; 49(9):E434-E437.
14. Aggarwa Alok, Gupta Neha. The role of pirani scoring system in the management and outcome of idiopathic club foot by ponseti method, *International journal of science and research,* 1991; 5(6).
15. Tachdjian MO. *The Child Foot.* W.B. Saunders. Philadelphia. USA, 1985, 139-239.
16. Beatson TR, Pearson JR. A Method of Assessing Correction in Clubfoot. *J Bone Joint Surg.* 48(1):40-50.
17. Kite JH. *The Clubfoot.* New York Grune and Stratton. Inc, USA, 1964, 1966.
18. Gurnett CA, Boehm S, Connolly A, Reimschisel T, Dobbs MB. Impact of congenital talipes equinovarus etiology on treatment: outcomes. *Dev Med Child Neurol.* 2008; 50(7):498-502.
19. Dobbs MB, Rudzki JR, Purceii DB, Walton T, Porter KR. Factors predictive of outcome after use of the Ponseti method for the treatment of idiopathic clubfeet. *J Bone Joint Surg Am.* 2004; 86-A(1):22-27.
20. Changulani M, Garg NK, Rajagopal TS, Bass A, Nayagam SN *et al.* Treatment of idiopathic club foot using the Ponseti method. Initial experience. *J Bone Joint Surg Br.* 2006; 88:1385-1387.
21. Morcuende JA, Dolan LA, Dietz FR, Ponseti IV. Radical reduction in the rate of extensive corrective surgery for clubfoot using the Ponseti method. *Pediatrics.* 2004; 113:376-380.
22. Bensahel H, Catterall A, Dimeglio A. Practical applications in idiopathic clubfoot: a retrospective multicentric study in EPOS. *J Pediatr Orthop.* 1990; 10:186-188.
23. Mackay DW. New concept of and approach to club foot treatment: Section II- Correction of Club Foot. *J Pediatr Orthop.* 1983; 3:10-21.
24. Reimann I. Congenital idiopathic clubfoot. Thesis. Copenhagen: Munsgaard, 1967.
25. Zhao D, Liu J, Zhao L, Wu Z. Relapse of Clubfoot after Treatment with the Ponseti Method and the Function of the Foot Abduction Orthosis. *Clin Orthop Surg.* 2014; 6:245-52.
26. Flynn JM, Donohoe M, Mackenzie WG. An independent assessment of two clubfoot-classification systems, *J Pediatr Orthop.* 1983; 18:323,
27. Ponseti IV. *Congenital Clubfoot: Fundamentals of Treatment.* Oxford University Press, 1997.
28. Ponseti IV, Campos J. Observations on pathogenesis and treatment of congenital clubfoot. *Clin Orthop.* 1972; 84:50-60.
29. Dimeglio A, Bensahel H, Souchet P, Mazeau P, Bennet F. Classification of club foot. *J Pediatr Orthop B.* 1995; 4:129-36.
30. Wainwright AM, Auld T, Benson MK, Theologis TN. The classification of congenital talipes equinovarus. *J Bone Joint Surg [Br].* 2002; 84-B:1020-4.
31. Turco VJ. Resistant congenital clubfoot: one-stage posteromedial release with internal fixation: a follow-up report of a fifteen-year experience. *J Bone Joint Surg [Am].* 1979; 61-A:805-14.
32. Simonis, GW. Complete subtalar release in club feet. *J. Bone Joint Surg.* 1985; 67A:1044.