

E-ISSN: 2395-1958  
P-ISSN: 2706-6630  
IJOS 2020; 6(1): 591-595  
© 2020 IJOS  
[www.orthopaper.com](http://www.orthopaper.com)  
Received: 11-11-2019  
Accepted: 15-12-2019

**Dr. K Shanmuganathan**  
M.S. Ortho, Senior Assistant  
Professor, Government Theni  
Medical College, Tamil Nadu,  
India

**Dr. Soundarajan**  
Senior Resident, Government  
Theni Medical College, Tamil  
Nadu, India

## A study on clinicoradiological outcome of posterior and posterolateral decompression and stabilisation with pedicle screws and fusion for tuberculosis of dorsal and lumbar spine

**Dr. K Shanmuganathan and Dr. Soundarajan**

DOI: <https://doi.org/10.22271/ortho.2020.v6.i1k.1931>

### Abstract

**Background:** Tuberculosis is ubiquitous in distribution. Globally, early 30 million people suffer from tuberculosis. In this study we clinico radio logically evaluated the outcome of posterior and postero lateral decompression, stabilisation with pedicle screws and fusion for tuberculosis of dorsal and lumbar spine

**Aim of the study:** The aim of this prospective study is to analyse the clinico radiological outcome of posterior and postero lateral decompression, stabilisation with pedicle screws and fusion for tuberculosis of dorsal and lumbar spine and to study the improvement in the angle of kyphosis.

**Materials:** The study was conducted with 15 patients of Tuberculosis of Dorsal and Lumbar spine from July 2017 to June 2019 in our Govt Theni medical College Hospital.

**Results:** The mean preoperative Visual analog score was 8.7 (range 7-10) which improved to 1.7(1-4) at final follow up. Post operatively Frankel score of the patients very much improved. The mean preoperative kyphosis in the thoracic and thoracolumbar spine was 27.9 degrees which was corrected to a mean of 9.5 degrees in the final follow up.

**Conclusions:** It facilitates early mobilization and avoids problems of prolonged recumbency. It provides better functional outcome and significantly better sagittal plane and kyphosis correction.

**Keywords:** Skeletal tuberculosis, dorsal and lumbar spine, potts spine, posterior and posterolateral

### Introduction

Tuberculous osteomyelitis always arise secondary to a primary foci. The primary foci may be present in the lungs, lymph nodes or gastrointestinal tract. Following bacteremia, the organisms reach the spine through the Batson venous plexus, hematogenous spread or lymphatic drainage<sup>[10]</sup>.

### Types

Depending upon the focus of tuberculous infection in the vertebra, they can be classified into five types: Paradiscal (most common), central, anterior, appendicular and synovial. In late stages of the diseases, destruction of the body and the intervertebral disc causing collapse of the body according to the biomechanical forces acting along the vertebral column, leading to local kyphosis in the dorsal region. Healing takes place by bony fusion leading to deformity and if the deformity is severe, it leads to stretching of the spinal cord over the deformity, which in turns leads to late onset neurology<sup>[11]</sup>.

### Neurological deficits

The incidence of neurological involvement in Potts disease is 20-40%. Paraplegia rarely occurs in the tuberculous affection below L1 as the cord terminates at L1 where the spinal cord is capacious and contain only cauda equina. The presentation of patients with neurologic complications varies from subtle gait disturbances to complete deficits with bladder and bowel involvement.

**Corresponding Author:**  
**Dr. Soundarajan**  
Senior Resident, Government  
Theni Medical College, Tamil  
Nadu, India

**Classification:** The neurological deficit associated with spinal tuberculosis is traditionally divided into two types.

**Group A: Paraplegia of early onset:** It occurs with the active stage of the disease usually within first two years. The extrinsic causes are granulation tissue, abscess, tubercular debris, tuberculous caseous tissue, internal gibbus and pathological subluxation of vertebra. The intrinsic causes are Inflammatory edema and infective thrombosis/endarteritis of spinal vessels.

**Group B: Paraplegia of late onset:** It usually occurs after many years and after apparent quiescence of the disease. The extrinsic causes are transverse ridge of bone anterior to the spinal cord producing pressure and constricting scar around dura. The intrinsic causes are inflammatory edema and stretching of spinal cord. Based upon degree of motor weakness, Kumar 17 classified the tuberculous paraplegia into four grades:

I	The patient does not appreciate weakness but clinician notices clumsiness of gait and signs suggestive of upper motor neuron lesion (plantar extensor and ankle clonus).
II	Patient has motor weakness and signs of upper motor neuron lesion, but has sufficient power that he/she manages to walk (motor power grade 3 or above).
III	Bedridden (severe motor weakness) with signs of paraplegia but sensory loss less than 50%.
IV	Complete motor weakness with loss of sensation more than 50% and/or bladder bowel involvement and/or flaccid paraplegia and/or paraplegia with flexor spasms.



**Fig 1:** Pedicle screw system.

### Methods

With prone position of patient and General anaesthesia, pedicle exposed in posterior midline approach. We use the intersection technique to identify the pedicle which is a point between the line from transverse process and lateral aspect of facet joint.

- Once pedicle screws are inserted, temporary stabilisation done with rod on one side. Through transpedicular

**Frankel (1969)** <sup>[12]</sup> has classified the neural deficit in spinal tuberculosis into five grades:

A	Absent motor and sensory function below the segmental level.
B	Sensation present, absent motor function
C	Sensation present, some motor power present below the level of the lesion but not useful to the patient (Grade <3/5)
D	Sensation present, motor function present and patient could walk with or without aids(Grade 3,4/5)
E	Normal motor and sensory function. Abnormal reflexes may be present.

We used frankel grade to assess the degree of neurological deficit in our patients

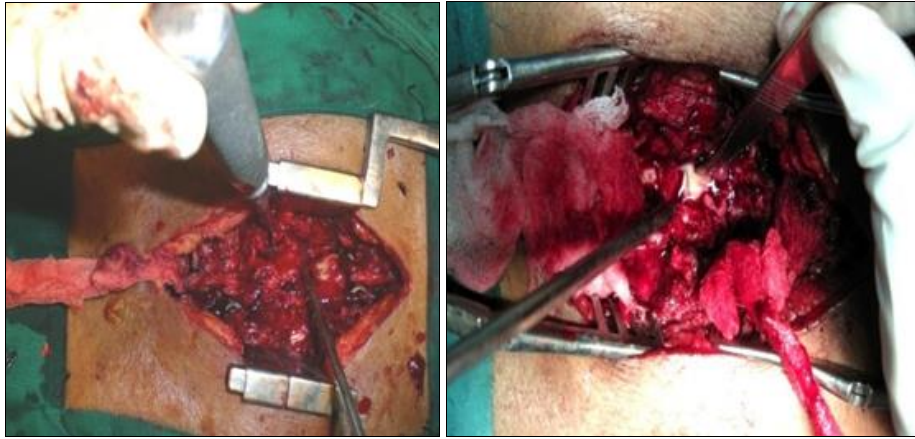### Materials

This study was conducted in our Hospital on 15 patients with Tuberculosis of Dorsal and Lumbar spine from July 2017 to June 2019.

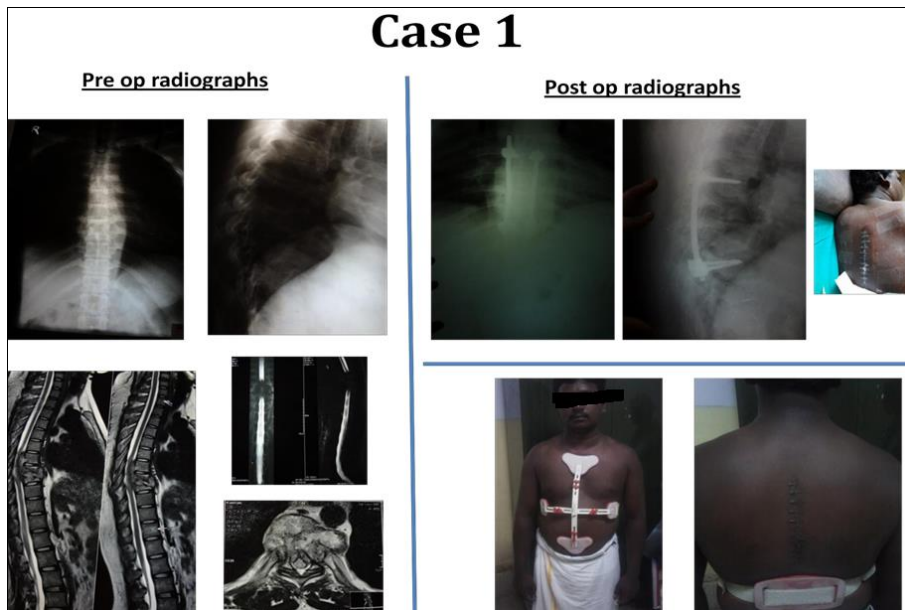
**Selection criteria:** The Inclusion criteria is age group of 12 to 70 years of age, mild to moderate amount of cold abscess. no improvement with conservative treatment and worsening of neurological deficit. Patients less than 12 years of age, huge cold abscess, severe kyphotic deformity with internal gibbus and patients not fit for anaesthesia are excluded from the study

### Implant

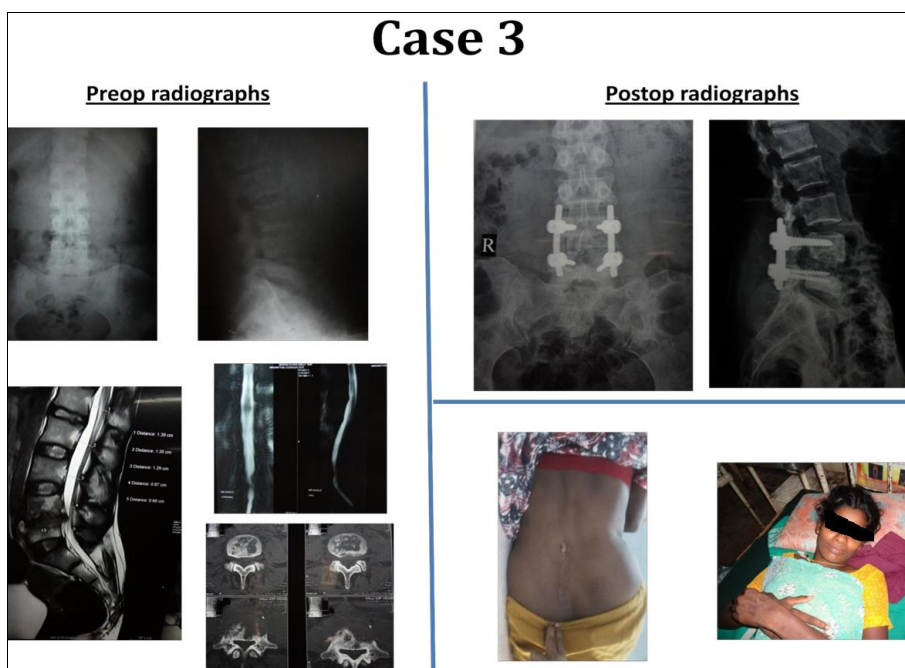
approach, body was approached posteriorly and posterolaterally and decompression done for dorsal spine. the disc space was distracted and the infected end-plate, disc, soft tissue, necrotic debris and abscess were meticulously debrided. Inter body fusion was done with bone graft, voids were filled with graft. Stabilization was done with pedicle screw construct.

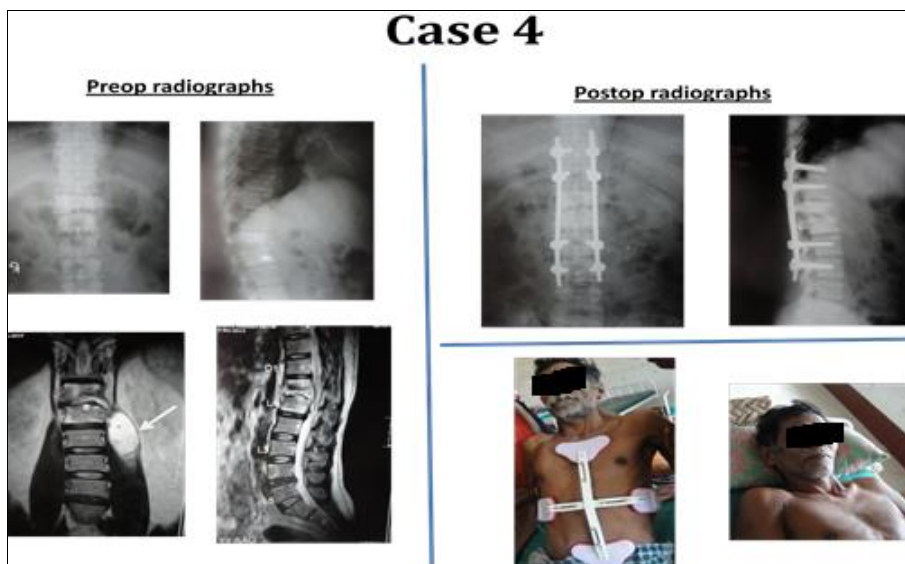


**Fig 2:** Exposure and Transpedicular region **Fig 3:** Evacuation of pus and granulation tissue



**Fig 4:** Range from 8 months to 2 years.





**Post-op follow up**

The patients are followed up at 3 months, 6 months, 1 year and every 6 months and evaluated for the Visual analogue pain scale and the functional outcome evaluated using Postoperative Frankel grading, Angle of kyphosis, Oswestry disability index.

**Results**

The mean preoperative Visual analog score was 8.7 (range 7-10) which improved to 1.7 (1-4) at final follow up implying better pain score postoperatively. The mean preoperative ESR value was 111.8 which improved to 31.7 at final follow up which indicates improvement in disease activity. Before surgery, 7 patients were classified as Frankel grade C, 2 patients each with grade B, D and E & one patient with grade A. After surgery, all patients with grade C improved to one grade,

Mean vas score	
Pre op	8.7
Post op	2.5

Mean Kyphotic Angle	
Pre op	27.9
Post op	9.5

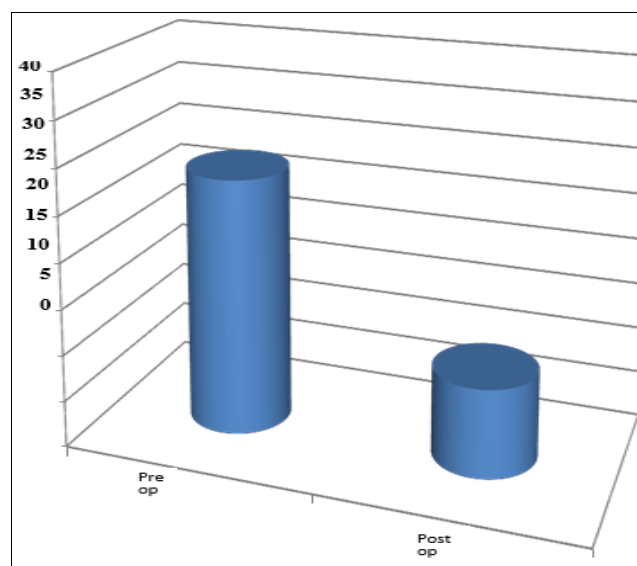


Fig 6: Mean kyphotic angle (Dickson method)

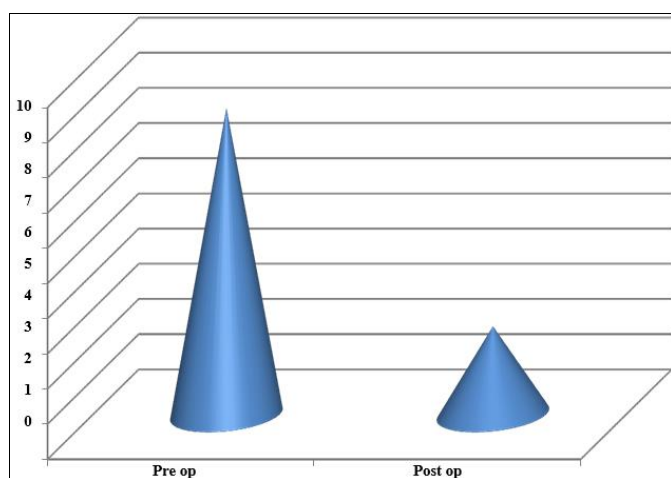


Fig 5: Mean Vas score

**Discussion**

Among the various types of decompression, Anterior approach is considered the gold standard for debridement and decompression. [3] Advantages of the traditional anterior approach are ability to directly access the disease and perform decompression, better correction of deformity, less muscle dissection and the ability to place a graft under compressive load for fusion. The disadvantages of anterior approach are morbidity and mortality associated with the transpleural and retroperitoneal approach like atelectasis, chest infection, pneumothoax and postoperative ileus, increase in spinal instability after surgical decompression in the immediate postoperative period. The structural bone graft in anterior approach does not give initial stability and graft related problems occur more often when the graft spans more than two-disc space. The tricortical iliac crest is associated with donor site morbidity. The stability of anterior instrumentation may not provide adequate fixation as there is concomitant inflammation associated with infection and the anterior bones are hyperemic and porotic. Implant holding is a problem and there might be risk of graft subsidence and graft slippage. we used transpedicular screws with Moss Miami system because

it has been proven to be a good method for stabilizing the thoracolumbar and lumbar spine. During instrumentation of the pedicle screws in thoracic and the lumbar spine, we inserted the screws into the healthy pedicles adjacent to the areas of bone destruction. There is a quick relief of instability<sup>27</sup> in patients treated with early stage spinal tuberculosis with transpedicular instrumentation. This posterior approach has a special advantage in that it avoids contact with the infectious focus, because the tuberculous infection usually involves the anterior column. The fact that tuberculous lesions may heal in spontaneous fusion makes this posterior approach feasible the transpedicular instrumentation helps in maintaining the spinal alignment and stabilization of the involved vertebra.

The cord was decompressed by excising a pedicle in order to allow access to the anterior debris. A limited debridement was undertaken to decompress the cord without creating a large defect. The transpedicular route for decompression is preferable to the transthoracic procedure since it allows an adequate global removal of the anterior, lateral and posterior cuff of tissue. The posterior instrumentation allows early mobilisation, thus avoiding the complications of prolonged recumbency. The stability provided by posterior fixation, particularly transpedicular fixation, protects the vertebral correction, and patients are able to return to normal activities within a short period of time. The benefits of our approach are early ambulation, decreased morbidity, and good access to dural abscesses, sequestered bone and small abscesses in the anterior spine. Posterior instrumentation can be used to correct deformity and any concurrent spinal stenosis in elderly patients can be treated simultaneously.

### Conclusion

It is a less morbid approach and avoids problems associated with thoracotomy and laprotomy. It facilitates early mobilization and avoids problems of prolonged recumbency. It provides better functional outcome and significantly better sagittal plane and kyphosis correction.

### References

1. Tuli SM. Tuberculosis of the skeletal system.4th edition. Chapter, 19, 193-194.
2. Jain AK, Dhammi IK, Prashad B. Simultaneous anterior decompression and posterior instrumentation of the tuberculosis spine using an anterolateral extrapleural approach J Bone Joint Br. 2008; 90:1477-81.
3. Hodgson AR, Stock FE, Fang HS, Ong GB. Anterior spinal fusion: The operative approach and the pathological findings in 412 patients with Pott's disease of the spine.Br J Surg. 1960; 48:172-8.
4. Hee HT, Majd ME, Holt RT. Better treatment of vertebral osteomyelitis using posterior stabilization and titanium mesh cages. J Spinal Disord Tech. 2002; 15:149-56.
5. Kruger A, Pfahler A, Anterior M. debridement, fusion and extrafocal stabilization in the treatment of osteomyelitis of spine. J spinal Disord. 1999; 8:304-9.
6. Fukuta S, Miyamoto K, Masuda T *et al.* Two stage surgical treatment using posterior spinal instrumentation for pyogenic and tuberculous spondylitis. Spine. 2003; 28:E302-8.
7. Moon MS, Woo YK, Lee KS *et al.* Posterior instrumentation and anterior interbody fusion for tuberculous kyphosis of dorsal and lumbar spine. Spine. 1995; 20:1910-16.

8. Lee TC, Lu K, Yang LC, Huang HY, Liang CL. Transpedicular instrumentation as an adjunct in the treatment of thoracolumbar and lumbar spine tuberculosis with early state bone destruction. J Neurosurg. 1999; 91(2):163-9.