

E-ISSN: 2395-1958
P-ISSN: 2706-6630
IJOS 2020; 6(1): 578-581
© 2020 IJOS
www.orthopaper.com
Received: 04-11-2019
Accepted: 08-12-2019

Singh G
Resident, Department of
Orthopaedics, Rohilkhand
Medical College and Hospital,
Bareilly (UP), India

Kumar A
Assistant Professor, Department
of Orthopaedics, Rohilkhand
Medical College and Hospital,
Bareilly, (UP), India

Agarwal VK
Assistant Professor, Department
of Orthopaedics, Rohilkhand
Medical College and Hospital,
Bareilly (UP), India

Somashekarappa T
Professor and Head, Department
of Orthopaedics, Rohilkhand
Medical College and Hospital,
Bareilly (UP), India

Corresponding Author:
Singh G
Resident, Department of
Orthopaedics, Rohilkhand
Medical College and Hospital,
Bareilly (UP), India

International Journal of Orthopaedics Sciences

Treatment of primary aneurysmal bone cyst of patella with percutaneous intralesional sclerotherapy using 3% polidocanol: A case report

Singh G, kumar A, Agarwal VK and Somashekarappa T

DOI: <https://doi.org/10.22271/ortho.2020.v6.i1k.1928>

Abstract

Introduction: Patella is an uncommon site for primary tumour of bone. Aneurysmal bone cyst account for 1 % of any primary bone lesion and its occurrence in patella is very rare.

Material and method: A case report of 20 years old male patient came with complain of pain in right knee joint with swelling from last 1 year with no history of trauma. On examination there was localised tender swelling present in the anterior aspect of knee over patella with full range of movement. On investigating routine investigations were unremarkable. X-ray right knee joint shows expansile osteolytic lesion with cortical thinning. MRI shows a large cyst with fluid level suggestive of aneurysmal bone cyst. 3 injections of 2ml of 3% polidocanol given 1 month apart intralesionally under fluoroscopy guidance. Clinical, functional and radiological follow-up for 3 consecutive months was done.

Discussion: Percutaneous sclerotherapy with 3% polidocanol is a safe alternative to conventional surgery for the treatment of Aneurysmal bone cyst.

Conclusion: Percutaneous sclerotherapy is emerging as an excellent method of treatment for aneurysmal bone cyst, and obviates the potential functional disabilities with other method of treatment.

Keywords: primary aneurysmal, patella, intralesional sclerotherapy, polidocanol

Introduction

Jaffe and Lichtenstein first described aneurysmal bone cysts (ABCs) as a separate clinicopathologic entity in 1942^[1]. In 2002, an ABC was defined by the WHO as "a benign cystic lesion of bone composed of blood filled spaces separated by connective tissue septa containing fibroblasts, osteoclast-type giant cells and reactive woven bone"^[2]. An ABC may be primary or arise secondarily in other benign or malignant bone tumors. Oliveira et al. reported cytogenetic differences between primary and secondary ABCs, with a primary ABC being a mesenchymal neoplastic disease with spindle cell proliferation exhibiting USP6 or CDH11 rearrangements in 2/3 of the cases whereas a secondary ABC morphologically mimics a primary ABC without the hallmark USP6 or CDH11 rearrangements^[3].

The patella is a rare site for primary tumours of bone. Incidence of Primary tumours of the patella account for approximately 0.06% of bone tumours and metastatic lesions are rare. The most common benign tumour in patella is giant cell tumour (33%), followed by chondroblastoma (16%). Malignant patella tumors include hemangioendothelioma (4%), lymphoma (4%), Osteosarcoma (3%), and metastatic tumors (3%)^[4]. Incidence of Aneurysmal bone cyst is 1% among primary bone lesions, and its occurrence in the patella is rare^[5]. Treatment with 3% polidocanol through percutaneous injection is a safe and effective treatment for aneurysmal bone cysts^[6, 7].

Material and Method

- A 20yr old male patient came to RMCH BAREILY with chief complain of pain and swelling over right knee joint since 6 month. There was no history of any trauma, fever or signs of local inflammation, loss of appetite, weight loss, exposure to tuberculosis.

- On examination the right knee was swollen and appeared bigger than left knee. There was no localized rise in temperature, but the patella was remarkably tender. In addition there was a palpable bony thickening of the patella. No synovial thickening or knee joint effusion was noted. ROM of right knee full. Patient was referred for radiological examination and for routine laboratory investigation. Laboratory studies revealed - Hemoglobin-12.8 gm%, Total leucocyte count- 8,300/mm³, Polymorphocytes-54%, Lymphocytes-20%, Eosinophilis-20%, Monocytes-60%, Basophilis-%, ESR-24, Urea-23mg/dl, Creatinine -0.5 mg/dl, INR- 1.33, random blood sugar- 114mg/dl.
- Radiographic examination of the right knee showed multiple cystic lytic lesions causing expansion of the patella. T1- and T2-weighted magnetic resonance imaging showing a smooth-contoured cystic mass with internal septa, involving half of the patella with a minimum expansion anteriorly and resulting cortical thinning. A preliminary diagnosis of ABC was made

[figure1].

- FNAC revealed low cellularity, hemorrhagic smears showing few osteoblasts and multinucleated giant cells [figure2].

Procedure

- Under spinal anesthesia, right knee of the patient was painted and draped.
- Under fluoroscopic guidance, 16-G needle is introduced from the inferior pole of patella and internal septas were broken by moving the needle insided the lesion. After aspiration of blood from the lesion, 2 ml of 3% polidocanol was given intralesionally.
- Total of 3 injections of 2ml of 3% polidocanol given 1 month apart intralesionally under fluoroscopy guidance. Clinical, functional and radiological follow-up for 3 consecutive months was done. Patient got relieve in his symptoms and radiologically consolidation of the lesion was seen [figure3].

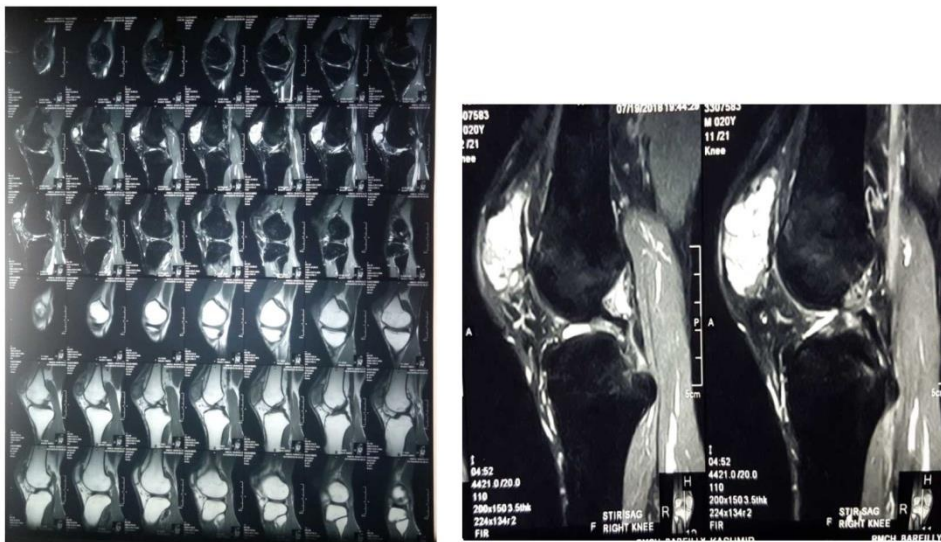


Fig 1: MRI Right knee joint

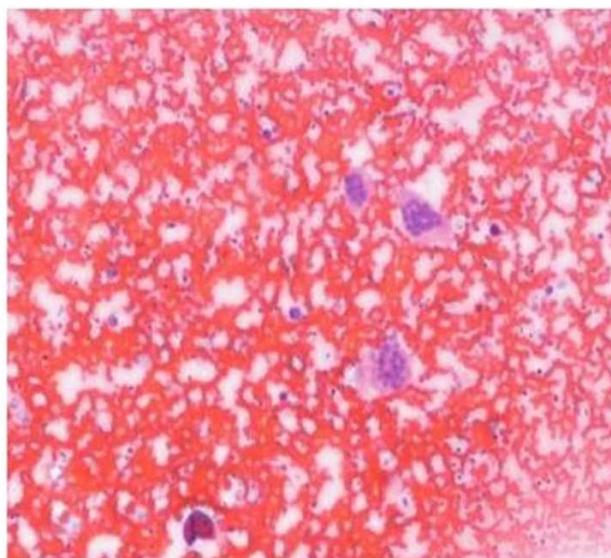
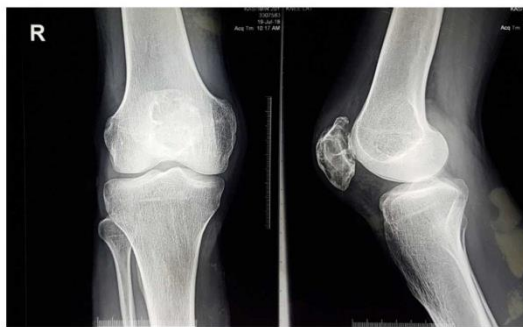
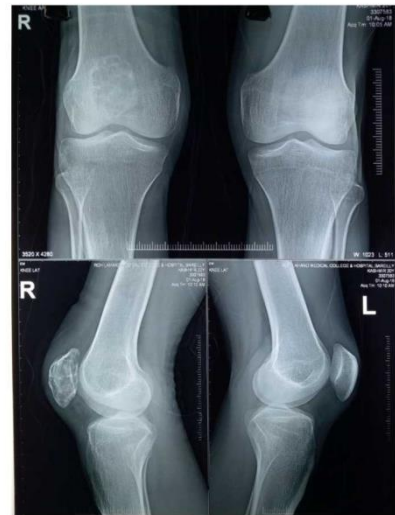
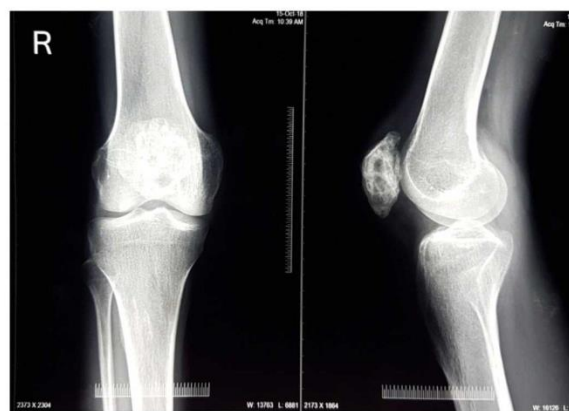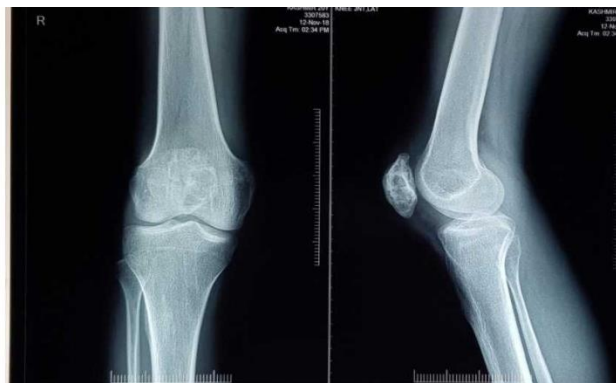Fig 2: FNAC

**Fig 3A:** Pre op. Xrays**Fig 3B:** Post op. Xrays at 1 month**Fig 3C:** Post op. Xrays at 2 month**Fig 3D:** Post op. Xrays at 3 month

Discussion

Primary and secondary tumours of the patella are infrequent. Metastatic tumours of the patella are less common than primary tumour. Aneurysmal bone cyst (ABC) is an expansile cystic lytic lesion, more common present in the second decade. ABCs although benign can be locally aggressive. The etiology of ABC is not definitively known, even though most believe it as a vascular malformation. ABCs are usually painful, so late presentation as a pathological fracture is less common than with unicameral bone cysts. The typical radiographic appearance of an ABC is an expansile osteolytic lesion with eccentric location. On computed tomography and magnetic resonance scans, internal septa with a honeycomb

pattern and fluid-fluid levels are seen within the lesion. Percutaneous sclerotherapy with polidocanol is a safe alternative to conventional surgery for the treatment of Aneurysmal bone cyst. Polidocanol is earlier used as an endovenous sclerosing agent to treat varicose veins and recently used effectively for aneurysmal bone cyst [8].

Conclusion

Percutaneous sclerotherapy is emerging as an excellent method of treatment for aneurysmal bone cyst, and obviates the potential functional disabilities with other method of treatment.

References

1. Jaffe HL, Lichtenstein L. Solitary unicameral bone cyst: with emphasis on the roentgen picture, the pathologic appearance and the pathogenesis, Arch. Surg. 1942; 44:1004-1025.
2. Sciot R, Dorfman H, Brys P, Dal Cin P, De Wever I, Fletcher CD, *et al*, Cytogenetic-morphologic correlations in aneurysmal bone cyst, giant cell tumor of bone and combined lesions. A report from the CHAMP study group, Mod. Pathol. 2000; 13(11):1206-1210.
3. Andre M. Oliveira, Antonio R. Perez-Atayde, USP6 and CDH11 Oncogenes Identify the Neoplastic Cell in Primary Aneurysmal Bone Cysts and Are Absent in So-Called Secondary Aneurysmal Bone Cysts, American Journal of Pathology. 2004; 165:1773-1779.
4. Mercuri M, Casadei R. Patellar tumors. Clin Orthop Relat. 2001; 163:35-46.
5. Reddy NS, Sathi VR. Primary aneurysmal bone cyst of patella. Indian J Orthop. 2009; 43:216-7.
6. Rastogi S, Varshney MK, Trikha V, Khan SA, Choudhury B, Safaya R: Treatment of aneurysmal bone cysts with percutaneous sclerotherapy using polidocanol. A review of 72 cases with long-term follow-up. J Bone Jointn Surg (Br). 2006; 88(9):1212-1216.
7. Varshney MK, Rastogi S, Khan SA, Trikha V. Is sclerotherapy better than intralesional excision for treating aneurysmal bone cysts? Clin Orthop Relat Res. 2010; 468(6):1649-1659.
8. R, Bandhu S, Sawhney S, Mittal R. Sonographically guided percutaneous sclerosis using 1% polidocanol in the treatment of vascular malformations. J Clin Ultrasound. 2002; 30(7):416-23.