



International Journal of Orthopaedics Sciences

E-ISSN: 2395-1958
P-ISSN: 2706-6630
IJOS 2020; 6(1): 586-590
© 2020 IJOS
www.orthopaper.com
Received: 09-11-2019
Accepted: 13-12-2019

Dr. Ravindra Shivgonda Patil
Associate professor, Orthopaedic
Department, DY Patil Hospital,
Kolhapur, Maharashtra, India

Dr. Vikas Illur
Assistant Professor, Orthopaedic
Department, DY Patil hospital,
Kolhapur, Maharashtra, India

Dr. Naresh Chaudary
Junior Resident, Orthopaedic
Department, DY Patil hospital,
Kolhapur, Maharashtra, India

Dr. Vijaysinh Manik Bhosale
Junior Resident, Orthopaedic
Department, DY Patil hospital,
Kolhapur, Maharashtra, India

**Dr. Gunjankumar Mukeshbhai
Ghelani**
Junior Resident, Orthopaedic
Department, DY Patil hospital,
Kolhapur, Maharashtra, India

Dr. Akshay Sanjay Anchalia
Junior Resident, Orthopaedic
Department, DY Patil hospital,
Kolhapur, Maharashtra, India

Comparative study of functional outcome between olecranon osteotomy and triceps lifting approach in osteosynthesis of distal humerus fracture

**Dr. Ravindra Shivgonda Patil, Dr. Vikas Illur, Dr. Naresh Chaudary,
Dr. Vijaysinh Manik Bhosale, Dr. Gunjankumar Mukeshbhai Ghelani
and Dr. Akshay Sanjay Anchalia**

DOI: <https://doi.org/10.22271/ortho.2020.v6.i1k.1930>

Abstract

Introduction: Intra-articular distal humeral fractures are very complex fractures. A variety of approaches are used to treat this fracture. The purpose of this study is to evaluate and compare the functional outcomes of two approaches that are olecranon osteotomy and triceps-lifting approach for the treatment of intra-articular distal humeral fractures.

Methods: This study includes 30 intra-articular distal humeral fractures patients who were treated with open reduction and internal fixation with anatomic plating by two different approaches. Lateral plating was performed in 6 patients, and medial and lateral parallel plating was performed in 12 patients in the olecranon osteotomy group, while lateral plating was performed in 3 patients, and medial and lateral parallel plating was performed in 9 patients in a triceps-lifting group. It includes retrospective and prospective study in the department of orthopaedic in DR. D Y Patil Medical College Kolhapur during the period from June 2017 to June 2019.

Results: After regular follow and after assessing the patient we came to the result that functional outcomes according to MAYO elbow score and extension-flexion motion arc values were significantly better in the olecranon osteotomy group. The mean complication rate in olecranon osteotomy was 33% and in tricep lifting approach the mean complication rate was 50%.

Conclusion: Olecranon osteotomy approach has better functional outcomes than the triceps-lifting approach. Intra-articular distal humerus fractures can be safely treated with olecranon osteotomy which provides more control over the elbow joint and better visualization and allows early postoperative rehabilitation.

Keywords: distal humerus fracture, olecranon osteotomy, tricep lifting approach

Introduction

Intra-articular fractures of the distal humerus occur in 0.5%-7% of all fractures and 30% of elbow fractures. Comminuted intra-articular distal humerus fractures are observed in 1 % of all fractures. The incidence of lower end of humerus fracture has a bimodal age distribution [1]. These fractures are seen both in younger & elder age groups. In the younger age groups are due to high energy trauma and in the elderly because of osteoporosis, these fractures are results of low energy trauma. These fractures are difficult to treat because of the complex anatomy of the distal humerus, articular comminution, and osteoporosis & poor bone stock.

Open reduction and internal fixation of displaced, intra-articular, intercondylar fractures of the distal humerus is done by any of the following technique ie reconstruction plate, 1/3 tubular plate, double tension band wiring, and distal humerus locking plate. For operative stabilization of bicondylar distal humerus fractures, adequate surgical exposure of the articular surface of the distal humerus and elbow joint is required and done by one of the following surgical exposures i.e olecranon osteotomy, triceps sparing approach, tricep reflecting and triceps splitting approach, but the gold standard being olecranon chevron osteotomy [2]. There are many surgical options for anatomical reconstruction [3]. The reconstruction of the osteotomy by tension band wiring may lead to complications such as delayed union, wound dehiscence,

Corresponding Author:
Dr. Ravindra Shivgonda Patil
Associate professor, Orthopaedic
Department, DY Patil Hospital,
Kolhapur, Maharashtra, India

non-union, mal-union, hardware failure, and pain secondary to prominent hardware. Alternative approaches to overcome these complications. Alternative approaches have been introduced such as the triceps- splitting, triceps-reflecting anconeus pedicle, the anconeus flap trans-olecranon approach, and the triceps-sparing approach. The primary goal in the management of intraarticular fractures of the distal humerus is to achieve good anatomical alignment, rigid fixation following early mobilization of the elbow can provide satisfactory results.

We hypothesize that the functional outcomes in comminuted intraarticular distal humerus fractures can be affected by different surgical approaches.

Methods and Materials

Study type:-both retrospective and prospective

Sample size total 30 (12+18)

Patients between 20 to 60 years were taken

Duration of study 2 years

Inclusion criteria

- All closed and Type-1 (Gustillo and Anderson) open distal humerus fractures.
- Fractures with intraarticular involvement

Exclusion Criteria

- Type-IIB & III (Gustillo and Anderson) open distal humerus fractures.
- Patients with open physis.
- Cases with associated vascular injuries.
- Non-co-operative patient.
- Injuries were over 3 weeks old.
- All pathological distal humeral fractures which include fractures secondary to neoplastic or infective (active or sequelae) pathology.

30 patients who were diagnosed with a fracture of the distal humerus were divided into two groups. Group A had 18 patients treated surgically by the trans olecranon approach. Group B had 12 patients treated surgically by the triceps lifting approach. Patients who did not attend follow up clinics due to chronic debilitating conditions were excluded from the study.

All fractures were classified under the AO Muller classification. After detailed clinical examination and radiological confirmation by x-rays and CT scan with 3D reconstruction and informed consent, all patients were intervened surgically. In our study, we have included patients of a minimum one year follow up. Out of 18 patients in group A, there were 11 females and 7 males.

Group A

- 4 cases of B3(22%)
- 6 cases of C1(33%)
- 5 cases of C2(27%)
- 3 cases of C3(16.6%)

In group B, out of 12 patients, there were 5 females and 7 males patients.

Group B

- 2 cases of B2(16.6%)
- 1 case of B3(8.3%)
- 4 cases of C1(33%)
- 3 cases of C2(25%)
- 2 cases of C3(16.6%)

Compound fracture of GUSTILO ANDERSON TYPE 1 were observed in two patients from each group.

Surgical technique

In group A of chevron olecranon osteotomy approach to the elbow joint, posteriorly skin incision to elbow joint. The ulnar nerve was dissected and protected by making it free from the surrounding tissues. Then, the elbow joint was exposed by performing an inverted V-shaped Chevron osteotomy 2 cm distal to the olecranon tip. The fragments were reduced with bone holding clamps and restoration of the joint was transiently done with K-wires. Permanent fixation is done with the help of plates and CC screws to maintain Joint integrity.

Lateral plating was done in 6 patients, and medial and lateral parallel plating was done in 12 patients. The olecranon osteotomy was fixed with a tension band wiring or 1 cancellous screw.

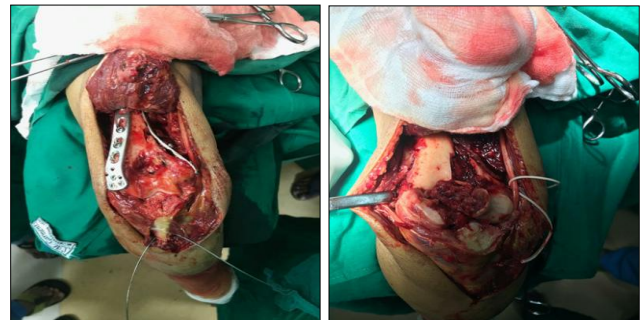

Fig 1: Intraoperative Images.

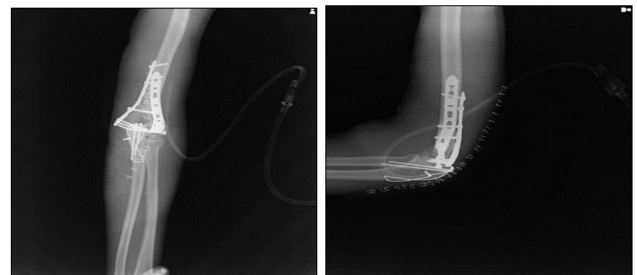

Fig 2: Post Operative X-rays.

In group B of triceps lifting approach to the elbow joint, a posterior skin incision to elbow was made, and the ulnar nerve was then exposed and protected. The triceps muscle from the attachment site was detached and lifted in a “V” form with the fascia and the muscle was split up to the condyles. The fracture line was visualized and reduced with bone holding clamps and provisionally fixed with K-wires, and lateral plating was done in 3 patients and medial and lateral parallel plating was done in 9 patients. The triceps muscle was sutured to its anatomical site using a 1.0 absorbable suture.

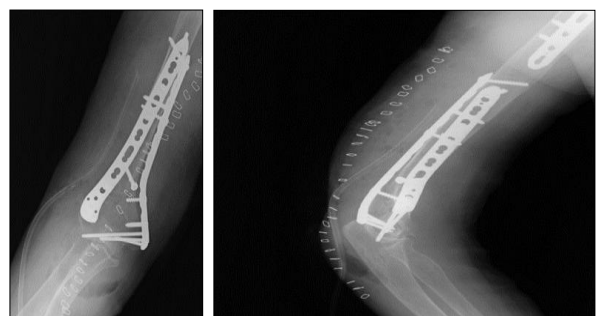


Fig 3: Post operative images.

Fixation approach

Articular reconstruction

The sequence of fixation is articular segment restoration, column realignment, and rigid anatomical fixation so early elbow mobilization can be done. Initially, temporarily fixation can be done by several K- wire followed by definitive fixation with screw place through medial and lateral plates or the placement of screw down the axis of trochlea to fix the main fragment.

Column reconstruction

The articular fragment is provisionally fixed to both the column medial and lateral by several K-wires inserted retrograde from distal to proximal direction.

Definite fixation of columns by several different plating techniques which include parallel plating, triple plating and orthogonal plating (90:90)

Postoperative care

A suction drain was removed by 48 hours post-operatively. Suture removal was done after the second week. The arm was

immobilized with above elbow back slab after surgery for 5 days and in a patient with inadequate stabilization, elbow immobilization was extended to for 10 days. Active elbow flexion and extension exercise were begun and gradually increased after removing the back slab.

Prophylactic antibiotics were given for the first 3 postoperative days & indomethacin for 45 days post-operative.

Basic patient demographics, mechanism of injury and AO fracture classification were recorded. The final functional outcome of patients was measured using MAYO

Complications

Infection
Elbow stiffness
Heterotopic ossification
Ulnar neuropathy
Nonunion
Malunion
Implant prominence
Implant failure

Table 1: Complications

	Group A {Olecranon Osteotomy}	Group B {Triceps reflecting approach}
1} Infection	1	0
2} Elbow stiffness	1	3
3} Ulnar Nerve Neuropathy	0	1
4} Heterotopic Ossification	0	1
5} Non-Union	0	0
6} Mal-Union	0	0
7} Implant Failure	0	0
8} Implant Prominence	1	0
Complication Rate	16.6%	41.6%

Results

Our study consists of 30 cases of the distal end of humerus fracture with a condylar extension which was treated by open reduction and internal fixation by different plating techniques. 19 cases were due to road traffic accident and 11 cases were due to direct fall in the mode of injury.

The mean follow duration in group A was (13- 25months range) and in the group, B was (12-30 months range)

There were 7 males and 11 females with a mean age of 43.5 yrs in group A & 7 males and 5 females in group B with a mean age of 38.2 yrs.

According to the MEP Scoring system in group A were excellent in 4, good in 9, fair in 3 and poor in 2 patients. In group B excellent in 2, good in 6, fair in 2 & poor in 2 patients.

In term of the type of implant between both groups, lateral plating was done in 6 patients & medial and lateral plating was in 12 patients in group A, While lateral plating was done in 3 patients & and medial and lateral plating was done in 9 patients.

Table 2: Mayo Elbow Performance Score

Mep Score	A {n=18}	B {n=12}
1} Excellent {90-100}	4	2
2} Good {75-90}	9	6
3} Fair {60-75}	3	2
4} Poor {<60}	2	2

The mean elbow flexion was 102.18° & elbow extension was 12.4° in olecranon osteotomy group while that in triceps lifting approach, mean elbow flexion was 92.4° & elbow extension was 10.8°. The mean complication rate was 33% in group A that of 50% complication rate in group B. In group A, 2 patients developed superficial wound infection which was treated by debridement and antibiotic therapy, 1 patient has elbow stiffness, Non-union in 1 patient, and 1 patient has implant prominence. In group B, 1 patient developed wound infection, elbow joint stiffness in 2 patient and ulnar nerve neuropathy in 1 patient & malunion at the fracture site in 2 patients. In terms of complications between the two groups, there was no significant difference was formed.

Table 3: Comparison B/w Olecranon osteotomy group & Tricep reflecting approach

	Parameters	A-Olecranon Osteotomy	B-Tricep Approach
1	Number of pts.	18 {M-7, F-11}	12 {M-7, F-5}
2	Mean Age	43.5	38.2
3	Mean Follow up		
4	MEP SCORE		
5	Type of Implant	Lateral plating- 6 Both column plating-12	Lateral plating-3 Both column plating-9
6	Complication Rate	33.3%	50%

Discussion

Intraarticular distal humerus fractures are difficult to treat because of the complex anatomy of elbow joint fracture fragment are small in size, involve both the medial and lateral columns, the limited amount of subchondral bone and close proximity to much neurovascular structure. The management of distal humerus fracture should be approached in a systematic way by understanding the fracture type, its natural history, using the principle of fracture and incorporating patient-related factors. The goal of treatment is an approach that provides adequate exposure, anatomic reduction of the elbow joint, stable fixation to allow for early rehabilitation and the minimization of complications.

ORIF is the standard treatment, with the objectives, as described by O'Driscoll, being:

1. Restoration of diaphyseal bone stock
2. A union between the distal fragments and the shaft
3. Soft tissue healing without infection
4. Stable, mobile articulation.

The functional outcome in the ORIF of comminuted distal humerus fractures depends on the restoration of an articular surface, stable anatomical fixation, and early mobilization. The type of surgical approach is the most important factor to obtain the best results. The most commonly performed approaches in the operative repair of comminuted distal humerus fractures are a posterior incision followed by olecranon osteotomy, triceps splitting or triceps sparing and triceps lifting. In this study, we compared the functional outcome between 18 patients who underwent olecranon osteotomy and 12 patients who underwent surgery using the triceps lifting approach. We observed significantly better functional outcomes with the olecranon osteotomy approach which allows early rehabilitation according to MAYO elbow score [4] and better extension and flexion elbow motion arc than triceps reflecting approach.

Both surgical approaches for distal humerus have their advantages and disadvantages. Olecranon osteotomy provides better joint visualization with a wide surface, anatomical reduction and fixation of the osteochondral fragment are easier with possible complications such as prominence or migration of the implant, displacement of fragment and non-union at osteotomy site which can reduce by doing chevron osteotomy. Triceps reflecting approach preserves neurovascular supply of anconeus which is a dynamic stable stabilizer of the elbow. The major disadvantage is complete detachment of triceps from olecranon and postoperatively elbow joint is immobilized in a fixed position at 90 degrees for a minimum of 3 weeks to allow healing of extensor muscles to restore extensor mechanism.

In our study, internal fixation with isolated lateral plating or with lateral and medial double plating was performed. A recent study shows that double plating provides stable fixation and preserves the anatomy of the medial and lateral column.

The mean age of the patient included in this study was 43.5 years in the olecranon osteotomy group and 38.2 years in the triceps reflecting approach. The age of the patient can affect the postoperative functional outcome. Chen *et al.* defined an extension of 22.9° in the patients who underwent triceps lifting and were 60 years of age or older. They also demonstrated that triceps lifting caused poor results in patients older than 60 years, whereas it had no significant effects on the functional results in those less than 60 years old, especially in patients younger than 40 years. In our study, the loss of extension observed after performing triceps lifting

was found to be 20.5° and after osteotomy was found to be 14, which is similar to the study by Mehmet Elmadag [5]. For elbow joint to function normally, the range of motion required is of 30-130 degrees. In our study, final postoperative follow up a range of motion is in mean of elbow flexion of 94.2 +_ 10.4 and mean loss of extension of 12.6+_ 8 in group A and in group B, mean of elbow flexion of 86.4 +_ 12.2 and mean loss of extension of 20.5+_ 6. In our study, in group olecranon, osteotomy elbow mobilization post-operatively started after a mean of 2 weeks. In triceps reflecting group, post-operatively elbow joint kept in 90° flexion for 3 weeks then after post-operative rehabilitation started to decrease damage to the extensor mechanism.

In our study, the incidence of open fractures was 2 patients, each in both groups and both patients underwent definitive surgical fixation within a week. The incidence of open fractures in our study was comparable to previous studies by Eugene *et al.*, Ali AM *et al.* and J.A Fernandez *et al.* Ali AM *et al.* reported 3 open injury cases in his study on 22 patients [6]. All patients were operated by definitive fracture fixation on the day of injury.

The incidence of heterotopic ossification was 5.5% in olecranon osteotomy and 8.3% in the triceps reflecting approach as noted on X-rays on 3-6 months follow-up. Zhang *et al.* and Chen G. *et al.* reported 4 out of 36 cases and 4 out of 33 cases respectively of HO in their study on patients with distal humerus fractures operated by olecranon osteotomy technique [7]. Gofton *et al.* observed that 13% of patients with type C fractures of distal humerus suffered postoperative HO [8]. Ali AM *et al.* reported that delay in operative treatment can cause contracture of soft tissue which leads to a poor outcome. We observe that the time interval between the injury in the surgery affected heterotopic ossification formation because patients had an operative delay of more than 2 weeks have to dare likely to develop heterotrophic ossification.

The incidence of ulnar nerve neuropraxia was 8.33% in the triceps reflecting group which was spontaneous resolve completely after 4 months. This incidence is similar to the incidence (10%) reported by Allende *et al.* Chen G.*et al.* in his study reported 2 patients out of 34 patients (6%) of the olecranon osteotomy group with ulnar nerve paraesthesia which recovered by 3 weeks.

The incidence of Implant prominence was 5.5% in the group of olecranon osteotomy

Implant removal was advised after 15 months follow-up, Zhang *et al.* in his study on 36 patients with distal humerus fractures operated by olecranon osteotomy approach, reported 6 out of 36 patients with implant prominence. Jupiter *et al.* reported 5 patients with symptomatic olecranon implants. Mckee *et al.* noted that 27% of patients operated by olecranon osteotomy required reoperation for symptomatic implant removal.

The surgical approach, anatomical fixation, implant type up and post-operative early elbow mobilization are the factors affecting functional outcome and range of motion of elbow joint. We observe that allowing early elbow movement after the surgical treatment of the comminuted fracture of the distal humerus is important for achieving a good result.

The limitations of our study are a collection of retrospective data evaluation of existing data, small sample size, loss of follow-up and heterogeneous fracture severity.

Conclusion

In this study, we compared patients that were treated by olecranon osteotomy with a tricep lifting approach. We have

observed that the olecranon osteotomy approach has better joint visualization, better control of articular fragment and it allows early postoperative rehabilitation then tricep lifting approach.

References

1. Robinson CM, Hill RM, Jacobs N, Dall G, Court-Brown CM. Adult distal humeral metaphysical fractures: epidemiology and results of treatment. *J Orthop Trauma*. 2003; 17:38e47.
2. Throckmorton TW, Zarkadas PC, Steinmann SP. Distal humerus fractures. *Hand Clin*. 2007; 23(4):457e469.
3. Ramsey L, Bratic AK, Getz CL *et al*. Open reduction and internal fixation of distal humerus fractures. *Tech Shoulder Elb Surg*. 2006; 7(1):44e51.
4. Mayo Elbow Performance Score. *Journal of Orthopaedic Trauma*. 2006; 20(Supplement):S127.
5. Zhang C, Zhong B, Luo CF. Comparing approaches to expose type C fractures of the distal humerus for ORIF in elderly patients: six years clinical experience with both the triceps-sparing approach and olecranon osteotomy. *Arch Orthop Trauma Surg*. 2014; 134(6):803-11. doi: 10.1007/s00402-014-1983-y. Epub 2014 Apr 29.
6. Eugene THEk, MironGoldwasser, Anthony L. Bonomo. Functional outcome of complex intercondylar fractures of the distal humerus treated through a triceps sparing approach. *Journal of elbow and shoulder surgery*, 2008, 1058-2746.
7. Zhang Chi, Biao Zhong, Congfeng Luo. Comparing approaches to expose type C fractures of the distal humerus for ORIF in elderly patients: six years clinical experience with both the triceps sparing approach and olecranon osteotomy, *Arch Orthop Trauma Surg*. 2014; 134:803-811.
8. Gofton WT, MacDermid JC, Patterson SD *et al*. Functional outcome of AO type C distal humeral fractures. *J Hand Surg Am*. 2003; 28(2):294-308.