



International Journal of Orthopaedics Sciences

E-ISSN: 2395-1958
P-ISSN: 2706-6630
IJOS 2020; 6(1): 540-544
© 2020 IJOS
www.orthopaper.com
Received: 06-11-2019
Accepted: 10-12-2019

Dr. Ashok Meena
SMS Medical College Jaipur, 5 A,
Purender Ji Ka Baagh, Mooti
Doongri Road, Jaipur,
Rajasthan, India

Dr. DS Meena
Sms Medical College Jaipur,
Rajasthan, India

Dr. Nirottam Singh
Dr. S.N. Medical College
Jodhpur, Rajasthan, India

Dr. Abhijit SEN
KPC Medical College Kolkata,
West Bengal, India

Functional outcome of hemi-hamate arthroplasty in proximal interphalangeal joint fracture–dislocations

Dr. Ashok Meena, Dr. DS Meena, Dr. Nirottam Singh and Dr. Abhijit SEN

DOI: <https://doi.org/10.22271/ortho.2020.v6.i1j.1919>

Abstract

Aim of study was to access functional outcome in unstable dorsal PIP joint fracture dislocations. We evaluated 25 patients age between 18 to 35 years. Eligible patient had unstable dislocations with comminuted fractures involving at least 40% of the volar middle phalangeal surface. Outcomes were assessed by Motion/stability, grip strength and visual analog scales of pain and function. The mean follow-up period was 20 (range 18- 29) months. Surgery performed 38 days after injury (range 8–90 days). Average PIP motion was 88° range (75–110); DIP motion was 80° range (75–90), PIP flexion contracture 6.2° range (0–15°). Hemi-hamate arthroplasty provides good functional outcome with minimal donor site morbidity.

Keywords: PIP dislocation, hamate graft, shotgun volar approach

Introduction

Proximal interphalangeal joint (PIP) fracture dislocations are complex fracture patterns which are difficult to manage. The PIP joint is more prone to injury due to a long lever arm forces applied to the fingertip. If not treated properly, they can cause pain and poor function with flexion deformities [1]. Most accepted classification of the palmar lip injury is given by Hastings and Carroll [2]. This classification is based on the percentage of middle phalanx articular surface which is injured. PIP is a highly congruent joint that allow only a single plane of motion. The PIP joint has minimal laxity to compensate for angular, axial or rotational stresses.

Dorsal fracture dislocations are more common than volar dislocations and are considered unstable when the fracture fragment of the middle phalanx base is over 40% of the articular surface [3]. The goal of treatment of any injury around the proximal interphalangeal joint is to establish a congruent joint [4] and allow early mobilization.

A number of surgical options available for the treatment of unstable fractures including external fixation [5, 6], volar plate arthroplasty [7, 8]. Osteochondral autograft [9] and open reduction internal fixation (ORIF) with mini screws and Kirschner wires.

The aim of this study is to determine the clinical and radiological outcome in patients who underwent hemi hamate arthroplasty for PIP dorsal fracture-dislocations.

When >40% of the PIP joint surface is fractured there is dorsal PIP subluxation occur because the entire volar bony buttress is lost. Collaterals are attached only to the fracture fragment which creates instability to PIP joint.

Materials and Methods

This Prospective study was carried out in department of Orthopaedics, SMS Medical College & Hospital, Jaipur from April 2016 to December 2018. 25 patients were included in the study with unstable dorsal proximal interphalangeal fracture dislocations. (Joint comminution of $\geq 40\%$).

Mean age was 24.7 years (range 18–35). Most patients were students 68.0%, followed by teacher 8.0%. Most common mode of injury was Sports injury (19/25) due to cricket ball followed by RTA (4/25) and door entrapment (2/25).

Corresponding Author:
Dr. Ashok Meena
SMS Medical College Jaipur, 5 A,
Purender Ji Ka Baagh, Mooti
Doongri Road, Jaipur,
Rajasthan, India

Clinical examination & Surgical Technique

Inspection of the finger, for any swelling and tenderness. Radiograph including both true anterior-posterior and lateral view should be done and document dorsal "V sign for instability in true lateral view.

We used radially based volar flap to Access the Pip joint, incision was given from the base of the proximal digital crease to the distal interphalangeal (DIP) joint crease (Fig.1). Dissection done superficial to the neurovascular bundle down to the flexor sheath, elevating the subcutaneous tissue off the sheath and retract the neurovascular bundles. The sheath was incised between the A2 and A4 pulleys along the lateral edge. The flexor tendons are retracted. The accessory collaterals insert into the volar plate which were incised longitudinally. The volar plate is divided transversely at its distal insertion and elevated to its proximal insertion. The collateral ligaments released from their proximal insertion. Joint is bent dorsally 150° (shotgun- approach) and the flexor tendons were carefully retracted to the radial or ulnar side, the volar plate was folded proximally (Fig. 2, 3). At this point, the fracture site was completely exposed.

In chronic cases, a elevator is required to free the dorsal capsule and adhesions. The volar fragments were excised and prepared smoothly to facilitate firm placement of the hemihamate autograft. After measuring the bony defect for the appropriate graft size (Fig.4). We returned the PIP joint to neutral position.

Next, incision is made over the base of the fourth and fifth metacarpals. The capsule was incised and elevated to expose the hamate. Hamate has a central ridge and bicondylar facet with articular contours which are similar to the base of the middle phalanx. The appropriate size donor graft measured. The proximal end of the graft should be thicker than the articular portion to allow the graft to recreate the volar lip and appropriate buttress. The graft is prepared after removal to fit in the defect (Fig.5). The graft is held in place with a provisional 1mm Kirschner wire, and then two 1.3-mm screws are placed in lag fashion to secure the graft. (Fig.6) to the intact dorsal cortex to prevent movement. After the joint was reduced (Fig.7), graft position & size of screw confirmed by X-Ray. The volar plate was reattached to the fibrous remnant of the accessory collateral ligaments from which it was detached. Joint stability checked in flexion and extension position. We repaired the flexor sheath in its anatomical position.

Postoperative rehabilitation protocol

After operation, a dorsal splint was applied with PIP joint in 20° flexion to protect the volar plate. On next day of surgery, patients were allowed to perform PIP mobilization and passive stretching exercises without hyperextension. After 2 weeks full active and passive ROM exercises were started with dorsal splint on fingers to maintain the PIP joint in neutral extension.

Follow up

Clinical postoperative evaluation done that includes measurement of the range of motion at the proximal interphalangeal, and distal inter-phalangeal joints. Extension deficits of the PIP joint was noted. Grip strength was obtained for the injured and non-injured hand. Antero-posterior and lateral radiographs were taken at 4 to 6 weeks to evaluate bone healing and joint congruity.

Statistical analysis

Descriptive statistics of injury and surgery characteristics were performed.

Results

A total of 25 patients were included the study, 24 were male and 1 was female. The mean age was 24.7 years (range 18–35). The mean follow-up period was 20 months (range 18-29 month).

Radiological evaluation confirmed union of the graft in all patients after 5.9 weeks (range 5-7).

(Figure 10). Delay between injury and operation on average was 38 days (range 0–90). Mean operation time was 90 min (range 75–120). Power grip strength in the operated hand was 91 % of the healthy side. Total range of motion (ROM) of the PIP joint was 88 ° (range 75–110).

Extension deficit of the PIP joint on average was 6.2 ° (range 0–15), ROM of the DIP joint was 75 ° (range 75–90). (Fig. 10, 11). In our study Post operative pain, ability to perform daily Activities. were assessed. 21 patients reported no pain associated with the injured finger and remaining 4 patients reported pain only with heavy activity. All patients were return to their previous occupation.

Complication

There was no infection and one patient had revision surgery due to loosening of screw during mobilization. All patients were satisfied and no residual pain at involved digit Except one patient who had mild pain and unable to completely straighten the finger.

Discussion

Most of the PIP joint fracture dislocations are dorsal dislocation and associated with fracture of the volar articular surface of the base of middle phalanx. Stable injuries are treated conservatively. For unstable acute injuries (<6 week) various treatments has been proposed including extension block Orthosis, percutaneous pinning, external fixation^{5,6}, traction methods ^[10], static and dynamic, open reduction internal fixation (ORIF) with mini screw, volar plate arthroplasty ^[7, 8] (VPA) and hemi-hamate autograft⁹ reconstruction.

Chronic unstable injuries are difficult to manage and may leads to persist pain, stiffness and disability. Treatment options for these injuries are limited that includes Osteotomy with open reduction and internal fixation, PIP joint arthrodesis or arthroplasty, Volar plate arthroplasty ^[7, 8]. and hemi-hamate arthroplasty⁹. Volar plate arthroplasty causes recurrent dorsal subluxation, angulation, decrease PIP motion, distal interphalangeal (DIP) joint stiffness. Internal fixation with mini-screws provide several advantages over the K-wires but with multiple fracture fragments that are difficult to hold properly. With External fixation devices (Suzuki fram) there was risk of pin tract infections that are beneficial in fresh injury.

The concept of using an osteochondral autograft was advanced by Hastings *et al.* ^[11] in 1999, who described the use of a hemi-hamate autograft for the treatment of PIP fracture-dislocations. The main goal of this technique in restoration of both a congruent articular surface. N. Lindenblatt *et al.* ^[12] studied Hemi hamate Arthroplasty for acute and chronic PIP Joint Fracture Dislocations. After 93 days (range 0–371 days) of injury, average PIP motion was 71° (range 0–90); DIP motion was 54° (range 10–90) with a mean PIP flexion contracture of 6.5° (range 0–20). Grip strength was average

91% of opposite hand. M. Burnier *et al.* [14] in 2016, found the mean active flexion at the proximal interphalangeal joint was to 83° with a mean fixed flexion of 17°. The mean active distal interphalangeal motion was 41°.

We treated 25 patients in our hand surgery unit with this technique. Re-established range of motion of the PIP joint averaged 88° including an average PIP extension deficit of 6.2°. In our study we found that results are better, the difference may be due to early surgical intervention and early mobilization of PIP joint that helps to maximize ROM in the injured digit and prevent adhesions.

Study by Williams *et al.* showed that the capability of this technique to re-establish the volar base of the middle phalanx which provides joint stability and early motion rehabilitation [13]. Williams *et al.* in 2003, found a total range of motion of the PIP joint of 85 ° with an average extension deficit of 9° was almost similar to our study. The average follow-up period

was shorter in our study as compared to the Williams *et al.*, (8 vs. 16 months). The mean time between injury and hemi-hamate arthroplasty in their study was 45 days and in our study it was 38 days which indicate there were acute injuries with less long-term consequences like collateral band shortening, volar plate adhesions, joint capsule stiffness, etc. Grip strength was 91% of the uninjured hand after the operation.

The short-term results of hamate osteochondral grafts for PIP fracture-dislocation are good, long term assessments must be required to for cartilage viability.

Studies evaluating long-term results with respect to the development of secondary osteoarthritis after hemi-hamate arthroplasty reported that the development of mild to severe osteoarthritis is roughly in 50 % of the cases [13]. The follow-up in the our study was not long enough to account for these long-term sequelae.

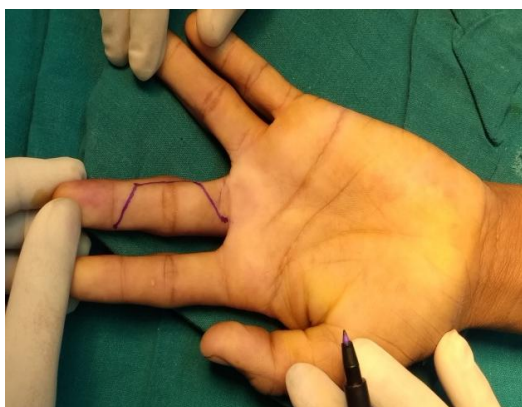


Fig 1: Access PIP- via a palmar incision

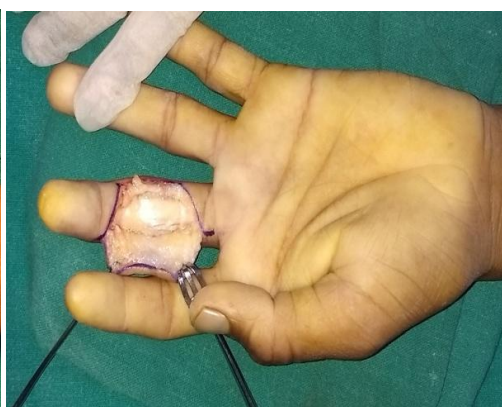

Fig. 2

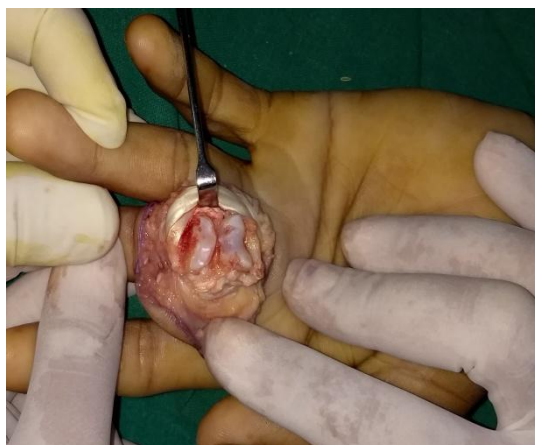

Fig 3: Joint is bent dorsally 150° (shotgun approach) and the joint surface, Fracture site becomes visible.

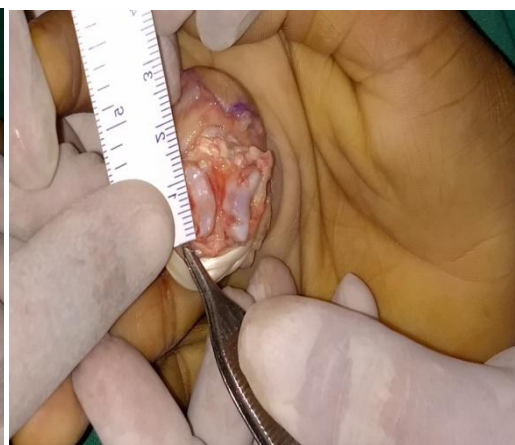

Fig 4: Dimensions of the bony defect are measured

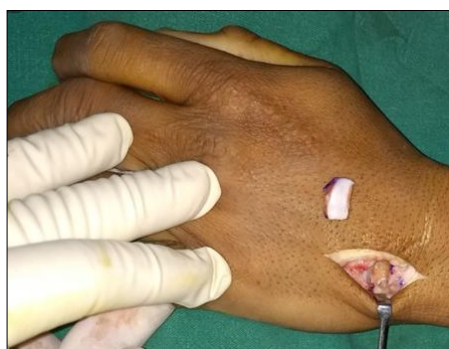

Fig 5: Graft is harvested from the dorsum of the hamate.

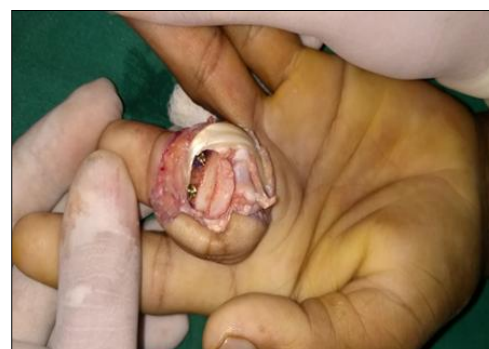

Fig 6: Hamate autograft in place and screws

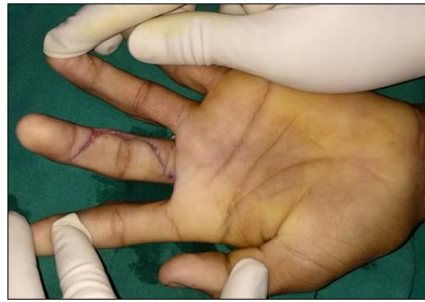

Fig.7 Reduction joint after Graft

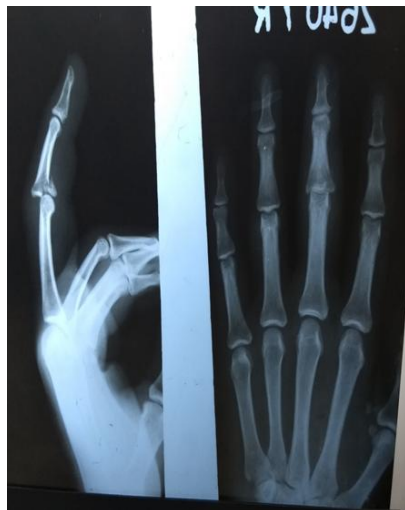

Fig 8: Pre op. X-Ray

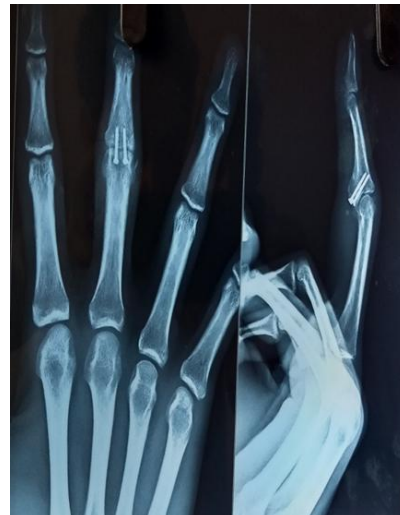

Fig 9: Post op. (5 week)-complete graft union

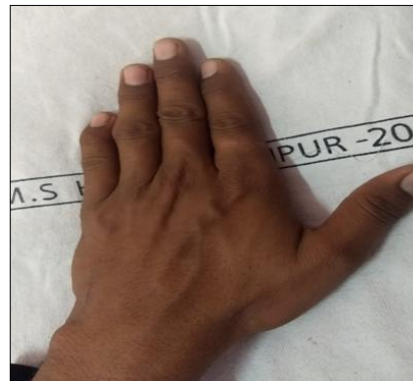
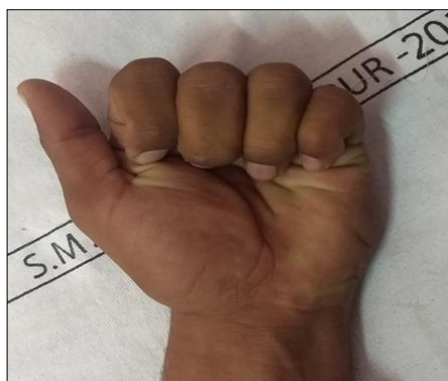

Fig 10-11: Post. operative hand function following hemi-hamate arthroplasty of the pip joint of the middle finger

Table 1: Patient characteristics

S. No	Age	Involved Hand	Injured Finger	Mode of Injury	Time Between Injury And Surgery (Days)	% Base Middle Phalanx Fracture
1	18	Dominant	Middle Finger	sports injury (cricket ball)	90	40%
2	24	non dominant	Ring finger	door Entrapment injury	45	50%
3	35	Dominant	Middle Finger	RTA	30	50%
4	20	Dominant	Ring finger	sports injury (cricket ball)	35	40%
5	18	Dominant	Middle Finger	sports injury (cricket ball)	60	40%
6	25	Dominant	Middle Finger	sports injury (cricket ball)	25	50%
7	18	non dominant	Ring finger	sports injury (cricket ball)	25	40%
8	21	Dominant	Ring finger	sports injury (cricket ball)	55	40%
9	22	nondominant	Middle Finger	sports injury (cricket ball)	8	50%
10	32	Dominant	Middle Finger	RTA	50	50%
11	21	nondominant	Ring finger	sports injury (cricket ball)	22	50%
12	20	Dominant	Middle Finger	sports injury (cricket ball)	40	40%
13	26	Dominant	Ring finger	sports injury (cricket ball)	30	40%
14	22	Dominant	Middle Finger	sports injury (cricket ball)	70	50%
15	25	nondominant	Middle Finger	sports injury (cricket ball)	35	40%
16	32	Dominant	Ring finger	RTA	22	60%
17	25	Dominant	Middle Finger	door Entrapment injury	15	50%

18	24	non dominant	Ring finger	sports injury (cricket ball)	37	50%
19	20	Dominant	Ring finger	sports injury (cricket ball)	45	60%
20	28	nondominant	Middle Finger	sports injury (cricket ball)	30	50%
21	26	nondominant	index finger	sports injury (cricket ball)	45	60%
22	27	nondominant	Ring finger	sports injury (cricket ball)	30	60%
23	30	nondominant	Ring finger	sports injury (cricket ball)	40	50%
24	33	Dominant	Middle Finger	RTA	30	40%

Table 2: Outcome of hemi-hamate arthroplasty

PIP ROM deg. (Post Op.)	Flexion Deformity at PIPJ	Radiological Union (WK)
100	5	6
85	10	6
80	10	6
95	0	5
85	10	5
80	10	6
110	0	7
80	5	6
90	10	5
85	5	7
95	0	6
95	0	5
80	15	6
80	10	6
85	5	5
80	10	6
85	5	7
80	0	6
90	5	5
90	10	6
95	5	7
80	10	6
90	5	6
95	5	7
90	5	6

Conclusion

Hemi-hamate arthroplasty is an excellent procedure for unstable dorsal fracture dislocations of PIP Joint with minimal donor site morbidity. Hemi-hamate arthroplasty restores a smooth joint surface of base of the middle phalanx.

Financial support and Sponsorship: Nil.

Conflicts of interest: No conflicts of interest.

References

- Benke GJ, Stapleforth PG. Injuries of the proximal interphalangeal joint of the fingers. *Hand*. 1979; 11:263.
- Hastings H, Carroll C. Treatment of closed articular fractures of the metacarpophalangeal and proximal interphalangeal joints *Hand Clin*. 1988; 4:503-527.
- Kiefhaber TR, Stern PJ. Fracture dislocations of the proximal interphalangeal joint. *J Hand Surg Am*. 1998; 23(3):368-80.
- Wilson JN, Rowland SA. Fracture-dislocation of the proximal interphalangeal joint of the finger. *J Bone Joint Surg Am*. 1996; 48:493-502.
- Hastings H, Ernst JM. Dynamic external fixation for fractures of the proximal interphalangeal joint. *Hand Clin*. 1993; 9:659-674.
- Agee JM. Unstable fracture dislocations of the proximal interphalangeal joint. Treatment with the force couple splint. *Clin Orthop*. 1987; 214:101-112.
- Deitch MA, Kiefhaber TR, Comisar BR, Stern PJ. Dorsal fracture dislocations of the proximal interphalangeal joint: surgical complications and long-term results. *J Hand Surg Am*. 1999; 24(5):914e-923.
- Dionysian E, Eaton RG. The long-term outcome of volar plate arthroplasty of the proximal interphalangeal joint. *J Hand Surg Am*. 2000, 25.
- Williams RM, Kiefhaber TR, Sommerkamp TG *et al*. Treatment of unstable dorsal proximal interphalangeal fracture dislocations using a hemi-hamate autograft. *J Hand Surg Am*. 2003; 28:856-865, (3):429e437.
- Schenck RR. Dynamic traction and early passive movement for fractures of the proximal interphalangeal joint. *J Hand Surg*. 1986; 11A:850-858.
- Hastings H, Capo J, Steinberg B *et al*. Hemicondylar hamate replacement arthroplasty for proximal interphalangeal joint fracture/dislocations. 54th Annual Meeting of the American Society for Surgery of the Hand. Boston MA, 1999.
- Lindenblatt N, Biraima A, Tami I, Giovanoli P, Calcagni M. Hemi-hamate Autograft Arthroplasty for Acute and Chronic PIP Joint Fracture Dislocations. *Handchir Mikrochir Plast Chir*. 2013;45:13-19.
- Afendras G, Abramo A, Mrkonjic A, Geijer M, Kopylov P, Ta' Gil M. Hemi-Hamate Osteochondral Transplantation In Proximal Interphalangeal Dorsal Fracture Dislocations. *(The Journal of Hand Surgery, European*. 2010; 35E(8):627-631.
- Burnier M, Awada T, Marin Braun F, Rostoucher P, Ninou M, Erhard L. Unstable proximal interphalangeal joint fractures with hemi-hamate osteochondral autografts Hemihamate arthroplasties *The Journal of Hand Surgery*, 2016.