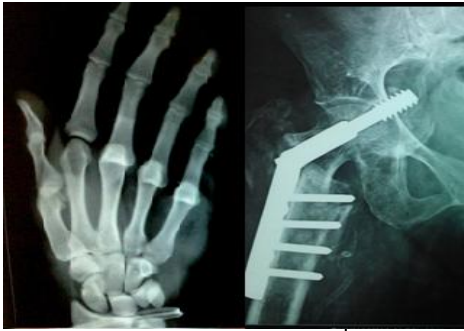

International Journal of Orthopaedics Sciences

E-ISSN: 2395-1958
P-ISSN: 2706-6630
IJOS 2020; 6(1): 446-454
© 2020 IJOS
www.orthopaper.com
Received: 21-11-2019
Accepted: 25-12-2019

Dr. Sharat Balemane
Assistant Professor, Department
of Orthopaedics, Yenepoya
Medical College, Mangalore,
Karnataka, India

Dr. Adarsh Vajrangi
Research Scholar, Department of
Orthopaedics, Yenepoya Medical
College, Mangalore, Karnataka,
India

Dr. Thippeswamy
Assistant Professor, Department
of Anaesthesiology Yenepoya
Medical College, Mangalore,
Karnataka, India

Dr. Fardeen Sharief
Senior Resident, Department of
Orthopaedics Yenepoya Medical
College, Mangalore, Karnataka,
India

Comparative study of the effect of suprascapular nerve block under ultrasound guidance and blind shoulder infiltration (Using lignocaine and methylprednisolone acetate) in chronic shoulder pain

Dr. Sharat Balemane, Dr. Adarsh Vajrangi, Dr. Thippeswamy and Dr. Fardeen Sharief

DOI: <https://doi.org/10.22271/ortho.2020.v6.i1h.1905>

Abstract

Introduction: Shoulder joint is very important joint for day to day activities and pain in shoulder results in leads to increased functional disability with poor quality-of life. Chronic shoulder pain common complaints encountered by treating physicians all over world. The incidence of chronic shoulder pain is approximately 15-30% with variations among different population and age groups. The treatment modalities available for alleviating chronic shoulder pain varies from simple anti-inflammatory drugs to interventional procedures like intra-articular steroid injections, supra-scapular nerve block (SSNB).

AIM: To compare the pain relief and return of function in shoulder joint using suprascapular nerve block under ultrasound guidance (lignocaine and methylprednisolone acetate) versus shoulder infiltration (lignocaine and methylprednisolone acetate) in chronic shoulder pain.

Study Design: Prospective, randomised study, data was collected from patients with chronic shoulder pain in the age group of 18-60 years coming to orthopedic outpatient department at Yenepoya Medical College Hospita with chronic shoulder pain.

Materials and Methods: Suprascapular nerve block group: 2ml of 40mg methyl prednisolone +2ml of lignocaine given, supervision of anesthetist under ultrasound guidance. Intra articular steroid group: 2ml of 40mg methyl prednisolone acetate +2ml 2% lignocaine hydrochloride given through posterior approach to shoulder. Eligible participants was randomly assigned to receive the same combination of medications either by supra scapular nerve block under ultrasound guidance or blind shoulder infiltration and compare the effect of lignocaine and corticosteroid in suprascapular nerve block and shoulder infiltration in chronic shoulder pain by assessing DASH score, Constant-Murley score, SPADI score and VAS pain score on day 7 and day 28 of the procedure.

Results: There were no significant differences between the groups in terms of pain, demographic variables, Range of movement and disability scores when compared to baseline. ($p > 0.05$). However suprascapular nerve block showed slight better improvement in pain, range of movement and disability score at initial (i.e. at 1week) and at 4 week follow up when compared with that of intra-articular steroid infiltration but scores were not statistically significant. Parameters obtained in both groups were significant at final assessments when compared to the baseline scores.

Conclusion: Suprascapular nerve block can be considered as a safe, effective, well tolerated treatment and alternative line of treatment in patient suffering from chronic shoulder pain.

Keywords: Chronic shoulder pain, supra scapular nerve block, intra-articular injection

Introduction

Shoulder joint is very important joint for day to day activities and pain in shoulder results in leads to increased functional disability with poor quality-of life ^[1]. Chronic shoulder pain is defined as shoulder pain lasting for a period of more than 6 months. Shoulder joint pain is one of the common complaints encountered by treating physicians all over world ^[1]. Prevalence of shoulder pain varies widely (from 1% to 67%) across different population. The incidence of chronic shoulder pain is approximately 15-30% with variations among different population and age groups ^[2-4]. The most common etiologies of chronic shoulder disorders include rotator cuff syndrome, gleno-humeral joint osteoarthritis, adhesive capsulitis, post traumatic pain and

Corresponding Author:
Dr. Adarsh Vajrangi
Research Scholar, Department of
Orthopaedics, Yenepoya Medical
College, Mangalore, Karnataka,
India

persistent pain following surgery [5]. Other causes can be rheumatologic disorders like osteoarthritis, fibromyalgia, rheumatoid arthritis or secondary to the damage of nerves supplying shoulder joint due to trauma or neurodegenerative diseases like diabetes, chronic alcoholism, etc. Condition in which steroid are contraindicated are Septic arthritis, tuberculosis, uncontrolled diabetic mellitus, systemic infection. The treatment modalities available for alleviating chronic shoulder pain varies from simple anti-inflammatory drugs to interventional procedures like intra-articular steroid injections, supra-scapular nerve block (SSNB), etc.[6] A substantial number of patients may not be appropriate surgical candidates, or they may have significant medical comorbidities. SSNB has a long history of reducing pain and improving range of motion in patients with shoulder pain [7]. The supra-scapular nerve (SSN) innervates nearly 70% of the shoulder joint and therefore, its blockade is a commonly accepted mode of pain therapy in acute and chronic settings [8]. SSNB being simple, inexpensive and associated with minimal complication [9]. Different approaches in blocking the SSN to reduce its complications have been proposed by different authors. The incidence of pneumothorax associated with supra-scapular block is reported as <1%. Avoiding entering the supra-scapular notch in the vertical plane has been postulated to decrease the risk of pneumothorax [10]. The present study describes a novel technique to block SSN for chronic shoulder pain.

Supra-scapular nerve anatomy:

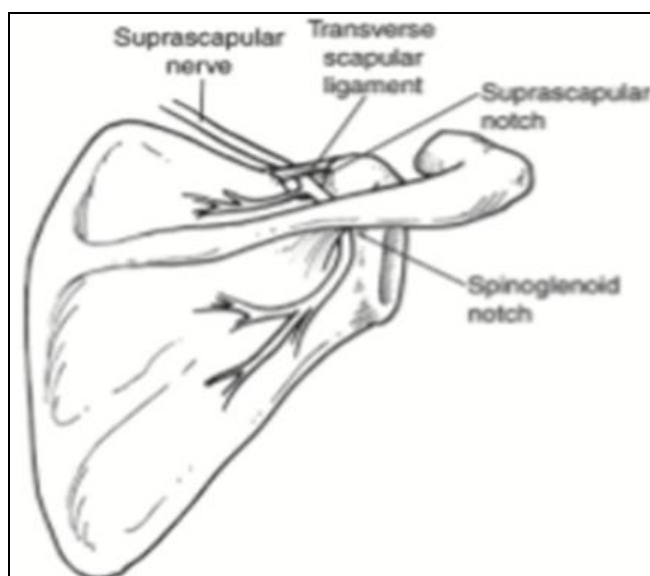


Fig 1: Suprascapular nerve course and relations [11]

Supra-scapular nerve, a mixed nerve, originates in upper trunk of brachial plexus, C5 and C6 roots, receiving in over 50% contributions of C4 root and crosses the deep posterior triangle of neck, below omohyoid muscle and trapezium, entering the supra-scapular incisures/notch below the superior transverse scapular ligament. The nerve then enters into the supra-scapular fossa, where two motor branches to the supraspinatus muscle originate [fig1]. Just proximal to the

supra-scapular notch, the SSN gives off the sensitive branches, which travels with it through the notch before proceeding laterally to innervate the acromio-clavicular joint and its associated bursa and the coraco-clavicular and coracohumeral ligaments. It continues its descending oblique path bypassing the spinoglenoid (SGN) incisure, under the inferior transverse scapular ligament present in 50% of people. It follows then toward the infraspinatus fossa, in which it provides three to four motor branches for infraspinatus muscle.

Sonoanatomy

Sonographically, the suprascapular nerve often appears hyperechoic. At the suprascapular notch, the suprascapular nerve is located deep to the supraspinatus muscle and also deep to the suprascapular artery (SSA) and the superior transverse scapular ligament [fig-4] (STSL) [12-24].

Materials and Methods

The data was collected after ethical committee clearance for the study is obtained. After explaining the procedure, participants willing to enroll will be asked to read the participant information sheet, clarify doubts and sign the consent form. Data was collected from patients with chronic shoulder pain in the age group of 18-60 years coming to orthopedic outpatient department at Yenepoya Medical College Hospital. The eligible participants was randomly assigned to receive the same combination of medications either by supra scapular nerve block under ultrasound guidance or blind shoulder infiltration and compare the effect of lignocaine and corticosteroid in suprascapular nerve block and shoulder infiltration in chronic shoulder pain by assessing DASH score, Constant-Murley score, SPADI score and VAS pain score on day 7 and day 28 of the procedure. The intervention will be carried out by principal investigator under the physical guidance of the co-PI. The ultrasound scanning will be done (co-PI). All care will be taken to ensure good quality of health care.

Group A: suprascapular nerve block group: 2ml of 40mg methyl prednisolone +2ml of lignocaine given, supervision of anesthetist under ultrasound guidance.

Group B: intra articular steroid group: 2ml of 40mg methyl prednisolone acetate +2ml 2% lignocaine hydrochloride given through posterior approach to shoulder.

Treatment options K, H

Group A

Scanning technique

The technique consists of injecting anesthetic agent in supraspinatus fossa of affected shoulder, with the patient sitting down and upper limbs pending beside the body, palpate anatomical parameters like clavicle, acromioclavicular articulation, acromion, scapula spine and coracoid process. This entire area is sterilized with alcohol, the needle introduction on a perpendicular line is drawn from the angle of the scapula upward to bisect the spine of the scapula. About 2cm lateral to the intersecting point, in the upper outer quadrant of the scapula [fig3].

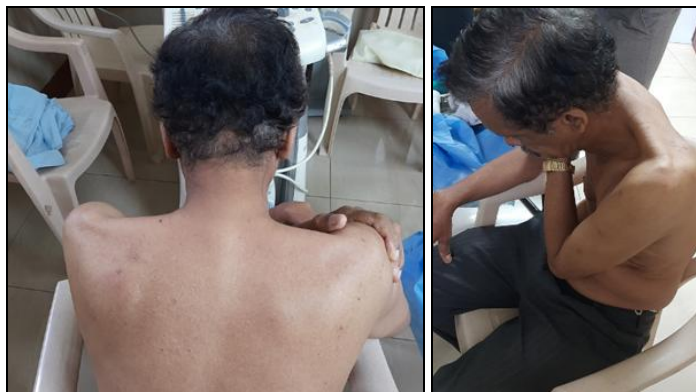

Fig 2: Patient in sitting position and place the hand over to the contralateral shoulder. This will move the scapula laterally to provide more space for SSN scanning.

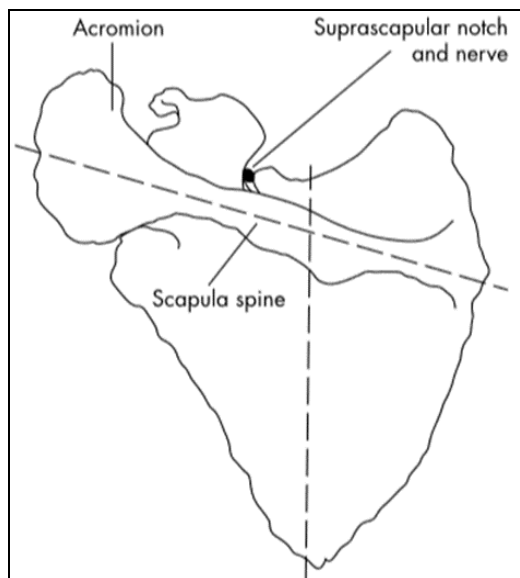


Fig 3: Suprascapular nerve block (using bupivacaine and methylprednisolone acetate) in chronic shoulder pain E M Shanahan, M Ahern *et al...*^[25]

Preparation of skin and transducer done, a linear 38-mm high frequency 10-12 MHz transducer was placed on scapula and transverse view of the suprascapular nerve (SSN) and suprascapular vessels with best possible way was obtained. Patient was asked to place the hand over to the contralateral shoulder [fig 2]. This will make scapula to move more laterally to provide space for SSN scanning. This will also make the target SSN injection to be placed more laterally away from thorax and surrounding structure. Transducer was placed oblique to the spine of the scapula in the supraspinous

fossa because oblique course of SSN between the suprascapular notch and spinoglenoid notch. The transducer on one side was placed over the scapular spine and other side directing towards the coracoid process ^[12-24].

Localization of Nerve

Trapezius muscle (TZ, more superficial) and the supraspinatus muscle (SSM). The bony landmarks are the supraspinous fossa, the suprascapular notch located anterior at the lateral part of the superior margin of the scapula and the spinoglenoid notch located more postero-laterally.

SSM was first identified, when compared to overlying trapezius muscle SSM was thicker and was present in supraspinous fossa. A continuous hyperechoic line deep to the SSM was visualised to be floor of supraspinous fossa. Transducer was moved laterally to visualize the acromial end of the clavicle and/or the acromion; both cast a superficial bony shadow. Outer end of the transducer was turned slowly and anteriorly towards the tip of the palpable coracoid process. Transducer slowly angled anteriorly to visualize the suprascapular notch. One can visualise the SSN with in the scapular foramen at suprascapular notch. Above the SSN suprascapular artery can be visualised and the superior transverse scapular ligament. Pneumothorax can be caused by accidental anterior advancement of the needle by puncturing the pleura. Supraspinous fossa was followed posteriorly to find the neck of the scapula which shows up as a depression of the supraspinous fossa bone shadow. The optimal location to perform SSN block is half way between the scapular notch and the spinoglenoid notch. The SSN is located next to the suprascapular artery and underneath the deep fascia of the SSM ^[12-24].

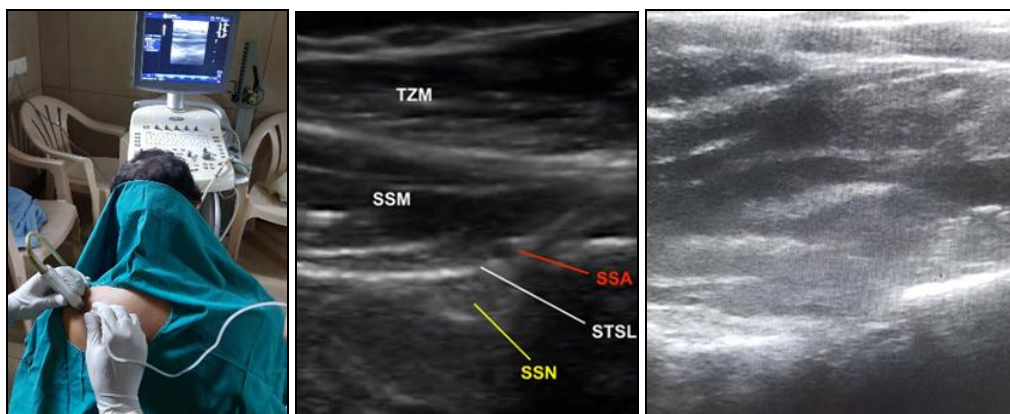


Fig 4: Sonoanatomy of suprascapular nerve and its surrounding structures over the suprascapular notch

Needle insertion approach

Halfway between the suprascapular and the spinoglenoid notches SSN is blocked and there is no need to visualize the notches at the time of injection [fig 5] ^[12-24].

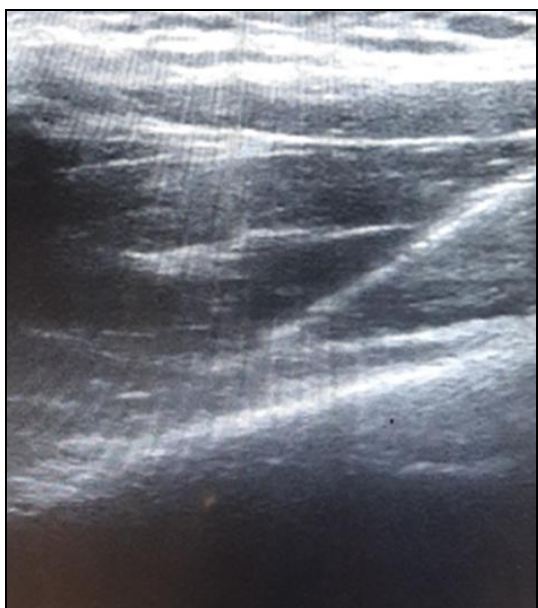

Fig 5: Sonogram showing the needle tip in the supraspinatus muscle heading towards the suprascapular nerve

Local anesthetic injection

First local anesthetic with corticosteroid was injected deep to the fascia of the SSM. If local anesthetic spread is detected initially within the SSM, it is necessary to advance the needle further to traverse the fascia of the SSM [fig6] ^[12-24].

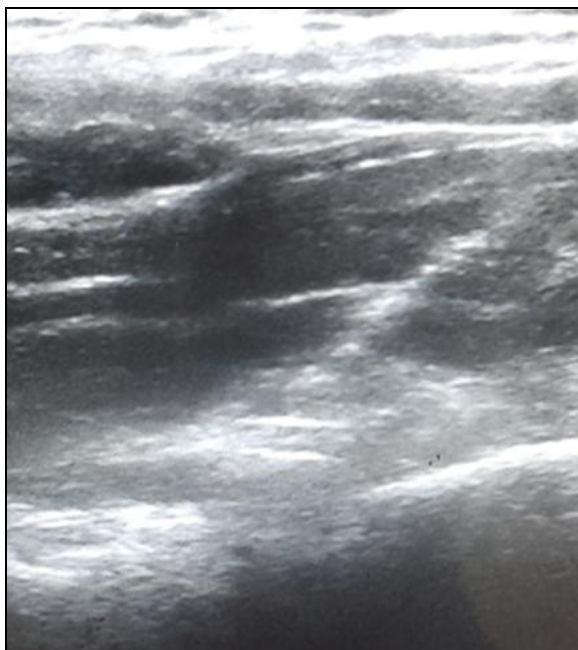


Fig 6: Sonogram showing a local anesthetic bolus injected immediately above the suprascapular nerve and artery

Group B: Intra articular steroid the needle will be inserted 2 to 3cm inferior to the posterolateral corner of the acromion and directed anteriorly in the direction of the coracoid process. As with any injection, aspiration will be done to ensure that there has not been needle placement in the blood vessel. Injection was given slowly, but with consistent pressure.

Source of Data: Patients undergoing procedure for compare the effect of lignocaine and corticosteroid infiltration in suprascapular nerve block and shoulder infiltration in chronic shoulder pain at Yenepoya Medical College from period of NOV 2019 to Feb 2020.

Sample Size

- 40 patients were included in study, patient with chronic shoulder pain with minimum of 6 months duration who come to orthopaedics OPD.
- 20 patients in intra-Articular steroid infiltration and 20 patients in suprascapular nerve block.
- Sampling technique- simple random sampling technique
- Randomization- Simple random
- Validation of study tool-Pre-validated tools are being used
- Data will be analysed using SPSS version 23 and presented at mean +/-SD. Patient characteristic data will be analysed with one way ANOVA for continuous variable and chi square test for categorical value. P <0.05 will be considered as significant.

Statistical Analysis

1. Data will be entered in MS excel.
2. Data will be analysed in SPSS version 22
3. Variable (Test used to assess): Age (one sample t test), Sex (chi-square test), Diagnosis (Chi square test), Side affected (Chi square test)

Inclusion criteria

All patients with a chronic shoulder pain have to meet the following inclusion criteria before enrollment:

- Pain and stiffness in one or both the shoulders for at least 6 months.
- Restricted and passive range of motion at the glenohumeral joint.
- Pain at night causing sleep disturbance and inability to lie on the affected side.
- No history of recent trauma.
- No previous injection in the involved shoulder.
- No history of allergy to local anesthetics.
- No medical condition such as coagulation disorders.

Exclusion Criteria

If one of the following exclusion criteria applies, the patient is not eligible for the study:

Condition in which steroid are contraindicated are Septic arthritis, tuberculosis, uncontrolled diabetic mellitus, systemic infection and hence following clinical examination and investigation are done in detail to rule out the above pathology and the patient are included in the above study. If any of above condition patient is suffering with they are excluded from the study.

- 1) **Septic arthritis:** Clinical history and examination+ blood investigation (CBC, ESR and CRP).
- 2) **Diabetic mellitus:** FBS, PPBS, hba1c(if k/c/o DM or symptoms suggestive of DM)
- 3) **Tuberculosis:** Clinical history (UN explained weight loss and loss of appetite), x ray of shoulder joint if pathology suspected.
- 4) **System infection:** History, CBC, ESR, CRP

Discontinuation criteria: Patients with irregular follow-up was excluded from the study.

Adverse events: We did not find any adverse events in either of the groups. However, any unanticipated adverse event occur (such as hypersensitivity to methylprednisolone), the same was adequately managed by the co-PI.

Rehabilitation

The patients was prescribed NSAIDs for five days in patient in both group and was taught home exercise program to be done by patients themselves. The home exercise program comprised of wall slides, wand exercises, towel stretch, active capsular stretch exercise, pendulum exercise and shoulder circumduction [Fig 7].

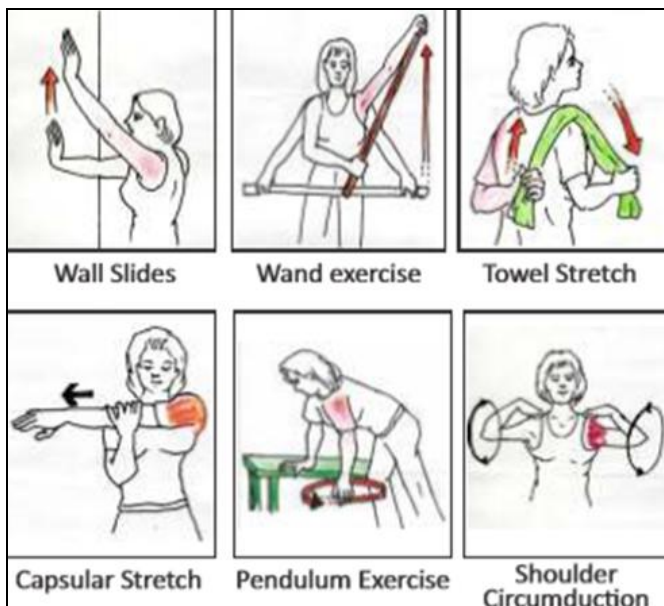


Fig 7: Rehabilitation-home exercise programme

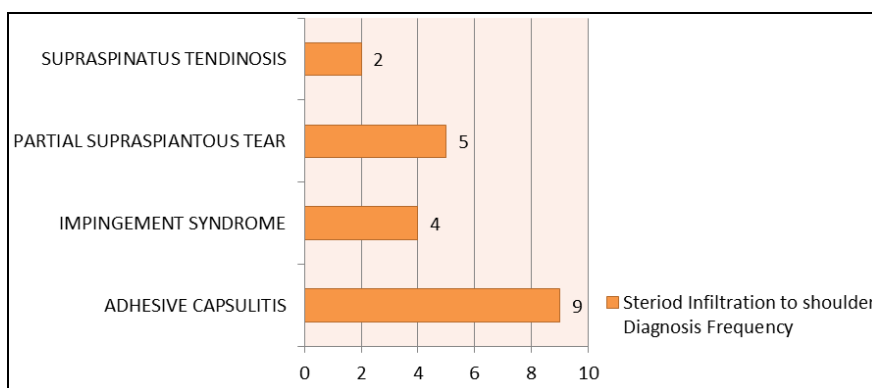
Results and Interpretation

Forty patients (16 females and 24 males) with the mean age

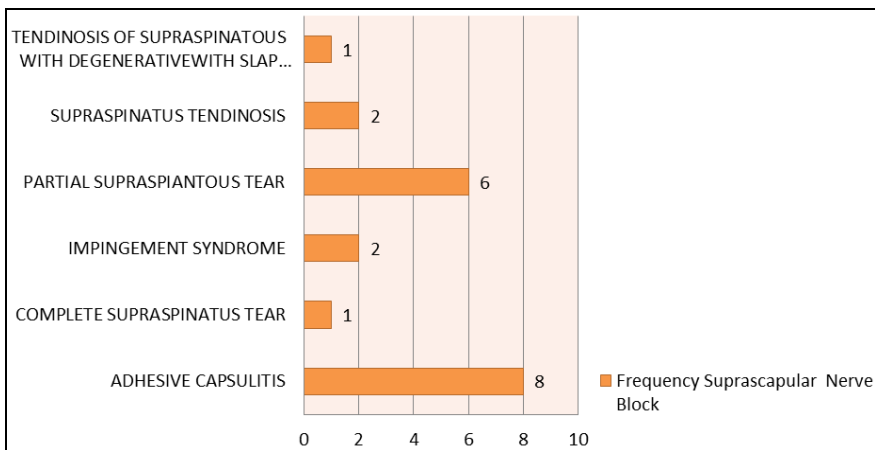
of 49.57 years were included in this study. In SI group, there were 7 females and 13 males with the mean age of 50.25±5.955years (ranged between years). Duration of the symptoms was more than 6 months in all the patients. 10 patients (50%) had dominant shoulder involvement (Table 1). In SSNB group, there were 9 females and 11 males with the mean age of 48.85 ±7.088 years (ranged between years). Duration of the symptoms was more than 6 months in all 20 patients. 10 patients (50%) had dominant shoulder involvement (Table 1). All the patients both in steroid infiltration as well as suprascapular nerve block group had come for regular follow-up assessment. 1 complications occurred in SSNB group-patient had initial relief in pain but gradually after period of 1week patient started complaining of severe pain and underwent MRI of shoulder and was diagnosed to have complete tear of rotator cuff, later patient underwent rotator cuff repair. 3 patients in SI group complained for increase in pain but gradually pain was reduced within 3-4 days. At final assessment no patient claimed for any side effect of the interventions. Constant score in suprascapular group- 7(good), 10(satisfactory) and 3 (adequate) at 4 weeks of follow up and that in intra-articular steroid infiltration group was-8 (good), 7(satisfactory), 4(adequate) and 1(poor) result was noted [fig8 and 9]. There were no significant differences between the groups in terms of pain, demographic variables, Range of movement and disability scores when compared to baseline. (p >0.05). However suprascapular nerve block showed slight better improvement in pain, range of movement and disability score at initial (i.e. at 1week) and at 4 week follow up when compared with that of intra-articular steroid infiltration but scores were not statistically significant. Parameters obtained in both groups were significant at final assessments when compared to the baseline scores (Tables 2 and 3). No statistically significant difference in the improvements of follow-up parameters was obtained between the groups after the treatment and at the final assessment (Table 4).

Table 1: Demographic data of the patients and their relation with Symptoms

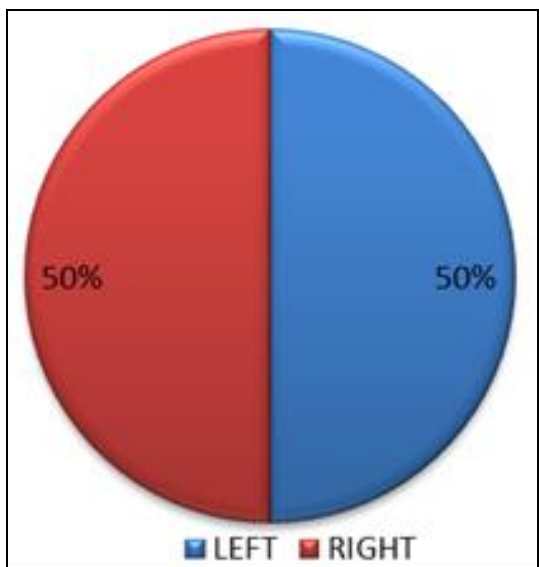
	SIS Group	SNB Group	Relation (p)
Age	50.25 ±5.955	48.85 ±7.088	0.229
Sex (Male/Female)	13 (65%) 7 (35%)	11 (55%) 9 (45%)	0.423
Diagnosis			0.698
Adhesive Apsulitis	9 (45%)	8 (40%)	
Complete Supraspinatus Tear	0 (0%)	1 (5%)	
Impingement Syndrome	4 (20%)	2 (10%)	
Partial Supraspinatus Tear	5 (25%)	6 (30%)	
Supraspinatus Tendinosis	2 (10%)	2 (10%)	
Tendinosis Of Supraspinatus With Degenerative with Slap 1 Tear	0 (0%)	1 (5%)	



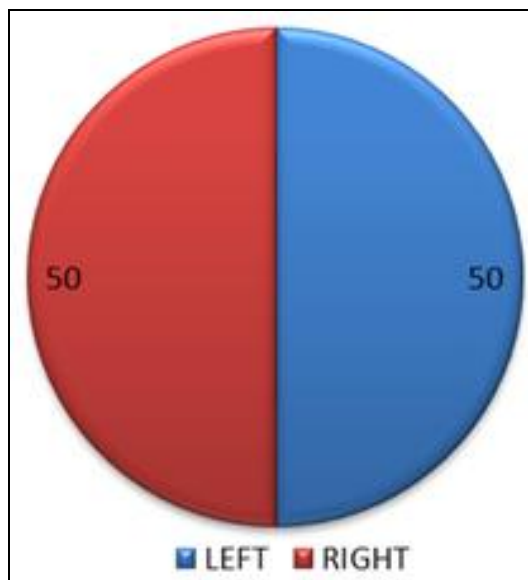
Bar graph 1: Steroid Infiltration to shoulder Diagnosis



Bar graph 2: Suprascapular Nerve Block Diagnosis



Pie Chart 1: Steroid Infiltration to shoulder Side affected



Pie Chart 2: Suprascapular nerve block shoulder side affected

Table 2: Differences in follow up in the Steroid Infiltration to shoulder (one sample t test)

	PRE-operative	1 st week		4 th weeks	
	Mean ±SD	Mean ±SD	P	Mean ±SD	p
Dash core	51.48 ±19.36	31.72 ±16.81	0.0	11.5 ±5.85	0.0
Vas score	7.24 ±1.513	2.80 ±1.82	0.0	0.75 ±1.07	0.005
Spadi score	59.80 ±14.53	35.14 ±14.99	0.0	13.09 ±5.29	0.0
Constant murley	31.35 ±12.88	57 ±10.63	0.0	75.65 ±9.02	0.0

Table 3: Differences in follow up in the suprascapular nerve block (one sample t test)

	Pre-operative	1 st week		4 th weeks	
	Mean ±SD	Mean ±SD	P	Mean ±SD	p
Dash score	50.15 ±12.04	23.74 ±10.80	0.0	9.67 ±7.41	0.0
Vas score	7 ±1.52	2.15 ±1.08	0.0	0.35 ±0.81	0.69
Spadi score	61.84 ±18.52	29.23 ±15.01	0.0	12.64 ±13.23	0.0
Constant murley	32.60 ±13.44	59.22 ±10.60	0.0	76.24 ±5.85	0.0

Table 4: Differences in improvements between the groups (Independent sample t test)

	1 st week		4 th weeks	
	t	p	t	P
Dash score	-1.791	0.081	-0.863	0.393
Vas score	-1.368	0.179	-1.331	0.191
Spadi score	-1.245	0.221	-0.141	0.888
Constant murley	0.661	0.513	0.245	0.808



Fig 8: Before infiltration restriction of abduction, internal rotation and flexion of right shoulder



Fig 9: Improvement with painless range of movement at 4 weeks of follow up after suprascapular nerve block

Discussion

Despite the several advances in the field of chronic pain, we still do not fully understand the nature and mechanisms of these condition. Previous results about intra-articular steroid injection to shoulder pain are controversial with different steroid preparations and by using different routes these results are usually compared with physiotherapy. In this study, we found no significant difference in pain relief, range of movement and functional outcome of Intra-articular steroid infiltration when compared with the ultrasound-guided steroid infiltration with local anaesthesia around suprascapular nerve in patient suffering from chronic shoulder pain of more than 6 months duration. The effect was prolonged and sustained even at the 6th week of follow-up. Taskaynatan *et al.* [23, 28] compare the effects of suprascapular nerve block with those of steroid injection in patients with non-specific shoulder pain. A total of 60 patients with shoulder pain lasting for more than four week. 30 patient is each group was included after randomization. Patients were evaluated before treatment, within one week and one month later, in terms of pain, range of motion, satisfaction, and disability. The difference in all follow-up parameters was statistically significant in the assessment periods in both groups ($p < 0.05$). No complications was noted in suprascapular nerve block when compared to steroid injection. In other study done by Davinder Kumar Verma *et al*, 2019 [27] A prospective randomized, single dose of IASI (intra-articular steroid injection) with ultrasound-guided suprascapular nerve block (USNB) in patients with AC of ≥ 12 weeks'. The functional outcome measures were assessed with SPADI and passive range of motion (ROM). Follow-up at 1-week, 3-week, and 6-week time-points. However, there was no statistically significant differences were found between the two groups at baseline or at follow-up ($P > 0.05$). Comparing SSNB with other interventions, Jones and Emery [25-26] demonstrated that SSNB was superior to conventional physiotherapy at 1month in patients with adhesive capsulitis and rotator cuff tendinitis,

respectively. Comparing SSNB with intra-articular corticosteroid injection, Kamel and Adey-[26] Wakeling demonstrated that SSNB was superior in pain intensity and range of motion at 1 month in rheumatoid arthritis and adhesive capsulitis patients, respectively, while [27] Wassei found no statistically significant differences at 1 month in hemiplegic shoulder pain [29-30].

The results of the present study was more familiar with above study. SSNB can be considered as simple, safe and most accurate procedure when done under ultrasound guidance. SSNB can be considered as other therapeutic options such as anti-inflammatory drugs and IASIs [30]. Because it reduces peripheral inputs and decrease central sensitization of postsynaptic dorsal horn nociceptive neurons of the spinal cord [31]. Also causes depletion of substance P and nerve growth factor in the synovium and afferent C fibers of the glenohumeral joint after the blockade may also contribute to the long-term relief [32]. It also causes transient reduction in the local sensitization that could enable patients to have a better compliance with the recommended exercises, which have a known therapeutic effect [33]. We may affirm that there is a benefit of SSNB in shoulder pain of different etiologies in terms of pain, range of motion and function, that seems to be superior to the classic therapeutic modalities

Conclusion

- No significant difference was noted in pain, shoulder ROM and functional score between both intra-articular steroid infiltration and suprascapular nerve block in the present study.
- No major complications were associated in either of group. However initial (1st week) and final functional outcome (4th weeks) of suprascapular nerve block was slightly better when compared to intarticular steroid infiltration.
- This study provides evidence that suprascapular nerve block can be considered as a safe, effective and well

tolerated treatment for patients with chronic shoulder pain.

- Suprascapular nerve block can be considered as alternative treatment with patient suffering from chronic shoulder pain.
- Further randomized multicentric study with adequate follow up is required for further arrival of conclusion.

Limitation

- Small sample size with short follow up.
- All of the studies were conducted in outpatient settings and hence our findings are generalisable to those settings.

References

- Kemp BJ, Bateham AL, Mulroy SJ, Thompson L, Adkins RH, Kahan JS. Effects of reduction in shoulder pain on quality of life and community activities among people living long-term with SCI paraplegia: A randomized control trial. *J Spinal Cord Med.* 2011; 34:278-84.
- Luime JJ, Koes BW, Hendriksen IJ, Burdorf A, Verhagen AP, Miedema HS *et al.* Prevalence and incidence of shoulder pain in the general population; a systematic review. *Scand J Rheumatol.* 2004; 33:73-81.
- Pribicevic M. The Epidemiology of Shoulder Pain: A Narrative Review of the Literature, Pain in Perspective. Ch. 7. Intech Publishers; ISBN 978-953-51-0807-8, Published: October 24, 2012.
- Taskaynatan MA, Yilmaz B, Ozgul A, Yazicioglu K, Kalyon TA. Suprascapular nerve block versus steroid injection for non-specific shoulder pain. *Tohoku J Exp Med.* 2005; 205:19-25.
- Uhl RL. Shoulder pain. In: Smith HS, editor. *Current Therapy in Pain.* Philadelphia, PA: Saunders Elsevier, 2009, 147-51.
- Simopoulos TT, Nagda J, Aner MM. Percutaneous radiofrequency lesioning of the suprascapular nerve for the management of chronic shoulder pain: A case series. *J Pain Res.* 2012; 5:91-7.
- Pitkin GP, editor. Therapeutic nerve block. In: *Conduction Anesthesia.* Philadelphia, PA: JB Lippincott, 1946, 884-6.
- Karatas GK, Meray J. Suprascapular nerve block for pain relief in adhesive capsulitis: Comparison of 2 different techniques. *Arch Phys Med Rehabil.* 2002; 83:593-7.
- Woolf CJ. Somatic pain-Pathogenesis and prevention. *Br J Anaesth* 1995; 75:169-76.
- Harmon D, Hearty C. Ultrasound-guided suprascapular nerve block technique. *Pain Physician.* 2007; 10:743-6.
- Kninç Z. Addition of suprascapular nerve block to a physical therapy program produces an extra benefit to adhesive capsulitis a randomized controlled trial. *Am J Phys Med Rehabil?* 2015; 94:912-20. Doi:10.1097/PHM.0000000000000336.
- Salgia A, Agarwal T, Puri SR, Sanghi S, Mohapatra A. Role of suprascapular nerve block in chronic shoulder pain: A comparative study of 60 cases. *Medical Journal of Dr. DY Patil University.* 2014; 7(1):44.
- Battaglia PJ, Haun DW, Dooley K, Kettner NW. Sonographic measurement of the normal suprascapular nerve and omohyoid muscle. *Man Ther.* 2014; 19:165-8.
- Borglum J, Bartholdy A, Hautopp H, Krogsgaard MR, Jensen K. Ultrasound-guided continuous suprascapular nerve block for adhesive capsulitis: one case and a short topical review. *Acta Anaesthesiol Scand.* 2011; 55:242-7.
- Chan C-W, Peng PWH. Suprascapular nerve block: a narrative review. *Reg. Anesth Pain Med.* 2011; 36:358-73.
- Draeger RW, Messer TM. Suprascapular nerve palsy following supraclavicular block for upper extremity surgery: report of 3 cases. *J Hand Surg Am.* 2012; 37:2576-9.
- Elsharkawy HA, Abd-Elsayed AA, Cummings KC, Soliman LM. Analgesic efficacy and technique of ultrasound-guided suprascapular nerve catheters after shoulder arthroscopy. *Ochsner J.* 2014; 14:259-63.
- Hackworth RJ. A new and simplified approach to target the suprascapular nerve with ultrasound. *J Clin Anesth.* 2013; 25:347-8.
- Herring AA, Stone MB, Nagdev A. Ultrasound-guided suprascapular nerve block for shoulder reduction and adhesive capsulitis in the ED. *Am J Emerg Med.* 2010.
- Ko SH, Kang BS, Hwang CH. Ultrasonography- or electrophysiology-guided suprascapular nerve block in arthroscopic acromioplasty: a prospective, double-blind, parallel-group, randomized controlled study of efficacy. *Arthroscopy.* 2013; 29:794-801.
- Peng PWH, Wiley MJ, Liang J, Bellingham GA. Ultrasound-guided suprascapular nerve block: a correlation with fluoroscopic and cadaveric findings. *Can J Anaesth.* 2010; 57:143-8.
- Siegenthaler A, Moriggl B, ML Ekusch S, Schliessbach J, Haug M, Curatolo M *et al.* Ultrasound-Guided Suprascapular Nerve Block, Description of a Novel Supraclavicular Approach. *Reg Anesth Pain Med.* 2012.
- Soneji N, Peng PWH. Ultrasound-guided pain interventions-a review of techniques for peripheral nerves. *Korean J Pain.* 2013; 26:111-24.
- Taskaynatan MA, Ozgul A, Aydemir K, Koroglu OO, Tan AK. Accuracy of ultrasound-guided suprascapular nerve block measured with neurostimulation. *Rheumatol Int* 2011.
- Verma DK, Neyaz O, Nanda S, Handa G. Comparison of outcome of ultrasound-guided suprascapular nerve block versus intra-articular steroid injection in adhesive capsulitis of shoulder: A randomized control trial. *Indian Journal of Rheumatology.* 2019; 14(2):113.
- Jones D, Chattopadhyay C. Suprascapular nerve block for the treatment of frozen shoulder in primary care: a randomized trial. *Br J Gen Pract.* 1999; 49:39-41.
- Kamel G, Emery P. Modified suprascapular nerve block with bupivacaine alone effectively controls chronic shoulder pain in patients with rheumatoid arthritis. *Ann Rheum Dis.* 1993; 52:215-8.
- Adey-Wakeling Z, Crotty M, Shanahan EM. Suprascapular nerve block for shoulder pain in the first year after stroke a randomized controlled trial. *Stroke.* 2013; 44:3136-41. Doi:10.1161/STROKEAHA.113.002471.
- Taskaynatan MA, Yilmaz B, Ozgul A, Yazicioglu K, Kalyon TA. Suprascapular nerve block versus steroid injection for non-specific shoulder pain. *Tohoku J Exp Med.* 2005; 205:19-25
- Abdelshafi ME, Yosry M, Elmulla AF, Al-Shahawy EA, Adou Aly M, Eliewa EA. Relief of chronic shoulder pain: A comparative study of three approaches. *Middle East J Anaesthesiol.* 2011; 21:83-92.
- Koh KH. Corticosteroid injection for adhesive capsulitis in primary care: A systematic review of randomised clinical trials. *Singapore Med J.* 2016; 57:646-57.
- Woolf CJ. Somatic pain-Pathogenesis and prevention. *Br*

- J Anaesth. 1995; 75:169-76.
33. Lewis RN. The use of combined suprascapular and circumflex (articular branches) nerve blocks in the management of chronic arthritis of the shoulder joint. Eur J Anaesthesiol. 1999; 16:37-41.
34. Steuri R, Sattelmayer M, Elsig S, Kolly C, Tal A, Taeymans J *et al.* Effectiveness of conservative interventions including exercise, manual therapy and medical management in adults with shoulder impingement: A systematic review and meta-analysis of RCTs. Br J Sports Med. 2017; 51:1340-7.