



E-ISSN: 2395-1958
P-ISSN: 2706-6630
IJOS 2020; 6(1): 431-435
© 2020 IJOS
www.orthopaper.com
Received: 10-11-2019
Accepted: 14-12-2019

Dr. Rakesh Krishna Gade
Postgraduate, Department of
Orthopaedics, GSL Medical
College and General Hospital,
Rajamahendravaram, Andhra
Pradesh, India

**Dr. Guttarlapalli Pradeep
Gandharva**
Associate Professor, Department
of Orthopaedics, GSL Medical
College and General Hospital,
Rajamahendravaram, Andhra
Pradesh, India

Dr. Jonnalagedda Satya Prasad
Professor and Head, Department
of Orthopaedics, GSL Medical
College and General Hospital,
Rajamahendravaram, Andhra
Pradesh, India

Corresponding Author:
**Dr. Guttarlapalli Pradeep
Gandharva**
Associate Professor, Department
of Orthopaedics, GSL Medical
College and General Hospital,
Rajamahendravaram, Andhra
Pradesh, India

Study of surgical management of proximal tibial fractures using anatomical proximal tibia locking compression plate

Dr. Rakesh Krishna Gade, Dr. Guttarlapalli Pradeep Gandharva and Dr. Jonnalagedda Satya Prasad

DOI: <https://doi.org/10.22271/ortho.2020.v6.i1h.1901>

Abstract

Introduction: Ever since the advents of high velocity transport system, there is an alarming increase in road traffic accident (RTA) with increased orthopaedic related morbidity and mortality. Proximal tibia being involved in body weight transmission through knee joint and leg, it plays a vital role in knee function and stability. The aim of surgical treatment of proximal tibial fractures is to restore and preserve normal knee function, which can be accomplished by anatomical restoration of articular surfaces, maintaining mechanical axis, restoring ligamentous stability and preserving a functional pain free range of motion of knee. Treatment of these injuries using minimally invasive percutaneous plate osteosynthesis (MIPPO) techniques may minimize soft tissue injuries and damage to vascular integrity of fracture fragments.

Materials and Methods: This study was a hospital based prospective study centered in department of orthopedics at GSL Medical College Rajahmundry, from December 2017 to May 2019 in which 20 patients with proximal tibia fractures were treated with locking compression plate (LCP).

Results: The assessment of clinical outcome was made according to Rasmussen's functional grading system. End results showed excellent outcome and out Of 20 patients, 19 Patients (85%) showed radiological UNION.

Conclusion: Surgical management of proximal tibial fractures will give excellent anatomical reduction and rigid fixation to restore articular congruity, help to facilitate early mobilization and reducing post-traumatic osteoarthritis and hence to achieve optimal knee function. LCP remains a good choice in comminuted or more severe patterns of fractures.

Keywords: Proximal tibia fractures, locking compression plate, minimally invasive percutaneous plate osteosynthesis, Intra-articular fractures

1. Introduction

Ever since the advents of high velocity transport system, there is an alarming increase in road traffic accident (RTA) with increased orthopaedic related morbidity and mortality.

Proximal tibia being involved in body weight transmission through knee joint and leg, it plays a vital role in knee function and stability. Fractures of proximal tibia have historically been difficult to treat because of its subcutaneous location of the anteromedial surface of the tibia.

Severe bone and soft tissue injuries are not infrequent and there is high incidence of open fracture compared with other long bones [1].

The aim of surgical treatment of proximal tibial fractures is to restore and preserve normal knee function, which can be accomplished by anatomical restoration of articular surfaces, maintaining mechanical axis, restoring ligamentous stability and preserving a functional pain free range of motion of knee [1].

The incidence of malunion, non-union and infections are relatively high in many reported series, causing significant long term disability. Recently more attention has been paid to the condition of soft tissue envelope. Soft tissue friendly approaches and minimally invasive techniques have improved the outcome. Treatment of these injuries using minimally invasive percutaneous plate osteosynthesis (MIPPO) techniques minimize soft tissue injury and damage to vascular integrity of fracture fragments.

Over the last decade plate fixation has become popular for the treatment of proximal tibial fractures. This coupled with biological advantage of percutaneous insertion has resulted in high union rates. Locking compression plate device offers potential biomechanical advantage over other methods by,

- Better distribution of forces along the axis of bone,
- Can be inserted with minimal soft tissue stripping using minimally invasive percutaneous plate osteosynthesis (MIPPO),
- Substantially reduces failure of fixation in osteoporotic bones,
- Reduces the risk of a secondary loss of intraoperative reduction by locking with screws to the plate,
- Unicortical fixation option,
- Better preservation of blood supply to the bone as a locked plating does not rely on plate bone compression,
- Provides stable fixation by creating a fixed angle construct and angular stability and allows early mobilization. Locking compression plate has added advantage of the ability to manipulate and reduce the small and often osteoporotic fracture fragments directly.

2. Materials and Methods

This is a study of proximal tibial fractures treated with locking compression plate (LCP) which was conducted in the Department of Orthopedics at GSL Medical College Rajahmundry, from December 2017 to May 2019. Clearance was obtained from hospital ethical committee. During this period 20 patients were treated for proximal tibial fractures by LCP fixation and all the required data was collected from the patients during their stay in the hospital and during follow up at regular intervals.0

The Inclusion Criteria

1. Age above 18 years.
2. Closed / Open Gustilo-Anderson Type I, II and IIIA.
3. Intraarticular / Extraarticular proximal tibial fractures (AO 41A and 41C).

The Exclusion criteria

1. Pathological fractures.
2. Patients medically unfit for surgery

Classification system

Schatzker's classification: Currently, more widely used. Differentiation between medial & lateral tibial plateau fracture is done.

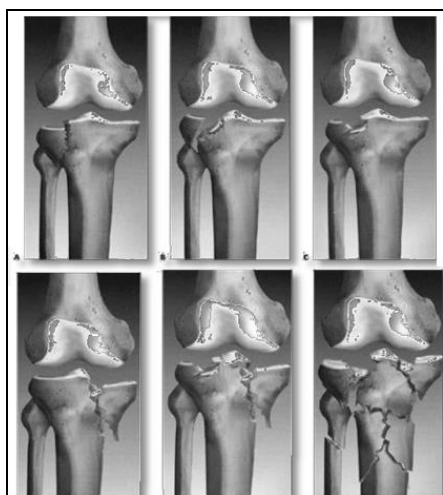


Fig 1: Schatzker's Classification Upper End of Tibia

2.1 Management

The patients were first seen in the casualty/ OPD. The history was taken followed by general and local examination of the patient. Concerned specialists undertook appropriate management of any associated injuries. Intensive care was given to those patients who presented with shock following head injuries and immediate resuscitative measures were taken. Once the patient's general condition was fit, relevant x-rays were taken. Higher investigations such as CT scan were done if indicated.

The patients were taken for surgery at the earliest possible time depending on their medical condition, skin condition and the amount of swelling. If definitive surgery was delayed, fracture was immobilized with an above knee posterior splint. All surgeries were done under C-arm image intensifier control. Fractures were fixed either with MIPPO technique or by open reduction and internal fixation with LCP.

2.2 Preoperative planning

- Consent of the patient/ patient attenders was taken prior to the surgery.
- •Appropriate length of the plate to be used was assessed with the help of radiographs.
- A dose of tetanus and antibiotic was given preoperatively.
- Preparation of the part was done before the day of surgery.
- The injured leg was immobilized in a plaster of paris slab during preoperative period.
- Instruments to be used were checked and sterilized.

2.3 Position

Patient supine on radiolucent operating table.

2.4 Operative procedure

- Type of anaesthesia: Spinal anaesthesia.
- Betadine scrub was given to the limb.
- Pneumatic tourniquet was applied after exsanguinations and time noted.
- Painting and draping of the part done.
- Through anterolateral approach, intraarticular fractures were exposed and reduced anatomically, whereas extraarticular fractures were treated through MIPPO technique.
- After achieving reduction, appropriate sized plate was taken and fracture was stabilized using cortical and locking screws. Cortical screws were put before putting locking screws.
- The major intra-operative problems encountered were in case of comminuted fractures that were tried to reduce by MIPPO technique and later converted to open reduction after unsuccessful attempts.
- Tourniquet was released and haemostasis secured.
- Wound closed leaving suction drain insitu.

2.5 Postoperative

Postoperatively after obtaining rigid internal fixation, the patients were mobilized after removal of drains, for 2-5 days the range of motion allowed was 0-20, from the 5th day the range of motion was gradually allowed to be increased to 90 or more. After suture removal on 12-14th day if no complications, full range of movement was allowed. An immediate postoperative x-ray was also done. Intravenous antibiotics were given for 48 hours in case of closed fractures and more as required in case of open fractures. Analgesics

were given till adequate pain relief was obtained. The patients were advised quadriceps exercises, early active knee mobilization and non-weight bearing crutch walking, on discharge. In case of comminuted fractures with unstable fixation, external support was given in the form of slab and mobilization was started after confirming the healing process clinically and radiologically.

2.6 Follow up

After suture removal, follow up was done at 6 weeks during which patient were clinically evaluated and an x-ray was taken to look for signs of fracture union and loss of reduction if any. The second follow up was done at 3 months during which one more x-ray was done and a clinical evaluation of union done. Based on the clinical and radiological signs of union patients were allowed partial weight bearing and gradually progressed to full weight bearing. Partial weight bearing was delayed until 6-8 weeks and full weight bearing allowed after 12- 16 weeks if fracture union seen. The patients were then followed up at 6 months during which time the anatomic and functional evaluation was done using the Rasmussen’s functional grading system.

3. Results

In our study 20 fractures of upper end of tibia were treated. All cases were fresh, 16 patients were males and 4 patients were females. The median age was 44 years ranging from 22-68 years. 18 of the fractures were caused by road traffic accidents and 2 were due to fall. 11 patients were with fracture on left side and 9 on right side.

Of the 20 ‘upper end of Tibia’ fractures, 1 was of Schatzker type I, 2 were Schatzker type II, 6 were of Schatzker type III; 5 were of Schatzker type IV; 5 were of Schatzker type V and remaining 1 was of Schatzker type VI. All fractures were closed.

4 patients had associated injuries. Of them, 1 patient had comminuted fracture of contralateral tibia.

13 out of 20 fractures were treated by closed reduction and remaining 7 by open reduction. All patients were operated within 7 days 5 of them within 3 days of injury. Average time duration of surgery was 103 minutes with shortest duration being 75 min and longest being 150 min.

Duration for fractures treated by open reduction was more averaging 123 minutes. The size of plate was selected based on the type of fracture. 6 and 7 holed plates were used more commonly for upper end of tibia.

Of 20 patients, 19 Patients (85%) showed radiological UNION within 18 weeks. One patient went for NONUNION with implant failure. Broken plate was removed and treated with Limb Reconstruction system and bone grafting which united over 16 weeks following second procedure.

Average flexion in this study was 105 degree with more than 65% patients having knee range of motion more than 110°.

Average knee extensor lag in this study was 5.60 degrees.

In this study, very few patients had significant varus/ valgus malalignment. The duration of follow- up ranged from 3 months to 18 months.

Table 1: Sex Distribution

Sex	No of Cases	%
Male	16	80
Female	4	20

Table 2: Age Distribution

Age in years	No of cases	%
21 – 30	3	15
31 – 40	5	25
41 – 50	5	25
51 – 60	6	30
Above 60	1	5

Table 3: Age Distribution

Age in years	No of cases	%
21 – 30	3	15
31 – 40	5	25
41 – 50	5	25
51 – 60	6	30
ABOVE 60	1	5

Table 4: Type of Fracture Upper End Tibia

Type of fracture	No of cases	Percentage
Schatzker type i	1	5
Schatzker type ii	2	10
Schatzker type iii	6	30
Schatzker type iv	5	25
Schatzker type v	5	25
Schatzker type vi	1	5
Total	20	100

Table 5: Mechanism of Injury

Mechanism of injury	No of cases	Percentage
Road traffic accident	18	90
Fall from height	2	10
Total	20	100

Table 6: Relationship Between Age & Mechanism of Injury

Age (in years)	Vehicular accidents		Fall from height	
	No of cases	Percentage	No of cases	Percentage
> 50 years	4	20	2	10
< 50 years	14	65	0	0
Total	18	90	2	10

Table 7: Relationship Between Sex and Cause of Fracture

Sex	Vehicular accidents		No of Perc Cases	Entage
	No of Cases	Percentage		
Male	15	75	1	5
Female	3	15	1	5
Total	18	90	2	10

Table 8: Associated Injuries/ Illness

Associated	No. of cases	Percentage
Associated injury (n=20)	4	20.00
Illness	0	0

Table 9: Duration of Surgery

Operative time (minutes)	No of cases	Percentage
< 90 min	5	25
91 – 120 min	12	60
> 120 min	3	15
Total	20	100

Table 10: Type of Reduction

Type PF reduction	No of cases	Percentage
Closed	13	65
Open	7	35
Total	20	100

Table 11: Size of Plate Used

Size of plate Used	No of Cases	Percentage
4 – 6 Holed	6	30
7 – 9 Holed	10	50
10 – 12 Holed	4	20
>12 Holed	0	0
Union (Weeks)	No of Cases	Percentage
<16	8	40
16-18	9	45
19-20	2	10
21-22	0	0
Delayed Union	0	0
Non-Union	1	5

Table 12: Time at Which Full Weight Bearing Achieved

Achieved time (weeks)	No of Cases	Percentage
8 – 10	5	30
> 10 – 12	9	45
> 12 – 14	4	20
> 14	1	5

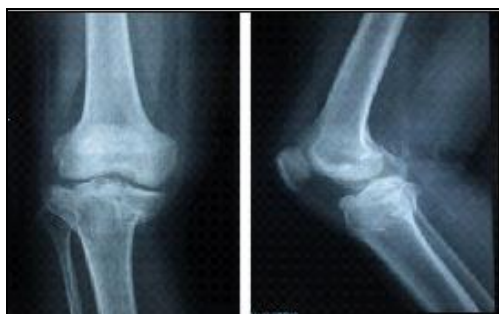

Fig 2: Case Study, Pre-Op Xray

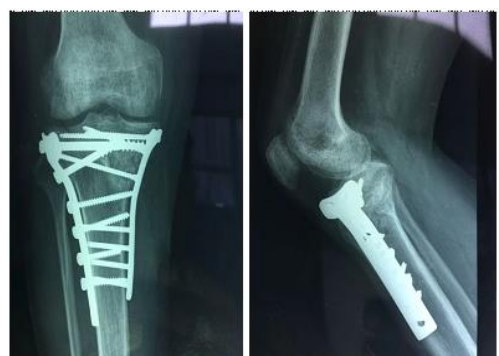

Fig 3: Post Op X Ray

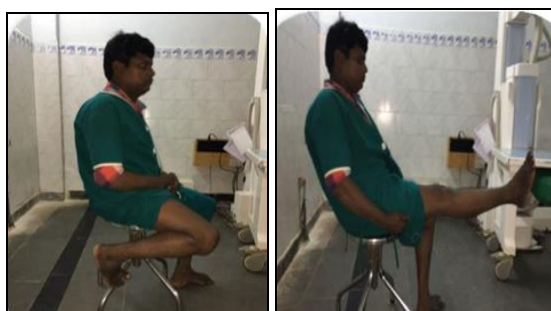

Fig 4: Clinical Pictures of Range Of Movements

4. Discussion

Proximal tibia fractures present a spectrum of soft tissue and bony injuries that can produce permanent disabilities. Their treatment is challenged by fracture comminution, instability, displacement and extensive soft tissue injures. The goals of treatment are restoration of joint congruity, normal limb alignment, knee stability and a functional range knee motion. The major limitations of non-operative treatment include inadequate reduction of articular surface and ineffective limb alignment control. Furthermore the extended period of hospitalization and recumbence are not cost-effective in today’s health care environment.

The aim of this study is to evaluate the clinical outcome of fracture of proximal tibia treated with locking compression plate and its complications. 19 out of 20 upper tibial fractures showed clinical and radiological union in average period of 16 weeks following surgery. 1 patient went for non-union due to implant breakage.

Rambold ^[5] in 1960 reported that internal fixation of tibial plateau fractures and early mobilization contributes to good anatomical and functional results. Dennis Jensen ^[6] in 1990 got good results by surgical treatment of proximal tibia fractures. Chaix *et al.* ^[7] reported 86% good to excellent results by surgical means of treatment. Lee *et al.* ^[8] reported good to excellent results by surgical means of less invasive stabilization system treatment. Feng *et al.* ^[9] reported good results when fixed with LCP in comparison with dynamic compression plate (DCP) with an additional benefit of minimally invasive surgery. Kim *et al.* ^[10] reported good results with MIPPO technique in treatment of open proximal tibial fractures with adequate soft tissue coverage.

The period of immobilization was again individualized depending on the security of rigid fixation and other circumstances demand. The benefits of early knee motion include - reduce knee stiffness and improved cartilage healing (regeneration). However, these benefits are to be cautiously balanced by risks, including loss of fracture reduction, failure of internal fixation and compromised ligament and soft tissue healing. Several studies stated that the prognosis is given by the degree of displacement, type of fracture, method of treatment and quality of postoperative care.

5. Conclusions

- At the end of our study, following conclusions were drawn from the surgical management of proximal tibial fractures.
- Road traffic accidents or high velocity injuries are the most common cause of these fractures. These high velocity injuries are associated with more severe or comminuted fracture patterns.
- Most of these injuries occur in younger and active age groups.
- The main aim of surgical treatment includes precise reconstruction of the articular surface with elevation of the depressed bone fragment in case of intraarticular fracture, bone grafting in case of bone loss and stable fragment fixation allowing early range of movement.
- Preoperative soft tissue status and their repair at right time, significantly changes the outcome.
- All fracture united well in time.
- Infection plays a vital role in influencing the result of the surgical outcome.
- Period of joint immobilization plays a major role in the end result.
- ORIF with LCP seems to be good implant choice in

proximal tibia fractures including difficult fracture situations.

6. References

1. Kenneth A. Egol and Kenneth J Koval, In: Fractures of proximal tibia: chapter 50, Rockwood and Green's Fractures in Adults. 6th edition, Lippincott Williams and Wilkins, 2006, 2.
2. Dendrinos GK, Kontos S, Katsenis D, Dalas K. Treatment of high-energy tibial plateau fracture by the Ilizarov circular external tibial plateau fixator. JBJS. 1996; 78(B):710-717.
3. Barei DP, Nork SE, Mills WJ, Coles CP, Henley MB, Benirschke SK. Functional Outcomes of Severe Bicondylar Tibial Plateau Fractures Treated with Dual Incisions and Medial and Lateral Plates. JBJS. 2006; 88(A):1713-1721.
4. Patil DG, Ghosh S, Chaudhuri A, Datta S, De C, Sanyal P. Comparative study of fixation of proximal tibial fractures by nonlocking buttress versus locking compression plate. Saudi J Sports Med. 2015; 15:1420
5. Rambold C. Depressed fractures of the tibial plateau. JBJS. 1960; 42A:783-797.
6. Dennis Jensen. Tibial plateau fractures. JBJS (Br). 1990; 72-b:49-52.
7. Chaix. Fractures of the tibial plateau, Insall JN, Winsdor RE, Scottw. Surgery of the knee, 2nd Ed, New York, Churchill Livingstone, 1993; 1038.
8. Lee JA, Papadakis SA, Moon C, Zalavras CG. Tibial plateau fractures treated with the less invasive stabilisation system. Int Orthop. 2007; 31:415-418.
9. Feng W, Fu L, Liu J, Qi X, Li D, Yang C. Biomechanical evaluation of various fixation methods for proximal extra-articular tibial fractures. J Surg Res. 2012; 178:722-727.
10. Kim JW, Oh CW, Jung WJ, Kim JS. Minimally invasive plate osteosynthesis for open fractures of the proximal tibia. Clin Orthop Surg. 2012; 4:313-320.
11. Mankar SH, Golhar AV, Shukla M, Badwaik PS, Faizan M, Kalkotwar S. Outcome of complex tibial plateau fractures treated with external fixator. Indian J Orthop. 2012; 46: 570-574.
12. Taheri E, Sepehri B, Ganji R, Nasirai C. Effect of Screws Placement on Locking Compression Plate for Fixating Medial Transverse Fracture of Tibia. Biomed Eng Res. 2012; 1:13-18.
13. Moore TM. Volume 3: Fractures of lower extremity in Campbell operative orthopedics: twelfth edition; Mosby, 2013, 2669.
14. Prasad GT, Kumar TS, Kumar RK, Murthy GK, Sundaram N. Functional outcome of Schatzker type V and VI tibial plateau fractures treated with dual plates. Indian J Orthop 2013; 47: 188-94.