

E-ISSN: 2395-1958
P-ISSN: 2706-6630
IJOS 2020; 6(1): 212-215
© 2020 IJOS
www.orthopaper.com
Received: 17-11-2019
Accepted: 21-12-2019

Dr. Sagar Jawale
Assistant Professor, Department of
Orthopedics, Rural Medical
College, PMT, Loni, Rahata,
Maharashtra, India

Dr. Deepak Tambe
Associate Professor, Department of
Orthopedics, Rural Medical
College, PMT, Loni, Rahata,
Maharashtra, India

Dr. Gaurav Ranglani
Junior Resident, Department of
Orthopedics, Rural Medical
College, PMT, Loni, Rahata,
Maharashtra, India

Dr. Pushpak Kumar
Assistant Professor, Department of
Orthopedics, Rural Medical
College, PMT, Loni, Rahata,
Maharashtra, India

Dr. Mayur Joshi
Junior Resident, Department of
Orthopedics, Rural Medical
College, PMT, Loni, Rahata,
Maharashtra, India

Dr. Chinmaya Khodaskar
Junior Resident, Department of
Orthopedics, Rural Medical
College, PMT, Loni, Rahata,
Maharashtra, India

Dr. Het Patel
Junior Resident, Department of
Orthopedics, Rural Medical
College, PMT, Loni, Rahata,
Maharashtra, India

Dr. Ankit Gabani
Junior Resident, Department of
Orthopedics, Rural Medical
College, PMT, Loni, Rahata,
Maharashtra, India

Corresponding Author:
Dr. Deepak Tambe
Associate Professor, Department of
Orthopedics, Rural Medical
College, PMT, Loni, Rahata,
Maharashtra, India

Comparison of outcome of tibial avulsion fracture of the posterior cruciate ligament using open reduction internal fixation by cc screw and arthroscopic suture bridge technique

Dr. Sagar Jawale, Dr. Deepak Tambe, Dr. Gaurav Ranglani, Dr. Pushpak Kumar, Dr. Mayur Joshi, Dr. Chinmaya Khodaskar, Dr. Het Patel and Dr. Ankit Gabani

DOI: <https://doi.org/10.22271/ortho.2020.v6.i1d.1865>

Abstract

Introduction: Number of operative techniques have been described with the use of lag screws, steel wires, arthroscopic tight rope fixation, arthroscopic suture bridge technique. As there is continuous advancement in newer technique, we are comparing outcome of PCL tibial avulsion fixed by two different methods open reduction internal fixation by CC screw and arthroscopic suture bridge technique. **Method:** The PCL tibial avulsion was approached by posterior Burks and Schaffer approach, fixed by CC screw in half of the patient and in another half, we used arthroscopic suture bridge technique. One fiber wire is used in arthroscopic technique.

Results: Anatomical reduction and fixation of PCL avulsion by arthroscopic fixation is equally effective when compared with ORIF by CC screw fixation.

Conclusion: The use of CC screw could be a simple and reliable technique for PCL avulsion fractures of the tibia. Patients achieved good knee function after surgery, but arthroscopic suture bridge technique of PCL avulsion fixation gives better knee function and less intraoperative complications.

Keywords: PCL tibial avulsion, CC screw, fiber wire, arthroscopy, suture bridge technique.

Introduction

The function of PCL is to prevent posterior translation of tibia on femur [1]. Dashboard injury and hyperflexion of the knee joint is the most commonly reported mechanism of PCL tibial avulsion fracture [2, 3]. Recent literature suggest that operative management is better than conservative treatment [4-8] hence, to obtain excellent functional results a displaced PCL avulsion fracture must be internally fixed. That to if not treated properly potentially leading to chronic pain and anteromedial knee pain and patellar degeneration [9, 10]. Avulsion of the PCL can be diagnosed with the help of plain radiography, resulting in operative management including open reduction and internal fixation or arthroscopically assisted surgery [11-14]. Open reduction with internal screw fixation through a posterior approach has been reported as suitable approach for stable fixation [5, 6] given the deep location of PCL and the complexity of the anatomy, minimally invasive arthroscopic techniques [2-4, 7] have been developed. We have studied here the outcome of PCL avulsion fracture fixation by two different methods of fixation in 12 number of patients in which 6 patients has underwent ORIF CC screw fixation and 6 patients underwent arthroscopic suture bridge fixation using no.5 fire wire. Both the techniques provide accurate reconstruction of the anatomic footprint and rigid fixation for early rehabilitation. Arthroscopy does not require an open approach or second surgical procedure for hardware removal.

Methods

Preoperative planning and work up: Patients coming to casualty or orthopedic OPD from mar 19 to Oct 2019 are selected with following inclusion and exclusion criteria (fig.3);

■ Inclusion criteria

Displaced PCL avulsion fracture.

Grade III posterior drawer test.

PCL avulsion in unilateral or bilateral knee.

■ Exclusion criteria

Polytrauma or ipsilateral hip fracture

Ipsilateral proximal tibia.

Patient with major head injury or unconscious.

Patient not giving consent.

The diagnosis of all 12 patients are made by history taking, clinical examination (posterior drawer test), followed by Radiographic evaluation like x ray antero posterior view (standing) and lateral view as well as MRI is done (fig.3).

Patients with comminuted fragments of tibial avulsion on MRI are selected for arthroscopic fixation.

■ Surgical technique

All patients are operated under regional anesthesia and receives our institute's standard antibiotic protocol i.e. inj. Zostum 1 gm I.V. BD and inj. Amika iv bd given one day prior to operation and for next 2 days. Thorough examination of the knee instability is done under anaesthesia, tourniquet is applied to patient's thigh, leg is prepared and draped under all aseptic precaution. Prone position is given to those patients who underwent CC screw fixation and supine position to patients to go Arthroscopic fixation.

Open reduction and internal fixation by CC screw

A 10 -20 cm inverted L-shaped incision was made in the skin

and subcutaneous tissue of the posterior aspect of the knee, along the transverse crease of the popliteal fossa, inward to the edge of medial head of gastrocnemius muscle and distally along the medial aspect of lower leg (fig.1). After identification and protection of the small saphenous vein and medial sural cutaneous nerve, the deep fascia was incised medial to these structures to expose the medial head of the gastrocnemius and semitendinosus. The medial head of the gastrocnemius muscle and the popliteal vessels and nerves were retracted laterally to expose the posterior joint capsule, and the joint capsule was incised longitudinally to expose the PCL and avulsion fracture fragments. Any blood clots or soft tissue embedded in the fracture fragments were removed. In patients with an old fracture, any granulation tissue on the fracture fragments was completely removed to expose a fresh mattress of bone on the intercondylar eminence of the tibia. Then, with a thick cushion placed in front of the patient's thigh, the anterior drawer test was applied to the lower leg and the injured knee was bent to obtain anatomic reduction of the fracture fragments. Two Kirschner wires were used for temporary fixation. When the appropriate position was accurately identified by C-arm fluoroscopic examination. A guide needle was drilled vertically into the plate with the help of low rpm drill machine, and a hollow lag screw of the appropriate diameter was screwed and fixed with pressure applied to bring the fragments together. For large fracture fragments, an additional cancellous lag screw. The Kirschner wires and guide needle were then removed, and the posterior drawer test was performed; if the test was negative, the wound was closed with sutures.

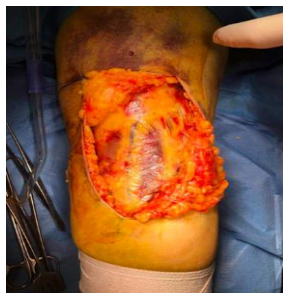

Fig 1: Inverted L Shape incision

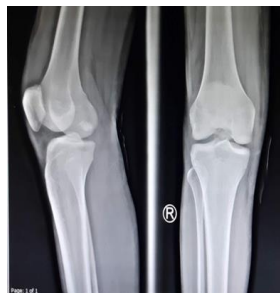

Fig 2: X-Ray of PCL Avulsion fracture

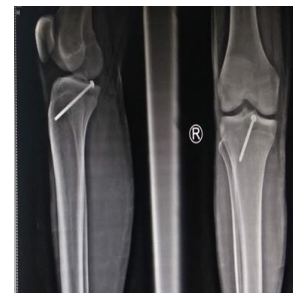

Fig 3: PCL Avulsion fracture fixed by CC Screw

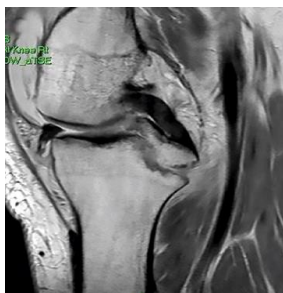


Fig 4: MRI imaging showing PCL Avulsion fracture

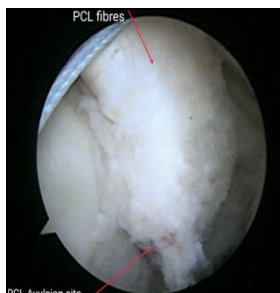


Fig 5: Arthroscopic view of Avulsed PCL fibers

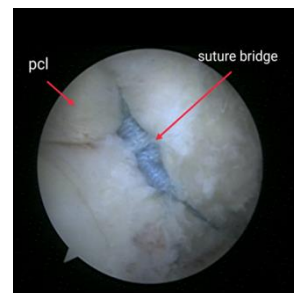


Fig 6: Arthroscopic representation of suture bridge

Arthroscopic suture bridge technique

Arthroscopy starts from the high anterolateral portal. The hematoma is washed out via anterolateral portal using the gravity for

the irrigation inside the knee. The floppy ACL sign and significant PCL laxity are common arthroscopic findings.

With the use of a high anteromedial portal, synovium of the intercondylar notch is shaved and the intervening fat between

the ACL and PCL is partially removed. At this time, any concomitant meniscal and chondral injury is evaluated and managed. Once the posteromedial compartment is visualized, a high and low posteromedial portal is created. Using the shaver, the posterior aspect of the PCL and the posterior joint capsule are separated to create a working space. With the help of switching stick 7 mm cannula is inserted through both posterior portals. Using the high posteromedial portal for

visualization and the low posteromedial and anteromedial portals as the working portals, a plane is developed between the posterior aspect of the PCL and the posterior joint capsule (fig.5). Crater of fracture identified and delineated, using shaver till cancellous part is visible and reducibility of fracture is checked. Two Beath pins are introduced using PCL-T jig (set at 60° angle) on each side of fracture crater. Beath pins are drilled over by 4.5 mm cannulated reamer. During all these procedure knees is kept at 90° of flexion. Care is taken to avoid injury to neurovascular bundle.

Ends of no.5 FireWire passed around the bone ligament junction on each side & retrieved from lower posterior portal. Then a multiple sliding knots are used to create loop and suture bridge and several half hitches are used to create the 'suture bridge' (Fig. 6). We kept the length of suture bridge reaching to close to the lower part of avulsed bone fragment and try to avoid too short or too long suture bridge.

Ends of fiber wire are retrieved from right and left tunnels

that are already created with the help of looped ethilon through 4.5 mm reamer. Limbs of suture are manipulated through lower posterior portal if required. Traction is applied to the suture while anterior drawer is applied to tibia and reduction is checked under direct visualization. Then suture is tied over anterior tibia on suture disc. Reduction of the PCL fragment is also checked by fluoroscopy.

Post-operative protocol

All 12 patients post operatively given extension knee brace with small bolster kept behind proximal tibia to keep proximal tibia slightly anterior as compare to femur. Static quadriceps exercises, straight leg raise, ankle pumps are started on second day of surgery. All patients kept non weight bearing for 6 weeks.

Results

Table 1: Assessment by Lysholm score with relevant data

Case	Age(yr s.)/sex	Mode of injury	Duration of operative intervention(days)	Associated knee injuries	Procedure performed	Lysholm score		Degree of flexion after 5 months	Complications
						Pre-operative	Post-operative		
1	24/M	Dashboard injury	10	Med. Meniscus tear	CC screw	0	100	120	-
2	39/M	Dashboard injury	11	-	CC screw	0	99	130	-
3	18/M	Dashboard injury	7	-	Arthr.	0	95	130	-
4	27/M	Dashboard injury	9	-	CC screw	0	95	120	-
5	48/F	Fall at home	12	-	CC screw	20	89	110	Superficial infection
6	26/M	RTA	7	Med.Meniscus tear	Arthr.	0	95	120	-
7	34/M	RTA	8	Med.Meniscus tear	Arthr.	0	99	130	-
8	29/M	RTA	11	-	Arthr.	0	100	120	-
9	60/M	Dashboard injury	10	-	Arthr.	0	95	130	-
10	23/M	Dashboard injury	12	-	CC screw	0	84	120	Superficial infection
11	31/M	RTA	10	-	Arthr.	24	99	130	-
12	54/F	fall at home	12	-	CC screw	0	95	120	-
Mean	34.4		9.9						

A total of 12 patients (2 females and 10 males) with mean age of 34.4 were selected.

Out of 12 patients only 2 females have fall at home while all 10 males have got high energy trauma (RTA). Out of these 10 males, 6 males got dashboard injury.

Average duration of operative intervention after trauma is 9.9 days. 6 patients underwent CC screw fixation for PCL Avulsion while remaining half patients underwent arthroscopic suture bridge fixation.

Out of 6 patients who underwent arthroscopic suture bridge fixation, 2 patients are treated for medial meniscus injury while, the same was not possible in one patient which was fixed by CC screw.

All the patients were followed up at least 4 months. A satisfactory anatomical reduction of fracture fragments was achieved by both procedures. Functional outcome assessed by Lysholm scoring system was excellent in 5 out of 6 patients in whom CC screw fixation done and in all six patients were excellent in whom arthroscopic fixation by bridge technique done. Average Lysholm scoring in CC screw fixed patients is 93.6 while in arthroscopic fixation patient it is 97.1 which is almost excellent in both.

2 patient had superficial wound infection which was treated with IV antibiotics and regular dressing in CC screw fixed patient.

Instability tested clinically using the Drawer test and radio

logically by stress x-ray was found to be mild in two of the patients rest of the patients had no instability.

Discussion

Open reduction can be performed by the traditional posterior approach or postero lateral or medial approach (15). Open approaches to be disadvantageous as a result of the anatomic insertion site of PCL is deep within tibial plateau and proximity of neurovascular bundle and large amount of post-operative scar tissue may restrict range of motion.

In addition, division of medial head of gastrocnemius to enhance exposure of avulsion site can lead to post-operative weakness of the muscle (15).

On contrary to it, arthroscopic fixation elicits us to deal with other lesion like meniscal tears and are less surgically invasive hence less soft tissue damage and decreased scar formation.

With arthroscopic suture bridge technique, we experienced that comminuted fracture pattern can also be healed without any laxity because of ligament taxis, which helps to mold the bony fragments and facilitate reduction.

One of the main advantages of arthroscopic technique over open reduction is that there is no need of hardware removal.

Conclusion

1. Both techniques give excellent results by Lysholm

scoring if executed in proper method.

2. Arthroscopic suture bridge technique has advantage of treating other new injuries simultaneously, but it requires surgical skills, inventory and learning curve for the same.

References

1. Kannus PJ, Bergfeld M, Jarvinen RJ, Johnson M, Pope P, Renstrom *et al.*, injuries to the posterior cruciate ligament of the knee, *Sports Med.* 1991; 12:110-131.
2. Kim SJ, Shin SJ, Choi NH, Cho SK. Arthroscopically assisted treatment of avulsion fractures of the posterior cruciate ligament from the tibia. *J Bone Joint Surg Am.* 2001; 83-A (5):698-708. (PubMed: 11379739).
3. Shino K, Nakata K, Mae T, Yamada Y, Shiozaki Y, Toritsuka Y. Arthroscopic fixation of tibial bony avulsion of the posterior cruciate ligament. *Arthroscopy.* 2003; 19(2):E12. Doi: 10.1053/jars.2003.50062. (PubMed: 12579141).
4. Zhao J, He Y, Wang J. Arthroscopic treatment of acute tibial avulsion fracture of the posterior cruciate ligament with suture fixation technique through Y-shaped bone tunnels. *Arthroscopy.* 2006; 22(2):172-81. Doi: 10.1016/j.arthro.2005.10.020. [PubMed: 16458803]. *Trauma Mon.* 2018; 23(3):e55650.
5. Yang CK, Wu CD, Chih CJ, Wei KY, Su CC, Tsuang YH. Surgical treatment of avulsion fracture of the posterior cruciate ligament and postoperative management. *J Trauma.* 2003; 54(3):516-9. Doi: 10.1097/01.TA.0000047048.37775.32. [PubMed: 12634532].
6. Bali K, Prabhakar S, Saini U, Dhillon MS. Open reduction and internal fixation of isolated PCL fossa avulsion fractures. *Knee Surg Sports Traumatol Arthrosc.* 2012; 20(2):315-21. Doi: 10.1007/s00167-011-1618-6. [PubMed: 21761230].
7. Seitz H, Schlenz I, Pajenda G, Vecsei V. Tibial avulsion fracture of the posterior cruciate ligament: K-wire or screw fixation? A retrospective study of 26 patients. *Arch Orthop Trauma Surg.* 1997; 116(5):275-8. [PubMed: 9177803].
8. Chen W, Tang D, Kang L, Ding Z, Sha M, Hong J. Effects of micro endoscopy-assisted reduction and screw fixation through a single mini-incision on posterior cruciate ligament tibial avulsion fracture. *Arch Orthop Trauma Surg.* 2012; 132(4):429-35. Doi: 10.1007/s00402-011-1426-y. [PubMed: 22080931].
9. Meyers MH, Solated avulsion of the tibial attachment of the posterior cruciate ligament of the knee, *J Bone Joint Surg.* 1975; 57:669-672.
10. Tegner Y, Lysholm J, Rating systems in the evaluation of knee ligament injuries, *Clin Orthop Relat Res.* 1985; 198:4249.
11. Dhillon MS, Singh HP, Nagi ON, Posterior cruciate ligament avulsion from the tibia: fixation by a posteromedial approach, *Acta Orthop Belg.* 2003; 69:162-167.
12. Hughston J, Bowden J, Andrews J, Norwood L, Acute tears of the posterior cruciate ligament. Results of operative treatment, *J Bone Joint Surg.* 1980; 62:438-450.
13. Zhao J, He Y, Wang J. Arthroscopic treatment of acute tibial avulsion fracture of the posterior cruciate ligament with suture fixation technique through Y-shaped bone tunnels, *Arthroscopy.* 2006; 22:172-181.
14. Torisu T. Isolated avulsion fracture of the tibial

attachment of the posterior cruciate ligament, *J Bone Joint Surg.* 1977; 59:68-72.

15. Jazayeri SM, Esmaili Jah AA, Karami M. A safe posteromedial approach to posterior cruciate ligament avulsion fracture. *Knee Surg Sports Traumatol Arthrosc.* 2009; 17:244247.