



International Journal of Orthopaedics Sciences

E-ISSN: 2395-1958
P-ISSN: 2706-6630
IJOS 2020; 6(1): 88-91
© 2020 IJOS
www.orthopaper.com
Received: 23-11-2019
Accepted: 27-12-2019

Rohan Memon

Senior Resident, Department of
Orthopaedics, NHL Municipal
Medical College, Ahmedabad,
Gujarat, India

Ketan Parmar

Resident, Department of
Orthopaedics, NHL Municipal
Medical College, Ahmedabad,
Gujarat, India

Nishant Suvagiya

Resident, Department of
Orthopaedics, NHL Municipal
Medical College, Ahmedabad,
Gujarat, India

Clinical outcome of treatment of fractures of lower third shaft humerus by Enders nails in adult age group

Rohan Memon, Ketan Parmar and Nishant Suvagiya

DOI: <https://doi.org/10.22271/ortho.2020.v6.i1b.1845>

Abstract

Introduction: Fractures of the lower third of humerus are common. Although plate fixation has its undebatable place in operative treatment of these fractures, most acute fractures can be dealt with using less invasive Ender nailing. This study was performed to assess the overall outcome and complications of Ender nailing in fractures of lower third shaft humerus.

Materials and Methods: It is a prospective study of 20 cases of fracture of lower third humerus admitted to NHL Medical College and VS General Hospital between October 2017 and September 2019 treated with close reduction and internal fixation with Enders nail. Functional outcome was evaluated using DASH scoring system and radiological outcome was evaluated by serial radiographs.

Results: In 65% of the patients, DASH score was within normal range and in 15% of the patients the disability was mild to moderate as scoring was slightly higher than normal and in 20% the disability was severe as the DASH score could not be calculated because of non union.

Conclusion: Enders nail fixation require very minimal soft tissue dissection and being a close reduction, the biology of the fracture is also not disturbed and the chances of nerve injury are much less, In this series, Ender nailing gave overall satisfactory results and appeared as a safe and efficient technique.

Keywords: DASH scoring, Enders nails, lower third shaft humerus

Introduction

Fractures of the lower third of humerus are common, Plate osteosynthesis has always been a gold standard and always given a good result for union of the bone if properly done according to principle of Open Reduction Internal Fixation (ORIF) but has the disadvantage of excessive periosteal stripping, large incision and increased chances of infection and iatrogenic radial nerve palsy^[1].

The Enders nail method was based on principle of 3 point fixation when introduced in the medullary canal of long bones and was first used in the fracture of long bones of lower extremities and soon became very popular method for fracture fixation of long bone and later used for diaphyseal fracture of humerus^[2]. The need for anatomic reconstruction and the absolute rigidity of AO techniques, however, easily leads to extensive soft tissue dissection; iatrogenic radial nerve lesion is a common complication of plating in humeral shaft fractures^[3]. The aim of this study was to evaluate the functional outcome of titanium enders nailing in fractures of lower third shaft humerus in the adult age group and the outcome to be evaluated using DASH score^[4].

Materials and Methods

This prospective study was carried out at NHL Medical College, VS General Hospital, Ahmedabad between October 2017 and September 2019. After informed consent and clearance from the Ethical Committee of our Institute, 20 patients with age group of 18-60 years with isolated close fracture of lower third shaft humerus presenting to our outpatient department and emergency department were included in the study. Patients with open fracture of shaft humerus, polytrauma patients, patient not willing for surgery and patient with other injuries of the same limb were excluded from the study. All patients were treated with closed reduction and internal fixation with enders nail. Enders nails can be inserted in antegrade fashion with the entry point at the proximal part of the humerus and retrograde fashion with

Corresponding Author:

Rohan Memon

Senior Resident, Department of
Orthopaedics, NHL Municipal
Medical College, Ahmedabad,
Gujarat, India

entry point at the distal end of the humerus. In our study we have used the antegrade and retrograde method of insertion in the humeral shaft. Follow up was done at 1 week, 3 weeks, 3 months and 6 months and were assessed clinically for pain and range of motion and radiologically to look for bony union. At the last follow up DASH questionnaire were given to the patients and score of individual patients were calculated and then this data was statistically analysed to produce the results of the study.

Surgical technique

The operation was performed under general anaesthesia. A careful pre-operative planning to assess the medullary canal diameter on radiographic films was made to anticipate the appropriate number and size of nail. The patient was positioned supine with the arm placed on an arm rest. Incisions were placed on the palpable subcutaneous lateral epicondyle. The curved awl directed the track well into the medullary canal. First a C or S shaped Ender nail was inserted from either entry portals depending on the fracture geometry, and was advanced to the fracture site. After appropriate manipulation under fluoroscopy, the nail was advanced to the subchondral part of the humerus head. Similarly, a nail from the proximal part was inserted as well. Length of the nails was confirmed with imaging before the final hammering. If the medullary cavity permitted, a third nail was inserted, usually from the lateral condyle

Results

Majority of patients were between 21 to 50 years of age group. Majority of patients (70%) showed fracture union within 12-14 weeks remaining 20% patients showed fracture union after 5 months and 2 patients had non-union for which enders nails were removed and open reduction internal fixation with bone grafting was done (Table no 1). The DASH scoring was calculated for all the patient after the fracture was clinically united as after serial questionnaire and the score was found to be in the range of 10-20 in 8 patients, 21-30 in 7 patients 31-40 in 2 patients and 41-50 in 1 patient (Table no 2). DASH score was not calculated in 2 patients who showed nonunion

Table 1: Average time taken for fracture union

No of patients	Average time taken for fracture union
14	12-14 weeks
04	20-24 weeks
02	>24 weeks

Table 2: DASH score was not calculated patients

DASH Score	No of patients
10-20	08
21-30	07
31-40	02
41-50	01

Discussion

The classical method of treatment of lower one third humerus

shaft fracture has been the use locking metaphyseal plate, but Internal fixation with plates carries risks of infection, neurological injury and non-union. In our series all the patients were operated with retrograde epicondylar entry and antegrade entry by enders nails. Ender nailing relies on configuration and spatial orientation of the nails to achieve rotational stability^[5]. The aim of this biological, minimally invasive fracture treatment is to achieve a level of reduction and stabilization that is appropriate to the age of the patient^[6]. With reamed interlocking nails, locking screws may be used to provide rotational stability. They rely on bone quality and hence achieve poor fixation in Osteopenic bone^[7]. Insertion of locking screws can sometimes be tedious, time consuming and may lead to neurovascular complications. By not relying on interlocking screws for stability, nerve damage^[8]. Ender nailing does not require reaming. Reaming for interlocking nails may have deleterious effects on fracture union. It destroys the residual endosteal blood supply^[9]. Although being intramedullary implants, Ender nails relatively preserve the Endosteal blood supply. This gave us the option of plating the humerus of the patient with non-union in our study. The minimally invasive procedure for Ender nailing with preservation of soft tissues, periosteum and fracture haematoma provides flexible stability for biological union. It offers internal bracing, helping in maintenance of the fracture fragments in acceptable alignment. This decreases the necessity of plaster immobilisation and allows early return to normal activity^[10].

The use of Ender or bundle nails in adults and elderly (pathological fractures following unicameral bone cysts) age groups has been shown to be minimally invasive and safe, and to produce excellent functional and cosmetic results^[11]. The literature suggests that this technique gives minimal X-ray exposure, short operative time and causes less soft tissue insult^[12]. This decreases the overall morbidity in elderly and poly traumatised patients.

Hall RF *et al.*, done a prospective study with ender's nail in 89 patients with humeral shaft fracture and the outcome was measured by union time and the frequency of the complications. Average time of union was 7.2 weeks^[13].

Shazar N *et al.*, performed a retrospective review of 94 patients treated with ender's nailing. The average duration of follow up was 71 weeks. In 91.5% of the patients union occurred without any additional intervention and the functional result was good in 74% of the patients^[14].

In our study 90% of the patient showed fracture union and non-union was seen only in 2 patients, and 75% of the patients had DASH Score Between 10-30.

Limitation

In our study the sample size was small and so, to draw a definite conclusion a study with a larger sample size and longer duration of follow up is needed. Furthermore, DASH scoring is a measure of disability of the upper extremity. It is not a specific scoring for the arm only. So, there may be other factors like pathology of shoulder and wrist which may affect the scoring.

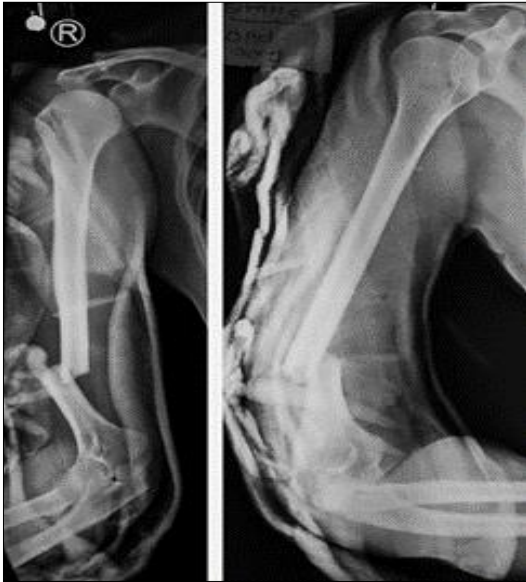

Fig 1: preoperative x-ray

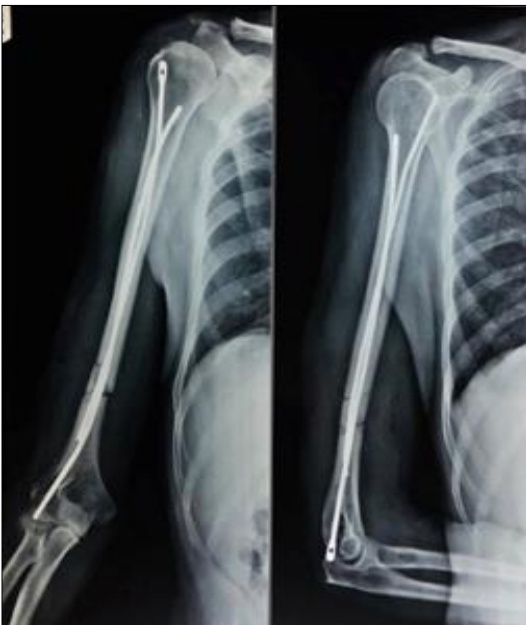


Fig 2: Postoperative x-ray

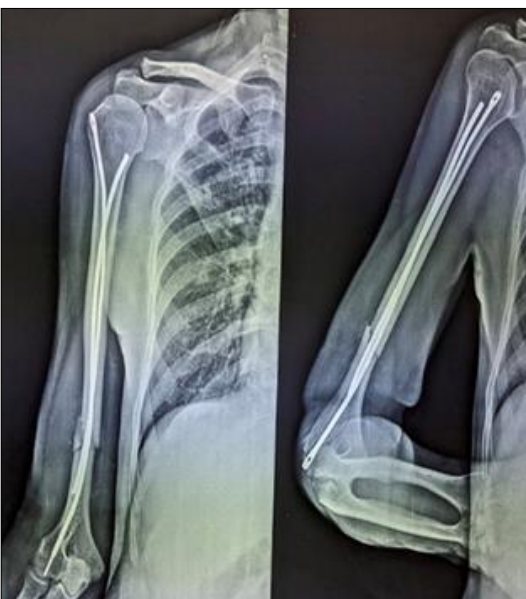

Fig 3: 2 Weeks follow up

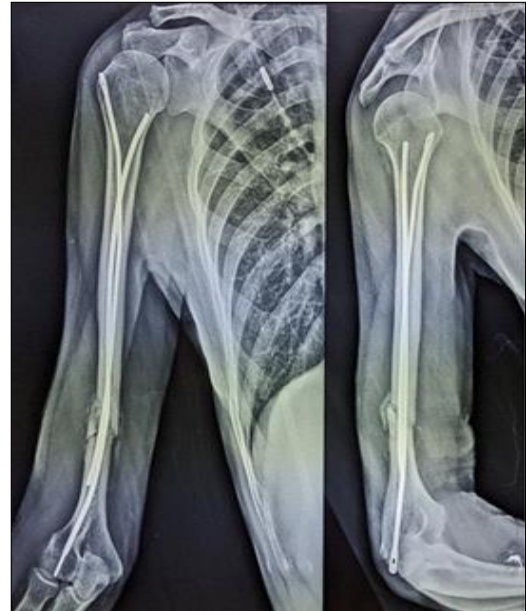

Fig 4-6: Weeks follow up

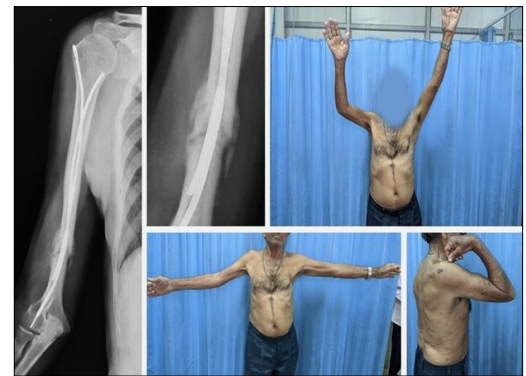

Fig 5-10: Weeks follow up

Conclusion

Intramedullary flexible nailing presents a consistent series of advantages, including advantages of a biological (physiological consolidation), mechanical (flexible stability), and practical (comfort for the patient) nature [15]. This simple and safe surgical technique provided good overall outcome for humerus diaphyseal fractures in our study. With the above advantages, the indications of operative intervention can be extended to include a wider group of patients for surgical intervention.

References

1. Uthoff HK, Poitras P, Backman DS. Internal plate fixation of fractures: short history and recent developments. *Journal of Orthopaedic Science*. 2006; 11(2):118-26.
2. Bong MR, Koval KJ, Egol KA. The history of intramedullary nailing. *Bulletin of the NYU Hospital for Joint Diseases*. 2006; 64(3/4):94-97.
3. Wang JP, Shen WJ, Chen WM, Huang CK, Shen YS, Chen TH. Iatrogenic radial nerve palsy after operative management of humeral shaft fractures. *J Trauma*. 2009; 66(3):800-03.
4. Atroshi I, Gummesson C, Andersson B, Dahlgren E, Johansson A. The disabilities of the arm, shoulder and hand (DASH) outcome questionnaire: reliability and validity of the Swedish version evaluated in 176 patients. *Acta Orthopaedica Scandinavica*. 2000;

- 71(6):613-18.
5. Franck WM, Olivieri M, Jannasch O, Hennig FF. Expandable nail system for osteoporotic humeral shaft fractures: preliminary results. *J Trauma*. 2003; 54:1152-1158.
 6. Gupta SK, Kumar MK, Reddy KR, Guru Prasad SS, Gopichand K. Comparative study of management of humeral diaphyseal fractures by DCP plate and IMIL nail. *Journal of Evolution of Medical and Dental Sciences*. 2014; 17(7):1782-88.
 7. Capelli RM, Galmarini V, Molinari GP, De Amicis A. The Fixion expansion nail in the surgical treatment of diaphyseal fractures of the humerus and tibia. Our experience. *Chir Organi Mov*. 2003; 88:57-64.
 8. Dalton JE, Salkeld SL, Satterwhite YE, Cook SD. A biomechanical comparison of intramedullary nailing systems for the humerus. *J Orthop Trauma*. 1993; 7:367-374.
 9. Williams PR, Shewring D. Use of an elastic intramedullary nail in difficult humeral fractures. *Injury*. 1998; 29:661-670.
 10. Roposch A, Saraph V, Linhart WE. Flexible intramedullary nailing for the treatment of unicameral bone cysts in long bones. *J Bone Joint Surg*. 2000; 82(A):1447-1453.
 11. Stedtfeld HW. [Fracture management in elderly patients. A technically and ethically challenging responsibility.] (In German). *Fortschr Med*. 1993; 111:102-106.
 12. Huber RI, Keller HW, Huber PM, Rehm KE. Flexible intramedullary nailing as fracture treatment in children. *J Pediatr Orthop*. 1996; 16:602-605.
 13. Hall RF, Pankovich AM. Ender nailing of acute fractures of the humerus. A study of closed fixation by intramedullary nails without reaming. *J Bone Joint Surg Am*. 1987; 69(4):558-67.
 14. Shazar N, Brumback RJ, Vanco B. Treatment of humeral fractures by closed reduction and retrograde intramedullary Ender nails. *Orthopedics*. 1998; 21(6):641-46.
 15. Spina N, Mus L, Basile G, Santamaria S. Flexible intramedullary classical nailing in childhood: use in fractures of the femur and humerus. *Chir Organi Mov*. 1998; 83:277-283.