

E-ISSN: 2395-1958  
P-ISSN: 2706-6630  
IJOS 2020; 6(1): 11-14  
© 2020 IJOS  
www.orthopaper.com  
Received: 08-11-2019  
Accepted: 12-12-2019

**Dr. Rahul Kadam**  
Department of Orthopaedics,  
MGM Medical College & Hospital  
Navi Mumbai, Maharashtra,  
India

**Dr. Shrinath Viswanath**  
Third Year Resident,  
Department of Orthopaedics,  
MGM Medical College & Hospital  
Navi Mumbai, Maharashtra,  
India

**Dr. Abhay Chhallani**  
Department of Orthopaedics,  
MGM Medical College & Hospital  
Navi Mumbai, Maharashtra,  
India

**Dr. Akshay Shah**  
Department of Orthopaedics,  
MGM Medical College & Hospital  
Navi Mumbai, Maharashtra,  
India

**Corresponding Author:**  
**Dr. Shrinath Viswanath**  
Third Year Resident,  
Department of Orthopaedics,  
MGM Medical College & Hospital  
Navi Mumbai, Maharashtra,  
India

## A prospective study of the comparison between PFN (proximal femur nail) and PFNA (proximal femur nail antirotation) in the treatment of Intertrochanteric fracture femur: Union rates and functional outcome

**Dr. Rahul Kadam, Dr. Shrinath Viswanath, Dr. Abhay Chhallani and Dr. Akshay Shah**

DOI: <https://doi.org/10.22271/ortho.2020.v6.i1a.1824>

### Abstract

The Proximal femur nail is an essential intramedullary device in the internal fixation of Peritrochanteric fractures of the femur. The evolution of the implant has proceeded from extramedullary plates to intramedullary nails which provide stable fixation of peritrochanteric femur fractures.

**Keywords:** Acute type 3 acromioclavicular joint dislocation, conservative management

### Introduction

The Proximal femur nail is an essential intramedullary device in the internal fixation of Peritrochanteric fractures of the femur. The evolution of the implant has proceeded from extramedullary plates to intramedullary nails which provide stable fixation of peritrochanteric femur fractures.

The common indications of proximal femur nailing are:

1. Intertrochanteric fractures of the femur
2. Sub-trochanteric fracture femur
3. Neck of Femur Fracture
4. Proximal Femoral shaft fractures

Intertrochanteric fractures are one of the most common fractures of the hip more so in the elderly with osteoporotic bones.

Morbidity and mortality are seen to be very high if these fractures are left untreated. Hence surgery is the treatment of choice for such fractures. It is estimated that by 2020, almost 20% of the Indian population will be older than 60 years and the annual incidence of hip fractures will reach 6, 00, 000<sup>[1]</sup>.

Most of the intertrochanteric fractures arising from low-energy trauma, occur in patients older than 65 years. Surgical stabilization of unstable intertrochanteric fractures in elderly is a challenge because of preoperative comminution, lateral wall breach, Osteoporosis and other comorbidities. Although consistently good results are obtained while treating stable intertrochanteric fracture, treatment failure rates with unstable fracture are comparatively higher<sup>[2,3]</sup>.

The fracture pattern, osteoporosis and comorbidities in the patients were the uncontrollable factors in reducing the surgery-related complication rate. However, the surgery related complications could be reduced by the advanced surgical management utilizing the new fixation devices<sup>[4]</sup>.

Surgical fixation facilitates the early mobilization of patients with proximal femur fractures and helps prevent the complications of prolonged immobilization such as Thromboembolism, Respiratory and Urinary tract infection. According to OTA classification, Intertrochanteric fractures are classified into stable and unstable fractures (AO 31A2.2-3.3). Unstable fractures are treated by nails.

The nail occupies the medullary canal, preventing excessive sliding and medialization of the shaft even in A3 fractures [5]. The design of the nail itself has evolved over time and has been re-engineered to provide a more stable fixation of the fracture.

One of the newer nails is the PFNA (Proximal Femoral Nail Antirotation), one which incorporates a helical blade to provide anchorage to the femoral neck and Head. This helps compact the cancellous bone inside the Femoral Neck and Head, conferring stability and rigidity to the fixation.

This study aims to compare the outcomes following fixation of peritrochanteric fractures of the femur with the PFNA and the previous generation PFN.

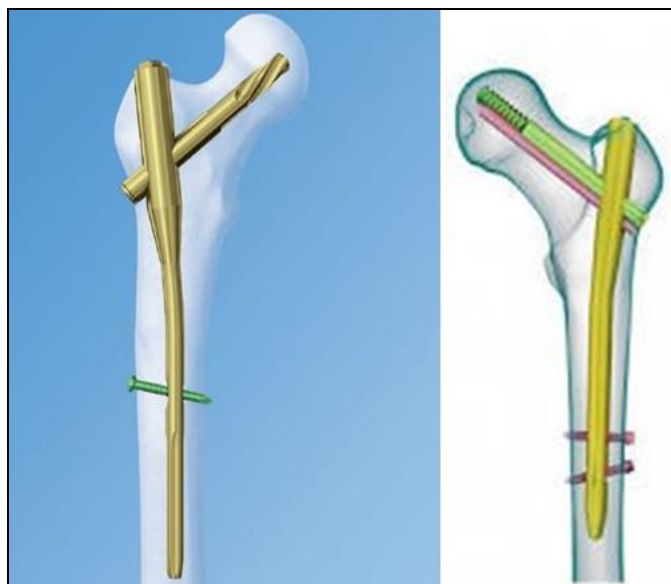


Fig 1: Left-PFNA2 Right: Inter-TAN

### Materials and Methods

32 Patients with peritrochanteric femur fractures were treated at MGM Hospital Kamo the Between the duration of January 2018 to August 2018 All patients were operated upon by 3 senior surgeons in the Department of Orthopaedics in this period. After excluding the patients who had open fractures, polytrauma and pathological fractures, 32 patients were selected for this study out of which 22 were women and 10 were men aged 60 and above (mean 70.2 years). Inclusion criteria were patients with isolated, closed with Evans [6] type 2, 3, 4, 5 inter- trochanteric fractures.

### Inclusion criteria

1. Intertrochanteric fractures of the femur
2. Sub-trochanteric fracture femur
3. Neck of Femur Fracture
4. All patients treated with a PFN/PFNA, who were willing to undergo surgery and were able to give consent for the same

### Exclusion criteria

1. Polytrauma Patients
2. Open Fractures
3. Pathological Fractures
4. Patients unsuitable for surgery

### Patient evaluation parameters

All patients who were included in the study were assessed using the Harris Hip Score and Radiographic Assessment of Union of fracture.

### Harris Hip Score: Appendix 1

The Harris Hip Score (HHS) is a clinician-based outcome measure frequently used for the evaluation of patients following a total hip arthroplasty. It was developed in 1969, and has since undergone multiple revisions. Today, the scope of the HHS has increased, and many clinicians now use it for the assessment of femoral neck fractures and osteoarthritis [7]. Four subscales make up HHS. The first is pain, which measures pain severity (44 points); function, which is made up of daily activities and gait (47 points); the absence of deformity, which is a subscale that measures hip flexion, adduction, internal rotation, leg length discrepancy and range of motion measures. (4 points), and range of motion (5 points) [7].

The survey has 10 question items and scores range from 0-100 with higher scores representing less dysfunction and better outcomes.

### Operative Procedure

After taking a written informed consent, operations were performed by one of 3 expert surgeons. Operations were performed on traction table in supine position and closed reduction was performed with C-arm guidance.

Surgery was performed using standard steps, as recommended by the manufacturer. We used a titanium cannulated 170 mm long by 10-12 mm diameter PFNA nail. The helical blade of 14 mm diameter was inserted in femoral neck without drilling.

The Short PFN is a 180 mm long by 10-12 mm diameter cannulated stainless steel nail with a longitudinal slot throughout to accelerate endosteal bone healing.

Two bolts were inserted into the neck of femur of 8 mm and 6.4 mm via guide wires. Additional screws were inserted to provide stability if required.

Both the nails were dynamically or statically locked distally. The Neck-Shaft angle, of both the devices was 130 degrees.

In all the cases, cefuroxime (1.5g) antibiotic was given pre-operatively and thromboprophylaxis with low molecular weight heparin was administered.

Postoperative rehabilitation was started at the earliest as tolerated by the patient.

The patients were evaluated at intervals of one month, two months and 6 months, On the basis of Radiographic evaluation and Harris Hip Score.

### Results

The study included a total of 32 patients treated for proximal femur fractures with closed reduction and nailing with PFN and PFN-A2.

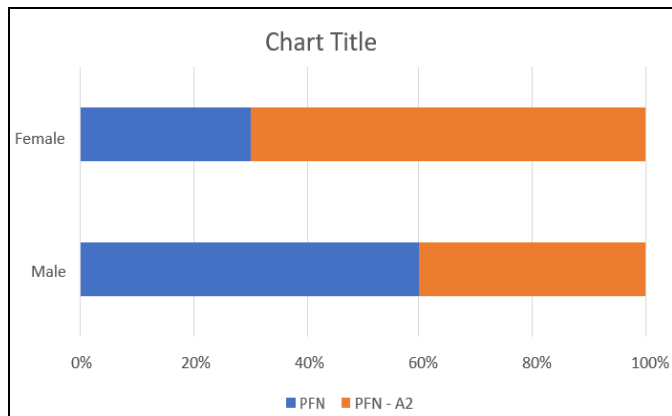
#### 1. Age group

The mean age for the PFN group was 70 years and for the PFN A2 group was 70.4 years. The average age of the study population was 70.2 years.

#### 2. Sex

Table 1: Sex distribution

Sex	PFN	PFN – A2
Male	13	9
Female	3	7
Total	16	16

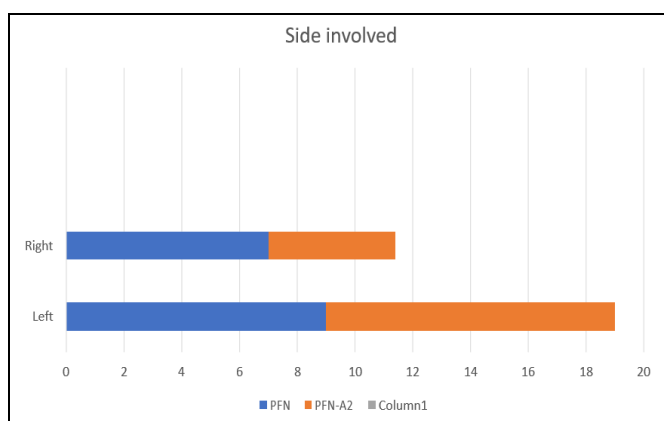


**Fig 2:** Sex distribution

**3. Side involved**

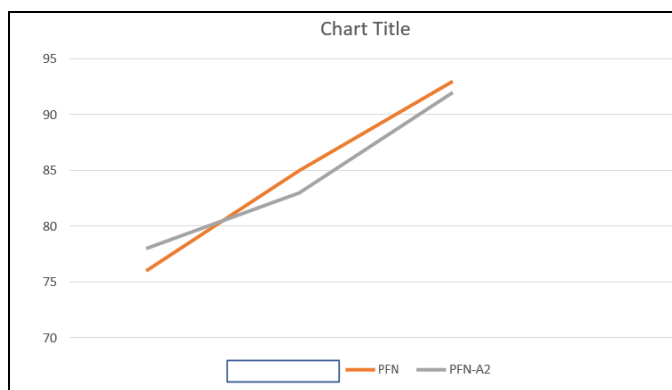
**Table 2:** Side distribution

Side	Left	Right
PFN	9	7
PFN- A2	10	6



**Fig 3:** Side distribution

**4. Harris hip score**



**Fig 4:** Harris hip scores

The PFN and PFN – A2 show excellent results at the end of six months which are not statistically significant in difference. The scores were higher for the A2 group initially but similar by the end of 6 months. The higher early scores could be attributed to lesser operating time and less blood loss.

**Complications**

We had one superficial infection in the A2 group and one delayed union for the PFN group.

**Discussion**

The choice of implant for the fixation of peri-trochanteric fractures of the hip remains a highly debated issue with a host of options.

This study was conducted on 32 adult patients with peri-trochanteric fractures who were managed operatively using either PFN or PFNA after closed reduction at a tertiary care centre. The patients in both the groups were comparable in terms of demography and the fracture type.

The mean duration of surgery was significantly lower in the PFNA group as compared to PFN group. This was mainly because of the use of a single helical blade in PFNA as compared to two screws in PFN. The PFNA involves gentle tapping of the helical blade over a guide pin thereby avoiding the steps involved in reaming of canals for lag screw and de-rotation screw as required in a PFN.

The positioning of the guide wire for insertion of helical blade is also easier as compared to two guide wires for PFN.

The mean blood loss was significantly lower in PFNA group as compared to PFN group. The decrease in blood loss in PFNA group is attributed to decreased duration of surgery and smaller surgical incision for the placement of PFNA Blade as compared to longer surgical time and longer incision for insertion of lag Screw and de-rotation screw in PFN Group.

However, the amount of blood loss was not severe enough to necessitate a blood transfusion in any case. Exposure to X-rays, as determined by the number of intraoperative fluoroscopic images taken showed significantly lower scores for PFNA as compared to PFN. The reasons for this are the same as that for increased duration of surgery in case of PFN.

The mean duration of hospital stay (postoperatively) did not differ between the two groups. There were no cases of post-operatively DVT/thromboembolism, peri-implant fractures or implant failures in either of the groups.

**Conclusion**

Our study suggests that the PFNA is a better implant in elderly patients with poor bone stock and the shorter operating time and easier placement of the helical blade facilitates a lower requirement of analgesics and allows for early mobilization.

The main benefits are the shorter surgical time and the decreased need for fluoroscopy.

The small sample size and duration of follow up are limiting factors.

**Acknowledgement**

I would like thank my head of unit, colleagues for their constant support and helping hands in making the study successful. I would also like to thank The Department of Orthopaedics at MGM Hospital Kamothe.

**Declarations**

Funding: No Funding Sources Conflict of interest: None Declared

**References**

1. Kulkarni G, Limaye R, Kulkarni M, Kulkarni S. Intertrochanteric fractures. Indian J Orthop. 2006; 40:16.
2. Kovalkj, Cantu RV. Intertrochanteric fractures: Rockwood and greens fractures in adults, 6th edition, Bulcholzrw, Heckmanjd, Court-Brown C, eds, philadelphia: Lippincott Williams and Wilkins, 2006, 1793-825

3. Kregor PJ, Obremskey WT, Kreder HJ *et al.* Unstable peritrochanteric femoral fractures J Orthop Trauma. 2005; 19:63-66
4. Hardy DR, Descamps PY, Krallis P, Fabeck L, Smets P, Bertens CL *et al.* Use of an intramedullary hipscrew compared with a compression hip-screw with a plate for Intertrochanteric femoral fractures: A prospective, randomized study of one hundred patients. JBJS (Am). 1998; 80:618-30.
5. Oh Jong-Keon, Hwang Jin-Ho, Sahu Dipit. Department of Orthopaedic Surgery, Korea University College of Medicine, Guro Hospital, Seoul, Korea Nailing of Intertrochanteric Fractures: Review on Pitfalls and Technical Tip Journal of Orthopaedics, Trauma and Rehabilitation. 2010; 14:3-7.
6. Evans EM. The treatment of trochanteric fractures of the femur. J Bone Joint Surg Br. 1949; 31B:190-203.
7. Nilsson A, Bremander A. Measures of hip function and symptoms: Harris hip score (HHS), hip disability and osteoarthritis outcome score (HOOS), Oxford hip score (OHS), Lequesne index of severity for osteoarthritis of the hip (LISOH), and American Academy of Orthopedic Surgeons (AAOS) hip and knee questionnaire. Arthritis care & research. 2011; 63(S11):S200-S207.