

E-ISSN: 2395-1958
P-ISSN: 2706-6630
IJOS 2019; 5(4): 1064-1069
© 2019 IJOS
www.orthopaper.com
Received: 04-08-2019
Accepted: 06-09-2019

Dr. D Vihari Sasank
Junior Resident, Department of
Orthopaedics Mamata Medical
College, Khammam, Telangana,
India

Dr. Sanjeev Chincholi
Professor, Department of
Orthopaedics, Mamata Medical
College, Khammam, Telangana,
India

A study on surgical management of extra articular distal femur fractures by retrograde intramedullary interlocking nail in adults

Dr. D Vihari Sasank and Dr. Sanjeev Chincholi

DOI: <https://doi.org/10.22271/ortho.2019.v5.i4r.1833>

Abstract

The distal femur fractures are complex injuries, and it can be challenging to manage. These fractures often are unstable, comminuted and tend to occur in elderly or multiply injured patients. Because of the proximity of these fractures to the knee joint, regaining full knee motion and function may be difficult. If the fracture of the hip square measure excluded, 31% of femoral fractures involve the distal portion. Distal femur fractures by definition require distal 9 cm of the femur^[2].

Extra-articular fractures of the distal femur are serious injuries that frequently result in varying degrees of permanent disability. The degree of functional loss is often the result of articular cartilage and bone damage, soft tissue injury or a combination thereof^[3].

Several published studies in the 1960s reported better results with non-surgical than surgical management of distal femur fractures^[10, 11]. But now, the most predictable results are presently attained with surgical interventions, and it is now recognized that operative fixation with ability to obtain an anatomical reduction of the joint surface, restoring axial alignment and beginning early range of motion present clear advantage over closed means of treatment^[12-16]. In 1970, the AO (Arbeitsgemeinschaft für Osteosynthesefragen) reported "if normal or near-normal function is to be achieved then unquestionably, if correctly employed, open reduction and internal fixation ensures a very high rate of success"^[1]. The AO has used angled blade plate in the treatment of these fractures, but there was an increased incidence of infection, inadequate fixation in the osteoporotic bone, malunion and the need for bone grafting in many cases^[8].

In cases with severe metaphyseal comminution, supracondylar nailing offers a lot of biological technique of fixation with less reduction of soft tissue. Fixation of intercondylar fractures is also possible with additional compression screws to stabilise the intra-articular fragments. Metaphyseal fragments are left undisturbed, which limits the need for bone grafting. It is especially useful in obese patients and fractures occurring below hip implants or above total knee implants that have an open notch design. It provides excellent axial and rotational stability for treating both open and closed fractures resulting in early mobilisation. Furthermore, small incision area results in rapid recovery with minimal morbidity for the patient.

Keywords: Distal femur, extra articular fractures, retrograde, intramedullary interlocking nail

Introduction

Objectives

The main objectives the present study is as follows.

- To study the advantages of retrograde intramedullary nailing.
- To look into the technical difficulties and complications associated with the surgical procedure.
- To study the union rates and functional outcome of treatment of distal femur fractures by retrograde intramedullary nailing.

Methods

A prospective study was done in the Department of Orthopaedics, which consists of 40 patients of extra-articular distal femur fractures were treated surgically by internal fixation with intramedullary interlocking nail during the period of two years

Corresponding Author:
Dr. Sanjeev Chincholi
Professor, Department of
Orthopaedics, Mamata Medical
College, Khammam, Telangana,
India

Inclusion Criteria

- All patients with age group above 18 years having Extra-articular distal femur fractures (AO Type 33A) were included (By definition, distal femur fractures include distal 15cm of the Femur) with an indication for surgical management.
- Patients have multiple fractures, and that was occurring below hip implants or above knee implants with an open notch design.

Exclusion Criteria

- Distal femur fractures of the AO type 33 B & C.
- Open distal femur fractures of Gustilo type-III.
- Open distal femur fractures presenting after 8 hours.
- Distal femur fractures in children (in whole the growth plate is still open)
- Pathological distal femur fractures.
- Patients lost in follow up.
- Patients managed conservatively for other medical reasons.
- Distal femur fractures with neurovascular compromise.

Operative procedure

Patients were operated under epidural/spinal/general anaesthesia. The patient was placed in supine position over a radiolucent operating table. A pneumatic tourniquet was applied. Then the limb was cleaned with detergent and cetrimide, scrubbed with povidine iodine (7.5%), painted with povidine (five percent) and draping done.

Positioning and Fracture Reduction

The procedure is performed on a radiolucent operating room table with the leg prepared out from the iliac crest to the middle of the calf. Sterile stocknet is placed over foot and ankle. Although some authors recommend placing as bolster under the hip, this can lead to malrotation. The easiest position is supine with the femoral nail inserted with the patella in neutral rotation. A bolster is placed under knee to flex it approximately to 45 deg. too much flexion, approximately 90 deg. puts the patella in danger, over the insertion site. Conversely, too little flexion leaves the proximal anterior tibia in the way of the surgical route. Tourniquet use is optional.

Incision and Nail Entry Point

Use a vertical skin incision from the inferior pole of the patella to the tibial tuberosity. The knee joint is opened using a trans-patellar capsule incision.

Self-locking retractors are used. Then the fat is pushed to one side using blunt dissection.

The point of entry of the nail lies centrally between the condyles in the sulcus intercondylar, approximately 1 cm anterior to the insertion of the posterior cruciate ligament.

Preparation of the Medullary Canal

After the creation of the entry portal, awl was removed and replaced with a ball-tipped guide wire. This guide wire was advanced across the fracture into the diaphysis under fluoroscopic control. There are several ways to achieve a reduction. The most simple is manual traction and the application of correctional forces. An eight mm end-cutting reamer was used to enlarge the condylar portal and then progressively reamed in 0.5 mm increments to one to 1.5 mm larger than the diameter of the selected nail. The shaft was reamed to a point slightly proximal to the expected tip of

the nail. The entry point was reamed 1.5 mm more significant than the selected nail to avoid displacing the condyle when the nail is inserted.

Nail Selection

The size of the implant was based on the location and extent of the fracture. It was ensured that the size chosen will enable the nail to be locked securely into the proximal non-fractured zone.

Nail Insertion 58, 60

A nail of the proper length and diameter was connected with the alignment rod placed through the guide bar. The apex at the distal end of the nail usually was directed dorsally, and guide bar positioned laterally. The nail was advanced over the guide wire into the distal condyles and then across the fracture site, into the diaphysis. The nail was developed until the distal end was countersunk two to five mm below the surface of the intercondylar notch and guide wire was removed. Failure to countersink the nail may adequately lead to patellar impingement. Anterior to posterior or lateral to medial blocking screws can be used to help align the nail and prevent malreduction at this point.

Templates

Distal locking is usually done first.

First place the template corresponding to the nail size on the introducer / target device. It will remain on the target device throughout the interlocking procedure.

Before locking, the nail guide wire (if used), must be removed, the nail holding screw must be fully tightened by means of the spanner. This enables you to ensure that the nail and the target device have been properly aligned.

Before distal interlocking is begun, the correct position of the nail in the medullary cavity must be verified in both planes under image intensifier control.

Screws placement 58, 60

These supracondylar nails should be statically locked with at least two distal and two proximal screws. One proximal screw may be used if the nail has at least 10 cm of secure intramedullary purchase.

The distal interlocking screws usually were placed first. A stab incision was made through the fascia to the cortex through the most distal hole in the drill guide. The drill sleeve was advanced through the drill guide to the cortex and drill bit was used to penetrate both cortices. For proper screw selection, depth measurements were taken by reading the calibration of the drill bit.

To place the screw, sleeve was withdrawn and the appropriate length screw and screwdriver was assembled. Screwdriver was placed through the sleeve and screw advanced through both cortices. Second distal locking screw was placed in the same manner.

Two screws usually are used for proximal interlocking. The more distal screw is placed first. A stab incision is made, and drill sleeves are passed to the femoral cortex. Under fluoroscopy, the hole was drilled, screw length measured, and the screw was placed. A second proximal locking screw was placed similarly.

Alternatively, proximal- locking screws were inserted with a freehand technique or radiolucent drill. The wounds were irrigated copiously and closed in layers.

Romovac drain is placed if an open reduction is required. Before the medullary cavity is opened, the point of entry

should be verified in both planes using the image intensifier. In the AP view, the supracondylar nail should be centered in the medullary cavity, and in the lateral plane, the safe central insertion of the nail must be ensured, taking into account the 80 curvature of the nail. The exact point of entry depends on the type of fracture and its particular tendency to dislocate, bearing in mind the individual anatomic features of the case

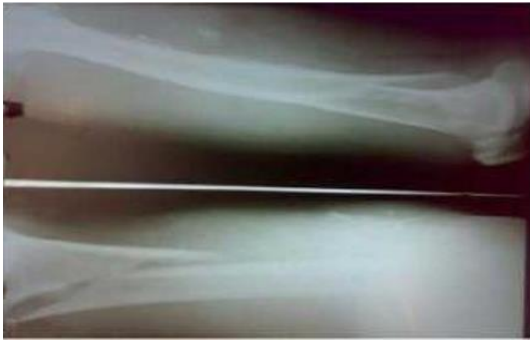

Fig 1: Pre-operative x-ray

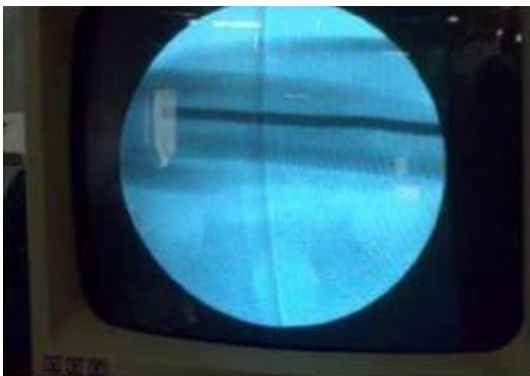


Fig 2: Guidewire passing through the fracture site




Fig 3: Supracondylar nail passing over guidewire

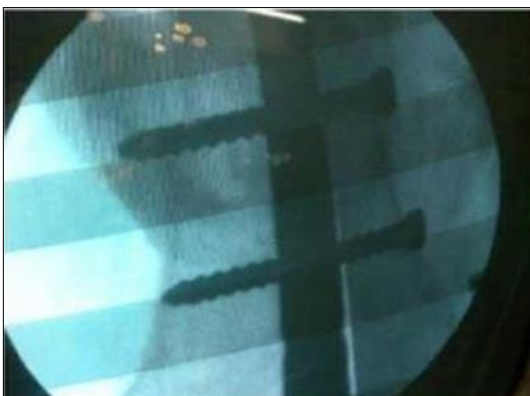


Fig 4: Distal locking (2 Screws)

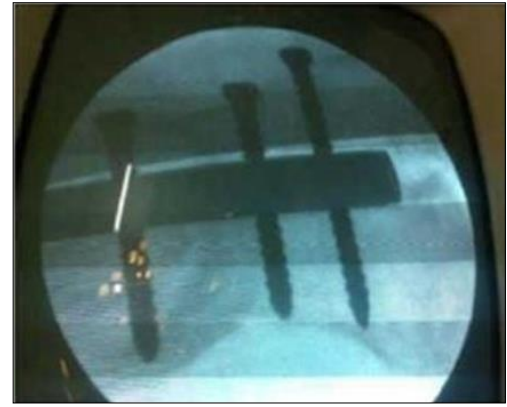


Fig 5: Distal locking (3 Screws)

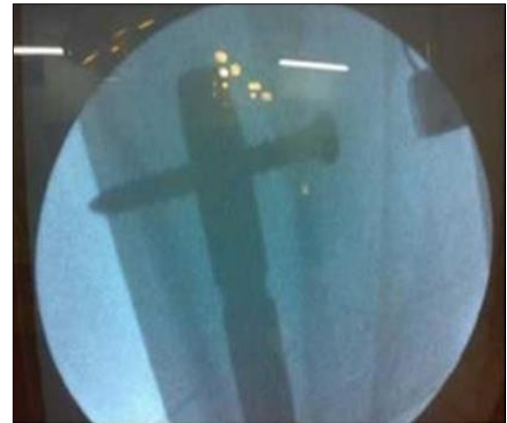

Fig 6: Proximal locking

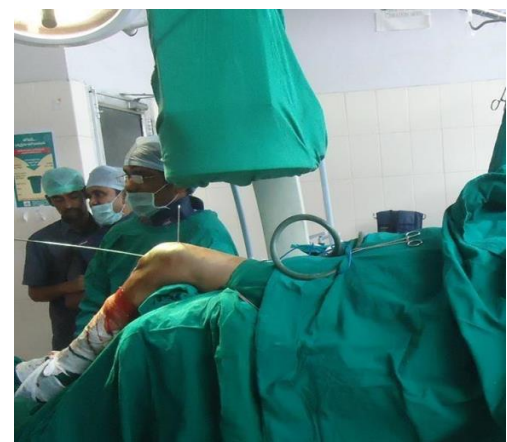

Fig 7: preparation

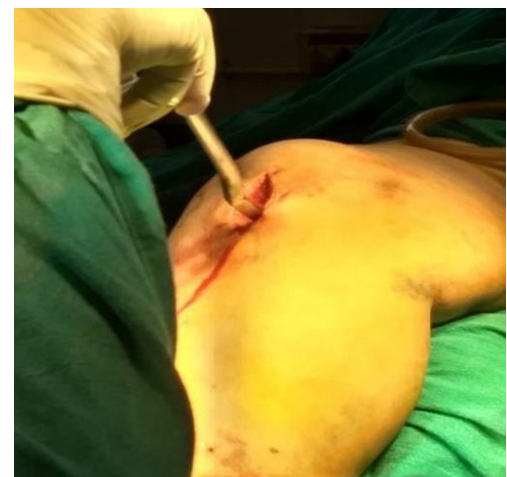

Fig 8: entry point with bone Awl

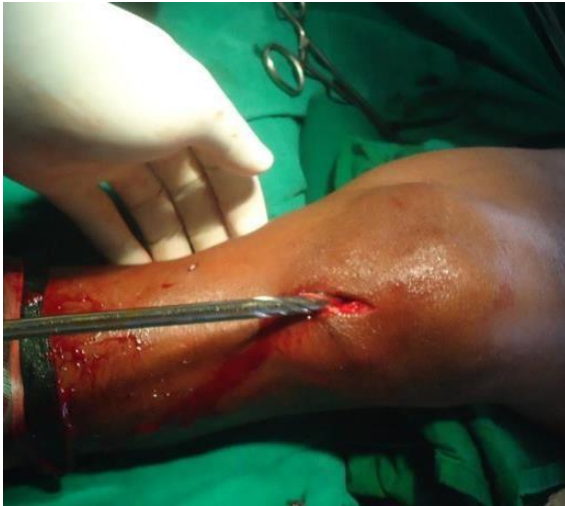

Fig 9: reaming

Post-operative management

- Day 1:- use of a CPM machine is strongly advised. The rationale includes, it enhances cartilage healing, increased knee motion, decreased limb swelling and a lower incidence of quadriceps adhesions. It is maintained full time until ambulation is started.
- Day 2:- Started with active quadriceps and hamstring exercises and continued CPM.
- Day 3:- Gait training progresses from the use of parallel bars to a walker or crutches, with weight-bearing as determined by the stability of the fixation intraoperatively. In patients with stable internal fixation, partial weight-bearing (i.e., up to 10 to 15 pounds of body weight) is permitted. In unstable fractures, weight-bearing is delayed until radiological evidence of fracture healing, and a fracture brace may be necessary.
- By six weeks if x-rays show signs of progressive fracture consolidation, increased weight-bearing with support is allowed.

Duration of follow-up

- Clinical follow up at 4thweek, 8thweek, 10th week, 14th week, three months and until evidence of radiological union (or) Implant failure.
- During each follow-up, assessment of a range of motion, assessment of the soft tissues, and evaluation of the rotational alignment, leg length discrepancy and deformities with Neer's Criteria and any complications will be recorded

Method of Evaluation: Clinical assessment Radiological Union: 1

- The radiological examination was performed in two planes and assessed for callus formation and varus-valgus and flexion-extension deformities. "Union" was defined as the appearance of bridging callus and trabeculations extending 55 across the fracture site. "Non-union" was defined as no evidence of fracture union progression in six months of follow up.
- "Delayed union" was defined as the appearance of the signs of fracture union, but the progress of union to consolidation is delayed than is otherwise expected. "Malunion" was defined as varus-valgus angulations higher than five degrees, apex anterior-posterior angulations higher than 10 degrees and rotational malalignment greater than 15 degrees.

Preoperative Complications

- Inappropriate initial patient selection is one of the leading causes of later fixation failure and infection.
- The need to assess the intercondylar notch region to ensure that intraarticular fracture lines and comminution have not irreparably compromised the retrograde entry portal area. Computed tomography can provide this information.

Intra-operative Complications

- Injury to the knee joint, resulting in pain or instability, is the most common complication.
- It is essential to place the retrograde entry portal in the proper location. This minimises the risk of injury to the posterior cruciate ligament, and facilitates proper axial fracture alignment after nail insertion.⁴⁴An anterior, medial or lateral malposition will infringe on the distal femoral articular surface or the patellofemoral joint.
- The potential for damage to the undersurface of the patella also exists during the insertion of these reamers.
- Another potential problem of intramedullary reaming is reaming debris left in the knee joint. It makes sense to irrigate the knee after completion of the procedure thoroughly.
- Leaving the end of the nail sticking in the knee joint is a poor technique; however, the highest risk of nail protrusion is not from an intraoperative error but subsequent distal nail migration.
- Bleeding or neurological complications are very rare.

Postoperative Complications

- Knee Pain
- Knee Stiffness
- Delayed union and non-union
- Infection
- Patello-femoral arthritis
- Limb length discrepancy
- Synovial metallosis
- Heterotopic ossification

Results

Table 1: Time taken for radiological union

Time of union (Weeks)	Number	Percentage
16 to 18	3	7.50%
18 to 20	12	30.00%
20 to 22	15	37.50%
22 to 24	10	25.00%
Total	40	100.00%

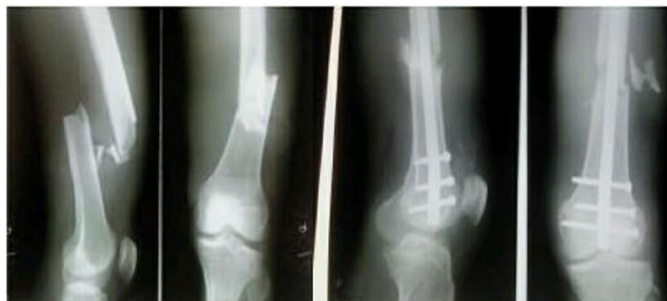Average (Mean \pm SD) time to fracture union was 21.08 \pm 1.95weeks (ranging from 16 weeks to 24 weeks). 3 (7.50%) cases took 16 to 18weeks time to radiological union. 12 (30.00%) incidents took between 18 to 20weeks time to radiological union. 15 (37.50%) incidents took between 20-22 weeks. There were ten delayed unions (25.0%) which took 22-24 weeks. None of the patients required bone grafting.

Table 2: Functional outcome evaluation scale by Neer's rating score

Outcome	Number	Percentage
Excellent (> 85 Points)	33	82.50%
Good (70-84 Points)	04	10.00%
Fair (50-69 Points)	01	2.50%
Poor (< 50 Points)	02	5.00%

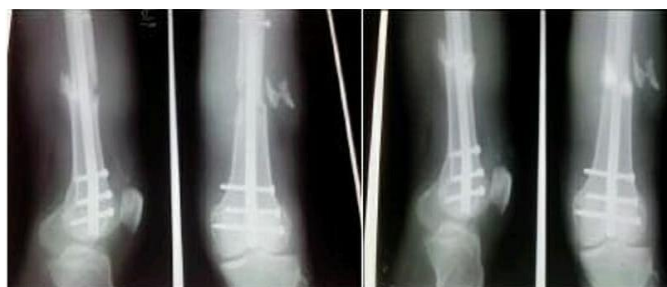Long term final results were rated using Neer's rating system, which allows points for pain, function, working ability, joint movements, gross and radiological appearance. Neer's rating score was allotted to each patient after 24 to 36 weeks. Using this scale there were 33 (82.50%) had excellent results, 4 (10.00%) had good results, 2 (5.0%) had poor results, and 1 (2.50%) patients were reported fair result outcome.

Case 1



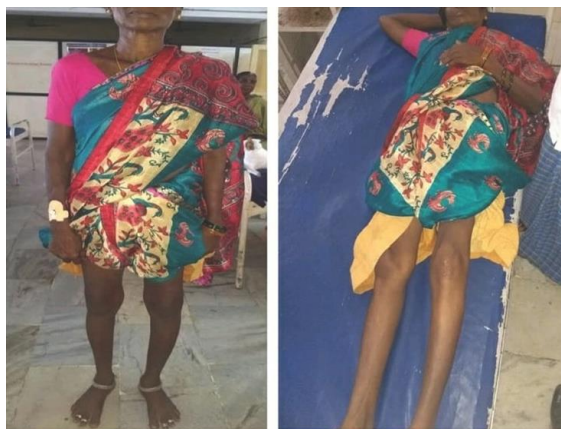Pre-operative X-ray

Immediate post-operative X-ray



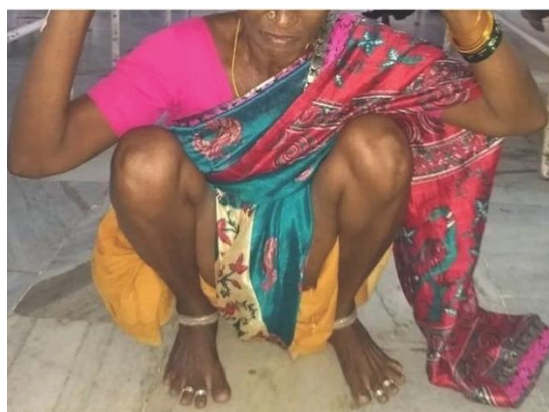4 weeks follow X-ray five months follow up X-ray

Clinical photographs



Full weight bearing

Active extension



Active flexion

Discussion

The present aim of the study is to study on surgical management of extra-articular distal femur fractures by a retrograde intramedullary interlocking nail in adults. Management of distal femur fractures is particularly tricky due to osteoporosis and other associated comorbidities. The key to control of these fractures is by surgical stabilisation, thus allowing early mobilization.⁵⁴

The concept of retrograde supracondylar intramedullary nailing in distal femur fractures was developed ifn an attempt to overcome the limitations of antegrade nailing in multiple system injuries (necessity of extension table) or distal fracture type and to ensure the advantages of minimally invasive technique in contrast to plate osteosynthesis. While supracondylar nailing is an accepted minimal invasive procedure for osteosynthesis of femoral fractures.

Biomechanical analysis of various supracondylar nailing systems compared with the plate systems predominantly have shown a lower torsional and axial stiffness but similar bending stiffness, particularly for physiologic and critical modes of varus loading. In 1991 it was reported "by virtue of intramedullary position", the GSH (Green SA, Seligson D, Henry SL) nail has a biomechanical advantage over laterally placed conventional devices.^[22] The intramedullary position decreases the lever arm, reducing varus or valgus moment on the fracture. The correct choice of the supracondylar nail insertion site is mandatory to restore the physiological rotation and mechanical alignment. The actual intercondylar location of this entry point has been variously described as dictated by the clinical experience of various surgeons. In the vast majority of femurs, the optimal entry portal for supracondylar femoral nailing is located in the expected safe position, anterior to the posterior cruciate ligament insertion and slightly medial to the center of the intercondylar groove. The potential compromise of the patella-femoral contact area by the retrograde entry portal can be recognized before nailing during the initial intraoperative fluoroscopic imaging of the fracture. In this way, the surgeon has the option, based on the individual clinical situation, to proceed with supracondylar nailing using a sub-optimal entry-portal location.

Interpretation and Conclusion

1. Retrograde intramedullary supracondylar nail is a good fixation system for distal third femoral fractures, particularly extra-articular type.
2. The operative-time is lessened with a decrease in blood loss.
3. If closed reduction can be achieved by not disturbing fracture hematoma and soft tissue.
4. Even with open reduction, there is less soft tissue trauma and less postoperative stiffness.
5. Distal screw related local symptoms is a general problem and aresimilar to implant and technique; and has a definite learning curve.
6. Utmost great care requiresto avoid infection.
7. There is no non-union, less delayed unions and rates of angular or rotational mal-unions.
8. Non-requirement of bone graft decreases the morbidity associated with the donor site.
9. Early surgery, closed reduction, at least two screws in each fragment and early post-operative knee mobilization are essential for good union and good knee range of motion.
10. There is no much variation in individual fracture type healing and weight-bearing

References

1. Whittle AP, Woodll GW. Campbell's operative orthopaedics, Chapter 51, In: Fractures of Lower Extremity, 10th ed, Mosby Inc., 2003, 3.
2. O'Brien PJ, Meek RN, Blachut PA, Broekhuysen HM. Fractures of the distal femur: Rockwood and Green's fractures in Adults. 5th ed, Lippincott Williams and Wilkins, 2001, 2.
3. Schatzker J. Fractures of the distal femur – revisited ClinOrthop. 1998; 347:43-56.
4. Neer CS, Grantham SA, Shelton ML. Supracondylar fracture of the adult femur. J Bone Joint Surg. 1967; 49A:591-613.
5. Selfert J, Stengal D, Matthes G, Hinz P, Ekkernkamp A, Ostermann, PAW *et al.* Retrograde Fixation of Distal femoral fractures: Results using a New Nail system. J Orthop Trauma. 2003; 17(7):488-495.
6. Jahangir J, Hossain MI, Mojumder MM, Hossain M, Hossain MA, Uddin MI. Management of Distal Femoral Fracture with Distal Femoral Nail. ChattagramMaa-O-Shishu Hospital Medical College Journal. 2017; 16(2):44-7.
7. Bucholz RW, Heckman JD. Rockwood and Greens fractures in adults. 6th Ed. London: Lippincott Williams and Wilkins, 2005.
8. Rabin SI, Carlson D, Rabin SL. Complications of Supracondylar Femur Fractures. Loyola U Orthopaedic J. 1995; 4:30-8.
9. Wolinsky P, Tejwani N, Richmond JH, Koval KJ, Egol K, Stephen DJ. Controversies in intramedullary nailing of femoral shaft fractures. JBJS. 2001; 83(9):1404-15.
10. Stewart MJ, Sisk TD, Wallace SL. Fractures of the distal third of the femur. J Bone Joint Surg. 1966; 48A:784-807.
11. Neer CS, Grantham SA, Shelton ML. Supracondylar fracture of the adult femur. J Bone Joint Surg. 1967; 49A:591-613.
12. Wenzl H, Casey PA, Heber, Belin J. Die operative Behandlung der distalen Femurfraktur: AO Bulletin; Chur AO, 1970.
13. Schatzker J, Horne G, Waddell J. The Toronto experience with the supracondylar fracture of femur 1966-1972. Injury. 1974; 6:113-128.
14. Schatzker J, Lambert DC. Supracondylar fractures of the femur. Clin Orthop. 1979; 138:77-83.
15. Olerud S. Operative treatment of supracondylar fractures of femur. Techniques and results in fifteen cases. J Bone Joint Surg. 1972; 54A:1015-1032.
16. Chiron HS, Tremoulet J, Casey P, Muller ME. Fractures of the distal third of the femur treated by internal fixation. Clin Orthop. 1974; 100:160-170.
17. Helfet DL, Lorich DG. Retrograde intramedullary nailing of supracondylar femoral fractures. Clin Orthop. 1988; 350:80-84.
18. Green SA. Distal intramedullary fixation of supracondylar fractures of femur. Tech Orthop. 1988; 3:71-6.
19. Gellman GD, Paiement HD, Green, Coughlin RR. Treatment of Supracondylar Femoral Fractures with a Retrograde Intramedullary nail. Clin Orthop Relat Res. 1996; 332:90-7.
20. Mize RD, Bucholz RW, Grogan DP. Surgical treatment of displaced, comminuted fractures of the distal end of the femur: An extensive approach, J Bone Joint Surg. 1982; 64A:871.