



# International Journal of Orthopaedics Sciences

E-ISSN: 2395-1958  
P-ISSN: 2706-6630  
IJOS 2019; 5(4): 1055-1063  
© 2019 IJOS  
www.orthopaper.com  
Received: 26-08-2019  
Accepted: 29-09-2019

**Munir Farooq**  
Professor and Head of  
Orthopedic Department, GMC  
Srinagar, Jammu and Kashmir,  
India

**Ajaz Ahmad Bhat**  
Medical Officer, Department of  
Health, Jammu and Kashmir,  
India

**Zubair Ringshawl**  
Postgraduate Scholar,  
Orthopedic Department, GMC  
Srinagar, Jammu and Kashmir,  
India

**Corresponding Author:**  
**Munir Farooq**  
Professor and Head of  
Orthopedic Department, GMC  
Srinagar, Jammu and Kashmir,  
India

## Hemiarthroplasty for proximal humerus fractures

**Munir Farooq, Ajaz Ahmad Bhat and Zubair Ringshawl**

**DOI:** <https://doi.org/10.22271/ortho.2019.v5.i4r.1821>

### Abstract

Proximal humerus fractures are common injuries that are increasing in incidence with the increasing life expectancy and associated rise in osteoporosis. Majority of the proximal humerus fractures are minimally displaced and can be treated non-operatively with good functional results. However unstable displaced fractures have high morbidity especially in older patients. These unstable and displaced fractures may require operative intervention to ensure a successful outcome. Evaluation of both patient and fracture characteristics is important in deciding the appropriate type of surgical intervention. The aim of surgical fixation is to restore articular congruency, alignment and the proper positioning of tuberosities with respect to humeral head. Hemiarthroplasty is indicated in fracture dislocations, head splitting fractures and some three or four part fractures. In the elderly, especially with more complex four-part fractures and fracture dislocations, hemiarthroplasty and reverse total shoulder arthroplasty are indicated to decrease complication rates and improve functional outcomes. Restoration of proper humeral height, version and tuberosity position are key to success in hemiarthroplasty. Fractures in which the tuberosities are unlikely to unite or cannot be reconstructed well, reverse total shoulder arthroplasty should be considered.

**Keywords:** Hemiarthroplasty, fracture, proximal humerus, tuberosities

### Introduction

#### Background

Fractures of proximal humerus account for nearly 5% of all fractures<sup>[1]</sup>. They occur most commonly in elderly population. The incidence of these fractures has increased considerably in the last two decades, probably due to increase in the life expectancy and the associated increase in the incidence of osteoporosis<sup>[2]</sup>. In patients older than 65 years, about 60% of all proximal fractures happen due to indoor (low energy) trauma<sup>[3]</sup>. In younger patients, high energy trauma is the cause and displacement is often more severe. These patients usually have a fracture dislocation<sup>[4]</sup>.

Majority of the proximal humerus fractures are minimally displaced and can be treated non-operatively with good functional results<sup>[5]</sup>. However unstable displaced fractures have high morbidity especially in older patients<sup>[6]</sup>.

Treatment of these unstable, displaced and comminuted fractures remains a challenge and optimal treatment continues to be controversial. Many different techniques of internal fixation have been described including bone sutures, tension band, cerclage wires, kirschner (K) wires, T-plates, intramedullary devices, double tubular plates, semitubular blade plate, the PlantTan Humerus Fixator plate and the Polaris nail<sup>[7]</sup>. Various complications have been reported using these techniques including cut-out or back out of the screws and plates, avascular necrosis, non-union, mal-union, nail migration, rotator cuff impairment and impingement syndrome<sup>[8]</sup>. This results in a painful shoulder with poor function<sup>[9]</sup>. Secondary prosthetic replacement of the humeral head in these fractures has also yielded unsatisfactory functional results<sup>[10]</sup>.

To overcome the common problems associated with the treatment of these fractures, the AO/ASIF group developed the proximal humeral internal locking system (PHILOS) plate. It aims to preserve the biology of humeral head by minimizing soft tissue dissection and secure an anatomical reduction using multiple screws with angular stability, thereby improving stability in osteoporotic bone<sup>[11]</sup>. But it also reportedly caused Avascular necrosis<sup>[12]</sup>, tuberosity avulsion, non-union and secondary stiffness.

Severely displaced fractures of the proximal part of the humerus have not achieved consistently

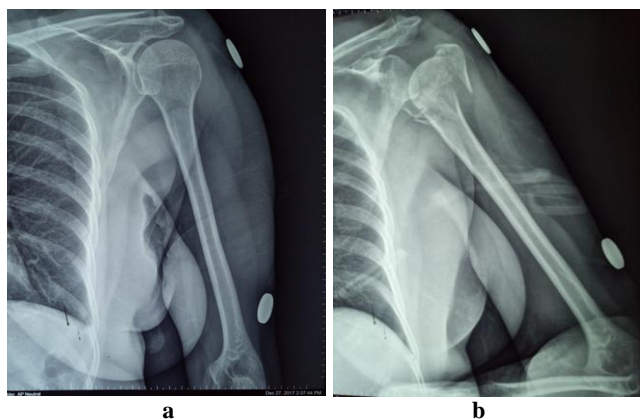
acceptable results when treated with conservative methods or open reduction and internal fixation techniques [12].

Hemiarthroplasty as a primary treatment alternative has been proposed in most relevant studies; however in some reports poor results were obtained [12, 13, 14]. Hemiarthroplasty is suggested as a treatment option in three and four part fractures with osteoporotic bone with a compression fracture affecting more than 45% of the head, and split fractures when the separated part is greater than 45% of the humeral head [12, 15, 16].

**Clinical evaluation**

The combination of history, examination and radiography plays a vital role in decision making. History includes age of patient, time since injury, hand dominance, functional level of shoulder prior to injury, any comorbidities, cognition and ability to participate in rehabilitation protocol. Clinical examination must include neurovascular examination. Sensations over lateral aspect of shoulder should be assessed for axillary nerve integrity. Distal neurological examination must be done to rule out brachial plexus injury.

Imaging must include a true AP, Scapular V-Y View, modified axillary view (Velpaue View). All these images can be taken with limb in a sling, so avoiding any manipulation of limb during radiography. CT Scans with 3-D reconstruction must be done in all cases which are considered for operative intervention. These imaging studies will provide valuable information regarding fracture displacement, presence of articular component, head split and also bone quality. For preoperative templating AP view of both shoulders with full profile of humerus must be taken in order to determine planned length and height of implant using Gothic Arch technique [17] (figure 1a & 1b)



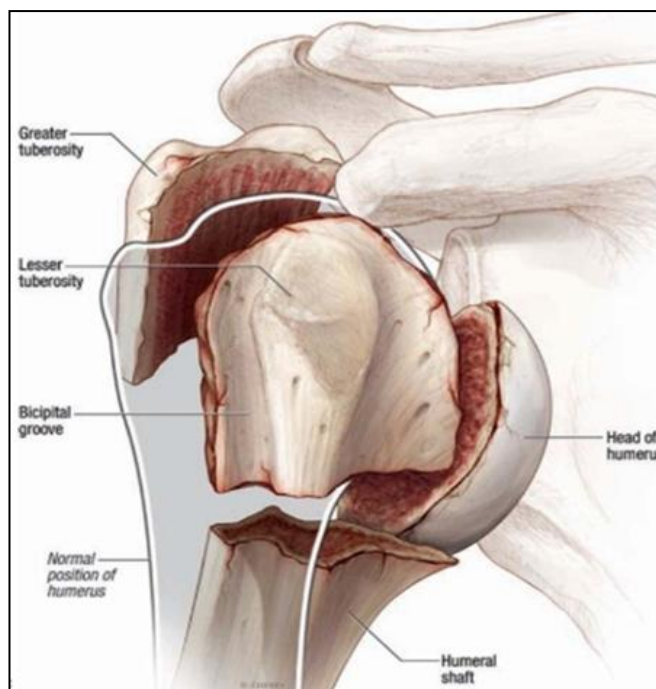
**Fig 1a & 1b:** Showing full length radiograph of both normal & fractured humeri

The distance between the superior most point of humeral head and transepicondylar axis of unaffected shoulder difference the distance between the fracture line medially and transepicondylar axis of affected shoulder gives the value of height which is to be restored after proper magnification control.

**Classification**

In 1934, Codman [18] classified proximal humerus fractures based on the anatomic location of the fracture. He divided the proximal humerus into four parts ie, head, greater tuberosity, lesser tuberosity, surgical neck (figure 2) based on epiphyseal lines [18]. Neer [19] expanded this classification scheme to include fracture displacement and angulation to define the

severity of the fracture pattern (Figure 3). He defined a fracture part as a fragment displaced >1 cm or angulation >45°. The probability of humeral head necrosis increases with the severity of the fracture.



**Fig 2:** Diagram showing cleavage plane of four parts of proximal humerus

	2-part	3-part	4-part	
Anatomical neck				
Surgical neck				
Greater tuberosity				
Lesser tuberosity				
Fracture-dislocation				
Anterior Posterior				

**Fig 3:** Near classification of proximal humerus features

The AO classification, which is less frequently used than the Neer and Codman classification systems, emphasizes determination of whether vascularity to the articular fragment is significantly compromised.

**Type A is an extra-articular unifocal fracture**

- A1 - tuberosity
- A2 - metaphyseal impacted region
- A3 - metaphyseal not impacted region.

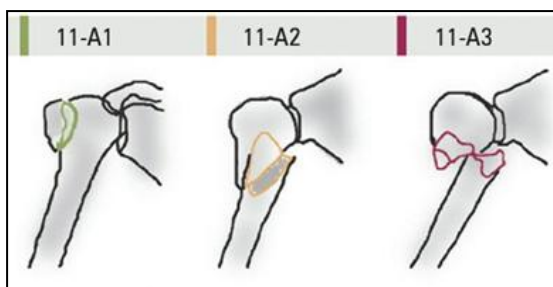


Fig 4: Showing extra-articular unifocal fractures

**Type B is an extra-articular bifocal fracture.**

- B1 - metaphyseal impacted region
- B2 - metaphyseal not impacted region
- B3 - dislocated shoulder

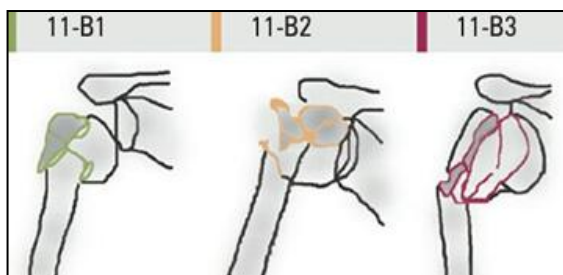


Fig 5: Showing extra-articular bifocal fractures

**Type C is a fracture or fracture-dislocation of the articular surface.**

- C1 - mild displacement
- C2 - impacted with marked displacement
- C3 - dislocated shoulder

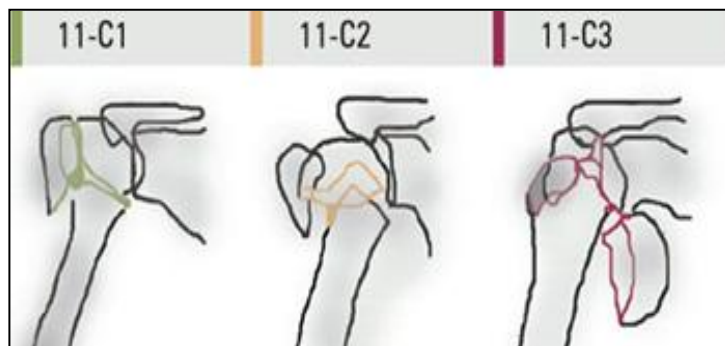


Fig 6: Showing fracture or fracture dislocation of articular surface

Before surgery is considered, it is important to determine if the blood supply and bone quality are adequate. The Hertel<sup>[20]</sup> radiographic criteria for perfusion of the humeral head (Figure 7) can be used to predict ischemia: metaphyseal extension of the humeral head of less than 8 mm and medial hinge disruption of more than 2 mm are predictive of ischemia. The combination of metaphyseal extension of the humeral head, medial hinge disruption of more than 2 mm, and an anatomical neck fracture pattern has a 97% positive predictive value for humeral head ischemia.

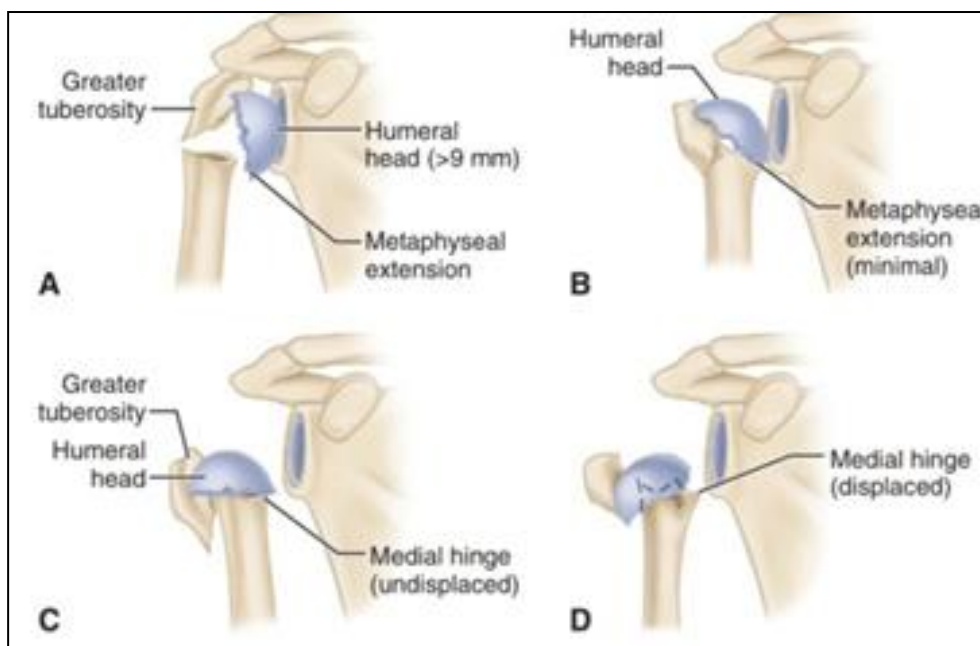


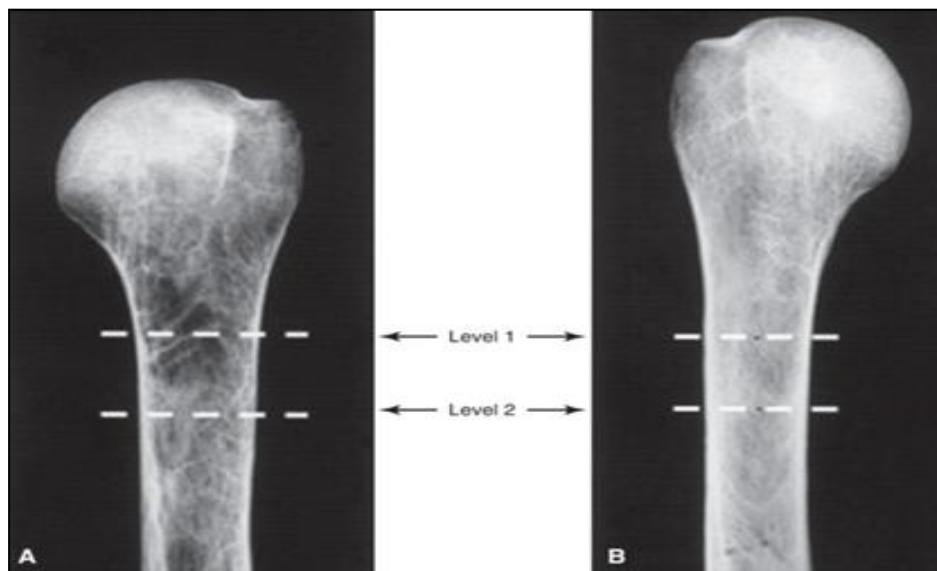
Fig 7(A-D): Hertel radiographic criteria for perfusion of humeral head. A, Metaphyseal extension of humeral head greater than 9 mm. B, Metaphyseal extension of humeral head less than 8 mm. C, Undisplaced medial hinge. D, Medial hinge with greater than 2-mm displacement.

According to the AO/ASIF classification system, extraarticular type A fractures have an intact vascular supply, whereas type B fractures have a possible injury to the vascular supply and type C articular fractures have a high probability of osteonecrosis.

The cortical thickness of the humeral diaphysis has been suggested to be a reliable and reproducible predictor of bone

mineral density and the success of internal fixation. The combined cortical thickness is the average of the medial and lateral cortical thickness at two levels<sup>[21]</sup> (Figure 8). Generally, a cortical thickness of less than 4 mm precludes internal fixation because adequate screw purchase cannot be obtained; sling immobilization, transosseous suture, or hemiarthroplasty may be better options.





**Fig 8(A-B):** Two levels used to measure cortical thickness of humeral diaphysis. Level 1, most proximal aspect of humeral diaphysis, is at level in which endosteal borders of medial and lateral cortices are parallel. Level 2 is 20 mm distal to level 1. Examples of patients with low bone mineral density (A) and high bone mineral density (B).

### Natural history/Nonoperative treatment

It is important to understand the natural history of nonoperative management of a condition in order to appreciate the added benefit of surgical intervention, arthroplasty or otherwise. In proximal humerus fractures, both patient and fracture characteristics determine the final outcome of nonoperative treatment. Court-Brown *et al.*, demonstrated good to excellent results in 80% of patients with valgus impacted fractures treated nonoperatively [22]. The preferred treatment in more displaced, unstable and comminuted fractures especially in the elderly remains a challenge and continues to be controversial.

Edelson *et al.*, studied the natural nonoperative history of more complex fractures that are otherwise treated surgically [23]. They found that more extensive and comminuted fractures did marginally poorer with regard to motion, as compared with three-part injuries. Although malunion was universal, most of the patients eventually became pain free, with sufficient motion and strength to perform basic activities of daily living. They describe that even in the most severe proximal humerus fracture, the clinical result is similar to that achieved with a successful shoulder fusion. Rasmussen and Zyoto in their studies of natural nonoperative history of proximal humerus fractures showed improved results with less displacement and comminution and lower functional scoring and motion in three- and four-part fractures, but with reasonable patient satisfaction [24, 25]. However, these studies are primarily retrospective and are limited to lower levels of evidence.

### Indications

The indications for arthroplasty fall into two categories: patient characteristics and fracture characteristics. Patients are required to be medically stable in order to tolerate extensive surgery and be able to actively participate in rehabilitation after surgery. Fracture characteristics include head-splitting patterns and fracture dislocations [26]. A head splitting fracture in a young patient can pose a real dilemma as the surgeon wants to preserve humeral head but this may not be technically feasible. The use of hemiarthroplasty in the management of displaced three and four part fractures is controversial and depends on both patient and fracture factors.

Patients who are elderly with low functional requirements and have poor bone-quality are more likely to benefit from hemiarthroplasty. Fractures that are comminuted, severely displaced, have features associated with avascular necrosis [20] and are delayed in presentation are also more likely to benefit from hemiarthroplasty.

Krishnan *et al.* found that age is the most important consideration in the surgical management of proximal humerus fractures. Patients greater than 70 years of age should undergo arthroplasty over osteosynthesis because of poor neuromuscular control and osteoporotic bone leading to poor fixation [27]. They also outlined three other factors to guide treatment: bone quality, fracture pattern, and the timing of surgery—acute (<4 weeks) or chronic (>4 weeks) [27].

### Surgical technique

The patient is placed on the operating table in semi-sitting position (beach-chair). The entire upper extremity is prepared and draped free. A deltopectoral approach is used.

The skin incision (figure 9) is started at the tip of the coracoid process and extended distally and laterally approximately 10-15cm. An electro cautery used for dissection throughout the procedure to minimize haemorrhage. The interval between pectoralis major and deltoid is identified by locating the cephalic vein and retracted laterally with deltoid muscle. The superior portion of pectoralis major tendon is divided to enhance exposure. A self retaining retractor is placed to maintain exposure during the procedure. The conjoined tendon is identified and traced to its insertion on the coracoid process and is retracted medially to expose the proximal humeral fracture.

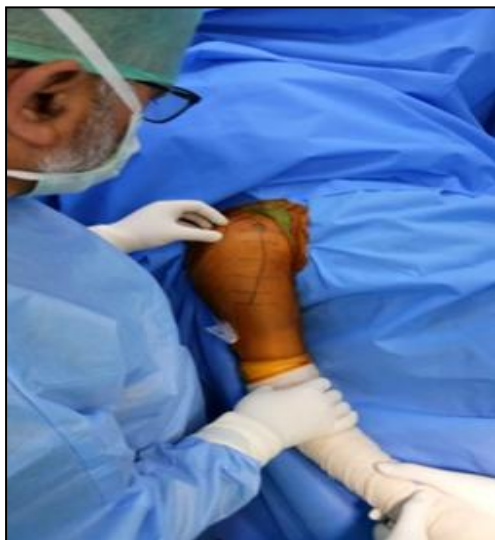A Cobb elevator is used to perform blunt dissection and tuberosities are identified. Control of the lesser tuberosity is achieved by identifying the tuberosity and subscapularis tendon anteriorly in the shoulder just posterior to the conjoined tendon. One or two sutures are placed through the subscapularis tendon (figure 10a) just medial to its osseous insertion on the lesser tuberosity. Suture is used for later fixation and also helped in retracting the tuberosity in order to gain access to the humeral head fragment. The humeral head fragment is identified and removed with locking forceps. Head is kept on the sterile field for later use as a bone graft

material and for size match with prosthetic head (figure 12). Removal of the humeral head (figure 10b) facilitates identification of the greater tuberosity, which is located posteriorly in the shoulder. Control of the greater tuberosity is achieved by identifying the posterior superior rotator cuff and three non absorbable sutures are passed through cuff tendons just medial to their insertion on the greater tuberosity (figure 10a).

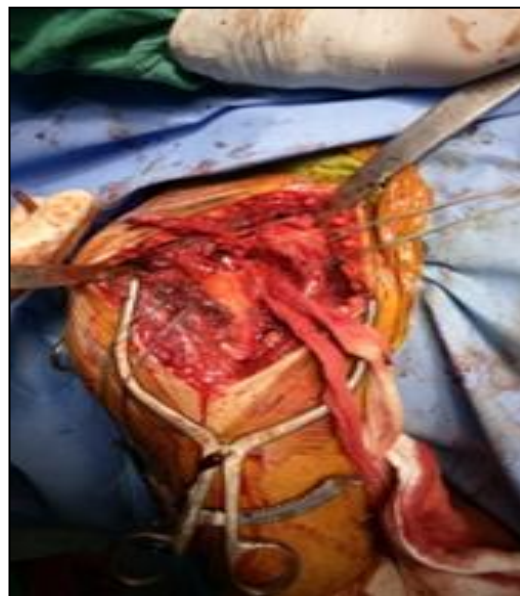The glenoid vault is inspected, and any remaining fragments of bone removed. The humeral shaft is exposed by extending and adducting the arm. The humeral shaft is reamed to determine canal size (figure 11). A modular trial stem size is placed to determine height and version. With arm at neutral, the head component should face the glenoid. A trial prosthetic stem is placed over version guide provided with jigs. The trial head is selected, and the tuberosities are temporarily reduced. Range of motion is evaluated. Assembly of trial head and stem is checked under C-Arm for proper height.

Two holes are drilled in the humeral shaft straddling then bicipital groove 1.5 cm distal to the fracture site at the fracture line (figure 13). Two number non absorbable sutures are placed prior to cementing so that they exit through the cortex of the shaft. These were used later for figure of eight fixation. A cement plug is placed in the shaft 1.5 cm distal to the stem. Prior to placing the stem, a 3 mm Dacron suture is placed in the medial hole of the prosthesis. The stem is then cemented in place over a version guide.

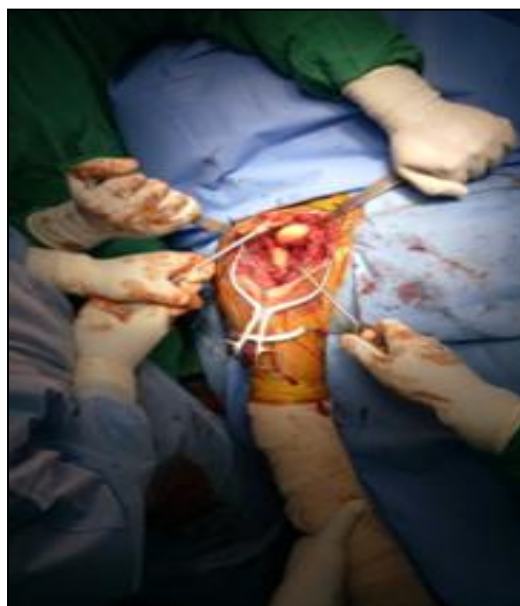The trial head is placed. Proper head size and height allowing approximately 50% anterior- posterior translation and 25% inferior translation with regard to glenoid is chosen. Proper height is achieved by measuring the distance from superior margin of pectoralis major insertion to superior aspect of humeral head which is 56 mm<sup>[28]</sup> (figure 14). This assembly of stem and head is again checked under C-Arm for proper height and head size. The trial is removed and prosthetic head was placed on the stem. The suture attached to the stem is passed through the bone tendon junction. Graft from the humeral head is prepared and placed at the tuberosity-stem interface. The tuberosities are reduced and fixed by the previously placed sutures in a circlage fashion (figure 15a-b) and the shaft sutures in a figure of eight fixation. Fixation of the greater tuberosity in relation to prosthetic head is aimed at in the range of 5-10 mm below the superior aspect of prosthetic head. Wound is closed in layers over a suction drain (figure 16).



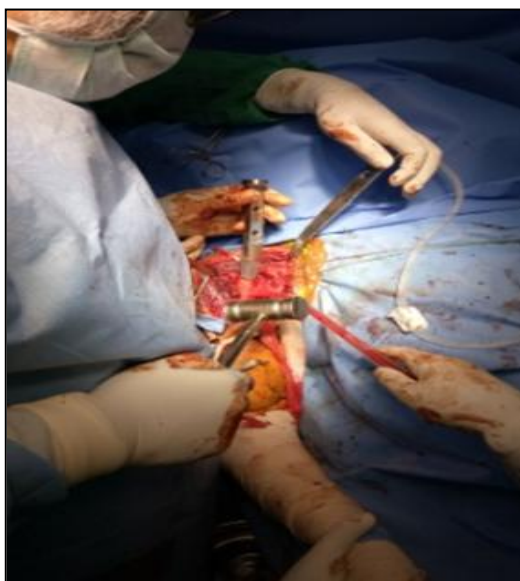
**Fig 9:** Showing marking of deltopectoral approach



**Fig 10a:** Showing tagging of tuberosities

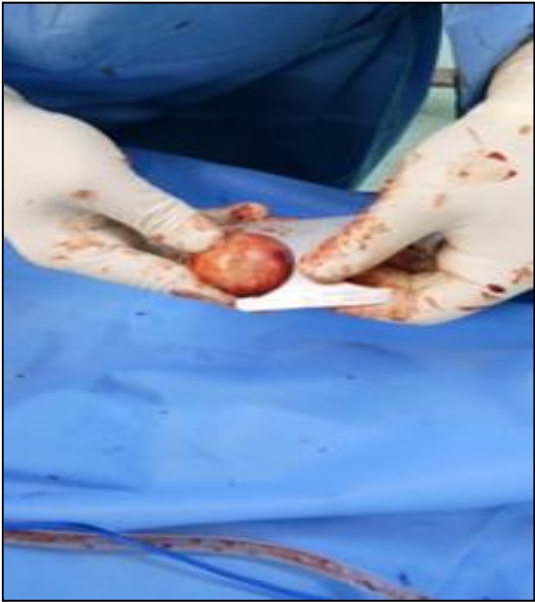


**Fig 10b:** Showing retrieval of head

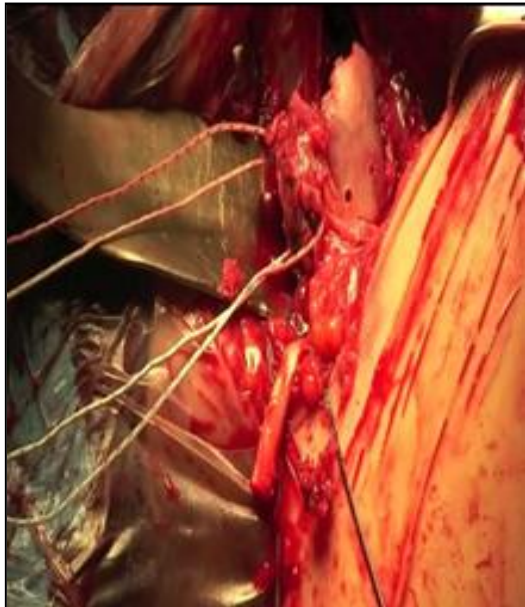

**Fig 11:** Showing reaming of canal

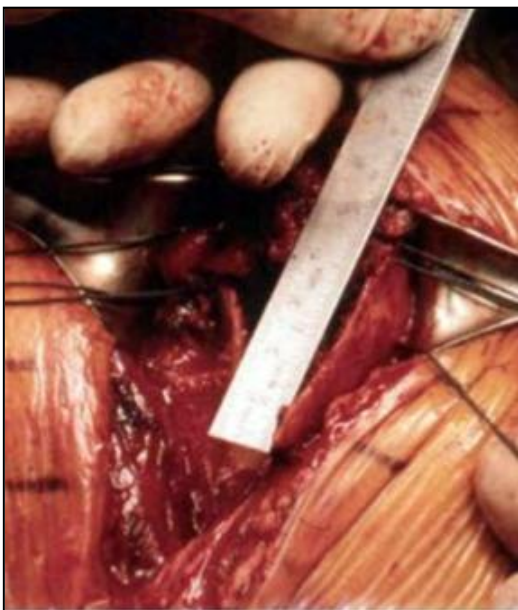



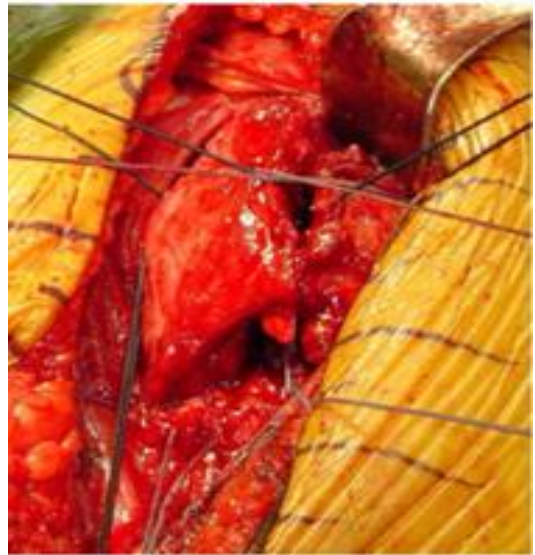**Fig 12:** Showing head matching for size



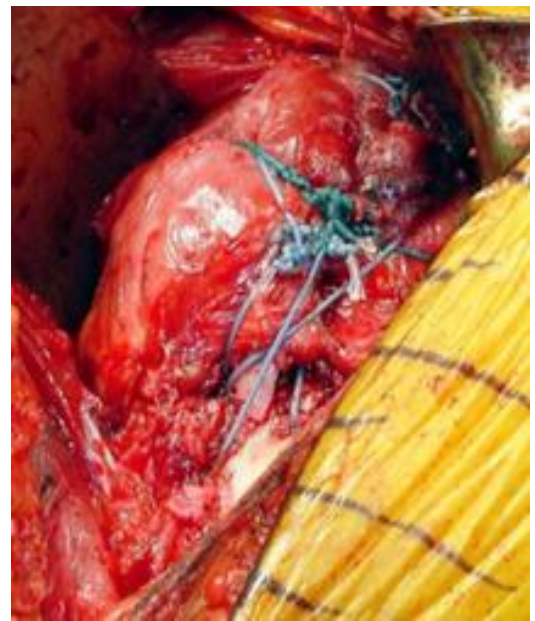**Fig 13:** Showing drill holes of shaft



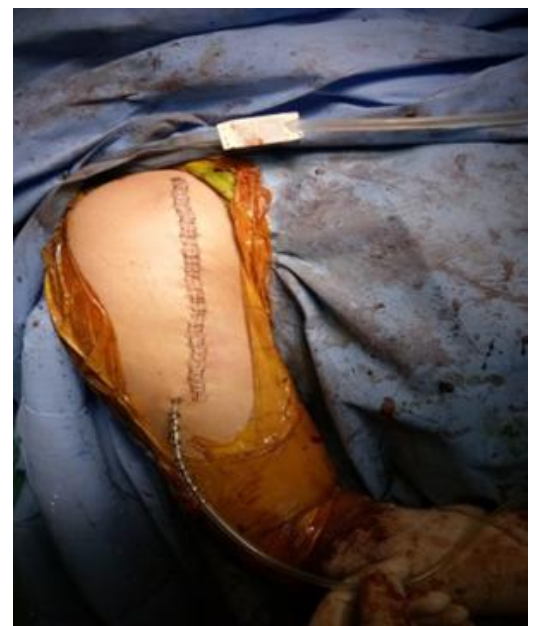**Fig 14:** Showing measurement for proper humeral height



**Fig 15a:** Showing preliminary of reduction of tuberosities



**Fig 15b:** Showing reduction of tuberosities



**Fig 16:** Showing closure of wound over suction drain

## Key components of successful hemiarthroplasty

### Tuberosity Position and Healing

Successful hemiarthroplasty requires union and proper positioning of the tuberosity. Boileau *et al.* [29] assessed clinical and radiologic parameters in a study of 66 patients who underwent hemiarthroplasty for displaced proximal humerus fracture. They concluded that factors associated with failure of tuberosity healing were poor positioning of prosthesis (i.e., excessive height and retroversion) and poor positioning of the tuberosity.

Loebenberg *et al.* [30] demonstrated that active range of motion (ROM) following hemiarthroplasty for four part humerus fracture is affected by the placement of the greater tuberosity fragment relative to the superior margin of the prosthetic head. They concluded that tuberosity placement 10 to 16 mm distal to the superior margin of the prosthetic head resulted in significantly improved active forward elevation and external and internal rotation compared with tuberosities positioned too proximal (3 to 9 mm) or too distal (17 to 28 mm).

### Humeral height

Determining proper prosthetic height is critical to the success of prosthesis humeral replacement and is challenging due to frequent fracture disruption of the medial metaphyseal calcar. Placing the prosthesis too low or high can cause improper tensioning of the deltoid and supraspinatus. Lengthening may result in tuberosity detachment, rotator cuff failure and impingement, whereas shortening reduces length and tension of the deltoid muscle, thus impairing its function [29].

Boileau *et al.* [29] reported that humeral lengthening >10 mm caused by a proud prosthesis significantly correlated with tuberosity detachment and proximal migration of the prosthesis under the acromial arch, resulting in limited function. Humeral lengthening created excessive tension on the supraspinatus. Shortening of the humerus was better tolerated clinically. Functional results were not significantly altered until humeral shortening reached or exceeded 15 mm [29, 31].

An anatomic approach to determining proper humeral height is performed by placing the top of the prosthetic humeral head approximately 5.6 cm proximal to the superior border of the pectoralis major tendon [28]. Preoperatively humeral height can be estimated using Gothic-Arch technique [17].

### Humeral head version

Achieving optimal humeral version is another technical challenge associated with hemiarthroplasty; the most common error is placing the component in excessive retroversion. Excessive retroversion can force malpositioning of the greater tuberosity in the horizontal plane, thereby creating excessive tension on the tuberosity and results in failure of tuberosity union [32].

We recommend placing the humeral component between 20° and 30° of retroversion. Improper version may result in anterior or posterior instability [33]. The transepicondylar axis and bicipital groove can serve as consistent anatomic landmarks when determining humeral head retroversion [34, 35]. Kummer *et al.* [34] demonstrated that 30° of retroversion can be consistently reproduced by placing the lateral fin of the humeral prosthesis 30° posterior to the posterior margin of the bicipital groove.

### Stem design and material

Recently, humeral stems have been designed for more accurate tuberosity placement and optimal bone grafting.

Some stems have window within them for placement of bone graft to enhance tuberosity healing [36]. A coating has also been added to some stems to promote bone healing to the stem. Rough hydroxyapatite coated surface at the metaphyseal portion of the prosthesis to enhance early bonding with bone. Another design has a microsurface of porous tantalum, which helps to stimulate bone healing and may be conducive to direct bone apposition [37]. Studies are needed to determine whether these modifications improve outcomes. Regardless of stem design, surgical technique is the most important factor in a successful outcome.

The so-called unhappy shoulder triad [29], in which the prosthesis is too proud and too retroverted with a greater tuberosity positioned too low, is the worst outcome associated with hemiarthroplasty. The triad inevitably leads to posterior migration of the greater tuberosity, with a poor functional result. Careful surgical technique and adherence to the aforementioned principles can result in successful outcomes.

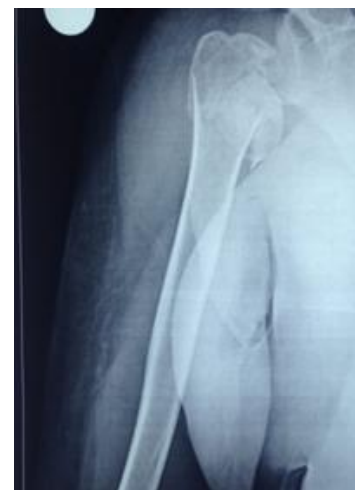

Fig 17a: showing head split fracture.

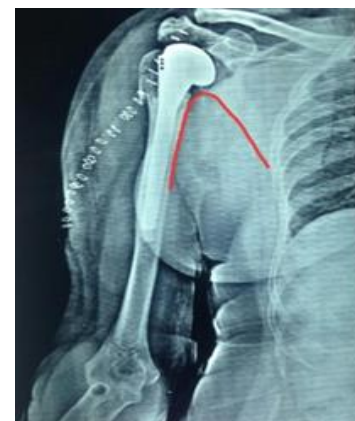

Fig 17b: A well placed prosthesis.

### Postoperative Rehabilitation

Immediately postoperatively, the affected extremity is placed in a sling in slight external or neutral rotation to relieve stress on the greater tuberosity. In general, rehabilitation begins on the first postoperative day. Pendulum and passive ROM exercises to 90° of forward elevation in the scapular plane and gentle external rotation to neutral are performed with the patient supine. The decision to initiate passive ROM exercise should be individualized to the patient and is dependent on the surgeon's confidence in the strength of tuberosity fixation. With tenuous tuberosity fixation, ROM exercises can be delayed for 2 to 3 weeks to minimize stress on the repair.



Gentle active motion of the wrist and elbow is encouraged immediately postoperatively. Active forward elevation and external rotation exercises are delayed until radiographic evidence of tuberosity healing is present. Once tuberosity healing is confirmed radiographically, gentle isometric rotator cuff and scapular strengthening can begin, typically at 6 to 8 weeks following surgery. The estimated maximum level of improvement can be achieved 9 to 12 months postoperatively.

### Conclusion

Proximal humerus fractures are the most common fracture of the shoulder girdle and are a significant health-care burden, especially in the elderly population. It is crucial to perform a full clinical evaluation, including relevant imaging, in order to treat these injuries appropriately. Both patient factors and fracture factors must be taken into consideration in choosing the surgical intervention. Patient factors include age, quality of bone, and the presence of comorbidities, while fracture factors include fracture pattern and timing of injury. In more complex and displaced fractures in osteoporotic bone, hemiarthroplasty is most commonly performed. For clinical success in hemiarthroplasty, the tuberosities need to be reconstructible and possess the potential to heal. Proper humeral height and version must be achieved in order to have successful functional outcome. If tuberosities are not reconstructible or have no potential to heal, reverse total shoulder arthroplasty should be considered.

### References

- Benger U, Johnell Redlund-johnell I. Changes in the incidence of fracture of upper end of humerus during a 30-year period: A study of 2125 fractures. *Clin Orthop Relat Res.* 1988; 231:179-182.
- Kannus P, Palvanen M, Niemi S, Paakkari J, Jarvinen M, Vuori I. Osteoporotic fractures of the proximal humerus in elderly finnish persons: sharp increase in 1970-1998 and alarming projections for the new millennium. *Acta Orthop Scand.* 2000; 71:465-70.
- Solberg BD, Moon CN, Franco DP, Paiement GD. Locked plating of 3-and 4-part proximal humerus fractures in older patients: The effect of initial fracture pattern on outcome. *J Orthop Trauma.* 2009; 23(2):113-119.
- Moonot P, Ashwood N, Hamlet M. Early results for treatment of three and four part fractures of the proximal humerus using the PHILOS plate system. *J Bone Joint Surg. [Br].* 2007; 89-B: 1206-1209.
- Koval KJ, Gallagher MA, Marsicano JG, Cuomo F, McShinawy A, Zuckerman JD. Functional outcome after minimally displaced fractures of the proximal part of the humerus. *J Bone Joint Surg Am.* 1997; 79(2):203-7.
- Jobin CM, Galatza LM. Proximal humerus fractures: pin, plate or replace. *Semin Arthro.* 2012; 23:74-82.
- Compito CA, Self EB, Biglani LU. Arthroplasty and acute shoulder trauma. Reasons for success and failure. *Clin Orthop.* 1994; 307:27-36.
- Bastian JD, Hertel R. Osteosynthesis and hemiarthroplasty of fractures of the proximal humerus: outcomes in a consecutive case series. *J Should Elb Surg.* 2009; 18:216-219.
- Gristina AG, Webb LX, Carter RE. The monospherical total shoulder. *Orthop Trans.* 1985; 9:54.
- Zyto K, Angus W, Frostick SP, Preston BJ. Outcome after hemiarthroplasty for three and four part fractures of the proximal humerus. *J Shoulder Elbow Surg.* 1998; 7:85-89.
- Boileau P, Walch G. The three dimensional geometry of the proximal humerus: implications of surgical technique and prosthetic design, *J Bone Joint Surg.* 1997; 79B:857.
- Wijgman AJ, Roolker W, Patt TW, Raaymakers EL, Marti RK. Open reduction and internal fixation of three and four part fractures of the proximal part of the humerus. *J Bone Joint Surg. [Am].* 2002; 84-A: 1919-1925.
- Schlegel TF, Hawkins RJ. Displaced proximal humeral fractures; Evaluation and treatment. *J Am Acad Orthop Surg.* 1994; 2:54-66.
- Robinson CM, Page RS, Hill RM *et al.* primary hemiarthroplasty for treatment of proximal humerus fractures. *J Bone Joint Surg Am,* 2003, 85-A.
- Ashish B, Ashok KS, Steve R *et al.* *Journal of Orthopaedic Surgery.* 2011; 19(2):194-9.
- Itoi E, Motzkin NE, Morrey BF *et al.* Scapular inclination and inferior stability of the shoulder. *J Shoulder Elbow Surg.* 1992; 1:131-139 1215-23.
- Krishnan SG, Pennington SD, Burkhead WZ, Boileau P. Shoulder arthroplasty for fracture: Restoration of the gothic arch. *Tech Shoulder Elbow Surg.* 2005; 6:57-66.
- Codman E. *The Shoulder: Rupture of the Supraspinatus Tendon and Other Lesions In or About the Subacromial Bursa.* Boston, MA, privately printed, 1934.
- Neer CS II: Displaced proximal humeral fractures: I. Classification and evaluation. *J Bone Joint Surg Am.* 1970; 52(6):1077-1089.
- Hertel R, Hempfing A, Stiehler M, Leunig M. Predictors of humeral head ischemia after intracapsular fracture of the proximal humerus. *J Shoulder Elbow Surg.* 2004; 13(4):427-33.
- Tingart MS, Apprelexa M, Von Stechow D *et al.* The cortical thickness of the proximal humeral diaphysis predicts bone mineral density of the proximal humerus, *J Bone Joint Surg.* 2003; 85B:611.
- Court-Brown CM, Cattermole H, McQueen MM. Impacted valgus fractures (B1.1) of the proximal humerus. The results of nonoperative treatment. *J Bone Joint Surg Br.* 2002; 84(4):504-8.
- Dines DM, Warren RF. Arthroplasty for proximal humerus fractures. In: Dines DM, Lorich DG, Helfet DL, editors. *Solutions for complex upper extremity trauma.* New York: NY, Thieme, 2008, pp. 79-87.
- Edelson G, Safuri H, Salami J, Vigder F, Militianu D. Natural history of complex fractures of the proximal humerus using a three-dimensional classification system. *J Shoulder Elbow Surg.* 2008; 17(3):399-409.
- Rasmussen S, Hvass I, Dalsgaard J, Christensen BS, Holstad E. Displaced proximal humeral fractures: results of conservative treatment. *Injury.* 1992; 23(1):41-3.
- Zyto K. Non-operative treatment of comminuted fractures of the proximal humerus in elderly patients. *Injury.* 1998; 29(5):349-52.
- Krishnan SG, Bennion PW, Reineck JR, Burkhead WZ. Hemiarthroplasty for proximal humeral fracture: restoration of the Gothic arch. *Orthop Clin North Am.* 2008; 39(4):441-50, 4.
- Murachovsky J, Ikemoto RY, Nascimento LG, Milani C, Warner JJ. Pectoralis major tendon reference (PMT): A new method for accurate restoration of humeral length with hemiarthroplasty for fracture. *J Shoulder Elbow Surg.* 2006; 15(6):675-678.
- Boileau P, Krishnan SG, Tinsi L, Walch G, Coste JS,



- Molé D. Tuberosity malposition and migration: Reasons for poor outcomes after hemiarthroplasty for displaced fractures of the proximal humerus. *J Shoulder Elbow Surg.* 2002; 11(5):401-412.
30. Loebenberg MI, Jones DA, Zuckerman JD. The effect of greater tuberosity placement on active range of motion after hemiarthroplasty for acute fractures of the proximal humerus. *Bull Hosp Jt Dis.* 2005; 62(3-4):90-93.
  31. Neer CS II, Kirby RM. Revision of humeral head and total shoulder arthroplasties. *Clin Orthop Relat Res.* 1982; (170):189-195.
  32. Cadet ER, Ahmad CS. Hemiarthroplasty for three and four part proximal humerus fractures. *J Am Acad Orthop Surg.* 2012; 20:17-27.
  33. Murthi A, Bigliani L. Four-part proximal humerus fractures, in Levine WN, Marra G, Bigliani L: *Fractures of the Shoulder Girdle.* New York, NY, Marcel Dekker, 2003, pp. 113-130.
  34. Kummer FJ, Perkins R, Zuckerman JD. The use of the bicipital groove for alignment of the humeral stem in shoulder arthroplasty. *J Shoulder Elbow Surg.* 1998; 7(2):144-146.
  35. Hernigou P, Duparc F, Hernigou A. Determining humeral retroversion with computed tomography. *J Bone Joint Surg Am.* 2002; 84(10):1753-1762.
  36. Kontakis GM, Tosounidis TI, Christoforakis Z, Hadjipavlou AG. Early management of complex proximal humeral fractures using the Aequalis fracture prosthesis: A two- to five-year follow-up report. *J Bone Joint Surg Br.* 2009; 91(10):1335-1340.
  37. Cohen R. A porous tantalum trabecular metal: Basic science. *Am J Orthop (Belle Mead NJ).* 2002; 31(4):216-217.